



Case Report

A rare presentation of leiomyosarcoma metastasis to the cervical spine: A case report and a brief review

Nenad Koruga^{1,2}, Alen Rončević¹, Anamarija Soldo Koruga^{2,3}, Jasmina Rajc^{2,4}, Josipa Flam^{2,5}, Tatjana Rotim^{2,6}, Tajana Turk^{2,6}, Sonja Škiljić^{2,7}, Marijan Cesarik⁸, Tomislav Paun⁸

¹Department of Neurosurgery, University Hospital Center Osijek, ²Faculty of Medicine, Josip Juraj Strossmayer University of Osijek, Departments of ³Neurology, ⁴Pathology and Forensic Medicine, ⁵Oncology, ⁶Diagnostic and Interventional Radiology, ⁷Anesthesiology and Critical Care, University Hospital Center Osijek, Osijek, ⁸Department of Neurology, Požega County Hospital, Požega, Požeško-Slavonska, Croatia.

E-mail: *Nenad Koruga - nkoruga@gmail.com; Alen Rončević - alenron@gmail.com; Anamarija Soldo Koruga - anamarijasoldo@gmail.com; Jasmina Rajc - rajcjasmija@gmail.com; Josipa Flam - jflam@mefos.hr; Tatjana Rotim - tatjana.rotim@gmail.com; Tajana Turk - turk.tajana@gmail.com; Sonja Škiljić - skiljicsonja@gmail.com; Marijan Cesarik - marijan.cesarik@gmail.com; Tomislav Paun - tomlav.paun6@gmail.com



*Corresponding author:

Nenad Koruga,
Department of Neurosurgery,
University Hospital Center
Osijek, Faculty of Medicine,
Josip Juraj Strossmayer
University of Osijek, Osijek,
Croatia.

nkoruga@gmail.com

Received: 27 January 2024

Accepted: 24 March 2024

Published: 12 April 2024

DOI

10.25259/SNI_66_2024

Quick Response Code:



ABSTRACT

Background: Leiomyosarcoma (LMS) is a rare malignancy that originates from smooth muscle. The most common sites of metastases include the lungs, liver, kidney, and skin. Notably, metastases of LMS to the central nervous system/or spine are extremely rare. When a cervical spinal LMS lesion was encountered, the patient successfully underwent gross total tumor resection with negative margins.

Case Description: A 63-year-old female had undergone an anterior cervical C5–C7 discectomy and fusion 18 years ago and resection of a retroperitoneal LMS 3 years ago. She newly presented with right-sided numbness and pain of 2 months duration that correlated with a focal right-sided C5-level hemiparesis (i.e., 4/5 motor strength). When the cervical magnetic resonance demonstrated a right-sided C5 intralaminar mass with extension into the C5–C6 foramen, she underwent posterior tumor resection; pathologically, this proved to be an LMS metastasis. Respectively, 1- and six months postoperatively, follow-up magnetic resonance imaging scans showed no tumor recurrence; she tolerated adjuvant oncological treatment accompanied by physical therapy. However, in one postoperative year, the lesion recurred, and she is presently under consideration for additional surgical management.

Conclusion: Gross total surgical resection is the first line of treatment for patients with metastatic LMS. Here, a patient with a C5 lamina/C5–C6 foraminal bony LMS metastasis underwent posterior tumor resection accompanied by adjuvant oncological treatment but exhibited disease recurrence within one postoperative year.

Keywords: Leiomyosarcoma, Metastasis, Radiculopathy, Spine

INTRODUCTION

Leiomyosarcoma (LMS) is a rare malignant tumor that arises from smooth muscle cells. It most commonly involves the uterus, followed by the gastrointestinal tract and retroperitoneum; its incidence is 0.7 cases per 100,000 patients/year.^[1] Metastases of LMS typically spread to the lungs, liver, kidneys, and skin; it is only rarely encountered in the central nervous system or spine.^[2] Metastatic LMS spinal lesions classically have a poor prognosis due to the high risk for tumor recurrence and relative resistance to radiation and/or chemotherapy.^[8] Here, a 63-year-

This is an open-access article distributed under the terms of the Creative Commons Attribution-Non Commercial-Share Alike 4.0 License, which allows others to remix, transform, and build upon the work non-commercially, as long as the author is credited and the new creations are licensed under the identical terms.

©2024 Published by Scientific Scholar on behalf of Surgical Neurology International

old female who, in 2021, had a retroperitoneal LMS resected newly presented with a right C5 level hemiparesis attributed to a C5 laminar/C5–C6 bony foraminal lesion. Following resection, the lesion proved to be a LMS metastasis that recurred within one year following gross total tumor removal despite adjuvant oncologic treatment.

CASE REPORT

A 63-year-old female presented with a right mild hemiparesis (i.e., 4/5 motor deficit) and relative right-sided C5 sensory level of 1 month's duration. In 2005, she had a C5–C7 anterior cervical discectomy and fusion, while in 2021, she had a retroperitoneal LMS completely removed. She underwent posterior surgical resection of the right-sided C5 laminar/C5–C6 bony foraminal lesion documented by magnetic resonance imaging (MRI) that proved to be a LMS metastasis [Figure 1]. Immunostained slides and histological findings revealed atypical, polymorphic spindle cells with numerous mitoses and smaller foci of necrosis; cells were immunohistochemically positive for smooth muscle actin, muscle-specific actin, and desmin; marker CD34 was negative [Figure 2].

Postoperative course

Postoperative cervical MRI scans revealed no tumor recurrence 1 and 6 months postoperatively [Figures 3-5].

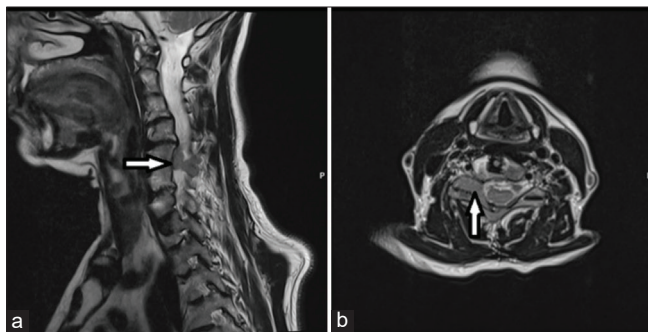


Figure 1: Preoperative sagittal (a) and axial (b) T2-weighted MRI scans revealed the right-sided tumor mass lesion at the levels of C5 and C6. Arrows point to the primary tumor site on both images.

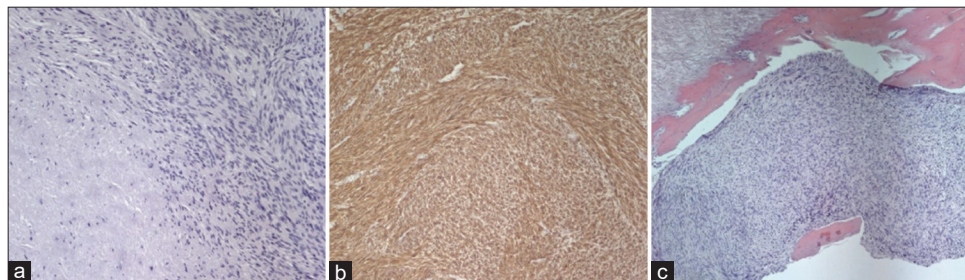


Figure 2: (a) $\times 10$ magnification – Hematoxylin and eosin staining: Spindle-shaped cells with moderate nuclear pleomorphism, with area of necrosis, (b) $\times 10$ magnification – Immunohistochemical staining, diffuse smooth muscle actin, positivity in tumor cells, and (c) $\times 5$ magnification – hematoxylin and eosin staining, tumor infiltration, and destruction of the bone.

Postoperative follow-up computed tomography scan of the thorax, abdomen, and pelvis two months after surgery also revealed no additional metastatic tumors; the patient underwent adjuvant oncologic treatment (i.e., docetaxel and gemcitabine) during a timespan of 4 weeks. However, one year later, the C5 lesion recurred, and she is presently undergoing consideration for additional surgical treatment.

DISCUSSION

LMS rarely metastasizes to the spine

LMSs are highly malignant tumors that rarely metastasize to the spine. Sun *et al.*, in 2013, reported a metastatic LMS lesion to the cervical spine with destruction of the C6 vertebra; the patient underwent an anterior decompression and fusion.^[8] In 2022, LiBrizzi *et al.* retrospectively analyzed bone metastases in LMS patients; most involved the femur, humerus, and spine; the latter were typically managed with kyphoplasty, decompression alone, and/or decompression and fusion.^[4]

Survival rates for spinal LMS

LMS are aggressive, highly malignant lesions that frequently recur and metastasize.^[5] Elhammady *et al.*,^[2] in 2007 and Ziewacz *et al.*,^[10] in 2012 both presented large groups of patients with LMS; the five patients in the former study demonstrated a better overall survival rate of 8.6 years versus 10.7 month-survival for the nine patients in the latter series.^[5]

Bony metastases for LMS lesions

LMS rarely causes osseous spinal vertebral metastases.^[6] In their meta-analysis, Imura *et al.* concluded that chemotherapy could prolong survival in patients with LMS metastases who were ineligible for resection of metastatic lesions.^[3] Recently, published studies documented several primary cervical spinal LMS lesions [Table 1] following both surgery and oncologic treatment in which the longest recurrence-free survival was 38 months.^[7,9,10]

Table 1: Comparison of two recently published studies of primary LMS of the cervical spine with two metastatic cases.

Author/year	Radiologic findings/study	Treatment	Follow-up/outcome
Sun <i>et al.</i> , 2022	C3–C5, case report, primary LMS	GTR+ Radiotherapy	1 month, alive
Zhang <i>et al.</i> , 2022	C2–C3, primary LMS C4, primary LMS C2, primary LMS	Subtotal resection GTR GTR+Radiotherapy	6 months, progression-free survival 38 months, recurrence-free
Sun <i>et al.</i> , 2014	C6, metastasis	GTR+Radiotherapy	13 months, progression-free survival
Our study, 2023	C5, metastasis	GTR+Chemotherapy	12 months, recurrence-free survival

GTR: Gross total removal, LMS: Leiomyosarcoma

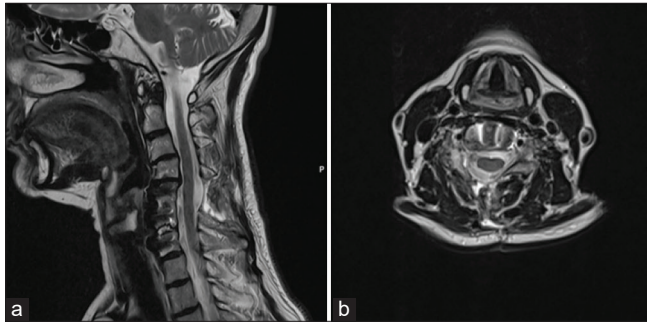


Figure 3: Postoperative sagittal (a) and axial (b) MRI T2-weighted scans one month after surgery revealed a complete tumor removal.

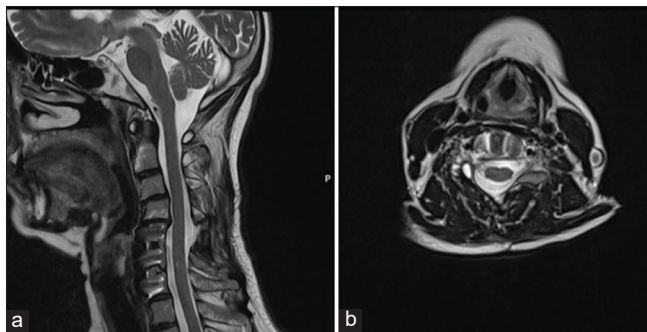


Figure 4: Postoperative sagittal (a) and axial (b) MRI T2-weighted scans six months after surgery revealed a complete tumor removal, no tumor remnants and recurrences.

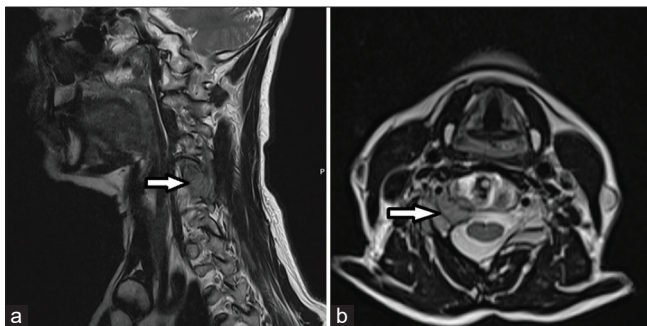


Figure 5: Postoperative sagittal (a) and axial (b) MRI T2-weighted scans a year after surgery revealed tumor recurrence at the previous surgical site. Arrows depict sites of tumor recurrence on both images.

CONCLUSION

The prognosis for patients with metastatic LMS is poor due to the high rate of metastases. Here, a 63-year-old female with a 2021 diagnosis of a retroperitoneal LMS was newly presented with a C5 laminar/C5–C6 foraminal bony lesion that, despite gross total posterior excision, recurred one year later.

Ethical approval

The Institutional Review Board approval is not required.

Declaration of patient consent

The authors certify that they have obtained all appropriate patient consent.

Financial support and sponsorship

Nil.

Conflicts of interest

There are no conflicts of interest.

Use of artificial intelligence (AI)-assisted technology for manuscript preparation

The authors confirm that there was no use of artificial intelligence (AI)-assisted technology for assisting in the writing or editing of the manuscript, and no images were manipulated using AI.

REFERENCES

1. Ducimetière F, Lurkin A, Ranchère-Vince D, Decouvelaere AV, Peoc’h M, Istier L, *et al.* Incidence of sarcoma histotypes and molecular subtypes in a prospective epidemiological study with central pathology review and molecular testing. *PLoS One* 2011;6:e20294.
2. Elhammady MS, Manzano GR, Lebwohl N, Levi AD. Leiomyosarcoma metastases to the 207spine. Case series and review of the literature. *J Neurosurg Spine* 2007;6:178-83.
3. Imura Y, Takenaka S, Outani H, Nakai T, Yasuda N, Nakai S,

- et al.* Impact of surgery and chemotherapy on metastatic extrauterine leiomyosarcoma. *Curr Oncol* 2022;29:2301-11.
4. LiBrizzi CL, Vankara A, Meyer CF, Levin AS, Morris CD. Bone metastases in patients with leiomyosarcoma: A retrospective analysis of survival and surgical management. *Sarcoma* 2022;2022:6806932.
 5. Maimone G, Nicassio N, Malik I, Cambria M. Metastatic leiomyosarcoma of the spine 216 updates in management and surgical strategy. *Open J Mod Neurosurg* 2013;3: 98-103.
 6. Shapiro S. Myelopathy secondary to leiomyosarcoma of the spine. *Case report. Spine* 1992;17:249-51.
 7. Sun H, Zhuang M, Cheng D, Zhu C, Liu Z, Qiu X. Primary leiomyosarcoma of cervical spine invading the vertebra without obvious osteoclasia: Case report and literature review. *J Spinal Cord Med* 2022;45:643-7.
 8. Sun Z, Wang H, Yang H, Jiang W. Leiomyosarcoma metastatic to the cervical spine causing a C6 compression fracture: A case report. *Oncol Lett* 2014;8:263-5.
 9. Zhang J, Chen Y, Xing X, Wang Q, Liu K, Zhang E, *et al.* Primary leiomyosarcoma of the spine: an analysis of imaging manifestations and clinicopathological findings. *Insights Imaging* 2022;13:195.
 10. Ziewacz JE, Lau D, La Marca F, Park P. Outcomes after surgery for spinal metastatic leiomyosarcoma. *J Neurosurg Spine* 2012;17:432-7.

How to cite this article: Koruga N, Rončević A, Soldo Koruga A, Rajc J, Flam J, Rotim T, *et al.* A rare presentation of leiomyosarcoma metastasis to the cervical spine: A case report and a brief review. *Surg Neurol Int.* 2024;15:128. doi: 10.25259/SNI_66_2024

Disclaimer

The views and opinions expressed in this article are those of the authors and do not necessarily reflect the official policy or position of the Journal or its management. The information contained in this article should not be considered to be medical advice; patients should consult their own physicians for advice as to their specific medical needs.