

Comparison of horizontal versus vertical split conjunctival autograft in the management of double head pterygium: A retrospective analysis

Shreesha Kumar Kodavoor, Soundarya B¹, Ramamurthy Dandapani²

Purpose: To compare horizontal and vertical split conjunctival autograft technique in the management of double head pterygium. **Methods:** Retrospective analysis of 96 and 99 eyes with double head pterygia that underwent horizontal (Group 1) and vertical (Group 2) split conjunctival autografting, respectively. Comparison of recurrence rates and other complications was done. **Results:** Recurrence was seen in 5.2% and 4% of the eyes in Groups 1 and 2, respectively ($P > 0.05$). Other complications like subconjunctival hemorrhage, graft edema, graft retraction, granuloma, and graft loss were also comparable among the two groups. **Conclusion:** Both the techniques provide good results with comparable efficacy in terms of rates of recurrence and complication profiles.

Key words: Conjunctival autograft, double head pterygium, split conjunctival autograft

Access this article online

Website:

www.ijo.in

DOI:

10.4103/ijo.IJO_235_20

Quick Response Code:



Pterygium, being a common ocular surface disorder, presents with a wing-shaped overgrowth of the bulbar conjunctiva over the limbus, most often nasally. The presence of both nasal and temporal pterygia in the same eye, termed as double-head pterygium, is not so rare in tropical countries like India.^[1] The recurrence rates following conjunctival autografting in the management of pterygium range from 2% to 39%.^[2,3] There is a need for a larger size donor tissue in beheaded pterygia to cover both sites of bare sclera adequately in order to reduce the risk of recurrence. This poses a challenge in treating such cases. Numerous surgical procedures have been described, some of which include split conjunctival grafts, amniotic membrane transplantation, and conjunctival rotational autograft.^[1,4,5] This study aims at studying the two methods of split conjunctival autografts, i.e., horizontal and vertical split techniques, and comparing their outcomes on the basis of complication rates.

Methods

Ninety-six eyes of 96 patients who underwent double-headed pterygium excision with horizontal split conjunctival autograft and 99 eyes of 99 patients who underwent double-headed pterygium excision with vertical split conjunctival autograft from 2011 to 2017 were retrospectively analyzed in the study. The study was approved by the Ethics committee and adhered to the tenets of Declaration of Helsinki. The procedure of choice for each patient was selected on the basis of the size of the bare scleral defects following pterygium tissue excision. In cases of larger defects, a horizontal graft split technique was used due to the availability of larger sized grafts in this technique. All surgeries were performed by a single surgeon at a tertiary eye care hospital in south India.

Cornea Services, ¹Cornea, Refractive and Cataract Surgery, ²Chairman, The Eye Foundation, Coimbatore, Tamil Nadu, India

Correspondence to: Dr. Shreesha Kumar Kodavoor, Cornea Services, The Eye Foundation, 582, Diwan Bahadur Rd, R.S. Puram, Coimbatore - 641 002, Tamil Nadu, India. E-mail: eskay_03@rediffmail.com

Received: 04-Feb-2020

Revision: 01-Apr-2020

Accepted: 24-Jun-2020

Published: 15-Dec-2020

Clinical history and visual acuity before the surgery were recorded. Pterygium was graded according to the extent of involvement (grade-1: crossing limbus; grade-2: midway between limbus and pupil; grade-3: reaching up to pupillary margin; and grade-4: crossing pupillary margin). Up to grade-3 primary double-head pterygia were included in this study. Grade-4 and recurrent pterygia were excluded from the study. In most of the cases, the nasal head was of a higher grade than the temporal head.

Surgical technique

Patients in both the groups underwent the procedure under topical anesthesia and local infiltration. The nasal pterygium head was first avulsed and fibrovascular tissue was excised followed by the same procedure for the temporal pterygium. Hemostasis was achieved using gentle wet field cautery. Adequate sized graft was harvested from the superior conjunctiva with meticulous dissection of conjunctiva from the Tenon's capsule. The conjunctiva was split horizontally into two parts in the Group 1 patients, whereas vertical splitting was done in Group 2 [Figs. 1 and 2]. In the horizontal split group, the grafts were oversized by 0.25 mm on all sides. In vertical split, it was just adequate to cover the defect size. The split grafts were each placed over the nasal and temporal defects and were secured using fibrin glue, Tisseel (Baxter, Vienna, Austria) in both groups. In Group 1, the limbal orientation was maintained on the nasal side for maintaining uniformity. In Group 2, the limbal orientation was maintained on both sides while securing the grafts.

The patients were followed up on postoperative day 1, 2 weeks, 6 weeks, 6 months, and at 1 year. Any patient with a follow-up of

This is an open access journal, and articles are distributed under the terms of the Creative Commons Attribution-NonCommercial-ShareAlike 4.0 License, which allows others to remix, tweak, and build upon the work non-commercially, as long as appropriate credit is given and the new creations are licensed under the identical terms.

For reprints contact: WKHLRPMedknow_reprints@wolterskluwer.com

Cite this article as: Kodavoor SK, Soundarya B, Dandapani R. Comparison of horizontal versus vertical split conjunctival autograft in the management of double head pterygium: A retrospective analysis. Indian J Ophthalmol 2021;69:66-8.

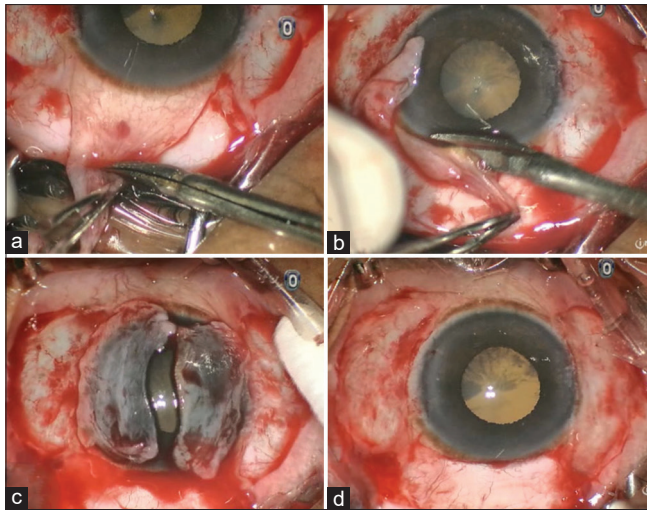


Figure 1: Horizontal split CAG. (a) Horizontal splitting of graft. (b) Separating graft from limbal end. (c) Placement and orientation of grafts. (d) Grafts secured with tissue glue

less than 6 months was excluded from the study. The outcome was measured in terms of the complications and was compared between the two groups, with recurrence being considered as the primary complication. Recurrence was defined as fibrovascular tissue growth of 1.5 mm or more beyond the limbus onto the clear cornea with conjunctival dragging as described by Singh *et al.*^[6] Other complications noted and compared were graft edema, retraction, subconjunctival hemorrhage, dellem, graft loss, and formation of granuloma. Statistical analysis was done using the z-score test to compare and identify any statistically significant difference between the occurrence of complications between the two groups ($P < 0.05$).

Results

A total of 195 eyes with double head pterygia were studied, out of which 96 eyes and 99 eyes underwent horizontal and vertical split conjunctival autografting, respectively. The mean age of the patients in Group 1 was 46.18 \pm 12.22 years and in Group 2 was 46.83 \pm 10.78 years. The male: female ratio was 33:63 and 36:63 in Group 1 and Group 2, respectively. The patients in Group 1 had a mean follow-up of 16.79 \pm 6.39 months whereas the Group 2 patients had a mean follow-up of 18.30 \pm 7.48 months. The shortest and longest follow-up in Group 1 was 7 months and 34 months, whereas, in Group 2, it was 7 months and 44 months, respectively. The demographic data is summarized in Table 1.

The primary outcome compared was the rate of recurrence. Recurrence was seen in five eyes (5.2%) in the horizontal split CAG group and four eyes (4.04%) in the vertical split CAG group. The difference between the two groups was not statistically significant ($P > 0.05$). Among the recurrences, Group 1 had two recurrences on the nasal side and three on the temporal side, whereas Group 2 had three on the nasal side and one on the temporal side. The preoperative grading of pterygia in eyes with recurrence was grade-3 in all nasal recurrences and grade-2 on temporal recurrences. The mean period of recurrence following surgery was 8.2 \pm 2.27 months in Group 1 and 7 \pm 2.34 months in Group 2 with the earliest recurrence noted at 6 months and 5 months in Group 1 and 2, respectively. Other complications seen were subconjunctival hemorrhage, graft retraction, transient graft edema, granuloma, and graft loss. They are listed in Table 2. All five cases of recurrence in Group 1 and three out of the four cases in Group 2 had graft retraction. Two out of five cases of

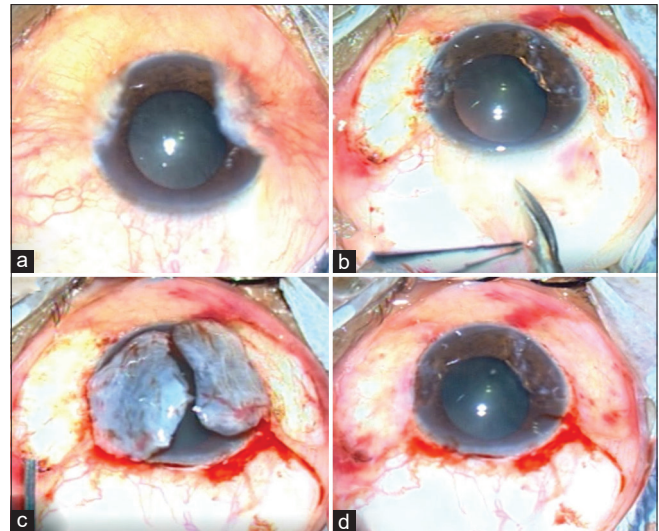


Figure 2: Vertical split CAG. (a) Intraoperative image of double head pterygium. (b) Vertical splitting of grafts. (c) Placement and orientation of grafts without limbal orientation. (d) Grafts secured with tissue glue

Table 1: Demographic data

Parameters	Horizontal Split CAG	Vertical split CAG
Total number of eyes	96	99
Mean age (years)	46.18 \pm 12.22	48.83 \pm 10.78
Male:Female	33:63	41:58
Mean follow up (months)	16.79 \pm 6.39	18.30 \pm 7.48

recurrence in Group 1 had a history of granuloma, whereas none of the eyes with recurrence had developed granuloma. There was no statistically significant difference among the two groups in the complications except in graft loss, which was seen in three eyes in the vertical split CAG group with no incidence in the horizontal split CAG group. The three cases of graft loss were seen at 2-week follow-up. These cases were included in the study. Three out of the four recurrences that later developed had graft loss. Among the graft loss, two were nasal (preoperative grade-3) and one was temporal (preoperative grade-2). The reason for graft loss in the vertical split CAG group could not be explained.

Discussion

Reduced recurrence rate is considered the most important treatment outcome in managing pterygia. This holds good even in cases of double head pterygia, where there is no fixed gold standard method currently. The older bare sclera technique^[7] has been surpassed by surgical procedures with newer modifications which aim at preventing recurrences. Among the various techniques followed like the sliding conjunctival flaps, extended removal of pterygium with an extended conjunctival transplant, amniotic membrane grafting, and use of adjunctive agents (mitomycin C and β -irradiation), the most widely used method is conjunctival autografting.^[8-10]

The autografting technique in case of double head pterygia has to be modified to provide a graft cover for two bare scleral defects on either side. This can be achieved by either splitting the graft vertically or horizontally. Both these techniques have been found to provide cosmetically acceptable results with reduced recurrence rates.^[1,11-14]

Table 2: Comparison of complications between the two groups

Complication	Horizontal Split CAG	Vertical split CAG	P
Recurrence	5 (5.20)	4 (4.04)	0.69
SCH	28 (29.16)	22 (22.22)	0.26
Graft retraction	17 (17.70)	21 (21.21)	0.53
Transient graft edema	56 (58.33)	50 (50.50)	0.27
Granuloma	2 (2.08)	2 (2.02)	0.97
Graft loss	0 (0.0)	3 (3.03)	0.08

SCH: Subconjunctival Haemorrhage

The prerequisite for these techniques is the harvesting of a sufficiently large superior conjunctival graft to cover both nasal and temporal bare scleral areas. Another point to be considered here is the maintenance of the limbal orientation of the graft, which may not be possible in all cases, especially in cases with large bare scleral defects. As seen from the results of our study, no significant difference among the incidence of complications in the two techniques was found. In cases where horizontal splitting of the graft was done, limbus to limbus orientation was maintained only on one side where the inferior or the limbal half of the conjunctiva is used. There was no difference in rates of recurrence among the two heads in the group, which shows that limbal orientation is not an essential factor to prevent recurrence.

The management of double-headed pterygium has been studied by a few. In a study conducted by Maheshwari,^[1] seven eyes with double head pterygium that underwent horizontal split CAG were retrospectively analyzed with a mean follow-up of 17.7 ± 6 months and no recurrence was reported. Duman and Kosker,^[12] and Elhamaky and Elbarky^[14] reported no recurrence in eyes which underwent vertical split conjunctival autografting at 12-month follow-up in eight eyes and fifteen eyes with double head pterygia, respectively. All the above studies had a shortcoming of having a small sample size.

A previous study conducted by us on a different study group at our institute by Kodavoor *et al.* followed the technique of vertical split graft without limbal orientation in 87 eyes with double head pterygium with a mean follow up period of 17.28 ± 10.28 months and have reported a recurrence rate of 3.45%.^[13] Another study published by us followed a similar method for 95 eyes with double head pterygia and found a recurrence rate of 2.1%.^[15]

Inferior bulbar conjunctiva has also been found as a good donor alternative for superior bulbar conjunctiva; however, due to the difficulty in obtaining a thin Tenon's free graft and the increased rates of scarring, it may not be cosmetically acceptable. A method of conjunctival rotational autograft for one head and conjunctival autograft from the superior conjunctiva for the other was reported by Wu *et al.*^[5] on 20 patients where they found a recurrence rate of 35% with no statistically significant difference between the two methods followed for each head. Another comparative study conducted by Chan *et al.* studied the effects of CAG vs. Mitomycin C for double headed pterygia in 36 patients with a 12-year follow-up. One head underwent CAG, whereas after excision of the other head, MMC was applied on the bare sclera followed by suturing of the conjunctiva to the episclera. They found that CAG had a lower recurrence rate of 6.3% while compared to the use of MMC which had a recurrence rate of 28.1%.^[16] Amniotic membrane grafting is another option which has shown good results with recurrence rates of 3.8% to 5.6%.^[17,4] A study conducted by Lee *et al.*^[11] compared seven eyes that underwent amniotic membrane transplant with nine eyes that underwent horizontal split conjunctival autograft for double

head pterygia. They concluded that split CAG was superior to amniotic membrane grafting in terms of reduced recurrences as well as better cosmetic outcomes. Amniotic membrane grafting also adds to the cost of the procedure unlike CAG.

Conclusion

In cases of double head pterygia, finding a suitable method to provide good scleral coverage on both the bare areas becomes important to prevent or reduce recurrence. Our study is the first to compare vertical and horizontal split conjunctival autografts in the management of such cases. From this study, it can be concluded that both the above mentioned techniques provide good results, with comparable efficacy in terms of rates of recurrence and complication profiles.

Financial support and sponsorship

Nil.

Conflicts of interest

There are no conflicts of interest.

References

- Maheshwari S. Split-conjunctival grafts for double-head pterygium. *Indian J Ophthalmol* 2005;53:53-5.
- Kenyon KR, Wagoner MD, Hettlinger ME. Conjunctival autograft transplantation for advanced and recurrent pterygium. *Ophthalmology* 1985;92:1461-70.
- Lewallen SA. Randomized trial of conjunctival autografting for pterygium in the tropics. *Ophthalmology* 1989;96:1612-4.
- Solomon A, Pires RT, Tseng SC. Amniotic membrane transplantation after extensive removal of primary and recurrent pterygia. *Ophthalmology* 2001;108:449-60.
- Wu WK, Wong VW, Chi SC, Lam DS. Surgical management of double-head pterygium by using a novel technique: Conjunctival rotational autograft combined with conjunctival autograft. *Cornea* 2007;26:1056-9.
- Singh G, Wilson MR, Foster CS. Long-term follow-up study of mitomycin eye drops as adjunctive treatment of pterygia and its comparison with conjunctival autograft transplantation. *Cornea* 1990;9:331-4.
- Jaros PA, De Luise VP. Pingueculae and pterygia. *Surv Ophthalmol* 1988;33:41-9.
- Hirst LW, Smallcombe K. Double-headed pterygia treated with P.E.R.F.E.C.T for PTERYGIUM. *Cornea* 2017;36:98-100.
- Shahin MM, Elbendary AM, Elwan MM. Intraoperative subconjunctival bevacizumab as an adjunctive treatment in primary pterygium: A preliminary report. *Ophthalmic Surg Lasers Imaging* 2012;43:459-66.
- Zarei-Ghanavati M, Ghassemi H. Surgical management of pterygium. In: Djalilian A, editor. *Ocular Surface Disease*. Cham, Switzerland: Springer; 2017. p. 307-17.
- Lee BH, Lee GJ, Park YJ, Lee KW. Clinical research on surgical treatment for double-head pterygium. *J Korean Ophthalmol Soc* 2010;51:642-50.
- Duman F, Kosker M. Surgical management of doublehead pterygium using a modified split-conjunctival autograft technique. *Semin Ophthalmol* 2016;32:569-74.
- Kodavoor SK, Ramamurthy D, Tiwari N. Double-head pterygium excision with modified vertically split-conjunctival autograft: Six-year long-term retrospective analysis. *Indian J Ophthalmol* 2017;65:700-4.
- Elhamaky TR, Elbarky AM. Outcomes of vertical split conjunctival autograft using fibrin glue in treatment of primary double-headed Pterygia. *J Ophthalmol* 2018;2018:9341846.
- Kodavoor SK, Tiwari N, Ramamurthy D. Long-term analysis of an unconventional way of doing double-head pterygium excision. *Oman J Ophthalmol* 2019;12:166-70.
- Chan TC, Wong RL, Li EY, Yuen HK, Yeung EF, Jhanji V, *et al.* Twelve-year outcomes of pterygium excision with conjunctival autograft versus intraoperative mitomycin C in double-head pterygium surgery. *J Ophthalmol* 2015;2015:891582.
- Ma DHK, See LC, Liau SB, Tsai RJF. Amniotic membrane graft for primary pterygium: Comparison with conjunctival autograft and topical mitomycin C drops. *Br J Ophthalmol* 2000;84:973-8.