

CASE REPORT

LV pacing as an alternative option to conventional RV pacing in a patient with tricuspid valve replacement

Svetoslav Iovlev MD, PhD  | Nezabravka Chilingirova MD

"Saint Ekaterina" University Multiprofile Hospital for Active Treatment – Sofia, Bulgaria

Correspondence

Svetoslav Iovlev, "Saint Ekaterina" University Multiprofile Hospital for Active Treatment – Sofia, Sofia, Bulgaria.
Email: sviolev@yahoo.com

Abstract

Tricuspid regurgitation (TR) is a relatively common anomaly. In patients with tricuspid valve repair/replacement (TVR) the control of atrioventricular conduction irregularity can be demanding, given the unavailability for implantation of the right ventricular (RV) endocardial lead, which is not recommended in such cases because of the risk of lead fracture at the valve site and valve damage or failure. Thus, epicardial lead may be an option; it requires a surgical procedure and it is not preferred in patients with prior thoracotomy. Lead implantation via coronary sinus (CS) can be an alternative to conventional right ventricular pacing in this patient population.

KEYWORDS

CRT, tricuspid regurgitation, tricuspid valve repair

1 | INTRODUCTION

Tricuspid regurgitation (TR) is a relatively common anomaly. Because of the fact that it exists without any symptoms, it is very often proved only by echocardiography.

The existing data show that in patients with moderate or severe TR the mortality rate is very high.¹

Usually, heart valve repair is the first choice because it is associated with a lower risk of infection, it preserves and optimizes heart function and may reduce the potential need for long-term use of antiplatelet drugs compared to heart valve replacement.

In cases when the valve cannot be repaired, replacement is necessary; sometimes repaired valves may eventually require replacement. In addition, heart valve repair surgery is often harder to perform successfully than valve replacement surgery. Biological heart valves are preferred than mechanical ones.

The need of cardiac stimulation in patients with tricuspid valve repair/replacement is under discussion. One of the reasons for this is that endocardial leads, especially defibrillator (DF) ones that go through the valve, can additionally worsen valve functioning. The leads create a few problems: pressure on the valve leaflets,

conglutination, perforation, etc.² Lead extraction in cases with moderate to severe tricuspid valve insufficiency cannot decrease it.

Complication avoiding strategies in cases with necessity for cardio stimulation.

If the lead is already implanted:

1. to be sewed outside the valve ring.
2. the lead to be exchanged with an epicardial one³

What about left ventricular (LV) lead implantation?

Recently, there have been very few clinical cases of implantation of LV lead in a CS vessel branch in patients with tricuspid valve repair or replacement reported.

2 | CASE REPORT

In my practice there is such a case of a patient with implanted biological tricuspid valve and mitral mechanical valve repair (MVR) with severe stenosis of the biological tricuspid valve and symptomatic bradyarrhythmia. The patient had clear indication for cardiac stimulation therapy. Because

This is an open access article under the terms of the Creative Commons Attribution-NonCommercial License, which permits use, distribution and reproduction in any medium, provided the original work is properly cited and is not used for commercial purposes.

© 2020 The Authors. *Journal of Arrhythmia* published by John Wiley & Sons Australia, Ltd on behalf of the Japanese Heart Rhythm Society.

of the valve obstructions mentioned above, an implantation of endocardial lead in the RV was not possible. The option for an epicardial one was discussed with the patient but was refused. The necessity of cardiac stimulation was a fact, so we needed to find an alternative approach. LV lead implantation was discussed. The venography of the CS showed good posterior-lateral branch and the lead was implanted there (Figure 1).

3 | CONCLUSION

This case shows an alternative approach in patients who need cardiac stimulation and have tricuspid valve repair or replacement.

Cardiac resynchronization therapy (CRT) device with one lead implanted in a branch of the coronary sinus will take place even more frequently in the future in such cases.

4 | DISCUSSION

According to the contemporary guideline recommendations, permanent pacemaker implantation is the first choice for the treatment of patients with slow Atrioventricular conduction.⁴ However, when these patients have a biological tricuspid valve replacement, a pacemaker implantation becomes a demanding procedure. The conventional implantation of an endocardial pacing lead is not recommended with biological TVR because of the risk of lead fracture at the valve site and valve damage or failure. Comparably, the removal of an existing endocardial lead is often necessary when tricuspid valve prosthesis is indicated. Leadless pacing also requires crossing the biological tricuspid valve to be implanted and thus is also not recommended.^{5,6}

Usually, when the RV is inaccessible for lead implantation, an epicardial pacing lead is used. An important consideration in the

placement of an epicardial pacing lead is that it requires a surgical approach which can pose technical difficulties and can prolong hospital stays. In patients who have had multiple prior sternotomies or thoracotomies with resultant scar tissue and adhesion formation, as in the case of our patient, the risk of performing another surgery for epicardial lead placement can be associated with considerable morbidity.

In cases when the inaccessibility of the RV and the high risk of a repeated thoracotomy preclude the placement of endocardial or epicardial pacing leads, it is imperative to consider an alternative approach for pacing via the CS. This approach is not only minimally invasive but it also provides a stable position in the coronary vein, a reliable low threshold and an adequate ventricular pacing. On the other hand, risks of CS pacing include diaphragmatic stimulation, coronary vein dissection, lead displacement, and infection.

The advancement in specialized leads with guiding catheters designed to allow easier access to the CS ostium and to the venous system facilitated left ventricular long-term pacing and transformed it into a more reliable and feasible option. Left ventricular pacing via the CS may therefore be considered as an alternative for the management of atrioventricular conduction abnormalities in patients with inaccessible RV.

CONFLICT OF INTEREST

The authors declare no conflict of interest for this article.

ORCID

Svetoslav Iovcev  <https://orcid.org/0000-0003-4949-5334>

REFERENCES

- Nath J, Foster E, Heidenreich PA. Impact of tricuspid regurgitation on long-term survival. *J Am Coll Cardiol*. 2004;43(3):405–9.
- Mohaissen MA, Chan KL. Prevalence and mechanism of tricuspid regurgitation following implantation of endocardial leads for pacemaker or cardioverter-defibrillator. *J Am Soc Echocardiogr*. 2012;25(3):245–52. Epub 2012 Jan 27.
- Nishimura RA, Otto CM, Bonow RO, Carabello BA, Erwin JP 3rd, Guyton RA, et al. American College of Cardiology/American Heart Association Task Force on Practice Guidelines; 2014 AHA/ACC guideline for the management of patients with valvular heart disease: a report of the American College of Cardiology/American Heart Association Task Force on Practice Guidelines. *J Am Coll Cardiol*. 2014;63(22):e57. Epub 2014 Mar 3.
- ACC/AHA Task Force. ACC/AHA/HRS 2008 guidelines for device-based therapy of cardiac rhythm abnormalities. *Circulation*. 2008;117:E350–E408.
- Reddy VY, Exner DV, Cantillon DJ, Doshi R, Bunch TJ, Tomassoni GF, et al; LEADLESS II Study Investigators. Percutaneous implantation of an entirely intracardiac leadless pacemaker. *N Engl J Med*. 2015;373:1125–35.
- Reynolds D, Duray GZ, Omar R, Soejima K, Neuzil P, Zhang S, et al. A leadless intracardiac transcatheter pacing system. *N Engl J Med*. 2016.374:2604–5.

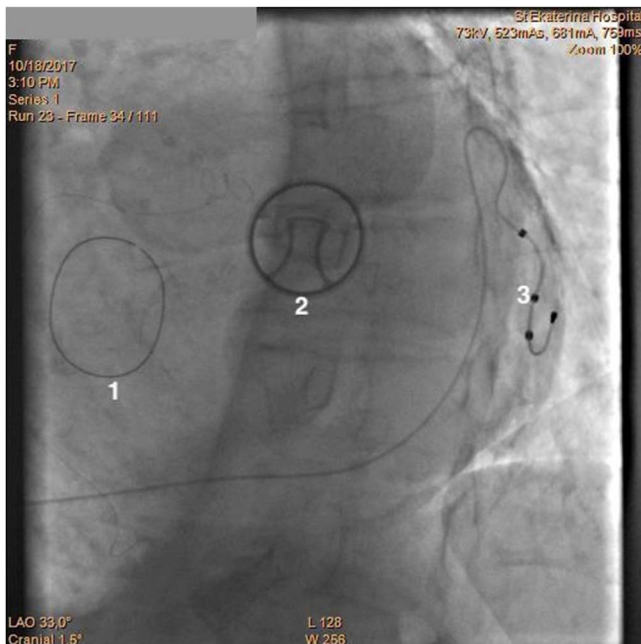


FIGURE 1 LV Lead implanted in postero-lateral CS branch

How to cite this article: Iovcev S, Chilingirova N. LV pacing as an alternative option to conventional RV pacing in patient with tricuspid valve replacement. *J Arrhythmia*. 2020;36:532–533. <https://doi.org/10.1002/joa3.12343>