



Since January 2020 Elsevier has created a COVID-19 resource centre with free information in English and Mandarin on the novel coronavirus COVID-19. The COVID-19 resource centre is hosted on Elsevier Connect, the company's public news and information website.

Elsevier hereby grants permission to make all its COVID-19-related research that is available on the COVID-19 resource centre - including this research content - immediately available in PubMed Central and other publicly funded repositories, such as the WHO COVID database with rights for unrestricted research re-use and analyses in any form or by any means with acknowledgement of the original source. These permissions are granted for free by Elsevier for as long as the COVID-19 resource centre remains active.

Acute Limb Ischemia in a Peruvian Cohort Infected by COVID-19

Juan Bautista Sánchez,¹ Juan Diego Cuipal Alcalde,¹ Rossi Ramos Isidro,¹ Carlos Zúñiga Luna,¹ W Samir Cubas,² André Coaguila Charres,³ José Egoávil Gutiérrez,⁴ Juan David Ochoa,⁵ and Patricia Fernández Arias,⁶ Lima, Peru

Background: Coronavirus disease 2019 (COVID-19) infection can cause alterations in the coagulation mechanism conditioning thrombotic phenomena such as acute limb ischemia (ALI) as the only manifestation of the infection. The aim of the study was to describe clinical and surgical characteristics of a group of patients infected with severe acute respiratory syndrome coronavirus 2 who presented ALI in the context of the COVID-19 pandemic at Lima, Peru.

Methods: A multicenter, observational, and retrospective study was performed in six general hospitals, from March to July 2020. The variables considered were the pathological history and associated habits, laboratory tests, the severity of COVID-19 infection and ALI, the anatomic location of the lesion, treatment, evolution, and discharge conditions.

Results: Thirty patients with ALI infected with COVID-19 were evaluated. Their mean age was 60 ± 15 years, the condition being more frequent in men (76.6%). The main comorbidities were arterial hypertension (33.3%), obesity (33.3%), and diabetes mellitus 2 (26.6%). There were 23.3% asymptomatic patients, and their only manifestation was ALI. Rutherford IIA and IIB stage included 93.2% of patients. The most frequent location of the thrombosis was the lower limbs (73.3% vs. 26.6%). Thrombectomy was performed in 76.6% of the patients, and amputation (primary and secondary) was performed in 30% of the patients. The mortality rate was 23.3%, all of it because of acute respiratory distress syndrome.

Conclusions: ALI is a vascular pathology associated with embolic and thrombotic processes. COVID-19 infection can cause severe alterations in coagulation mechanisms, leading some patients to present severe acute arterial complications such as thrombosis, as the only associated manifestation. We report a younger cohort than those described in other studies and with a high frequency of amputations despite adequate surgical treatment.

Authors' contributions: All authors contributed equally in the design, collection, analysis, writing, and final approval of the manuscript.

Conflicts of interest: None.

Funding: This research did not receive any specific grant from funding agencies in the public, commercial, or not-for-profit sectors.

¹Vascular and Endovascular Surgery Unit, Cardiac and Vascular Surgery Service, Guillermo Almenara Irigoyen National Hospital, Lima, Peru.

²Vascular and Endovascular Surgery Service, Thoracic and Cardiovascular Surgery Department, Edgardo Rebagliati Martins National Hospital, Lima, Peru.

³Thorax and Cardiovascular Surgery Service, Dos de Mayo National Hospital, Lima, Peru.

⁴Thorax and Cardiovascular Surgery Service, Cayetano Heredia National Hospital, Lima, Peru.

⁵Thoracic and Cardiovascular Surgery Department, Hipolito Unanue National Hospital, Lima, Peru.

⁶Thorax and Cardiovascular Surgery Department, Luis N. Saenz National Police Hospital, Lima, Peru.

Correspondence to: Juan Bautista Sánchez, MD, Vascular and Endovascular Surgery Unit, Cardiac and Vascular Surgery Service, Guillermo Almenara Irigoyen National Hospital, Grau Street 800, La Victoria 13, Lima, Peru; E-mail: juan.bautista.s@upch.pe

Ann Vasc Surg 2021; 72: 196–204

<https://doi.org/10.1016/j.avsg.2020.12.005>

© 2021 Elsevier Inc. All rights reserved.

Manuscript received: November 11, 2020; manuscript accepted: December 22, 2020; published online: 31 December 2020

INTRODUCTION

COVID-19 is a pathological condition caused by severe acute respiratory syndrome coronavirus 2 (SARS-CoV-2) infection.¹ Since the first cases reported in Wuhan (China), the symptoms of the infection have not been specific and are frequently associated with pulmonary complications.^{1,2}

Different extrapulmonary manifestations have been described related to acute thromboembolic phenomena in the context of a systemic inflammatory state, endothelial injury, and platelet dysfunction at cardiopulmonary, cerebrovascular, and peripheral venous and arterial level, affecting as high as 49% of patients and overshadowing the prognosis of the disease.^{3–5} Recent publications have described a sudden increase in cases of arterial thrombosis in patients with COVID-19, conditioning acute limb ischemia (ALI) and constituting a surgical emergency.^{6,7}

Peru is one of the most affected countries in the region by the pandemic, with a cumulative incidence of 23.57 per 1,000 habitants.⁸ These arterial complications, which have not been reported so far in Latin America, have been observed in our country, identifying an increase in cases of ALI in patients with COVID-19.

The objective of this study was to describe the clinical and surgical characteristics in a cohort of patients with ALI infected with COVID-19 in the main Centers of Vascular and Endovascular Surgery in Peru.

METHODS

Design, Population, and Sample Size

This was a multicentered, descriptive, observational, and retrospective study. We analyzed 30 patients infected with COVID-19, diagnosed by a molecular test of nasopharyngeal smear or qualitative serological test, associated with ALI. These patients were admitted and evaluated by the vascular and endovascular surgery areas in 6 general hospitals in Lima, Peru: Guillermo Almenara Irigoyen National Hospital, Edgardo Rebagliati Martins National Hospital, Cayetano Heredia National Hospital, Hipolito Unanue National Hospital, Dos de Mayo National Hospital, and Luis N. Saenz National Police Hospital, from March to July 2020. These hospitals had a Vascular Activity Condition (VASCCON) of 2, and the surgeries that treated life-threatening emergencies and limbs of patients were prioritized.

Data Collection and Study Variables

The primary source of information were medical records and operative reports of patients treated for

ALI and infected with COVID-19 during the period established by the study. The information collected was selected and arranged retrospectively according to the chronological order of their clinical and surgical care. The categorical variables considered were sex, age, body mass index (BMI), pathological history, risk factors, the severity of COVID-19 infection, anatomic location, stage of ischemia, surgery performed, and postoperative events, and the continuous variables considered were the laboratory tests obtained of the patients during hospital admission. The ALI assessment was based on the Rutherford classification system,⁹ and the severity of COVID-19 by the proposal of the World Health Organization.¹⁰ Primary amputation was defined as that performed without previous revascularization and secondary amputation as that performed after revascularization within the first 30 days after ALI diagnosis.

Surgical Technique

Surgeries were performed under general or regional anesthesia as required by the patient, using intravenous unfractionated heparin (UFH) before the arterial clamping. In patients with aortoiliac or femoropopliteal occlusion, an inguinal incision was used to expose the femoral bifurcation, and a brachial exposure was performed on the upper limb. When the tibial arteries were compromised, an infrageniculate approach was performed. Thromboembolectomy was executed using an embolectomy catheter, sized according to the site of occlusion. Patients were anticoagulated during hospitalization with low-molecular-weight heparin (LMWH) and UFH and at discharge with LMWH as bridging therapy to warfarin; the latter was left prescribed according to its clinical evolution and control by outpatient clinic. All embolectomy surgeries performed on our patients were technically successful, and their definition was based on the complete removal of the intraluminal clot from the affected vessel with the subsequent presence of adequate runoff and backflow.

Statistical Analysis

All statistical calculations were performed as descriptive analysis. Continuous variables were expressed as medians and interquartile ranges. The categorical variables were summarized as counts and percentages; likewise, the distribution of the frequencies in absolute values and relative values was made. In all cases, the data analysis was performed using the statistical programs Microsoft

Excel 2016 and STATA MP v16 for the Windows 10 version.

Ethical Aspects

The study protocol followed standard norms of the Declaration of Helsinki and was approved by the Guillermo Almenara Irigoyen National Hospital Specialized Surgery Department (NIT 1142-2020-0237). The names and addresses of the people included in the study were not used. Because of the retrospective nature of the work, informed consent was not required, and the authors signed a letter of commitment to the confidentiality of the data.

RESULTS

Data from 30 patients diagnosed with ALI and SARS-CoV-2 infection were evaluated. The mean age was 60 ± 15 years (32–99 years), being more frequent in males (76.6%). An average BMI of 28.6 ± 5.9 kg/m² was found. The main antecedents were arterial hypertension (33.3%), obesity (33.3%), and diabetes mellitus 2 (26.6%). No patients with myxoma, heart failure, a history of neoplasia, cerebrovascular disease, or vascular surgical history were found. The diagnosis of COVID-19 infection was made through molecular (26.6%) and serological (73.3%) tests. There were 7 patients (23.3%) who came to the hospital only because of ALI. Anticoagulation therapy (LMWH) previous to the ALI was received in 23.3% of the patients. The laboratory tests requested are shown in [Table I](#).

The mean ischemic time was 74.7 hr; the leading symptoms were absence of pulse (100%), pain (93.3%), and cyanosis (89.2%) ([Fig. 1](#)). The majority of patients (93.2%) were classified on Rutherford Stage IIA and IIB ([Table II](#)). The anatomic location of thrombosis was 73.3% on lower limbs and 26.6% on the upper ones, with popliteal (10.7%) and brachial (8.7%) arteries being the most affected ([Fig. 2](#)).

Thrombectomy and fasciotomy were performed in 23 (76.6%) and 6 (20%) patients, respectively, two of them required reoperation 120 hr average after the initial surgical treatment. Postoperative anticoagulation started at 5.7 ± 1.3 hr, and there were no postoperative complications such as bleeding, pseudoaneurysm, or infection of the operative site. Two patients (6.6%) were not operated on because of unfavorable evolution of COVID-19 ([Table II](#)). There were nine amputations (30%), five of them were primary and four were secondary. Rutherford classification patients presented mainly Stage IIA and IIB, 44.4% and 33.3%, respectively. On

primary amputations, the mean ischemia time was 206.4 hr, and the surgical indication was the prolonged ischemia time. On secondary amputations, the mean ischemia time was 23.5 hr, and the reason for the surgical indication was poor clinical evolution after initial thrombectomy ([Table III](#)).

The hospital stay was 16.6 ± 11.5 days, and 76.6% of the patients were discharged with ambulatory anticoagulant therapy. We reported a mortality of 23.3%, and the main cause was severe COVID-19 infection (85.7%), and a Rutherford IIB staging (71.4%) was associated ([Table IV](#)).

DISCUSSION

The relationship between COVID-19 and arterial thrombosis of limbs is widely described, and it has been frequently reported on male patients especially on older patients,¹⁰ although it has also been described on younger patients without comorbidities.¹¹

Several studies have sought the risk factors associated with the development of arterial thrombosis related to COVID-19, mainly hypertension, diabetes, dyslipidemia, heart failure, history of heart attack, and smoking,^{6,12,13} finding a significant association between older age and coronary disease with ALI ($p < 0.001$).¹⁴ In our findings, 18 patients (60%) presented only one or no risk factors, presuming that the mechanism of action of arterial thrombosis would not be directly associated with the aforementioned risk factors.¹⁵

Many of the seriously ill patients infected with COVID-19 and admitted to intensive care unit (ICU) have increased risk of presenting arterial and venous thromboembolic complications. Klok et al. described that in 184 patients with severe COVID-19, the prevalence of arterial thrombosis was 3.7%, and venous thrombosis was 28%¹⁶; however, Nicole et al. reported that the primary presentation was an acute thrombotic event, without respiratory symptoms, or mild respiratory discomfort.¹⁵ We have evidenced 14 cases between asymptomatic (23.3%), mild symptoms (10%), and moderate symptoms (13.3%), reinforcing the possibility that other pathophysiological mechanisms explain the prothrombotic state associated with COVID-19, excluding the severe condition of patients on ICU.

There is increasing evidence that associates the relationship between a prothrombotic state and COVID-19, as described in different studies that report an increase in D-dimer and fibrinogen values. Likewise, a series of 1,099 patients in China showed that 46% of the patients presented an elevated D-

Table I. Presurgical characteristics of patients infected by COVID-19 and ALI

Variables	Value (<i>n</i> = 30)	Percentage (%)
Sex		
Female	7	23.3
Male	23	76.6
Age (years)		
31–45	5	16.6
46–60	7	23.3
61–75	23	76.6
76–90	4	13.3
91–105	1	3.3
BMI (kg/m ²)		
Normal	8	26.6
Overweight	12	40
Obesity I	4	13.3
Obesity II	4	13.3
Obesity III	2	6.6
Background		
Arterial hypertension	10	33.3
Obesity	10	33.3
Diabetes mellitus 2	8	26.6
Peripheral arterial disease	4	13.3
Chronic coronary disease	4	13.3
Sedentary lifestyle	4	13.3
Atrial fibrillation	3	10
Smoking	3	10
Dyslipidemia	1	3.3
Chronic kidney disease	1	3.3
COVID-19 diagnosis		
Molecular test	8	26.6
Serological test	22	73.3
IgM	8	26.6
IgG	1	3.3
IgM + IgG	13	43.3
Severity of COVID-19		
Asymptomatic	7	23.3
Mild	3	10
Moderate	4	13.3
Severe	16	53.3
Anticoagulation before to ALI	7	23.3
ICU stay before to ALI (days)	5	16.6
Laboratory exams		
Hemoglobin (12–14 g/dL)	12.9 (11.6–14.5)	
Leukocytes (×1,000 cells/mm ³)	11.6 (9.7–16.1)	
Lymphocytes (×1,000 cells/mm ³)	1.76 (1.1–3.4)	
Platelets (×1,000 cells/mm ³)	284 (220–371)	
Glucose (mg/dL)	110 (82.5–124.5)	
Creatinine (mg/dL)	0.8 (0.6–1.2)	
C-reactive protein (mg/dL)	35.5 (24–61)	
INR (0.8–1.2)	1.06 (0.92–1.26)	
aPTT (27–41)	32.5 (28.3–37.8)	
Fibrinogen (2–4.2 mg/dL)	4.8 (4.7–6.3)	
AST (15–46 U/L)	56 (38–76)	
ALT (<50 U/L)	55 (40–81)	
Albumin (3.5–5 g/dL)	3.2 (2.9–3.8)	
D-dimer (up to 0.25 mg/L)	3.2 (1.6–4.3)	
Ferritin (5–148 ng/mL)	520.7 (396–862)	

ALI, acute limb ischemia; ALT, alanine transaminase; aPTT, activated partial thromboplastin time; AST, aspartate transaminase; ICU, intensive care unit; INR, international normalized ratio.

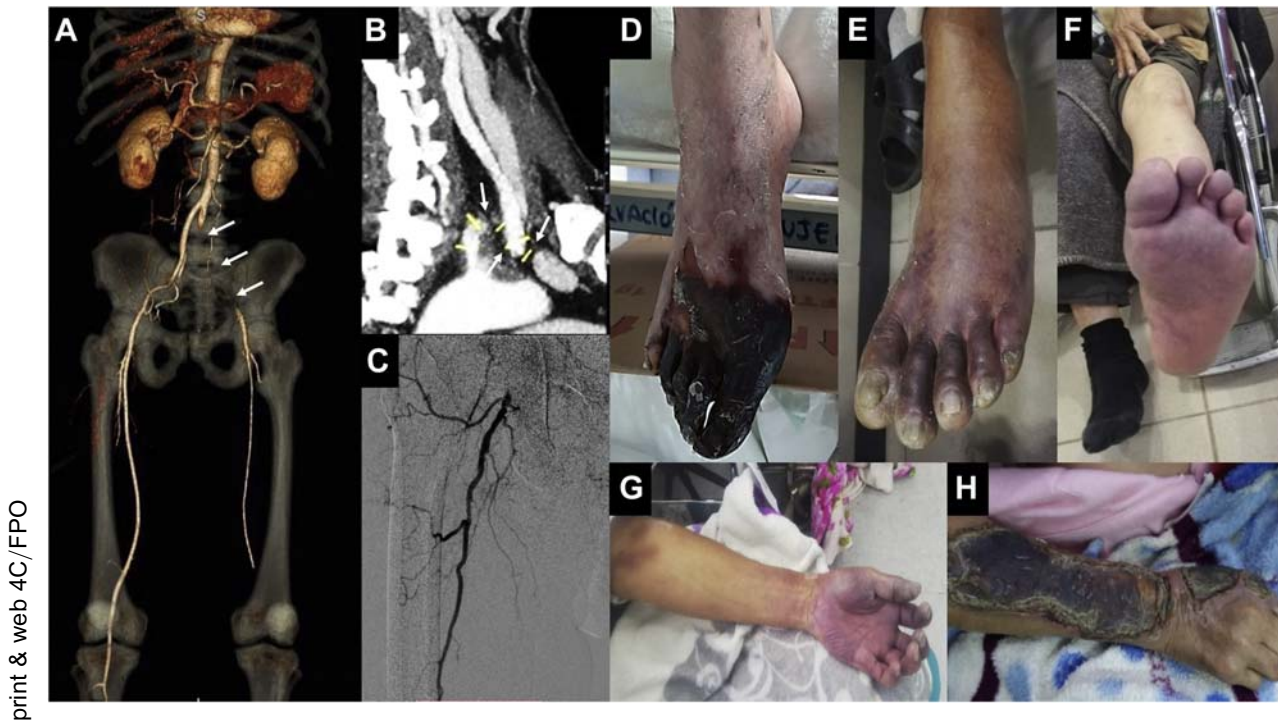

Fig. 1. (A) CT angiography with three-dimensional reconstruction showing an intraluminal thrombus affecting the common, external, and left internal iliac arteries with distal recanalization (Arrows). (B) CT angiography showing a thrombosis at the level of the origin of

the left subclavian artery (Arrow). (C) Arteriography with occlusion of the common and superficial right femoral artery. (D–H) Various clinical manifestations of ALI in patients infected by COVID-19.

dimer^{17,18} and were associated with poor prognosis and higher mortality.¹⁹ The mean fibrinogen concentrations in COVID-19 patients have been reported to be usually elevated and associated with an acute phase response,²⁰ as described in our work. The prolongation of the prothrombin time and the decrease in platelets in severe cases show that the coagulation mechanisms are significantly altered compared with uninfected people, allowing these laboratory evaluations to be classified as early predictors of severe forms of the disease.^{18,21,22}

ALI in COVID-19 can occur in two situations. During the in-hospital evolution of severe COVID-19 infection,^{6,23–26} Zhan et al. has reported a median of 19 (11–23 days) from the appearance of symptoms of the infection to the installation of ischemia²⁷ or they can be admitted to the emergency room for this vascular condition with mild or no respiratory symptoms.^{28–30}

We report an ischemic time of 39 hr, defined from the apparent onset of symptoms to surgical intervention. The factors that determined this time were related to the absence of an early and timely diagnosis, fear of patients going to the hospital, care focused on other more urgent symptoms of COVID-

19 infection, availability of beds for management in critical areas, emergency operating rooms, and transfer of the patient to hospital emergency rooms with adequate clinical suspicion. In contrast, Bellosta et al. reported a delay in the transfer of patients with suspected ischemic symptoms of 120 min.⁶

The Rutherford staging found in our series was predominantly IIA (75.9%) and IIB (17.2%), a result that differs from that reported by Bellosta et al. (IIB 75% and IIA 10%).⁶ This could be related to the magnitude of the inflammatory response and hypercoagulability that patients develop.³¹ Likewise, that most of the reported patients were hospitalized (76.6%), where they were clinically evaluated and detected as having ALI by the health team. It should be noted that the diagnosis of ALI in this type of patient was not based on any proposed protocol but mainly on the comprehensive clinical evaluation of the critical patient. Bellosta series found a mortality rate of 40% compared with 24% in our series.⁶

Conventional catheter embolectomy was the only revascularization treatment in our series (75.9%), as most reports in both upper and lower limbs.^{6,23,24,28} Pharmacological thrombolysis was

Table II. Clinical-surgical characteristics of patients infected by COVID-19 and ALI

Variables	Value (n = 30)	Percentage (%)
ALI time (hr)	39 (12–72)	
Clinical manifestations of the ALI		
No pulse	30	100
Pain	28	93.3
Cyanosis	25	89.2
Paresthesia	25	89.2
Pallor	23	76.6
Motor deficit	7	23.3
Rutherford staging		
I	0	0
IIA	23	76.6
IIB	5	16.6
III	2	6.6
Surgical treatment of the ALI		
Thrombectomy	23	76.6
Superior limb	6	20
Lower limb	17	46.6
Amputation	9	30
Primary	5	16.6
Superior limb	1	3.3
Lower limb	4	13.3
Secondary	4	13.3
Superior limb	1	3.3
Lower limb	3	10
No surgical treatment	2	6.6

ALI, acute limb ischemia.

applied occasionally in some reports, associated with thrombectomy^{6,17} or as the only procedure.²⁸ Other treatments described were angioplasties with or without a stent or bypass.^{6,26}

Recently published studies, mostly from Asia, Europe, and the United States, have usually described venous involvement above the arterial since the beginning of the pandemic.^{7,31} Between short and isolated reports, more frequent arterial involvement was shown in the lower limbs, predominantly the popliteal, anterior, and posterior tibial and superficial femoral, iliac, and distal aorta.^{7,12,23,24,26,28,32–34} This distribution coincides with our findings where these arteries were mainly counting about 50% of the total of vessels involved.

Concerning the upper limbs, frequent involvement of the subclavian, brachial, radial, and ulnar arteries and an isolated case of the brachiocephalic trunk have been reported.^{24,29,32,34,35} In our series, the subclavian artery and the brachial and ulnar arteries constituted more than 25% of the total of vessels affected. On the other hand, infrequent cases of

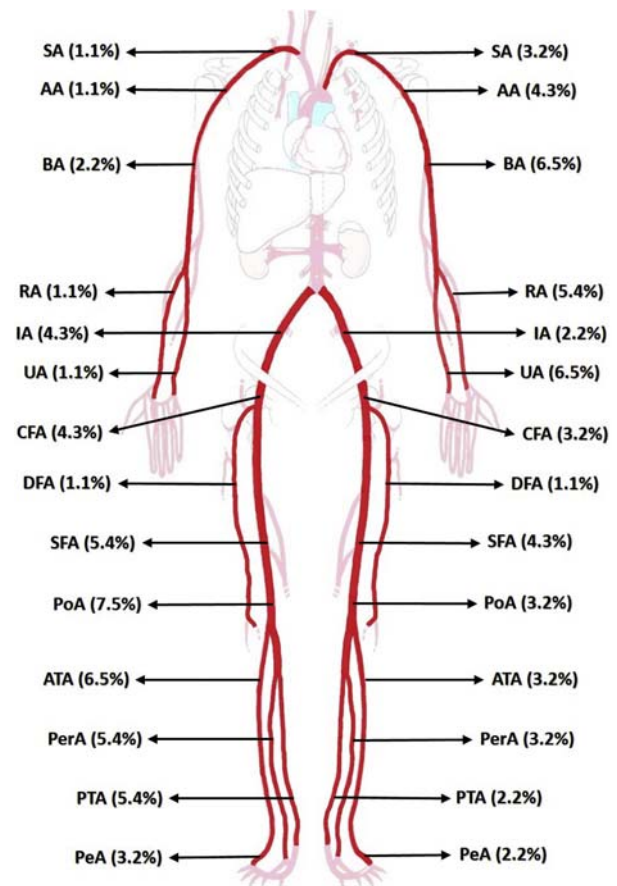


Fig. 2. Location of the affected arterial vessel in patients infected by COVID-19 and ALI. SA, subclavian artery; AA, axillary artery; BA, brachial artery; RA, radial artery; UA, ulnar artery; IA, iliac artery; CFA, common femoral artery; DFA, deep femoral artery; SFA, superficial femoral artery; PoA, popliteal artery; ATA, anterior tibial artery; PerA, peroneal artery; PTA, posterior popliteal artery; PeA, pedia artery.

thrombosis affecting aortic arch, descending thoracic aorta, aortobifemoral bypass, femoropopliteal bypass and stent, renal artery, mesenteric, and splenic arteries associated with a dark clinical course of the disease have been reported.^{6,7,12}

Our series reported a 30% amputation rate between primary and secondary. These results are higher than those described by Bellosta and Goldman, who reported rates of 6.3% and 25%, respectively.^{6,36} This amputation rate is higher than in patients with acute arterial thrombosis without COVID-19 infection reported in the United States and England.^{37,38} Our high amputation rate could be explained because of elevated number of patients with severe COVID-19 infection (53.3%) and a high number of moderate and severe infected patients among the amputated ones (77.7%).

Table III. Amputation in patients infected by COVID-19 and ALI

Variables	Amputation								
	Primary			Secondary					
	Patient 1	Patient 2	Patient 3	Patient 4	Patient 5	Patient 6	Patient 7	Patient 8	Patient 9
Sex	Female	Male	Male	Male	Female	Male	Female	Male	Male
Age (years)	99	51	69	62	65	61	32	68	81
Severity of COVID-19 infection	Asymptomatic	Moderate	Moderate	Severe	Moderate	Mild	Severe	Severe	Severe
ICU requirement	Not	Not	Not	Yes	Not	Not	Yes	Yes	Yes
Location of thrombosis	Infrainguinal	Iliac and infrainguinal	Infrainguinal	Infrainguinal	Upper limb	Infrainguinal	Upper limb	Infrainguinal	Infrainguinal
Rutherford staging	IIA	IIA	III	IIA	III	IIA	IIB	IIB	IIB
ALI time (hr)	144	288	312	48	240	72	6	8	6
Hospital stay (days)	32	35	32	46	10	32	28	11	23
Reason for amputation	Chronic prostration	Prolonged ALI	Prolonged ALI	ARDS	Infected limb	Unfavorable clinical course	Unfavorable clinical course	Unfavorable clinical course	Unfavorable clinical course

ALI, acute limb ischemia; ARDS, acute respiratory distress syndrome; COVID-19, coronavirus disease 2019; ICU, intensive care unit.

In our series, 60% of patients who developed acute arterial thrombosis during their stay in the ICU required amputation because of poor clinical evolution after thrombectomy; this fact was described by Klok et al., showing a high incidence of arterial thromboembolic complications and amputations in patients who required intensive medicine and mechanical ventilatory support.¹⁶

The decision of primary amputation in our series was based on different factors such as general condition, time of ischemia, or infection of the affected limb, and not on Rutherford's staging, contrary to what was proposed by Hardman et al.³⁹ Goldman et al. described that coagulation disorders observed in COVID-19 are usually more extensive and severe, finding worse evolution if they are associated with respiratory symptoms and leading to a high frequency of amputations.³⁶ These findings share a relationship with ours because we found that 78% of the amputations performed in our series were on patients with moderate to severe respiratory compromise. Secondary amputation was performed on 17.4% of patients who underwent thrombectomies, a finding much higher than reported (3–5%)³⁹ and one which could be related to the hypercoagulability state in patients infected with COVID-19,⁴⁰ thus conditioning adverse results after initial revascularization and higher amputation rates in young patients with acute arterial thrombosis.⁴¹

The mortality rate in our series was 23.3%, similar to other studies with mortality rates between 23 and 40%.^{6,14,36,42,43} The average age of the deceased was 59 years, corresponding to the age group most affected in our population.⁴⁴ It is expected that adults aged >80 years are the main affected group, with a higher rate in men in whom hypercoagulable states predominate.^{6,42,43,45} Thromboembolic phenomena and mortality correlate with the severity of the infection.^{6,14,35} In all the patients who died, they had greater clinical severity of COVID-19 infection, and mortality was attributed to acute respiratory distress syndrome. In deceased patients, the anatomic location of thrombosis was mainly infrainguinal (71.4%), similar to what was observed in several case reports.^{6,43}

The main limitations of the present work were related to the availability of auxiliary diagnostic studies in the context of the health emergency, such as transthoracic or transesophageal echocardiography, angiographic studies and among others, which could help us to identify the etiology of ALI (embolic vs. thrombotic primary) in the context of COVID-19 infection. On the other hand, we believe that the lack of a clear and standardized care

Table IV. Mortality in patients infected by COVID-19 and ALI

Variables	Mortality						
	Patient 1	Patient 2	Patient 3	Patient 4	Patient 5	Patient 6	Patient 7
Age (years)	65	63	32	68	81	58	52
Sex	Male	Male	Female	Male	Male	Male	Male
Severity of COVID-19 infection	Severe	Severe	Severe	Severe	Severe	Moderate	Severe
ICU requirement	Yes	Yes	Yes	Yes	Yes	Yes	Yes
Location of the ALI	Infrainguinal	Upper limb	Upper limb	Infrainguinal	Infrainguinal	Iliac and infrainguinal	Infrainguinal
Rutherford staging	IIA	IIA	IIB	IIB	IIB	IIB	IIB
Surgical treatment of ALI	Not	Not	Yes	Yes	Yes	Yes	Yes
Amputation	Not	Not	Yes	Yes	Yes	Yes	Not
Hospital stay (days)	7	8	28	11	23	10	8
Death cause	ARDS	ARDS	ARDS	ARDS	ARDS	ARDS	ARDS

ALI, acute limb ischemia; ARDS, acute respiratory distress syndrome; COVID-19, coronavirus disease 2019; ICU, intensive care unit.

protocol for the management of these cases was one of the main limitations that weighed on the prognosis and morbidity and mortality of the disease. Finally, the descriptive nature of our study has not allowed us to conclusively conclude or affirm statistically significant premises, which is why there is an urgent need for further analytical studies to help us understand the behavior of this pathology and its respective predictive factors of poor evolution.

CONCLUSIONS

ALI is a vascular pathology associated with embolic and thrombotic processes. COVID-19 infection can cause severe alterations in coagulation mechanisms, leading some patients to present severe arterial complications such as thrombosis, as the only associated manifestation. We report a cohort of 30 patients younger than those described in other studies and with a high frequency of amputations despite adequate surgical treatment. Our series is one of the first reported in Latin America, with a considerable number of patients that allowed us to describe relevant characteristics of arterial thrombosis in patients infected with COVID-19. At the close of this series, we are still admitting a significant number of patients with this condition, who could be added for future research.

REFERENCES

- Zhu N, Zhang D, Wang W, et al. A novel coronavirus from patients with pneumonia in China, 2019. *N Engl J Med* 2020;382:727–33.
- Lu R, Zhao X, Li J, et al. Genomic characterisation and epidemiology of 2019 novel coronavirus: implications for virus origins and receptor binding. *Lancet* 2020;395:565–74.
- Gupta A, Madhavan MV, Sehgal K, et al. Extrapulmonary manifestations of COVID-19. *Nat Med* 2020;26:1017–32.
- The Lancet H. COVID-19 coagulopathy: an evolving story. *Lancet Haematol* 2020;7:e425.
- Ackermann M, Verleden SE, Kuehnel M, et al. Pulmonary vascular endothelialitis, thrombosis, and angiogenesis in Covid-19. *N Engl J Med* 2020;383:120–8.
- Bellosta R, Luzzani L, Natalini G, et al. Acute limb ischemia in patients with COVID-19 pneumonia. *J Vasc Surg* 2020;6:1864–72.
- Etkin Y, Conway AM, Silpe J, et al. Acute arterial thromboembolism in patients with COVID-19 in the New York City area. *Ann Vasc Surg* 2020;70:290–4.
- National Center for Epidemiology, Prevention and Control of Diseases-Ministry of Health of Peru (MHP). Daily Report "COVID-19". Lima Peru., <https://www.dge.gob.pe/portalnuevo/categoria/covid-19/>; 2020 [cited September 27, 2020].
- Björck M, Earnshaw JJ, Acosta S, et al. Editor's choice - European Society for Vascular Surgery (ESVS) 2020 Clinical Practice Guidelines on the management of acute limb ischaemia. *Eur J Vasc Endovasc Surg* 2020;59:173–218.
- World Health Organization (WHO). Coronavirus disease 2019 (COVID-19): situation report, 82, <https://www.paho.org>.

- [org/es/tag/enfermedad-por-coronavirus-covid-19/](https://www.paho.org/es/tag/enfermedad-por-coronavirus-covid-19/); 2020 [cited September 15, 2020].
11. National Institute of Statistics and Informatics (NISI). XII National Census of Population and Housing 2017. Demographic Bulletin No.39, Lima, Peru, <https://www.paho.org/es/tag/enfe>; 2020 [cited September 20, 2020].
 12. Kashi M, Jacquín A, Dakhil B, et al. Severe arterial thrombosis associated with Covid-19 infection. *Thromb Res* 2020;192:75–7.
 13. Carranza M, Salazar D-E, Troya J, et al. Aortic thrombus in patients with severe COVID-19: review of three cases. *J Thromb Thrombolysis* 2020;9:1–6.
 14. Bilaloglu S, Aphinyanaphongs Y, Jones S, et al. Thrombosis in hospitalized patients with COVID-19 in a New York City health system. *JAMA* 2020;324:799–801.
 15. Ilonzo N, Rao A, Berger K, et al. Acute thrombotic events as initial presentation of patients with COVID-19 infection. *J Vasc Surg Cases Innov Tech* 2020;6:381–3.
 16. Klok FA, Kruip MJHA, van der Meer NJM, et al. Incidence of thrombotic complications in critically ill ICU patients with COVID-19. *Thromb Res* 2020;191:145–7.
 17. Guan W-j, Ni Z-y, Hu Y, et al. Clinical characteristics of coronavirus disease 2019 in China. *N Engl J Med* 2020;382:1708–20.
 18. Huang C, Wang Y, Li X, et al. Clinical features of patients infected with 2019 novel coronavirus in Wuhan, China. *Lancet* 2020;395:497–506.
 19. Lippi G, Favaloro E. D-dimer is Associated with Severity of Coronavirus Disease 2019: A Pooled Analysis. *Thromb Haemost* 2020;120:876–8.
 20. Levi M, Thachil J, Iba T, et al. Coagulation abnormalities and thrombosis in patients with COVID-19. *Lancet Haematol* 2020;7:e438–40.
 21. Wang D, Hu B, Hu C, et al. Clinical characteristics of 138 hospitalized patients with 2019 novel coronavirus-infected pneumonia in Wuhan, China. *JAMA* 2020;323:1061–9.
 22. Zhou F, Yu T, Du R, et al. Clinical course and risk factors for mortality of adult inpatients with COVID-19 in Wuhan, China: a retrospective cohort study. *Lancet* 2020;395:1054–62.
 23. Baccellieri D, Bilman V, Apruzzi L, et al. A case of Covid-19 patient with acute limb ischemia and heparin resistance. *Ann Vasc Surg* 2020;68:88–92.
 24. Perini P, Nabulsi B, Massoni CB, et al. Acute limb ischaemia in two young, non-atherosclerotic patients with COVID-19. *The Lancet* 2020;395:1546.
 25. Giacomelli E, Dorigo W, Fargion A, et al. Acute thrombosis of an aortic prosthetic graft in a patient with severe COVID-19-related pneumonia. *Ann Vasc Surg* 2020;66:8–10.
 26. Anwar S, Acharya S, Shabih S, et al. Acute limb ischemia in COVID-19 disease: a mysterious coagulopathy. *Cureus* 2020;12:e9167–.
 27. Schultz K, Wolf JM. Digital ischemia in COVID-19 patients: case report. *J Hand Surg Am* 2020;45:518–22.
 28. Mietto C, Salice V, Ferraris M, et al. Acute lower limb ischemia as clinical presentation of COVID-19 infection. *Ann Vasc Surg* 2020;69:80–4.
 29. Shao T, In-Bok Lee C, Jabori S, et al. Acute upper limb ischemia as the first manifestation in a patient with COVID-19. *J Vasc Surg Cases Innov Tech* 2020;6:674–7.
 30. Kaur P, Posimreddy S, Singh B, et al. COVID-19 presenting as acute limb ischaemia. *Eur J Case Rep Intern Med* 2020;7:001724.
 31. Connors JM, Levy JH. COVID-19 and its implications for thrombosis and anticoagulation. *Blood* 2020;135:2033–40.
 32. Mestres G, Puigmacià R, Blanco C, et al. Risk of peripheral arterial thrombosis in COVID-19. *J Vasc Surg* 2020;72:756–7.
 33. Vacirca A, Faggioli G, Pini R, et al. Unheralded lower limb threatening ischemia in a COVID-19 patient. *Int J Infect Dis* 2020;96:590–2.
 34. Kaur P, Qaqa F, Ramahi A, et al. Acute upper limb ischemia in a patient with COVID-19. *Hematol Oncol Stem Cell Ther* 2020.
 35. Galanis N, Stavrakia C, Agathangelidis F, et al. Coagulopathy in COVID-19 infection: a case of acute upper limb ischemia. *Int J Surg Case Rep* 2020;2020:204.
 36. Goldman I, Ye K, Scheinfeld M. Lower extremity arterial thrombosis associated with COVID-19 is characterized by greater thrombus burden and increased rate of amputation and death. *Radiology* 2020;297:E263–9.
 37. Genovese EA, Chaer RA, Taha AG, et al. Risk factors for long-term mortality and amputation after open and endovascular treatment of acute limb ischemia. *Ann Vasc Surg* 2016;30:82–92.
 38. Earnshaw JJ, Whitman B, Foy C. National audit of Thrombolysis for acute leg ischemia (NATALI): clinical factors associated with early outcome. *J Vasc Surg* 2004;39:1018–25.
 39. Hardman RL, Jazaeri O, Yi J, et al. Overview of classification systems in peripheral artery disease. *Semin Interv Radiol* 2014;31:378–88.
 40. Han H, Yang L, Liu R, et al. Prominent changes in blood coagulation of patients with SARS-CoV-2 infection. *Clin Chem Lab Med* 2020;58:1116–20.
 41. Torrealba JI, Osman M, Kelso R. Hypercoagulability predicts worse outcomes in young patients undergoing lower extremity revascularization. *J Vasc Surg* 2019;70:175–80.
 42. Cantador E, Núñez A, Sobrino P, et al. Incidence and consequences of systemic arterial thrombotic events in COVID-19 patients. *J Thromb Thrombolysis* 2020;50:543–7.
 43. Cheruiyot I, Kipkorir V, Kariuki B, et al. Arterial thrombosis in coronavirus disease 2019 (COVID-19) patients: a rapid systematic review. *Ann Vasc Surg* 2020;70:273–81.
 44. Mejía F, Medina C, Cornejo E, et al. Clinical features and prognostic factors related to mortality in hospitalized adult patients with COVID-19 in a public hospital in Lima, Peru 2020;. <https://doi.org/10.1371/journal.pone.00244171> [cited 27/09/2020].
 45. Capuano A, Rossi F, Paolisso G. Covid-19 kills more men than women: an overview of possible reasons. *Front Cardiovasc Med* 2020;7:131.