

Contents lists available at [ScienceDirect](#)

## International Journal of Surgery Case Reports

journal homepage: [www.casereports.com](http://www.casereports.com)

## Short- and long-term outcomes after pancreaticoduodenectomy following total gastrectomy: Report of case series and literature review



Satoshi Yokoyama<sup>a,\*</sup>, Kohei Ueno<sup>a</sup>, Yasuhiro Higashide<sup>a</sup>, Atsushi Noma<sup>a</sup>, Yuko Okishio<sup>a</sup>, Mitsuru Masuda<sup>a</sup>, Takumi Miyamoto<sup>a</sup>, Ryo Kamimura<sup>a</sup>, Shinichi Hosokawa<sup>a</sup>, Yoshikuni Yonenaga<sup>a</sup>, Daisuke Ito<sup>a</sup>, Masato Ichimiya<sup>a</sup>, Yoshito Yamashita<sup>a</sup>, Shiro Uyama<sup>a</sup>, Shady ElGhazly Harb<sup>b</sup>

<sup>a</sup> Department of Surgery, Japanese Red Cross Society, Wakayama Medical Center, 4-20 Komatsubara-dori, Wakayama, 640-8558, Japan

<sup>b</sup> Department of General Surgery, Faculty of Medicine, Cairo University, Al-Saray Street, El Manial, Cairo 11956, Egypt

## ARTICLE INFO

## Article history:

Received 15 September 2016

Received in revised form

13 November 2016

Accepted 13 November 2016

Available online 27 November 2016

## Keywords:

Pancreaticoduodenectomy

Total gastrectomy

Afferent loop syndrome

## ABSTRACT

**PURPOSE:** Pancreaticoduodenectomy (PD) following gastrectomy (TG) should be considered challenging even currently although its procedure and clinical value have been being standardized. Short- and long-term outcomes as well as standard reconstruction method following these procedures remain unclear. In order to clarify these issues, we reviewed worldwide English literature and 4 of our own cases of PD for patients with previous TG.

**METHODS:** Clinicopathological variables of 11 cases of PD for patients with previous TG were evaluated. Seven of these 11 were abstracted from a review of worldwide English literature and 4 of 11 were our own cases.

**RESULTS:** 3 cases was reconstructed using Y-limb made in previous TG and afferent loop syndrome (ALS) was observed in 2 of 3, in these cases whereas no cases of ALS were found in cases reconstructed using newly-made Y-limb. In cases where PD was indicated for cancer, early cancer death, defined as death related to cancer recurrence observed within 2 years after PD, was observed in 6 of 9 cases. Notably in cases of pancreatic cancer recurrent cancer was diagnosed within 1 year after PD in 5 of 7 cases and 4 of these patients died of pancreatic cancer soon after recurrence.

**CONCLUSION:** In cases of PD following TG, previously-made Y-limb should not be used for reconstruction following PD because of probable cause of previously-made Y-limb for ALS. Long-term outcomes of PD after TG seemed unsatisfactory notably in cases of pancreatic cancer and thus application of PD for patients with previous TG should be carefully decided until reasonable explanation for this dismal outcome is obtained.

© 2016 The Author(s). Published by Elsevier Ltd on behalf of IJS Publishing Group Ltd. This is an open access article under the CC BY-NC-ND license (<http://creativecommons.org/licenses/by-nc-nd/4.0/>).

### 1. Introduction

Recently, there has been increasing the number of pancreaticoduodenectomy (PD) procedures in patients with previous gastrectomy. This is owed to the improved survival of patients who underwent total gastrectomy for gastric cancer [1,2]. Although its procedure and clinical value have been being standardized, PD for patients who previously received total gastrectomy (TG) is considered challenging. Short- and long-term outcomes as well as standard reconstruction method following these procedures remain unclear.

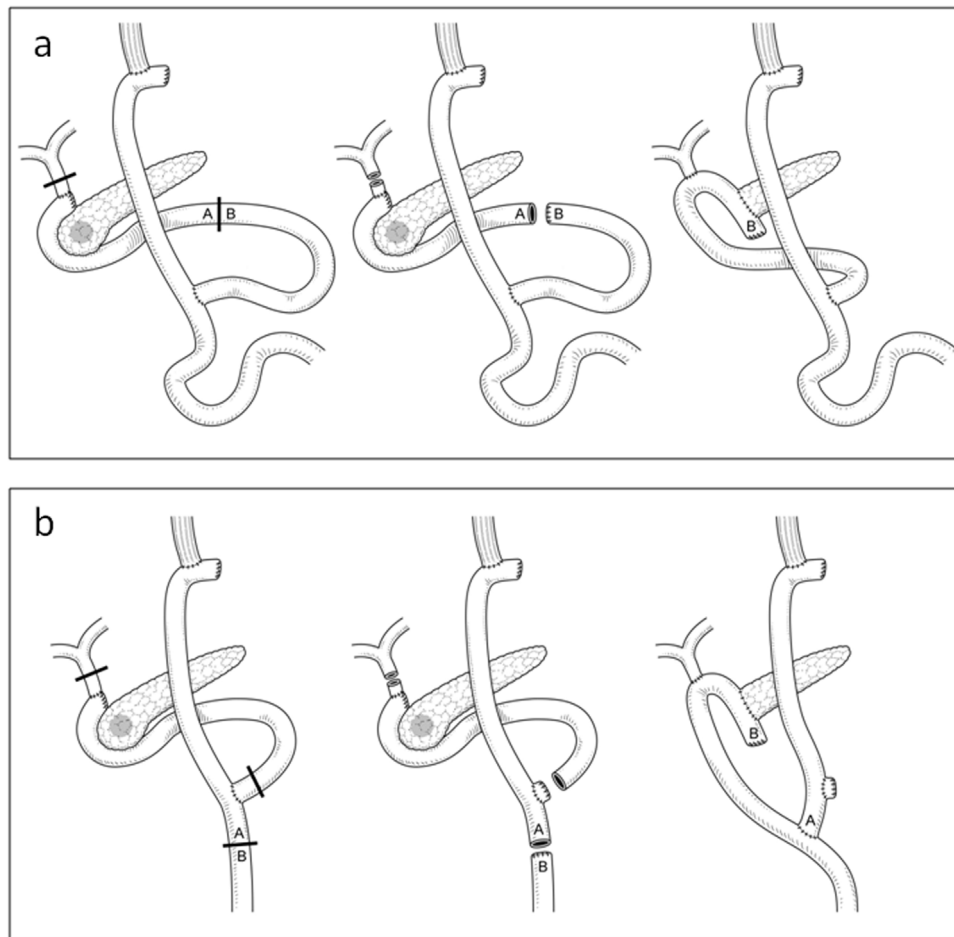
In this study, we examined the patient characteristics and short- and long-term outcomes of PD following TG by reviewing our own single-center experience of 4 cases as well as cases previously reported in worldwide English literature.

### 2. Methods

We conducted a retrospective, descriptive analysis of PD in patients who previously underwent PD for various indications. Among 172 patients who underwent PD at our institute from 2001 to 2015, 4 patients had undergone TG before PD. Literature search revealed only 5 papers describing 7 cases of PD following TG. We reviewed 11 cases to collect the following data: age, sex, indication of TG, reconstruction method following TG, interval between TG and PD, indication of PD, reconstruction type of PD, operative time,

\* Corresponding author.

E-mail address: [yokoyama.st@gmail.com](mailto:yokoyama.st@gmail.com) (S. Yokoyama).



**Fig. 1.** Reconstruction methods after PD following TG.

a: The previously fashioned Y-imb was utilised for pancreatic and biliary reconstruction during the PD.

b: The afferent loop is stapled and removed within the specimen, whereas a new Y-imb utilised for pancreatic and biliary reconstruction.

bleedings, hospital days, complication, and prognosis. The median follow-up period among all cases was 10.5 months (range, 6–60).

### 3. Results

#### 3.1. Characteristics of the patients undergoing TG

The demographics and operative findings of our 4 patients and additional 7 reviewed are summarized in Table 1. This summary includes 10 men and 1 woman with median age of 58 years (range, 45–68). Indication of TG was gastric cancer in 9 patients, gastric ulcer in 1 patient, and gastric malt lymphoma in 1 patient. Reconstruction method of TG was ‘Roux-en-Y’ in 9 patients, ‘esophagojejunostomy’ in 1 patient, and ‘jejunal interposition’ in 1 patient.

#### 3.2. Characteristics of the patients undergoing PD following TG

In the 11 patients, median age at PD was 69 years (range, 46–81), and median interval between TG and PD was 120 months (range, 15–360). Indication of PD was pancreatic ductal adenocarcinoma (PDAC) in 6 patients, lower bile duct cancer in 2, intraductal papillary mucinous carcinoma (IPMC) in 1, pancreatic gastorinoma in 1 and intraductal papillary mucinous neoplasm (IPMN) in 1.

Median operative time was 506 min (range, 412–672), with 509 min as median for those using same Y-imb made in previous

TG (range, 445–568), and a median of 471 min (range, 409–672) for those with a new reconstructed Y-imb. The overall mean blood loss was 840 ml (range, 303–1430), with mean of 1220 ml loss in the group using same Y-imb (range, 1009–1430), and a mean of 713 ml (range, 303–1300) blood loss in those with newly constructed Y-imb. Three patients (27.3%) required blood transfusions. The median hospital stay of the patients was 30 days (range, 19–71). Four patients (36.4%) had postoperative complications including afferent loop syndrome (ALS) (2, 18.2%), pancreatic fistula (POF) (1, 9.1%), and wound infection (1, 9.1%). POF was grade A and was treated conservatively. Of 2 ALS cases, 1 case was our first case of PD following TG, and was required for reoperation [3]. There was no operative mortality (Table 2). Three of 11 (27.3%) cases were reconstructed using Y-imb made in previous TG and ALS was observed in 2 of the 3 (66%) (Fig. 1a). The third patient in this group experienced SSI. Meanwhile, the group with a newly reconstructed Y-imb did not experience ALS (Fig. 1b) and only one patient suffered a postoperative complication in the form of pancreatic fistula.

In cases where PD was indicated for cancer, early cancer death, defined as death related to cancer recurrence observed within 2 years (range, 5.5–24 months) after PD, was observed in 6 of 9 cases. Notably in cases of pancreatic cancer (PDAC/IPMC), recurrent cancer was diagnosed within 1 year (range, 3–9 months) after PD in 4 of 7 cases and 4 of these patients died of pancreatic cancer soon after recurrence (within one year).

**Table 1**  
List of patients who underwent pancreaticoduodenectomy after total gastrectomy.

Case	Total gastrectomy										Pancreaticoduodenectomy									
	Age	Gender	Indication	Anastomosis	Age	Interval (months)	Indication	Reconstruction	Operative time (min)	Blood loss (ml)	Complication	Rec.Y/N	Disease free (months)	Survival (months)	A/D	Ref.				
1	58	M	gastric cancer	Roux-en-Y	69	132	pancreatic cancer	Roux-en-Y type	568	1009	afferent loop syndrome	Y	3	9	dead	†				
2	54	M	gastric cancer	Roux-en-Y	78	288	IPMC	New-Roux-en-Y type	412	725	none	Y	9	12	dead	†				
3	57	M	gastric cancer	Roux-en-Y	65	96	bile duct cancer	New-Roux-en-Y type	471	303	none	N	24	24	alive	†				
4	51	F	gastric cancer	Jejunum Interposition	81	360	pancreatic cancer	New-Roux-en-Y type	409	513	none	Y	3	5.5	dead	†				
5	65	M	gastric cancer	Roux-en-Y	69	43	pancreatic cancer	Roux-en-Y type	509	N/A	afferent loop syndrome	Y	N/A	N/A	dead	Ref. [4]				
6	45	M	gastric ulcer	Roux-en-Y	46	15	pancreatic gastrinoma	New-Roux-en-Y type	503	N/A	none	N	N/A	N/A	alive	Ref. [4]				
7	61	M	gastric cancer	Roux-en-Y <sup>a</sup>	71	120	pancreatic cancer	New-Roux-en-Y type	N/A	N/A	pancreatic fistula	Y	N/A	20	dead	Ref. [5]				
8	64	M	gastric cancer	Roux-en-Y	68	48	bile duct cancer	Roux-en-Y type	445	1430	none	Y	15	24	dead	Ref. [6]				
9	36	M	gastric cancer	esophagojejunostomy with Braun	56	56	pancreatic cancer	New-Roux-en-Y type	672	938	none	Y	6	9	dead	Ref. [7]				
10	62	M	recurrent gastric cancer	Roux-en-Y	72	120	pancreatic cancer	New-Roux-en-Y type	450	500	none	N	6	6	alive	Ref. [8]				
11	68	M	gastric cancer	Roux-en-Y	80	144	IPMN	New-Roux-en-Y type	540	1300	none	N	6	6	alive	Ref. [8]				

† our own case. N/A: Not available.  
<sup>a</sup> total gastrectomy, distal pancreatectomy, and splenectomy.

**Table 2**  
Operative findings and surgical complications.

Operative findings and surgical complications	
Operative findings	
Operation time (min)	506 (412–672)
Estimated blood loss (ml)	832 (303–1430)
Trasfusion (%)	3 (27.3%)
Length of hospital stay(day)	30 (19–71)
Surgical comlications	
Clavien-Dindo Grade I	SSI 1 (9.1%)
Clavien-Dindo Grade II	Pancreatic fistula (Grade A) 1 (9.1%) Afferent loop syndrome 1 (9.1%)
Clavien-Dindo Grade IIIb	Afferent loop syndrome 1 (9.1%)
Total	4 (36.4%)

**Discussion**

Pancreaticoduodenectomy is a technically demanding procedure, with a poor prognosis as well as poor survival benefit, ranging from 10 to 20% [9–14]. It becomes particularly challenging in patients with a history of major abdominal surgery such as total gastrectomy. This additional difficulty in such operations is caused by the adhesions and anatomical complexity around the pancreas subsequent to the previous TG procedure. Due to the small number of reported cases who have gone through both these complex procedures, no consensus has been reached regarding the standard procedure for reconstruction following PD for patients with previous TG.

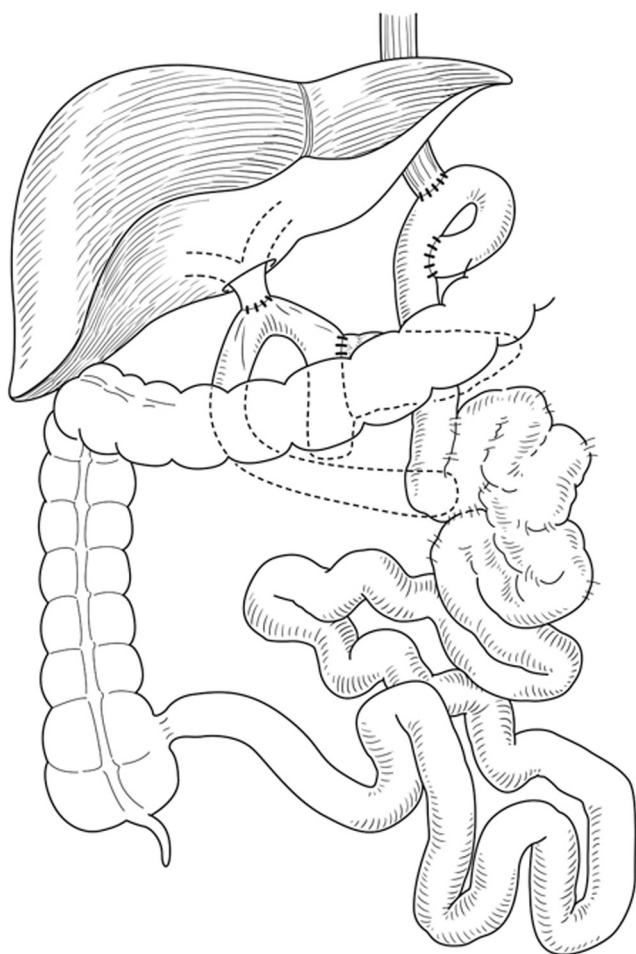
In our review of cases done in our centre and recorded in literature, the technique of Y-limb reconstruction during PD, was found to have an important impact on postoperative morbidity. ALS occurred in patients whose the previously fashioned Y-limb was utilised for pancreatic and biliary reconstruction during the PD. In our centre, one case was performed with this technique, where resection of the duodenal part of the afferent loop fashioned in the TG was done, and using the remaining part of this loop for pancreatico- and hepaticojejunostomy (Fig. 2). We applied this procedure to reduce the number of intestinal anastomoses. As a result, however, the jejunal limb used was markedly short, resulting in the development of refractory cholangitis due to ALS [3]. Besides avoiding ALS, the cases where we reconstructed a new Y-limb had less median operative time (471 min) and mean intraoperative blood loss (713 ml) as compared to cases where same Y-limb fashioned in TG was used.

Similarly, cases from other centres reported ALS occurring in one case out of two (50%) where the jejunal limb made in a previous TG was utilised in the PD. The rest of the cases in our centre and in other centres (n = 8), where a new Y-limb was refashioned during PD, no incidence of ALS was recorded.

Therefore, although number of cases is small, it may be safe to consider the reconstruction of a new jejunal Y-limb during PD in patients with previous TG. This is thought to avoid intestinal kinking and excess tension on the anastomosis, especially when the jejunal limb is short, and in turn avoid postoperative development of ALS.

The long term outcome, on the other hand, seems to be poor for patients who have pathologically proven pancreatic cancer (n = 7). Notably in cases of pancreatic cancer (PDCA/IPMC), recurrent cancer was diagnosed within 1 year after PD in 4 of 7 cases. Those 4 cases died of pancreatic cancer shortly after the diagnosis of recurrence. One out of the other 3 cases died within 2 years. A questionnaire was sent to the authors of the other reported cases to clarify the cause of death, but we did not get a clear answer.

Although this seems comparable to the long term survival of PD patients (10–20% 5 year survival), but it demands further evaluation of larger patients series who underwent similar procedures,



**Fig. 2.** Hepaticojejunostomy was performed using same previous afferent loop after total gastrectomy. The afferent loop was only 15–20 cm long.

in order to evaluate the feasibility of such complex procedure. Meanwhile, the possibility of having an immunological and/or oncological disadvantage by having a previous TG must be investigated.

In conclusion, PD should be attempted in TG patients, but with attention to the refashioning a new Y limb. However, because of the poor prognosis of PD following TG for pancreatic cancer, the indication for PD following TG should be carefully considered while taking the decision.

#### Authors' contributions

Satoshi Yokoyama made the conception and design of this case report. Authors other than SA contributed to the collection, analysis, and interpretation of the data. SA wrote the draft manuscript, and other authors performed the critical revision of the manuscript. All

authors gave final approval of the version to be published. SA has overall responsibility and guarantees the scientific integrity.

#### Competing interests

The authors declare that they have no competing interests.

#### Consent for publication

Written informed consent was obtained from the patient for the publication of this case report and any accompanying images. A copy of the written consent is available for review by the Editor-in-Chief of this journal.

#### Acknowledgement

We would like to thank Shady ElGhazly Harb, Lecturer of General Surgery, Faculty of Medicine, Cairo University, for reviewing the manuscript.

#### References

- [1] M. Sasako, Gastric cancer eastern experience, *Surg. Oncol. Clin. N. Am.* 21 (2012) 71–77.
- [2] S. Rausei, G. Dionigi, T. Sano, M. Sasako, A. Biondi, P. Morgagni, et al., Updates on surgical management of advanced gastric cancer: new evidence and trends. Insights from the first international course on upper gastrointestinal surgery–varese (Italy), december 2, 2011, *Ann. Surg. Oncol.* (July (10)) (2013).
- [3] S. Yokoyama, A. Sekioka, K. Ueno, Y. Higashide, Y. Okishio, N. Kawaguchi, et al., Pancreatoduodenectomy following total gastrectomy: a case report and literature review, *World J. Gastroenterol.* 20 (March (14)) (2014) 2721–2724.
- [4] R. Doi, K. Fujimoto, M. Imamura, Effects of preceding gastrectomy on the outcome of pancreatoduodenectomy, *J. Gastrointest. Surg.* 8 (2004) 575–579.
- [5] K. Noguchi, K. Okada, H. Kawamura, H. Ishizu, S. Homma, A. Kataoka, Operative procedure for pancreatoduodenectomy in a patient who had previously undergone total gastrectomy, distal pancreatectomy, and splenectomy, *Am. Surg.* 78 (2012) 103–105.
- [6] T. Oida, H. Kano, K. Mimatsu, A. Kawasaki, Y. Kuboi, N. Fukino, et al., Jejunal scarf-covering method in pancreatocoduodenectomy after total gastrectomy, *Case Rep. Gastroenterol.* 6 (2012) 472–477.
- [7] S. Mizuno, S. Isaji, I. Ohsawa, M. Kishiwada, T. Hamada, M. Usui, et al., Pancreatoduodenectomy with resection of the splenic artery and splenectomy for pancreatic double cancers after total gastrectomy: preservation of the pancreatic function via the blood supply from the posterior epiploic artery: report of a case, *Surg. Today* 42 (2012) 482–488.
- [8] S. Yun, D. Choi, Pancreatoduodenectomy in patients with a history of total gastrectomy for stomach cancers, *Int. Surg.* 99 (2014) 71–76.
- [9] R.J. Geer, M.F. Brennan, Prognostic indicators for survival after resection of pancreatic adenocarcinoma, *Am. J. Surg.* 165 (1993) 68.
- [10] K.E. Bakkevold, B. Arnesjø, O. Dahl, B. Kambestad, Adjuvant combination chemotherapy (AMF) following radical resection of carcinoma of the pancreas and papilla of Vater—results of a controlled, prospective, randomised multicentre study, *Eur. J. Cancer* 29A (1993) 698.
- [11] J.I. Tsao, R.L. Rossi, J.A. Lowell, Pylorus-preserving pancreatoduodenectomy. Is it an adequate cancer operation? *Arch. Surg.* 129 (1994) 405.
- [12] C.J. Yeo, J.L. Cameron, K.D. Lillemo, J.V. Sitzmann, R.H. Hruban, S.N. Goodman, et al., Pancreatoduodenectomy for cancer of the head of the pancreas. 201 patients, *Ann. Surg.* 221 (1995) 721.
- [13] K.W. Millikan, D.J. Deziel, J.C. Silverstein, T.M. Kanjo, J.D. Christein, A. Doolas, et al., Prognostic factors associated with resectable adenocarcinoma of the head of the pancreas, *Am. Surg.* 65 (1999) 618 (?).
- [14] G. Benassai, M. Mastroianni, G. Quarto, A. Cappiello, U. Giani, G. Mosella, Survival after pancreatoduodenectomy for ductal adenocarcinoma of the head of the pancreas, *Chir. Ital.* 52 (2000) 263–270.

#### Open Access

This article is published Open Access at [sciencedirect.com](https://www.sciencedirect.com). It is distributed under the [IJSCR Supplemental terms and conditions](#), which permits unrestricted non commercial use, distribution, and reproduction in any medium, provided the original authors and source are credited.