

Received: 2018.04.16
Accepted: 2018.08.08
Published: 2018.10.29

e-ISSN 1941-5923
© Am J Case Rep, 2018; 19: 1283-1287
DOI: 10.12659/AJCR.910642

Intraoperative Diagnosis and Management of Acute Hypotensive Blood Transfusion Reaction (AHTR): A Report of Two Cases

Authors' Contribution:
Study Design A
Data Collection B
Statistical Analysis C
Data Interpretation D
Manuscript Preparation E
Literature Search F
Funds Collection G

E 1 **Uzung Yoon**
ABE 1 **Madeel Abdullah**
DE 1 **Elia Elia**
ACDEF 2 **Jay Herman**

1 Department of Anesthesiology, Thomas Jefferson University Hospital, Philadelphia, PA, U.S.A.
2 Department of Transfusion Medicine, Thomas Jefferson University Hospital, Philadelphia, PA, U.S.A.

Corresponding Author: Uzung Yoon, e-mail: uzyoon@gmail.com
Conflict of interest: None declared

Case series

Patients: Female, 68 • Male, 86
Final Diagnosis: Acute hypotensive transfusion reaction
Symptoms: Hypotension
Medication: —
Clinical Procedure: —
Specialty: Anesthesiology

Objective: Challenging differential diagnosis

Background: Acute hypotensive transfusion reaction (AHTR) is characterized by the abrupt onset of hypotension immediately after the start of transfusion and usually resolves when transfusion ceases. Recent studies have shown an association with pre-operative treatment with an angiotensin-converting enzyme (ACE) inhibitor. This report presents two cases of AHTR in non-related patients and describes the diagnosis and management.

Case Report: A 68-year-old woman underwent lumbar fusion surgery due to spinal stenosis and an 86-year-old man underwent a pancreaticoduodenectomy (Whipple's procedure). Both patients had been treated pre-operatively with ACE inhibitors for hypertension. During surgery, both patients experienced acute profound intraoperative hypotension immediately after transfusion of packed red blood cells (RBCs). The blood transfusion was stopped immediately, and hemodynamic support was given with epinephrine, ephedrine, and phenylephrine. A diagnosis of acute hemolytic transfusion reaction was excluded by the direct antiglobulin test, serum hemolysis testing, exclusion of blood group mismatching, and a post-transfusion antibody screen. Other causes of hypotension were excluded. The two patients were confirmed to have had an AHTR, based on the current Centers for Disease Control and Prevention (CDC) criteria. In both cases, discontinuation of surgery was not possible, and surgery continued with intermittent hemodynamic support provided with catecholamines and vasopressin.

Conclusions: AHTR is a diagnosis of exclusion, based on laboratory and clinical findings. Antibody-mediated acute hemolytic transfusion reaction and any other causes of hypotension should be excluded as rapidly as possible. Patients who are at high risk of intraoperative bleeding might benefit from cessation of ACE inhibitors pre-operatively.

MeSH Keywords: Blood Group Incompatibility • Bradykinin • Hemolysis • Hypotension

Full-text PDF: <https://www.amjcaserep.com/abstract/index/idArt/910642>




2427



—



2



14



Background

Hypotension that occurs following transfusion can be caused by acute hemolysis, contamination of blood products, an anaphylactoid reaction, or anaphylaxis. In these cases, hypotension usually responds well with supportive management. Recently, a new type of post-transfusion reaction, known as acute hypotensive transfusion reaction (AHTR) has been described [1,2]. The incidence of AHTR has been reported to occur in between 0.05–2.6% of all transfusion reactions voluntarily reported to the U.S. Centers for Disease Control and Prevention (CDC) between 2010 and 2012 [1,2]. Because of the possible under-recognition and lack of voluntary reporting of adverse operative events, it is likely that the incidence of AHTR is much higher.

AHTR has been reported in patients undergoing apheresis and dialysis and in those taking angiotensin-converting enzyme (ACE) inhibitors [3,4]. The first intraoperative case of AHTR was described by Doria et al. in 2008 [5], with recent reports by Dalia et al. in 2016 [6] and Pollard et al. in 2017 [7]. AHTR is characterized by the abrupt onset of hypotension immediately after the initiation of transfusion and resolves rapidly after cessation of transfusion, with hypotension usually being the only symptom.

The National Healthcare Safety Network (NHSN) Hemovigilance (HV) Module from the CDC defines AHTR as an adverse reaction presenting with hypotension, when other causes of hypotension have been excluded, which resolves within one hour after cessation of transfusion [8]. AHTR is characterized as occurring within less than 15 minutes after the start of the transfusion and responds rapidly to the cessation of transfusion when the patient has no other conditions that could explain hypotension. AHTR may cause a drop in systolic blood pressure of greater than or equal to 30 mmHg and a drop in systolic blood pressure of less than or equal to 80 mmHg. This report presents two cases of AHTR in non-related patients, both of whom received pre-operative treatment with an ACE inhibitor and describes the diagnosis and management.

Case Report

Case 1

A 68-year-old woman underwent lumbar fusion surgery due to spinal stenosis. Her past medical history included hypothyroidism, hypercholesterolemia, and hypertension treated with lisinopril 20 mg daily. The patient continued her home medication, including lisinopril, until the morning of surgery. During surgery, blood loss was 1000 ml, and a packed red blood cell (RBC) transfusion was initiated. Prior to transfusion, her blood pressure was 130/75 mmHg. Within six minutes

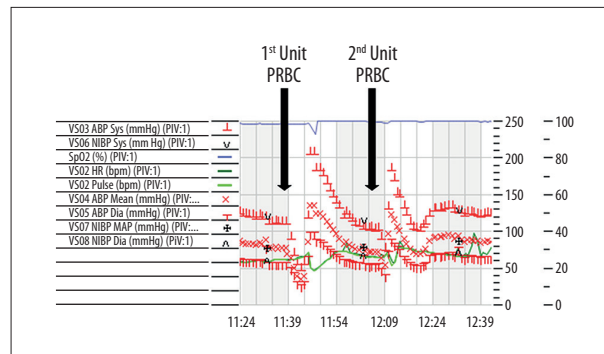


Figure 1. Case 1: Intraoperative vital signs during anesthesia.

of initiating the transfusion, the patient became acutely hypotensive, her blood pressure was 58/32 mmHg, which was refractory to intravenous fluids and required bolus doses phenylephrine, of 500 mgm in total over two minutes.

The blood transfusion was stopped immediately, and 100 mgm of epinephrine was administered (Figure 1). The surgical team was asked to look for sources of blood loss. Firstly, ongoing surgical bleeding and impaired fluid balance were excluded. Second, antibody-mediated acute hemolytic transfusion reaction was ruled out immediately by sending the remaining blood back to the blood bank. A diagnosis of acute hemolytic transfusion reaction was excluded by the direct antiglobulin test, serum hemolysis testing, exclusion of blood group mismatching, and a post-transfusion antibody screen. Medication and equipment errors were excluded. Next, anaphylaxis was excluded by physical examination, including the absence of a rash, urticaria, respiratory compromise, bronchospasm or laryngospasm. Her heart rate, pulse oximetry, temperature, and peak inspiratory pressures were unchanged from baseline. The end-tidal carbon dioxide (ETCO₂), or maximal concentration of CO₂ at the end of exhalation (expressed as% or mmHg) were unchanged (normal values of 5–6% CO₂, or 35–45 mmHg). Bacterial blood contamination was ruled out by normothermia and blood cultures. Laboratory testing of the urine was performed.

The patient became hemodynamically stable over the next 20 minutes and there was no continued need for continued vasopressor support. At this point, the working diagnosis was bradykinin-mediated acute hypotensive transfusion reaction (AHTR). After communicating with the surgical team, a decision was made to continue the surgery. Surgery continued but with the need for another transfusion. A new unit of packed RBCs was transfused. Within minutes of transfusion, the patient again had an acute episode of hypotension, which was successfully treated with 20 mgm of epinephrine. The surgery was completed, and the patient was transferred to the intensive care unit (ICU). Postoperative cardiac workup showed no evidence of ischemia or infarction and blood culture results were negative for bacterial growth, which also supported the diagnosis of AHTR.

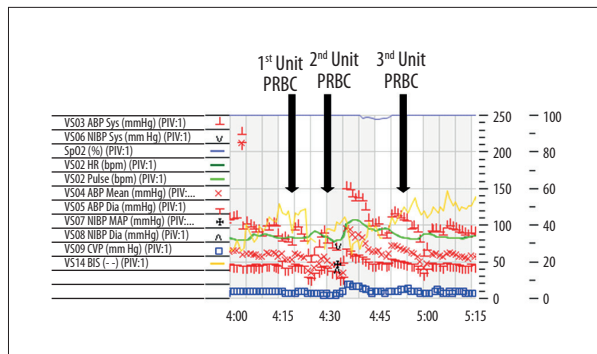


Figure 2. Case 2: Intraoperative vital signs during anesthesia.

Case 2

An 86-year-old man underwent a pancreaticoduodenectomy (Whipple's procedure) to remove a pancreatic mass. His past medical history included diabetes, hypertension, and hypercholesterolemia. His hypertension medication was lisinopril 40 mg, which he took on the morning of surgery. During surgery, there was a rapid loss of blood of approximately 700 ml within several minutes, requiring transfusion with packed RBCs.

Within five minutes of initiating the RBC transfusion, the patient's blood pressure decreased from 110/60 mmHg to 60/40 mmHg with its lowest level being 50/30 mmHg (Figure 2). The patient did not respond to phenylephrine bolus treatment (500 mg) or norepinephrine (40 mg), and so epinephrine (200 mg) was administered. The transfusion was stopped, surgical bleeding and impaired fluid balance were excluded. The remaining packed RBCs were returned to the blood bank immediately. An antibody-mediated acute hemolytic transfusion workup was negative. His heart rate, pulse oximetry, temperature, ETCO_2 , and peak inspiratory pressures were unchanged from baseline. There were no rashes or urticaria on physical examination. These findings resulted in a provisional diagnosis of bradykinin-mediated AHTR. Due to the patient's extensive blood loss of 700 ml and hemoglobin of 6.8 g/dL, a decision was made to attempt a further transfusion. Prior to and during the transfusion, the patient was treated with bolus doses of vasopressors. However, he still required epinephrine bolus treatment for hemodynamic support. Once the transfusion was completed, the patient's blood pressure returned to normal. He had no postoperative complications and was discharged from hospital four days following surgery. Postoperative cardiac workup, blood cultures, and urinalysis were all negative. In this case, the clinical presentation, combined with the transient episode of hypotension following transfusion strongly supported the diagnosis of bradykinin-mediated AHTR.

Discussion

These two case reports from our center demonstrate that our institution recognizes the diagnosis of acute hypotensive transfusion reaction (AHTR), as described by the National Healthcare Safety Network (NHSN) Hemovigilance (HV) Module from the Centers for Disease Control and Prevention (CDC) [8]. Currently, it is likely that the diagnosis of AHTR is under-recognized or unknown by many physicians. In 2008, our institution described the first case of intraoperative AHTR to have occurred during liver transplantation [5]. At that time, the diagnosis was challenging because intraoperative AHTR was poorly recognized, and the symptoms resulted in the cancellation of surgery [5]. The final diagnosis of AHTR was made postoperatively after bradykinin and aminopeptidase P (APP) titer analysis [5]. Since then, most anesthesiologists, surgeons, and blood bank physicians at our institution have become aware of intraoperative AHTR as a possible cause of hypotension after transfusion. This previous experience with intraoperative AHTR made it possible for the early recognition, timely diagnosis, and multidisciplinary clinical decision making regarding the management for both cases described in this case report. Dalia et al. reported difficulty in diagnosing intraoperative AHTR in a case of surgery for lumbar laminectomy, and that accurate diagnosis could not be established at the time of severe hypotension [6]. Pollard et al. also reported delayed recognition of AHTR in a case of surgical thoracic laminectomy where the initial working diagnosis was allergic transfusion reaction, which resulted in inappropriate patient management [7].

In both of the cases presented in this report, the diagnosis of AHTR was made following an institutional multidisciplinary flowchart, or clinical algorithm, that incorporated the CDC protocol for the diagnosis of AHTR [8]. A multidisciplinary approach was taken for the diagnosis and management of AHTR that included interdepartmental expert opinions from the departments of anesthesia, surgery, hematology, and the blood bank. Also, since consultation and collaborative work with the blood bank is crucial in this situation, our institution has established a blood bank policy that ensures that a transfusion-related hypotension workup takes priority over anything else. The clinical management process undergoes escalation from a transfusion physician to an anesthesiologist to establish the diagnosis and treatment plan. Following the flowchart and close communication with the surgeon and blood bank, all causes of hypotension can be excluded in a timely manner.

In the two cases of AHTR described in this report, no other signs or symptoms for the operative hypotension were found. Based on the CDC criteria and the known previous use by both patients of an angiotensin-converting enzyme (ACE) inhibitor (lisinopril), we concluded that our patients were experiencing a bradykinin-mediated AHTR reaction. As these cases have

demonstrated, it is important to recognize the diagnostic criteria and to rapidly be able to manage AHTR, especially in the intraoperative setting. Transfusion-related intraoperative hypotension is often a critical event, and patients who are hemodynamically unstable will be at high risk of further complications associated with hypotension. Also, as an intraoperative transfusion is required for acute or massive hemorrhage, withholding transfusion is not an option. A clear diagnosis needs to be made quickly to guide further management and to decide whether surgery needs to be terminated immediately or if it is safe to continue with surgery.

The intraoperative diagnosis of AHTR can be challenging. There is limited time for diagnosis as the patient might be actively bleeding or hemodynamically unstable. Also, it may be difficult to evaluate the patient for symptoms when under anesthesia. However, AHTR is a diagnosis of exclusion and is based on laboratory and clinical findings. Following our institutional multidisciplinary flowchart, ongoing surgical bleeding and under-resuscitation (abnormal fluid and electrolyte balance) were initially excluded. A diagnosis of acute hemolytic transfusion reaction was excluded by the direct antiglobulin test, serum hemolysis testing, exclusion of blood group mismatching, and a post-transfusion antibody screen, and medication and equipment errors were excluded. An anaphylactic reaction was excluded by physical examination, including the absence of a rash, urticaria, respiratory compromise, bronchospasm, or laryngospasm. Heart rate, pulse oximetry, temperature, end-tidal carbon dioxide (ETCO₂), and peak inspiratory pressures were unchanged. Bacterial contamination of the blood was considered and excluded, but the incidence of contamination with packed RBC transfusion is rare and usually manifests clinically with hyperthermia. Urinalysis and blood cultures were performed in both cases, but may not be very useful in the operating room setting due to the delay in these diagnostic procedures. Hypotension due to a cardiac origin was also excluded as this is usually associated with tachycardia or electrocardiography (ECG) changes. Also, postoperative cardiac workup was performed to rule out ischemia or infarction.

Currently, only the National Healthcare Safety Network (NHSN) Hemovigilance (HV) Module Protocol from the CDC has published criteria for the diagnosis of AHTR [8]. There are no guidelines or published literature describing the clinical diagnostic and management approach for patients if intraoperative AHTR is suspected. Three previously published case reports on intraoperative AHTR did not clearly describe the diagnostic approach [5–7].

Acute life-threatening transfusion reactions can result from several pathophysiologic causes, including bacterial contamination of blood products, acute hemolysis, anaphylaxis, transfusion-associated lung injury, and severe febrile reactions [9].

The diagnosis of AHTR is made by the predominant and often only sign of acute hypotension [10]. Increased levels of bradykinin in association with the use of an ACE inhibitor in patients with impaired bradykinin metabolism leads to AHTR [11]. Bradykinin is a powerful vasodilator with a half-life of 30 seconds that activates the vascular B₂-kinin B₂ receptors on endothelial cells that affect endothelial function, leading to the release of nitric oxide (NO), which is formed in a cascade reaction with activated factor XII, prekallikrein, and high molecular weight kininogen [11]. In normal individuals, the activity of bradykinin is limited due to its rapid degradation (in seconds) by three enzymes, kininase II or angiotensin-converting enzyme (ACE), aminopeptidase P (APP), and kininase-I. Bradykinin inactivation is degraded by the ACE inhibitor (75%), APP (20%), and kininase-I (5%), respectively. ACE inhibitor intake leads to inadequate bradykinin degradation and can result in profound hypotension [12]. Only a few laboratories are capable of measuring ACE and APP enzyme activity, and therefore it is impractical to recommend routine measurements of these enzymes. Doria et al. reported a low level of APP and ACE activity in a patient with intraoperative AHTR, and further transfusions were uneventful after the ACE-inhibitor was stopped, indicating the correlation with ACE-inhibitor use and AHTR [5].

Cessation of transfusion and supportive care is the primary management approach for patients with AHTR. Hypotension usually resolves once the transfusion is stopped [13]. According to Crews et al. [14] washing the red cells may prevent recurrent reactions, presumably by removing the activated Factor XII and other AHTR-initiating substances. However, washed packed RBCs take several hours to prepare and have a short shelf life.

Whether to cancel or proceed with surgery is a challenging decision. In both cases presented in this report, we decided to continue with surgery after a multidisciplinary discussion with the anesthesiologist, surgeon, and blood bank. In both cases, the priority was to rule out an antibody-mediated hemolytic transfusion reaction, which can be life-threatening and to decide whether or not to cancel surgery. After ruling out all other causes of hypotension, and having made the diagnosis of AHTR, a decision was made to continue surgery with hemodynamic support.

Previously, successful continuation of surgery with supportive therapy, including catecholamines or vasopressin, has been reported in AHTR [7]. However, the risk of continuing with surgery might include ongoing hemodynamic instability and the continuous need for aggressive vasopressor support. However, discontinuing surgery, once intraoperative AHTR is diagnosed, needs to be made carefully and on an individual base. Doria et al. reported a case of intraoperative AHTR during liver transplantation leading to the intraoperative cancellation of surgery and subsequent death of the patient due to progressive liver

failure [5]. Similarly, Dalia et al. reported early termination of surgery in a case of AHTR [6]. Therefore, communication and multidisciplinary decision making between the blood bank, the surgeon, and the anesthesiologist is key to the diagnosis and management of AHTR and to determine whether or not to continue with transfusion and/or surgery.

References:

1. Metcalf RA, Bakhtary S, Goodnough LT et al: Clinical pattern in hypotensive transfusion reactions. *Anesth Analg*, 2016; 123: 268–73
2. Harvey AR, Basavaraju SV, Chung KW, Kuehnert MJ: Transfusion-related adverse reactions reported to the National Healthcare Safety Network Hemovigilance Module, United States, 2010 to 2012. *Transfusion*, 2014; 55: 709–18
3. Owen HG, Brecher ME: Atypical reactions associated with use of angiotensin-converting enzyme inhibitors and apheresis. *Transfusion*, 1994; 34: 891–94
4. Abe H, Ikebuchi K, Shimbo M et al: Hypotensive reactions with a white cell-reduction filter: activation of kallikrein-kinin cascade in a patient. *Transfusion*, 1998; 38: 411–12
5. Doria C, Elia ES, Kang Y et al: Acute hypotensive transfusion reaction during liver transplantation in a patient on angiotensin-converting enzyme inhibitors from low aminopeptidase P activity. *Liver Transpl*, 2008; 14: 684–87
6. Dalia A, Gonzalez AA, Ostrum SG et al: Acute hypotensive transfusion reaction in a patient taking angiotensin-converting enzyme inhibitors therapy: A case report and literature review. *Int J Anesth Res*, 2016; 4: 195–99
7. Pollard R, Boraski M, Block JG: Hypotensive transfusion reaction treated with vasopressin in a patient taking an angiotensin-converting enzyme inhibitor: A case report. *A Case Rep*, 2017; 9(1): 4–8
8. Centers for Disease Control. NHSN Biovigilance Component, Hemovigilance Module, Surveillance Protocol v2.5.2. April 2018 [Accessed June 29, 2018]. Available from: <https://www.cdc.gov/nhsn/pdfs/biovigilance/bv-hv-protocol-current.pdf>
9. Kalra A, Palaniswamy C, Patel R et al: Acute hypotensive transfusion reaction with concomitant use of angiotensin-converting enzyme inhibitors. *Am J Ther*, 2012; 19: 90–94
10. Popovsky MA: *Transfusion reactions*. Bethesda, MD, USA: AABB Press, 2001; 222
11. Shiba M, Tadokoro K, Sawanobori M et al: Activation of the contact system by filtrate of platelet concentrates with a negatively charged white cell-removal filter and measurement of venous blood bradykinin level in patients who received filtered platelets. *Transfusion*, 1997; 37: 457–62
12. Owen HG, Brecher ME: Atypical reactions associated with use of angiotensin-converting enzyme inhibitors and apheresis. *Transfusion*, 1994; 34: 891–94
13. Quillen K: Hypotensive transfusion reactions in patients taking angiotensin-converting enzyme inhibitors. *N Engl J Med*, 2000; 343: 1422–23
14. Crews W, Kay JK, Herman JH: Washing red cells prevents recurrent acute hypotensive transfusion reactions. *Am J Clin Pathol*, 2014; 141: 285–87

Conclusions

Acute hypotensive transfusion reaction (AHTR) is a diagnosis of exclusion and is based on laboratory and clinical findings. An antibody-mediated acute hemolytic transfusion reaction should be excluded out immediately. Patients with a high risk of intraoperative bleeding might benefit from the avoidance of the use of an angiotensin-converting enzyme (ACE) inhibitor whenever possible until the interactions between AHTR with ACE and aminopeptidase P (APP) are better understood.

Conflict of interests

None.