

doi:10.3969/j.issn.1673-5374.2012.35.005 [http://www.crter.org/nrr-2012-qkquanwen.html]

Liu TT, Bi HS, Wang XR, Wang GM, Li HY, Wu H, Qu Y, Wen Y, Cong CY, Wang DG. Change of retinal nerve fiber layer thickness in patients with nonarteritic inflammatory anterior ischemic optic neuropathy. *Neural Regen Res.* 2012;7(35):2778-2783.

# Change of retinal nerve fiber layer thickness in patients with nonarteritic inflammatory anterior ischemic optic neuropathy<sup>☆</sup>

Tingting Liu, Hongsheng Bi, Xingrong Wang, Guimin Wang, Haiyan Li, Hui Wu, Yi Qu, Ying Wen, Chenyang Cong, Daoguang Wang

Eye Institute of Shandong Traditional Chinese Medicine University, Affiliated Eye Hospital of Shandong University of Traditional Chinese Medicine, Ophthalmology Department of Second Affiliated Hospital of Shandong University of Traditional Chinese Medicine, Jinan 250001, Shandong Province, China

## Abstract

In this study, 16 patients (19 eyes) with nonarteritic anterior ischemic optic neuropathy in the acute stage (within 4 weeks) and resolving stage (after 12 weeks) were diagnosed by a series of complete ophthalmic examinations, including fundus examination, optical coherence tomography and fluorescein fundus angiography, and visual field defects were measured with standard automated perimetry. The contralateral uninvolved eyes were used as controls. The retinal nerve fiber layer thickness was determined by optical coherence tomography which showed that the mean retinal nerve fiber layer thickness and the retinal nerve fiber layer thickness from temporal, superior, nasal and inferior quadrants were significantly higher for all measurements in the acute stage than the corresponding normal values. In comparison, the retinal nerve fiber layer thickness from each optic disc quadrant was found to be significantly lower when measured at the resolving stages, than in the control group. Statistical analysis on the correlation between optic disc nerve fiber layer thickness and visual defects demonstrated a positive correlation in the acute stage and a negative correlation in the resolving stage. Our experimental findings indicate that optical coherence tomography is a useful diagnostic method for nonarteritic anterior ischemic optic neuropathy and can be used to evaluate the effect of treatment.

## Key Words

nonarteritic anterior ischemic optic neuropathy; optical coherence tomography; retinal nerve fiber layer; visual field; optic nerve; peripheral nerve injury; neural regeneration

## Research Highlights

- (1) The retinal nerve fiber layer thickness in patients with nonarteritic anterior ischemic optic neuropathy was determined by optical coherence tomography. Its correlation with visual field defect was analyzed.
- (2) The retinal nerve fiber layer thickness from each optic disc quadrant was significantly increased in the acute stage, but significantly decreased in the resolving stage, in patients with nonarteritic anterior ischemic optic neuropathy.
- (3) In the acute stage, the thicker the retinal nerve fiber layer is, the worse the visual defects are. While in the resolving stage, the thinner the retinal nerve fiber layer is, the worse the visual defects are.
- (4) Optical coherence tomography is a useful diagnostic method for nonarteritic anterior ischemic optic neuropathy and can effectively evaluate the efficacy of treatment.

Tingting Liu<sup>☆</sup>, Ph.D., Associate chief physician, Eye Institute of Shandong Traditional Chinese Medicine University, Affiliated Eye Hospital of Shandong University of Traditional Chinese Medicine, Ophthalmology Department of Second Affiliated Hospital of Shandong University of Traditional Chinese Medicine, Jinan 250001, Shandong Province, China

Corresponding author: Hongsheng Bi, Ph.D., Chief physician, Eye Institute of Shandong Traditional Chinese Medicine University, Affiliated Eye Hospital of Shandong University of Traditional Chinese Medicine, Ophthalmology Department of Second Affiliated Hospital of Shandong University of Traditional Chinese Medicine, Jinan 250001, Shandong Province, China hong66bi66@yahoo.com.cn

Received: 2012-09-20  
Accepted: 2012-11-15  
(N20111127002/WLM)

## INTRODUCTION

Nonarteritic anterior ischemic optic neuropathy is potentially a devastating visual disease in middle-aged and older age groups<sup>[1-2]</sup>. Most affected patients describe a sudden visual field loss. The papilledema happens when a circulatory disturbance takes place in the front end of optic nerve and is called ischemic optic neuropathy. Visual defect is an important component for the diagnosis of nonarteritic anterior ischemic optic neuropathy but, in many cases, direct observation of visual defect might not be available<sup>[3]</sup>. Thus, a noninvasive diagnostic tool is needed.

Retinal nerve fiber layer thickness has been reported to be related to field defects<sup>[3]</sup>. Since stratus optical coherence tomography is a reliable and reproducible method to measure retinal nerve fiber layer thickness, it is possible to use optical coherence tomography imaging of the retina to provide a high-resolution, objective, noninvasive, and easily quantifiable *in vivo* diagnosis for nonarteritic anterior ischemic optic neuropathy<sup>[4-6]</sup>.

Bellusci *et al*<sup>[7]</sup> reported retinal nerve fiber layer thickness changes in nonarteritic anterior ischemic optic neuropathy patients at different time points; however, quantifiable correlation of retinal nerve fiber layer changes and visual defects was not described. In another study, although Danesh-Meyer *et al*<sup>[8]</sup> found a relationship between retinal nerve fiber layer changes and visual defects, they did not focus on the time points because the scanning laser polarimeter did not find the retinal nerve fiber layer changes in the acute stage.

In this study, nonarteritic anterior ischemic optic neuropathy patients were examined by fundus examination, optical coherence tomography, fundus fluorescein angiography and visual defects, while the unaffected eyes were used as control group. The aim of this study was to evaluate the diagnostic value of optical coherence tomography for nonarteritic anterior ischemic optic neuropathy and to find the relationship between retinal nerve fiber layer thicknesses and nonarteritic anterior ischemic optic neuropathy at different stages. In particular, retinal nerve fiber layer thickness was measured within 4 weeks and beyond 12 weeks following sudden visual field loss. The relationship between retinal nerve fiber layer changes and visual defects at different time points was then evaluated.

## RESULTS

### Quantitative analysis of involved subjects

A total of 16 patients (19 eyes) with nonarteritic anterior ischemic optic neuropathy were involved as the treatment group, while the contralateral uninvolved 11 eyes were used as controls. Another two eyes were excluded due to ocular injury and embolism of the central retinal vein. All the involved eyes entered the final analysis.

### Change of retinal nerve fiber layer in patients with nonarteritic anterior ischemic optic neuropathy

Acute stage (4 weeks) ischemic optic neuropathy was diagnosed in patients by retina angiography and papillary optical coherence tomography measurements (Figures 1A and B). The patient could not complete standard automated perimetry because of poor visual function in the acute stage. The entire optic disc was affected with diffuse retinal nerve fiber layer edema involving all four disc quadrants (temporal, superior, nasal, inferior), as shown by optical coherence tomography which grouped in corresponding sectors, as suggested by Garway-Heath *et al*<sup>[9]</sup>. The retinal nerve fiber layer thickness was clearly thinner in the resolving stage (12 weeks; Figures 1C and D). The visual function defects were visible in patients with nonarteritic anterior ischemic optic neuropathy in the resolving stage (Figures 1E and F).

The retinal nerve fiber layer thickness parameters measured at presentation (within 4 weeks) and beyond 12 weeks were significantly different in nonarteritic anterior ischemic optic neuropathy and normal control eyes ( $P < 0.01$ ). The mean retinal nerve fiber layer thickness value within 4 weeks was  $131.45 \pm 41.36 \mu\text{m}$ , which was much greater than the normal ( $95.96 \pm 23.70 \mu\text{m}$ ). On the contrary, the mean retinal nerve fiber layer thickness was significantly reduced beyond 12 weeks to  $65.25 \pm 18.06 \mu\text{m}$ , which was significantly lower than normal eyes ( $P < 0.01$ ). The retinal nerve fiber layer thickness from each optic disc quadrant (temporal, superior, nasal and inferior) were significantly higher than the corresponding normal values for all measurements in the acute stage (4 weeks;  $P < 0.01$ ), but significantly lower than the normal eyes beyond 12 weeks ( $P < 0.01$ ). The mean retinal nerve fiber layer thicknesses from  $360^\circ$  were averaged from the data of all quadrants in each group of controls, acute and resolving stages as summarized in Table 1.

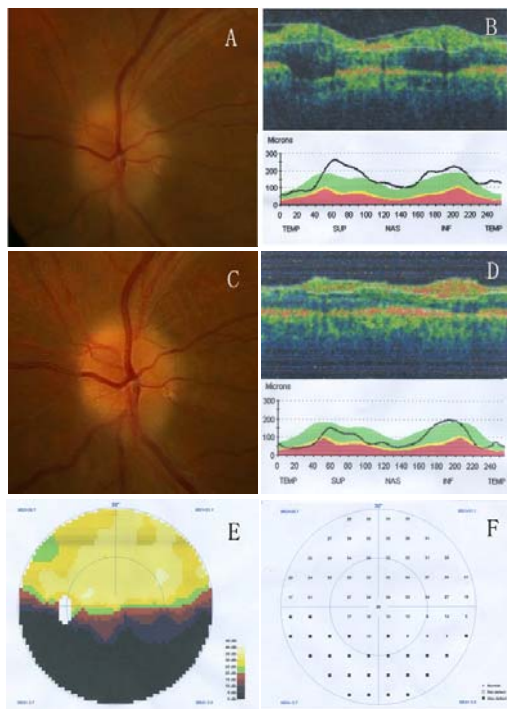


Figure 1 Retinal nerve fiber layer thickness *versus* related measurements of visual field defects in nonarteritic anterior ischemic optic neuropathy patients in acute and resolving stages.

(A, B) Acute stage. The optic disc is differentially affected with retinal nerve fiber layer edema (A) in different quadrants shown by optical coherence tomography (B).

(C, D) Resolving stage. The retinal nerve fiber layer thickness is thinner (D) than in the acute stage (B).

(E, F) The visual field defects of nonarteritic anterior ischemic optic neuropathy in the resolving stage.

(A, C) Retina angiography; (B, D) optical coherence tomography; (E, F) standard automated perimetry.

Table 1 Retinal nerve fiber layer thickness ( $\mu\text{m}$ ) of nonarteritic anterior ischemic optic neuropathy (nAION) group and normal group

Position	Normal fellow eyes	nAION eyes (< 4 weeks)	nAION eyes (> 12 weeks)
Temporal	78.2 $\pm$ 10.5	129.4 $\pm$ 42.2 <sup>a</sup>	55.3 $\pm$ 14.5 <sup>a</sup>
Superior	118.6 $\pm$ 8.3	144.5 $\pm$ 31.3 <sup>a</sup>	67.0 $\pm$ 18.2 <sup>a</sup>
Nasal	70.4 $\pm$ 4.6	104.4 $\pm$ 33.5 <sup>a</sup>	57.5 $\pm$ 12.8 <sup>a</sup>
Inferior	116.7 $\pm$ 10.6	147.5 $\pm$ 44.9 <sup>a</sup>	81.3 $\pm$ 14.6 <sup>a</sup>

Data are expressed as mean  $\pm$  SD, there are 19 eyes in nAION group and 11 normal control eyes. <sup>a</sup> $P < 0.01$ , vs. normal fellow eyes (*t*-test).

### Visual field defects in nonarteritic anterior ischemic optic neuropathy patients

Visual field defects were determined with standard automated perimetry. As shown in Table 2, the average visual defects in nonarteritic anterior ischemic optic neuropathy patients were significantly more than that in normal eyes ( $P < 0.01$ ).

### Correlation between visual field defects and retinal nerve fiber layer thickness

The correlations between inferior visual field defects and superior retinal nerve fiber layer thickness and between superior visual field defects and inferior retinal nerve fiber layer thickness of the disc area with nonarteritic anterior ischemic optic neuropathy were subjected to Pearson correlation analysis. Results showed that, in the acute stage, the correlations between inferior visual field defects and superior retinal nerve fiber layer thickness were positive and the positive correlation coefficients tended to increase together ( $r = 0.149\ 2$ ,  $P < 0.05$ ). There were no significant relationships between normal controls ( $P = 0.541$ ). In the resolving stage, the pairs of variables had negative correlation coefficients ( $r = -0.838\ 3$ ,  $P < 0.01$ ; Figure 2).

Table 2 Visual field mean deviation (dB) of nonarteritic anterior ischemic optic neuropathy (nAION) group and normal group

Position	Normal fellow eyes	nAION eyes (< 4 weeks)	nAION eyes (> 12 weeks)
Superior	1.638 $\pm$ 1.372	3.758 $\pm$ 1.916 <sup>a</sup>	6.468 $\pm$ 3.905 <sup>a</sup>
Inferior	1.115 $\pm$ 0.918	6.837 $\pm$ 4.844 <sup>a</sup>	3.068 $\pm$ 2.022 <sup>a</sup>

Data are expressed as mean  $\pm$  SD, there are 19 eyes in nAION group and 11 normal control eyes. <sup>a</sup> $P < 0.01$ , vs. normal fellow eyes (*t*-test).

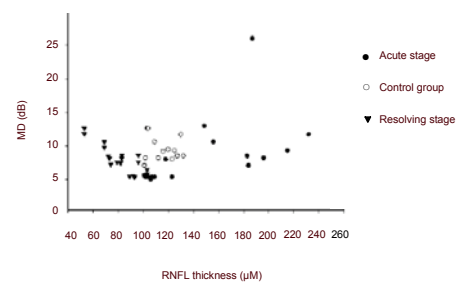
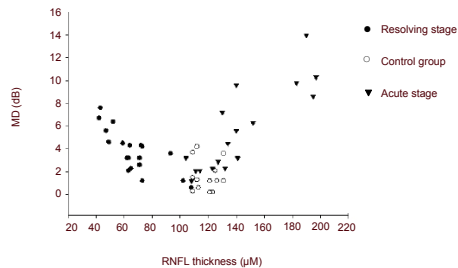


Figure 2 The correlation between inferior visual field mean deviation (MD; dB) and superior retinal nerve fiber layer (RNFL) thickness ( $\mu\text{m}$ ).

Scatter plots show the correlation between superior visual field MD and RNFL thickness of the disc area with nonarteritic anterior ischemic optic neuropathy. In the acute stage, the pairs of variables with positive correlation coefficients tend to increase together ( $r = 0.149\ 2$ ,  $P < 0.05$ ). There are no significant relationships between normal controls ( $P = 0.541$ ). In the resolving stage, the pairs of variables had negative correlation coefficients ( $r = -0.838\ 3$ ,  $P < 0.01$ ).

Figure 3 reflects the correlation between superior visual field defects and inferior retinal nerve fiber layer thickness at different sectors. In the acute stage, the pairs of variables with positive correlation coefficients tended to increase together ( $r = 0.409\ 7$ ,  $P < 0.05$ ). There

were no significant relationships between normal controls ( $P = 0.669$ ). In the resolving stage, the pairs of variables had negative correlation coefficients ( $r = -0.779\ 1$ ,  $P < 0.05$ ).



**Figure 3** The correlation between superior visual field mean deviation (MD; dB) and inferior retinal nerve fiber layer (RNFL) thickness ( $\mu\text{m}$ ).

In the acute stage, the pairs of variables showed positive correlation coefficients and tend to increase together ( $r = 0.409\ 7$ ,  $P < 0.05$ ). There are no significant relationships between any pair of variables in the correlation table ( $P = 0.669$ ). In the resolving stage, the pairs of variables showed negative correlation coefficients and tend to decrease ( $r = -0.779\ 1$ ,  $P < 0.05$ ), while the RNFL thickness increases.

## DISCUSSION

The strong correlations between retinal nerve fiber layer thicknesses and the progressive stages of visual defects suggests that variation of retinal nerve fiber layer thickness could be a stage specific character for the diagnosis and evaluation of nonarteritic anterior ischemic optic neuropathy. Retinal nerve fiber layer thickness measurement is conveniently available by optical coherence tomography. Since optical coherence tomography allows *in vivo* imaging and measurement of retinal and optic nerve anatomy, this method can provide objective quantitative data for different areas of the nerve fiber layer with nonarteritic anterior ischemic optic neuropathy<sup>[10-11]</sup> in both the acute stage and the resolving stage.

Retinal nerve fiber layer thickness changes at the different stages of neuropathy have been reported rarely. In this paper, in the first 4 weeks after sudden visual field loss, the mean retinal nerve fiber layer thicknesses from temporal, superior, nasal and inferior quadrants are significantly higher than the corresponding normal values. Conversely, the retinal nerve fiber layer thickness from each optic disc quadrant is significantly lower than in the control group beyond 12 weeks. The regions of edema are continuous. The diagnosis of nonarteritic anterior ischemic optic neuropathy currently relies on more

subjective findings, such as characteristic optic nerve damages usually accompanied by visual field changes. Measuring the retinal nerve fiber layer thickness is now considered a potential method of diagnosing nonarteritic anterior ischemic optic neuropathy and its progressive and resolving stages.

Retinal nerve fiber layers, consisting of the axons from retinal ganglion cells, are thicker at 4 weeks and thinner after 12 weeks. It is thicker in the acute stage because the first defects are optic nerve axon edema in the ischemic areas then edema in all four quadrants of the optic disc. Optic nerve axon degeneration starts after the acute stage. After 12 weeks, not only the edemas of the ischemic areas but also the non-ischemic areas are resolving. Although most non-ischemic retinal nerve fiber layer thicknesses are normal, the thicknesses of all ischemic quadrants show significant decreases. It is also reported that death of ganglion cells contributes to the decrease of the retinal nerve fiber layer thickness.

At different stages, the retinal nerve fiber layer thickness changes greatly suggesting a correlation between the retinal nerve fiber layer thickness and visual defects. The therapy of nonarteritic anterior ischemic optic neuropathy is still controversial<sup>[12]</sup>, especially the use of corticosteroid and intravitreal Bevacizumab. The retinal nerve fiber layer in eyes with nonarteritic anterior ischemic optic neuropathy remained swollen from the acute event<sup>[13]</sup>. Most of our imaging studies were performed more than 6 weeks after presentation, however, after 12 weeks death or apoptosis of the retinal ganglion cells may occur in response to the ischemic optic neuropathy. Therefore it is important to provide therapy before 12 weeks.

The rapid resolution of disc swelling and prompt improvement in visual acuity after Bevacizumab administration suggested that vascular endothelial growth factor-induced vascular permeability may play a role in tissue injury in nonarteritic anterior ischemic optic neuropathy<sup>[14]</sup>. Visual field defect and retinal nerve fiber layer thickness detected by optical coherence tomography varied among different studies, depending on the subjects and instruments<sup>[3, 15]</sup>, but their correlation was obvious. Although retinal nerve fiber layer thickness differences were found in all the quadrants, most researchers agreed that the superior quadrant representing the inferior hemifield visual field and the inferior quadrant representing the superior hemifield were most affected<sup>[9, 16]</sup>, which is consistent with the present study that average retinal nerve fiber layer thickness represents nonarteritic anterior ischemic optic neuropathy status.



Superior and inferior visual field indexes showed a strong correlation with inferior and superior retinal nerve fiber layer changes respectively. Most importantly the thickness of the retinal nerve fiber layer is positively correlated with the visual defects in the acute stage. That means the more edema the retinal nerve fiber layer has, the worse the visual defects are. While in the resolving stage, the retinal nerve fiber layer is negatively correlated with the visual defects, which suggest that the thinner the retinal nerve fiber layer is, the worse the visual defects are.

Retinal nerve fiber layer thickness analysis using optical coherence tomography may be clinically useful in identifying nonarteritic anterior ischemic optic neuropathy. It may also be used to search for clues to explain the nonarteritic anterior ischemic optic neuropathy and retinal nerve fiber layer changes following axon lesions<sup>[17]</sup>.

## SUBJECTS AND METHODS

### Design

A self-controlled clinical study.

### Time and setting

Experiments were performed from January 2009 to December 2010 in the Affiliated Eye Hospital of Shandong University of Traditional Chinese Medicine, China.

### Subjects

A total of 16 Chinese patients (19 eyes) with nonarteritic anterior ischemic optic neuropathy were tested and diagnosed based on clinical examinations, including fundus examination, visual field analysis, and stratus optical coherence tomography<sup>[18]</sup>. Each eye was tested three times.

### Inclusion criteria

(1) A history of sudden visual loss; (2) optic disc edema at onset must have been documented in the Ocular Vascular Clinic; (3) the eye had optic disc-related visual field defects; (4) there was no neurologic, systemic, or ocular disorder that could be responsible for optic disc edema and visual impairment.

### Exclusion criteria

Patients with any retinal or optic nerve lesion or any other factor (cataract) were excluded. The nonarteritic anterior ischemic optic neuropathy patients with only background diabetic retinopathy were included, but those who had active neovascularization, vitreous hemorrhages, traction

detachment, glaucoma or other complications influencing the visual acuity or fields were excluded. The other unaffected eyes were used as the control group.

All subjects ranged in age from 45 to 72 years at a mean  $56.9 \pm 7.2$  years. There were 10 men and 6 women. Fundus examination displayed optic disc uneven edema, and fluorescein fundus angiography revealed optic disc asymmetrical high fluorescence and leakage at an advanced stage. Visual field defects were linked with the physiological blind spot. All involved subjects signed the informed consent. This study was conducted in accordance with the ethics requirement in the *Declaration of Helsinki*.

## Methods

### Optical coherence tomography

The commercially available optical coherence tomography 3 (Stratus optical coherence tomography, software version 4.0; Carl Zeiss Ophthalmic Systems Inc., Humphrey Division, Dublin, CA, USA) was used to measure peripapillary retinal nerve fiber layer thickness (retinal nerve fiber layer Thickness 3.4 acquisition protocol). Patients in the sitting position were forced to place their lower mandible at the bracket and to gaze at the fixation point within the shot. The default sectors were defined as temporal ( $311^\circ$  to  $40^\circ$ ), superior ( $41^\circ$  to  $120^\circ$ ), nasal ( $121^\circ$  to  $230^\circ$ ), and inferior ( $231^\circ$  to  $310^\circ$ )<sup>[6]</sup>. In all nonarteritic anterior ischemic optic neuropathy eyes, the mean value of  $360^\circ$  averaged retinal nerve fiber layer thickness and mean temporal, superior, nasal and inferior optic disc quadrant retinal nerve fiber layer thickness obtained from three good-quality images (signal strength  $\geq 6$ ) were considered for statistical purposes.

### Standard automated perimetry

All participants underwent visual field testing with standard automated perimetry (Octopus 101 perimeter; Haag-Streit AG, Switzerland), glaucoma program, 30-2 strategy (tendency-oriented perimetry)<sup>[19]</sup>. The mean deviation was the calculation results using standard automated perimetry. All participants had at least one previous visual field test with the same perimeter. Test results with less than 10% of false-positive or negative responses were included.

### Statistical analysis

Data are expressed as mean  $\pm$  SD. A paired *t*-test was used to compare affected with unaffected eyes. The mean retinal nerve fiber layer values obtained from all 16 patients (19 eyes) with nonarteritic anterior ischemic optic neuropathy were compared with the control group. A

Pearson correlation coefficient ( $r$ ) was calculated for each sector to measure the degree of correlation between standard automated perimetry and retinal nerve fiber layer thickness. A  $P$  value  $< 0.05$  was considered statistically significant. Statistical analyses were performed using SPSS software version 12.0 (SPSS, Chicago, IL, USA).

**Funding:** This study was supported by the National Natural Science Foundation of China, No. 81173440 and the Natural Science Foundation of Shandong Province, No. ZR2009CL038.

**Author contributions:** Hongsheng Bi, Chenyang Cong and Daoguang Wang provided the data and validated the paper. Tingting Liu integrated the data. Tingting Liu, Hongsheng Bi and Xingrong Wang were responsible for the study concept and design. Guimin Wang, Haiyan Li, and Ying Wen analyzed the data. Tingting Liu and Yi Qu drafted the manuscript. Hui Wu performed statistical processing. Hongsheng Bi and Tingting Liu were in charge of funds. All authors approved the final version of the manuscript.

**Conflicts of interest:** None declared.

**Ethical approval:** The experimental proposals were approved by the Ethical Committee of Affiliated Eye Hospital of Shandong Traditional Chinese Medicine University in China.

**Author statements:** The manuscript is original, has not been submitted to or is not under consideration by another publication, has not been previously published in any language or any form, including electronic, and contains no disclosure of confidential information or authorship/patent application/funding source disputations.

## REFERENCES

- [1] Kerr NM, Chew SS, Danesh-Meyer HV. Non-arteritic anterior ischemic optic neuropathy: a review and update. *J Clin Neurosci*. 2009;16(8):994-1000.
- [2] Colen TP, van Everdingen JA, Lemij HG. Axonal loss in a patient with anterior ischemic optic neuropathy as measured with scanning laser polarimetry. *Am J Ophthalmol*. 2000;130(6):847-850.
- [3] Horowitz J, Fishelson-Arev T, Rath EZ, et al. Comparison of optic nerve head topography findings in eyes with non-arteritic anterior ischemic optic neuropathy and eyes with glaucoma. *Graefes Arch Clin Exp Ophthalmol*. 2010;248(6):845-851.
- [4] Savini G, Bellusci C, Carbonelli M, et al. Detection and quantification of retinal nerve fiber layer thickness in optic disc edema by stratus optical coherence tomography. *Arch Ophthalmol*. 2006;124(8):1111-1117.
- [5] Contreras I, Noval S, Rebolledo G, et al. Follow-up of nonarteritic anterior ischemic optic neuropathy with optical coherence tomography. *Ophthalmology*. 2007;114(12):2338-2344.
- [6] Chew SS, Cunningham WJ, Gamble GD, et al. Retinal nerve fiber layer loss in glaucoma patients with a relative afferent pupillary defect. *Invest Ophthalmol Vis Sci*. 2010;51(10):5049-5053.
- [7] Bellusci C, Savini G, Carbonelli M, et al. Retinal nerve fiber layer thickness in nonarteritic the acute and resolving phases. *Graefes Arch Clin Exp Ophthalmol*. 2008;246(5):641-647.
- [8] Danesh-Meyer HV, Carroll SC, Ku JY, et al. Correlation of retinal nerve fiber layer measured by scanning laser polarimeter to visual field in ischemic optic neuropathy. *Arch Ophthalmol*. 2006;124(12):1720-1726.
- [9] Garway-Heath DF, Poinosawmy D, Fitzke FW, et al. Mapping the visual field to the optic disc in normal tension glaucoma eyes. *Ophthalmology*. 2000;107(10):1809-1815.
- [10] Deleón-Ortega J, Carroll KE, Arthur SN, et al. Correlations between retinal nerve fiber layer and visual field in eyes with nonarteritic anterior ischemic optic neuropathy. *Am J Ophthalmol*. 2007;143(2):288-294.
- [11] Lopez-Peña MJ, Ferreras A, Larrosa JM, et al. Relationship between standard automated perimetry and retinal nerve fiber layer parameters obtained with optical coherence tomography. *J Glaucoma*. 2011;20(7):422-432.
- [12] Hayreh SS. Intravitreal triamcinolone for nonarteritic anterior ischemic optic neuropathy. *J Neuroophthalmol*. 2008;28(1):77-78.
- [13] Hayreh SS. Pathogenesis of nonarteritic anterior ischemic optic neuropathy. *Arch Ophthalmol*. 2009;127(8):1082-1083.
- [14] Ganssauge M, Wilhelm H, Bartz-Schmidt KU, et al. Non-arteritic anterior ischemic optic neuropathy (NA-AION) after intravitreal injection of bevacizumab (Avastin) for treatment of angoid streaks in pseudoxanthoma elasticum. *Graefes Arch Clin Exp Ophthalmol*. 2009;247(12):1707-1710.
- [15] Horn FK, Mardin CY, Laemmer R, et al. Correlation between local glaucomatous visual field defects and loss of nerve fiber layer thickness measured with polarimetry and spectral domain OCT. *Invest Ophthalmol Vis Sci*. 2009;50(5):1971-1977.
- [16] Cvenkel B, Kontestabile AS. Correlation between nerve fibre layer thickness measured with spectral domain OCT and visual field in patients with different stages of glaucoma. *Graefes Arch Clin Exp Ophthalmol*. 2011;249(4):575-584.
- [17] Zhang C, Guo Y, Slater BJ, et al. Axonal degeneration, regeneration and ganglion cell death in a rodent model of anterior ischemic optic neuropathy (rAION). *Exp Eye Res*. 2010;91(2):286-292.
- [18] Tian GH, Jia N, Lu CF, et al. Clinical characteristics of non-arteritic anterior ischemic optic neuropathy. *Zhonghua Yan Ke Za Zhi*. 2009;45(12):1064-1067.
- [19] Fukuchi T, Yoshino T, Sawada H, et al. Progression rate of total, and upper and lower visual field defects in open-angle glaucoma patients. *Clin Ophthalmol*. 2010;4:1315-1323.

(Edited by Ma HH, Liu YL/Yang Y/Song LP)