

# Salvage therapy for subclavian artery perforation resulting in mediastinal hematoma during percutaneous coronary intervention

## A case report

Wenhua Li, MS<sup>a,\*</sup>, Hongjian Shi, MD<sup>b</sup>, Yong Li, MD<sup>a</sup>

### Abstract

**Rationale:** Transradial access (TRA) is a widely used technique during percutaneous coronary intervention (PCI). However, mediastinal and cervical hematomas, the rare and severe complications of transradial approach, have extremely high mortality rates. To the best of our knowledge, there were no medical literatures about the successful anticoagulation reversal procedure of mediastinal hematoma in PCI till now.

**Patient concerns:** We here present a 54-year-old male Han patient who underwent PCI. Immediately after PCI, he reported an episode of neck and chest discomfort, dyspnea, cough recurrence, and cold sweats. Emergency chest computed tomography (CT) revealed a perforation of the subclavian artery resulting in a large mediastinal hematoma with potentially lethal tracheal compression.

**Diagnosis:** A diagnosis of the large mediastinal hematoma was made based on the enhanced computed tomography.

**Interventions:** The patient was successfully managed with palliative therapy of anticoagulation reversal instead of a covered stent graft and surgical operation.

**Outcomes:** Angiography confirmed the absence of leakage after anticoagulation reversal. The patient had an apparent remission of clinical dyspnea. Follow-up CT confirmed an almost entire absorption of the mediastinal hematoma 35 days postdischarge.

**Lessons:** The current case highlights the importance of anticoagulation reversal as well as careful guidewire and guide catheter manipulation by the radial approach. Early evaluation, prompt identification, appropriate treatment, and close monitoring are all essential for invasive cardiology.

**Abbreviations:** ACT = activated clotting time, CCU = cardiac care unit, CT = computed tomography, LAD = left anterior descending, LCA = left coronary artery, PCI = percutaneous coronary intervention, TRA = transradial access.

**Keywords:** anticoagulation reversal, mediastinal hematoma, percutaneous coronary intervention, transfemoral access, transradial access

## 1. Introduction

The past few decades have witnessed an increasing trend toward transradial access (TRA) in percutaneous coronary intervention

Editor: N/A.

*Patient consent:* Informed written consent was obtained from the patient for publication of this case report and accompanying images.

*Ethical approval:* The study protocol was approved by the Ethics Committee of Affiliated Wujin Hospital of Jiangsu University, and all participants provided written informed consent.

The authors have no funding and conflicts of interest to disclose.

<sup>a</sup> Department of Cardiology, <sup>b</sup> Department of Intervention, Affiliated Wujin Hospital of Jiangsu University, Changzhou, Jiangsu, China.

\* Correspondence: Wenhua Li, Department of Cardiology, Affiliated Wujin Hospital of Jiangsu University, Changzhou, Jiangsu, China (e-mail: 64641233@qq.com).

Copyright © 2019 the Author(s). Published by Wolters Kluwer Health, Inc. This is an open access article distributed under the terms of the Creative Commons Attribution-Non Commercial License 4.0 (CCBY-NC), where it is permissible to download, share, remix, transform, and buildup the work provided it is properly cited. The work cannot be used commercially without permission from the journal.

Medicine (2019) 98:19(e15550)

Received: 22 November 2018 / Received in final form: 1 April 2019 / Accepted: 10 April 2019

<http://dx.doi.org/10.1097/MD.00000000000015550>

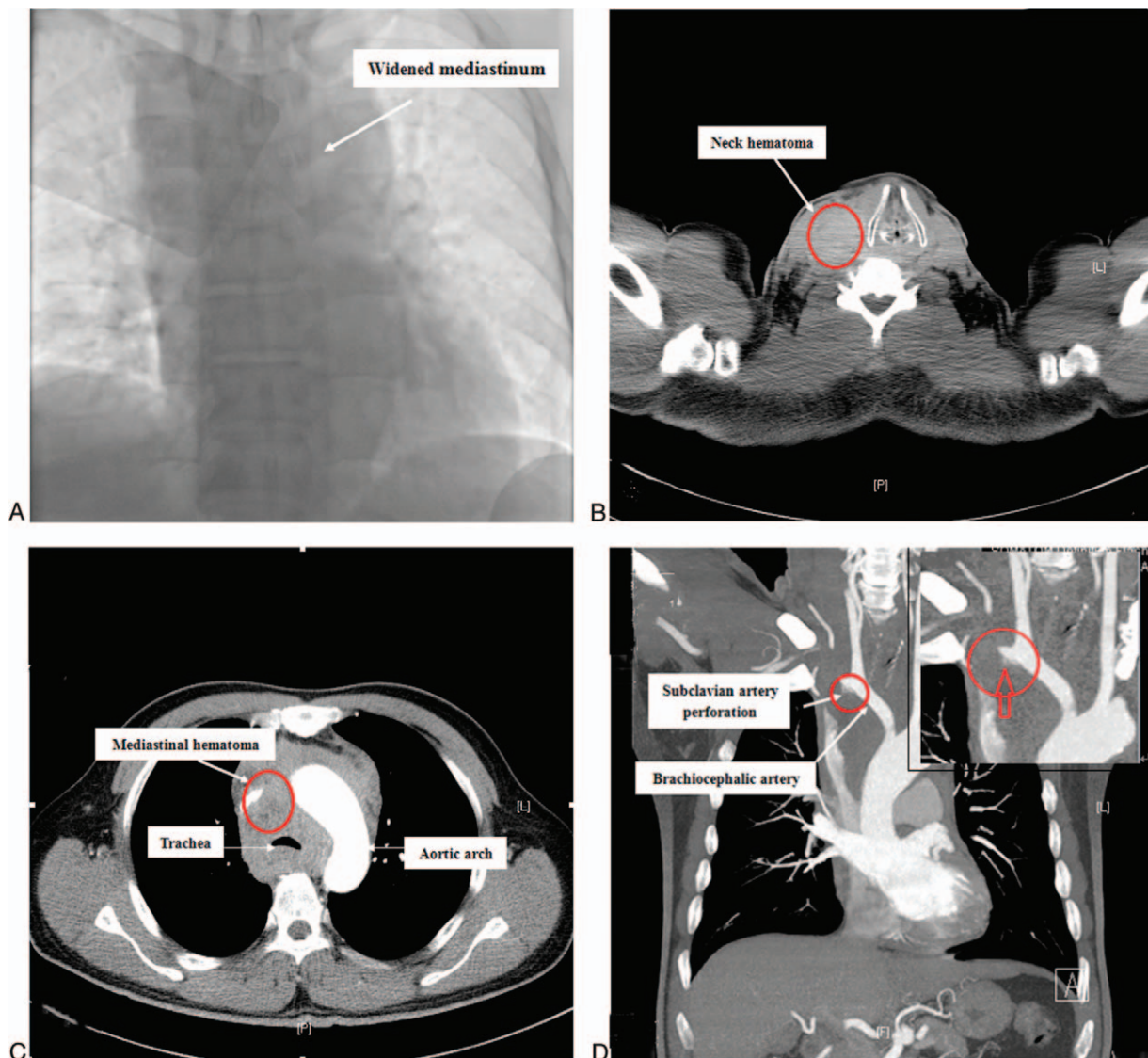
(PCI) in China. Compared with transfemoral access, TRA in PCI is a widely used technique with lower bleeding risk, less vascular complications, earlier ambulation, and improved patient comfort.<sup>[1–3]</sup> The common complications of transradial access include radial artery occlusion, nonocclusive radial artery injury, and radial artery spasm. However, mediastinal and cervical hematomas, some of the rare and severe complications of the transradial approach, occur in approximately 0.008% of coronary procedures and have extremely high mortality rates.<sup>[4]</sup> In this report, we presented a very uncommon case of subclavian artery perforation with the symptom of severe dyspnea due to the development of a large mediastinal hematoma.

## 2. Case report

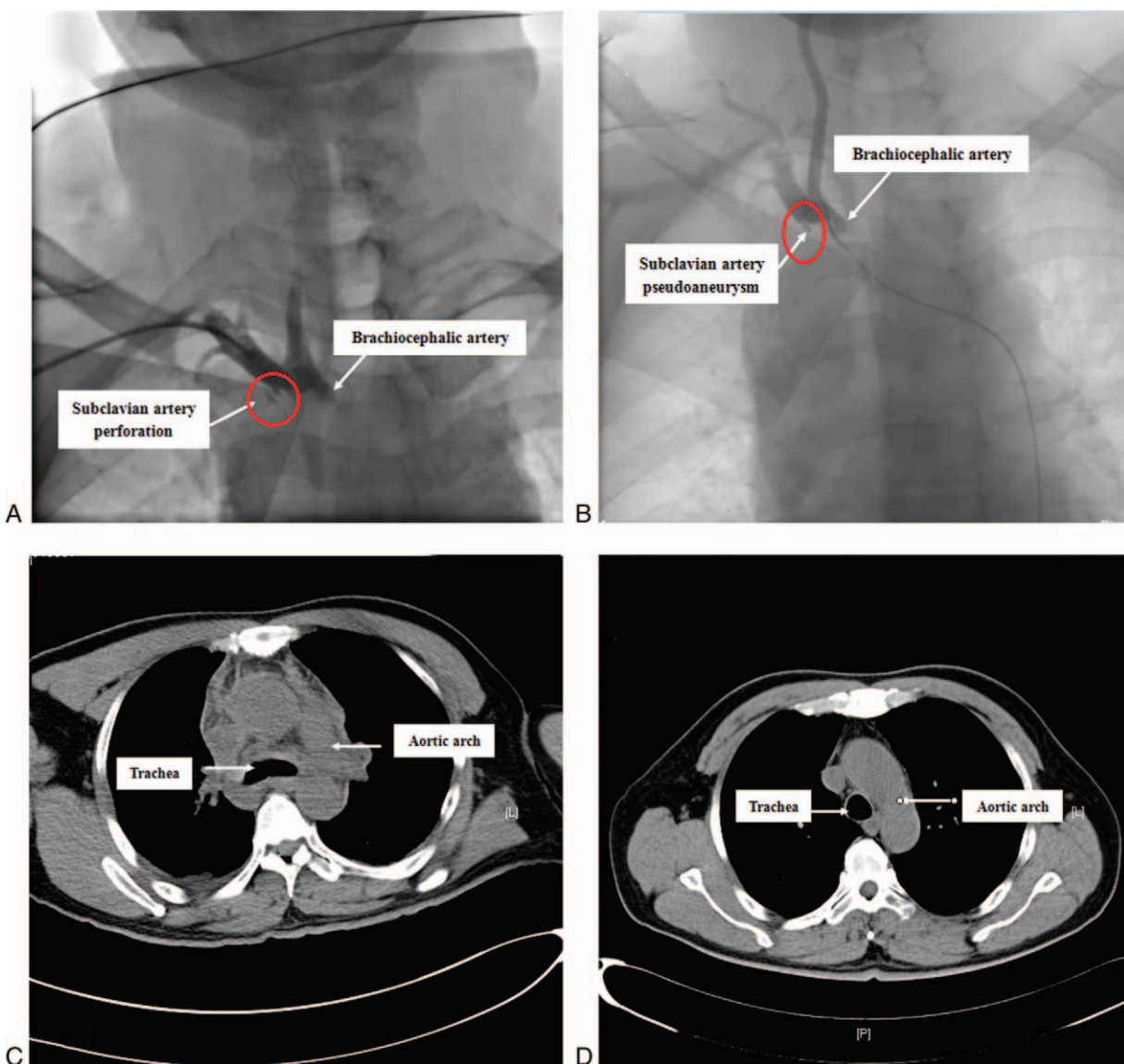
A 54-year-old male Han patient was referred to our hospital for a 6-day history of unstable angina on April 2, 2018. He complained of associated palpitation, diaphoresis, and pleuritic chest pain. The patient denied any history of trauma, cough, vomiting, or other constitutional symptoms. He had a 20-pack-year smoking history. His medical history was significant hypertension treated with amlodipine (5 mg/d). He received aspirin (Bayer, Leverkusen, Germany), clopidogrel (Sanofi, Paris, France), and other conventional treatments after admission. At the 3rd day, routine diagnostic coronary angiography revealed subtotal (99%) stenosis in the distal left anterior descending

(LAD) coronary artery by the right radial artery approach. Heparin (70–100 U/kg) was administered during the intervention guided by the activated clotting time (ACT; target value of 280–350 seconds). A 6 French EBU3.5 guide catheter (Medtronic, Minneapolis, MN) was advanced over an exchange length 0.035// hydrophilic J-wire without fluoroscopy, but could not be smoothly delivered to the ascending aorta due to resistance in the tortuous subclavian and the brachiocephalic artery. The distal guidewire was confirmed to be inside the lumen of the guide catheter by fluoroscopy. Therefore, the guidewire was again appropriately positioned in the ascending aorta under fluoroscopy. However, the guidewire's support was poor, and the guide catheter could not advance. Then, the dual-guidewire technique was successfully applied to advance the guide catheter to the left coronary artery (LCA). Finally, PCI was performed smoothly, during which the patient felt some discomfort on his right neck.

Immediately after the procedure, the patient was transferred to the cardiac care unit (CCU). Five minutes later, he reported an episode of neck and chest discomfort, dyspnea, cough recurrence, and cold sweats. However, sufficient peripheral artery oxygen saturation and normal blood pressure revealed stable hemodynamics. The patient was rapidly administered IV 10 mg furosemide (Jinling Pharmaceutical Co., Zhejiang, CN) for presumed acute left heart failure due to dyspnea, recurrent cough, and subtotal stenosis in LAD. However, the series of discomforts even worsened. Peripheral artery oxygen saturation declined to 90%–92% in room air and the heart rate significantly increased. Finally, careful physical examination showed a right-sided swelling at the base of the patient's neck and the absence of pulmonary rales. Chest fluoroscopy during PCI was promptly performed, which revealed a dramatically widened superior mediastinum (Fig. 1A).



**Figure 1.** (A) Chest fluoroscopy (anteroposterior orientation) during PCI showing enlarged mediastinum. (B) Plain computed tomography (CT) of the neck revealing a significant mass in the lower right neck. (C, D) Enhanced CT of the chest showing a mediastinal hematoma, compressed trachea, and a small perforation of the subclavian artery.



**Figure 2.** (A) Angiography of the brachiocephalic artery showing a small perforation of the subclavian artery via radial artery access. (B) Angiography of the brachiocephalic artery revealing the presence of right subclavian artery pseudoaneurysm after intravenous injection of protamine. (C) Plain computed tomography (CT) of the chest showing trachea compression alleviation on the 2nd day of hospitalization. (D) Plain CT revealing an almost entire absorption of the mediastinal hematoma 35 days postdischarge.

To further clarify this problem, an emergency-enhanced computed tomography (CT) scan was performed, which showed a significant mass in the lower right neck and the anterior mediastinum (Fig. 1B, C). The mass surrounded the thoracic ascending aorta and the trachea, indicating an anterior mediastinal hematoma. The trachea was severely compressed by the mediastinal hematoma (Fig. 1C). Coronal CT scan of the chest revealed a small perforation of the subclavian artery (Fig. 1D). Urgent consultations with the anesthesiologist, and cardiothoracic and vascular surgeons were performed for the evaluation of possible anoxic events and unstable hemodynamics. Emergency endotracheal intubation was suggested, which was declined by the patient himself and his family members.

Due to worsening dyspnea, the patient was taken to the catheter lab again. With the anesthetist on standby, angiography

of the brachiocephalic artery was performed via the right radial route, which revealed a perforation of the proximal right subclavian artery (Fig. 2A). At the beginning, a suggestion was made to place a covered stent graft. However, the perforation site was extremely close to the carotid artery. It was possible to completely occlude the carotid artery by the covered stent graft, which may cause cerebral infarction and even death. Then, the jailed balloon technique was suggested to prevent carotid artery occlusion. To increase the success rate of the surgery, the femoral route was applied. Then, the patient's recorded ACT was 285 seconds and he was rapidly administered 50mg IV protamine (First Biochemical Pharmaceutical Co., Shanghai, CN) to reverse the effect of heparin for presumed perforation and hematoma. Two minutes later, the ACT was 173 seconds, and angiography of the brachiocephalic artery was performed by the right femoral

route, which revealed reduced extravasation of contrast from the site of vascular perforation. Five minutes later, another 10 mg protamine was provided, which reduced the ACT to 120 seconds. Angiography confirmed the presence of right subclavian artery pseudoaneurysm and the absence of leakage at this moment (Fig. 2B). The patient had an apparent remission of clinical dyspnea. The patient was transferred to the cardiac care unit (CCU) for close observation.

The next day after PCI, aspirin (75 mg/d) and clopidogrel (75 mg/d) were continued. Plain chest computed tomography (CT) was performed to confirm trachea compression alleviation (Fig. 2C). To avoid lung infection, cefazolin (2g/d; Jiuxin Pharmaceutical Co., Shenzhen, CN) was prophylactically used for the next 48 hours. The patient was ultimately discharged 5 days later. The patient was advised to continue standard dual antiplatelet therapy for at least 12 months after discharge. Follow-up CT confirmed an almost entire absorption of the mediastinal hematoma 35 days postdischarge on May 15, 2018 (Fig. 2D). The patient had no chest discomfort in the following 6 months as assessed during outpatient visits.

### 3. Discussion

Transradial access was first described for coronary angiography by Campeau in 1989.<sup>[5]</sup> Tatli et al confirmed the safety profile of radial artery access, with a low incidence (0.04%) of periprocedural unusual vascular and hemorrhagic complications.<sup>[6]</sup> The vascular and hemorrhagic complications of transradial catheterization include access site major bleeding, perforation, radial pseudoaneurysm, and arteriovenous fistula. We described a rare case of perforation of the subclavian resulting in a large mediastinal hematoma with potentially lethal tracheal compression. It is likely that attempts to advance the guide catheter violently against resistance injured the vessel wall without confirming guidewire protrusion through the lumen of the guide catheter under fluoroscopy monitoring. Afterward, fluoroscopy showed that the guidewire came back into the lumen of the guide catheter from the ascending aorta, due to severe tortuosity of the subclavian and brachiocephalic arteries. When resistance is encountered, fluoroscopy should be used to ensure the appropriate guidewire position. Some existing techniques, such as balloon-assisted tracking, abduction of the arm, and deep inspiration, can avoid vessel shearing from the “razor effect” at the distal tip of the guide catheter.<sup>[7]</sup> In the current case, we finally took dual guidewires to strengthen support and successfully deliver the guide catheter to the ostium of the LCA under fluoroscopy.

Conservative managements of perforated subclavian and brachiocephalic arteries are hampered by the inefficient application of local pressure due to the presence of the collarbone and ribs. Habib et al described the case of a 79-year-old woman in whom perforation of the subclavian artery occurred during cardiac catheterisation via the radial artery, and the patient was treated by a covered stent.<sup>[8]</sup> Fahad Farooqi et al described an unusual small bi-lobed pseudoaneurysm originating from the right costocervical artery during PCI. This leakage was successfully treated by coil embolisation of the feeder artery.<sup>[9]</sup> In the current case, the perforation site was extremely close to the carotid artery, which made the covered stent and coil embolization ineffective. It is possible that the carotid artery was completely occluded by the covered stent graft, which may cause cerebral infarction and even death.

Therefore, with careful monitoring of the ACT value, the patient was administrated protamine to reverse the effect of heparin. In this case, salvage reversal of anticoagulation played an important role for treating subclavian artery perforation resulting in mediastinal hematoma, even probably more important than covered stent grafts in some cases. In the face of accidents, we should not overlook some of the most basic measures, which can sometimes save lives. However, protamine must be administrated with close ACT monitoring; otherwise, it might bring potential catastrophic consequences after PCI, for example, stent thrombosis.

In addition, the current case illustrates the importance of extensive differential diagnosis and careful physical examination when dyspnea occurs after PCI. Actually, heart failure is not rare during PCI, especially in case of significant stenosis or total occlusion in the LAD coronary artery. In the present case, heart failure was firstly taken into account due to dyspnea, recurrent cough, and myocardial ischemia during PCI. However, we reached a false diagnosis because of a noncomprehensive physical examination in the first place. Ineffective treatment with diuretics and the absence of pulmonary rales revealed that the possibility of heart failure was rather small. Once heart failure is unlikely; alternate diagnoses must be promptly considered, including fatal cardiac tamponade and acute pulmonary embolism. However, these diagnoses cannot explain the right-sided swelling observed at the base of the patient's neck. Therefore, artery perforation should be the main reason for progressive neck swelling.

### 4. Conclusion

Interventional cardiologists should avoid rough advancement of the guide catheter and the wire against resistance without fluoroscopy during *transradial* catheterization. Anticoagulation reversal, as one of the most basic measures, plays an important role for fatal hemorrhagic and/or vascular complications. Early evaluation, prompt identification, appropriate therapy, and close monitoring are all essential for the successful treatment of fatal complications.

### Acknowledgments

We thank the patient for allowing us to share this case and any accompanying images.

### Author contributions

**Conceptualization:** Wenhua Li.

**Data curation:** Wenhua Li, Hongjian Shi.

**Formal analysis:** Yong Li.

**Writing – original draft:** Wenhua Li, Hongjian Shi, Yong Li.

### References

- Stolker JM, Hadid M, Hussain ZM, et al. Training the next generation of invasive cardiologists: feasibility of implementing a trans-radial access program at an academic hospital. *Cardiovasc Revasc Med* 2016;17:431–7.
- Kilic S, Hermanides RS, Ottervanger JP, et al. Effects of radial versus femoral artery access in patients with acute myocardial infarction: a large centre prospective registry. *Neth Heart J* 2017;25:33–9.
- Valgimigli M, Gagnor A, Calabro P, et al. Radial versus femoral access in patients with acute coronary syndromes undergoing invasive management: a randomised multicentre trial. *Lancet* 2015;385:2465–76.

- [4] Yang W, Qiao S, Liu R, et al. [Clinical features and outcome of eight patients with mediastinal and neck hematoma after transradial cardiac catheterization approach]. *Zhonghua Xin Xue Guan Bing Za Zhi* 2014;42:406–12.
- [5] Campeau L. Percutaneous radial artery approach for coronary angiography. *Cathet Cardiovasc Diagn* 1989;16:3–7.
- [6] Tatli E, Buturak A, Cakar A, et al. Unusual vascular complications associated with transradial coronary procedures among 10,324 patients: case based experience and treatment options. *J Interv Cardiol* 2015;28:305–12.
- [7] Smilowitz NR, Saric M, Attubato MJ, et al. Mediastinal hematoma and tracheal compression following transradial percutaneous coronary intervention. *Case Rep Cardiol* 2018;2018:6790120.
- [8] Habib N, Jerzewski A, Koomen EM, et al. Subclavian artery perforation complicating coronary angiography. *Neth Heart J* 2012;20:288–90.
- [9] Farooqi F, Alexander J, Sarma A. Rare vascular perforation complicating radial approach to percutaneous coronary angioplasty. *BMJ Case Rep* 2013;2013: pii: bcr2012007732.