

Successful Treatment of Spontaneous Coronary Artery Dissection With Cutting Balloon Angioplasty

Mohamed Zghouzi¹, Homam Moussa Pacha², Yasar Sattar³, M. Chadi Alraies⁴

1. Internal Medicine, Detroit Medical Center, Detroit, USA 2. Cardiovascular Disease, University of Texas Health Science Center at Houston McGovern Medical School, Houston, USA 3. Internal Medicine, Icahn School of Medicine at Mount Sinai, New York, USA 4. Cardiology, Detroit Medical Center, Detroit, USA

Corresponding author: Mohamed Zghouzi, m.zghouzi@gmail.com

Abstract

Spontaneous coronary artery dissection (SCAD) is a rare but serious condition that requires immediate attention. It has a similar presentation to acute coronary syndrome in terms of chest pain, electrocardiogram changes, and an increase in troponins, and is considered to be a significant cause of myocardial infarction. Coronary angiography is needed to confirm the diagnosis, and subsequent repair should be pursued when needed. We describe a case of SCAD in a 72-year-old female treated using the cutting balloon angioplasty technique to create communication between the true and false lumens.

Categories: Cardiology

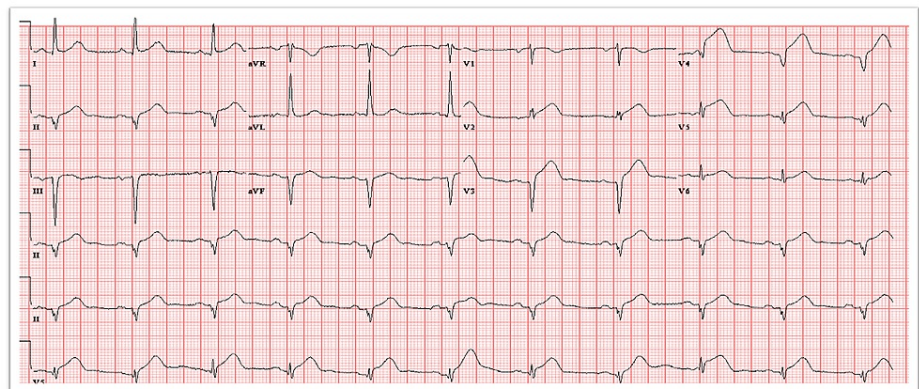
Keywords: spontaneous coronary artery dissection, scad, cutting balloon, endovascular angioplasty

Introduction

Spontaneous coronary artery dissection (SCAD) is a rare but serious condition that requires immediate attention. SCAD is an uncommon and underdiagnosed condition. It is a condition of a younger patient group and predominant in women [1,2]. It has a similar presentation to acute coronary syndrome (ACS) in terms of chest pain, electrocardiogram changes, and an increase in troponins, and is considered to be a significant cause of myocardial infarction. Coronary angiography is needed to confirm the diagnosis, and subsequent repair should be pursued when needed. The estimated prevalence of SCAD in patients presenting with ACS ranges from 1.7 to 4% [3,4], and in women younger than 50 years of age and presenting with ACS, it ranges from 9 to 43% [4-6]. Once the diagnosis is confirmed, management is often determined by the angiographic patency of the coronary artery. Options for therapy include conservative management with no intervention, coronary angioplasty, or coronary stenting. However, coronary imaging could establish the diagnosis and etiology. Therefore, the current recommendation is to refrain from coronary stenting, especially if the coronary flow is preserved. In this case, we present a patient with ACS who was found with coronary artery dissection and treated with cutting balloon angioplasty alone. To confirm the patency of the coronary artery, computed tomography angiogram was done a few weeks later, which showed patency of the vessel.

Case Presentation

A 72-year-old female with a medical history of hypertension, paroxysmal atrial fibrillation, type B thoracic aortic dissection status, post-percutaneous endovascular repair, stenting gastroepiploic artery aneurysm status post coil embolization, and mitral valve prolapse presented with chest pain. She described the chest pain as heavy and centrally located. The chest pain had progressed in severity by the time she was seen in the emergency department. ECG showed diffuse ST-segment elevation (Figure 1).



Review began 02/23/2021

Review ended 03/01/2021

Published 03/04/2021

© Copyright 2021

Zghouzi et al. This is an open access article distributed under the terms of the Creative Commons Attribution License CC-BY 4.0., which permits unrestricted use, distribution, and reproduction in any medium, provided the original author and source are credited.

How to cite this article

Zghouzi M, Moussa Pacha H, Sattar Y, et al. (March 04, 2021) Successful Treatment of Spontaneous Coronary Artery Dissection With Cutting Balloon Angioplasty. Cureus 13(3): e13706. DOI 10.7759/cureus.13706

FIGURE 1: ECG showing diffuse ST-segment elevation in leads V1-V5.

ECG, electrocardiogram

Bedside ECG was performed, showing an ejection fraction of 25%, severely hypokinetic anterior wall, and an akinetic apical septum, apex, and inferior wall. Laboratory investigation demonstrated a troponin level of 1 ng/mL.

The patient was taken emergently to the cardiac catheterization laboratory. Radial access and a 5-Fr tiger catheter were used. Complete occlusion of the mid-section of the left anterior descending (LAD) artery and Thrombolysis in Myocardial Infarction (TIMI) flow score of 0-1 due to spontaneous coronary artery dissection (Figure 2A) were noted. A 0.014-Fr Fielder XT coronary guidewire was advanced across the dissection planes, and the mid-LAD high-grade stenosis was achieved without difficulty. Although the initial plan was to stent the mid-LAD stenotic segment, as the lesion was not atherosclerotic, a decision to perform atherectomy balloon angioplasty of the segment using the 3.0 × 20 mm “cutting balloon” was made (Boston Scientific, Marlborough, MA, USA) (Figure 2B). Cutting balloon angioplasty created communication between the true and false lumens and restored the distal coronary flow (Figure 2C).

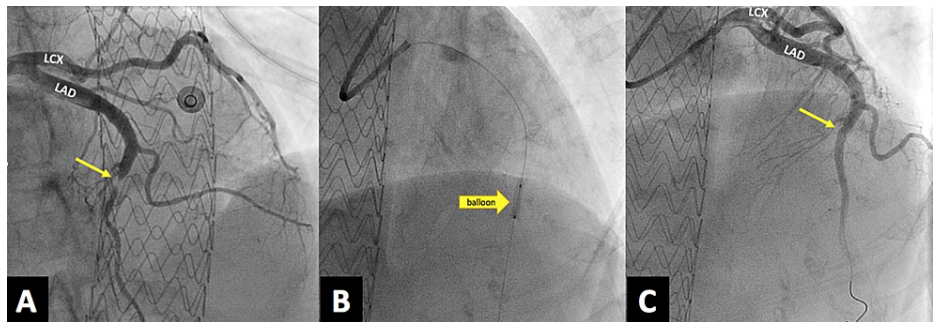


FIGURE 2: (A) Complete occlusion of the mid-section of the LAD artery and a TIMI flow score of 0-1 due to SCAD (arrow). (B) Coronary angiography showing 2.5-mm cutting balloon dilated in the proximal and distal segments of LAD artery (arrow). (C) Coronary angiography showing coronary flow restored to TIMI flow 3 after ballooning (arrow).

LAD, left anterior descending; TIMI, Thrombolysis in Myocardial Infarction; SCAD, spontaneous coronary artery dissection

After the procedure, the TIMI flow score was restored to 3. The procedure was uncomplicated, and the patient was discharged in good condition on warfarin and clopidogrel, given her history of paroxysmal atrial fibrillation.

A four-week follow-up coronary computed tomography was performed, showing a normal course and caliber of the LAD artery giving rise to two diagonal branches. Furthermore, the vessel was fully opacified throughout without luminal narrowing, stenosis, or evidence of dissection (Figure 3).

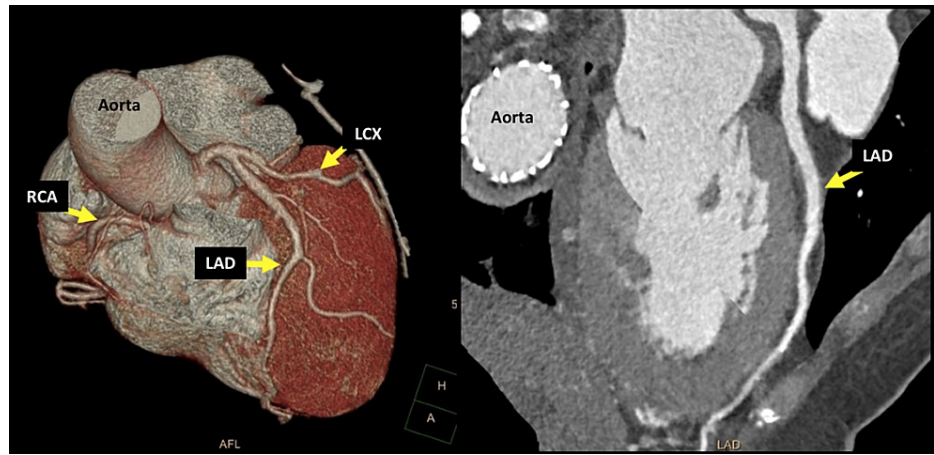


FIGURE 3: CTA showing ordinary course and caliber of LAD artery fully opacified without luminal narrowing or stenosis or evidence of dissection.

CTA, computed tomography angiography; LAD, left anterior descending; LCX, left circumflex artery; RCA, right coronary artery

Discussion

SCAD is defined as a spontaneous separation of the coronary artery wall that is not iatrogenic or related to trauma [2]. The first reported case of SCAD was in 1931 in middle-aged women.

Usually, patients present with an ACS spectrum such as unstable angina, non-ST elevation myocardial infarction, ST-elevation myocardial infarction, or sudden cardiac death [1]. The etiology is nonatherosclerotic and associated with clinical features such as fibromuscular dysplasia, pregnancy or postpartum state, connective tissue disorders, systemic inflammatory disease, and coronary artery spasm. Precipitators usually include exertion or emotional stress [1,2]. Many SCAD patients have a low pre-test probability of coronary artery disease, potentially missing the diagnosis or delayed intervention.

Coronary angiography is the golden standard for diagnosing SCAD. Furthermore, intracoronary imaging made the diagnosis of SCAD easy in patients presenting with ACS. This condition is usually sub-categorized into three types: type 1 (contrast staining delineating multiple lumens), type 2 (diffuse smooth narrowing), and type 3 (similar to atherosclerosis), with type 2 being the most common. The use of intracoronary in the form of optical coherence tomography and intravascular ultrasound can help diagnose type 2 and type 3 ACS [2,7].

The management of acute SCAD depends on the affected vessel's distal flow, clinical, and hemodynamic stability. Percutaneous coronary intervention (PCI) is often challenging and is associated with a high failure rate, even when distal coronary perfusion is preserved [8]. Medical management is reserved for clinically stable patients with a good distal coronary flow (TIMI score: 2-3) [8]. When hemodynamic stability is not achieved or in the case of failed medical management, PCI or coronary artery bypass grafting is indicated. There are several cases reported in the literature where scoring/cutting balloon angioplasty is used to treat SCAD, either as an initial treatment or when stenting failed to restore flow to the affected artery (Table 1).

There are scant data concerning the ideal medical therapy for acute SCAD. Aspirin is given to most patients, regardless of their atherosclerotic disease status. Clopidogrel and heparin are reserved for clinically appropriate situations. Beta-blockers play an important role in reducing arterial shear stress and ventricular arrhythmia and improving survival [2,9]. Angiotensin-converting enzyme inhibitors treatment is reserved for patients with left ventricular dysfunction. Treatment with nitrates or calcium channel blockers is reasonable in the presence of chest pain, which is likely related to dissection or coronary spasm.

Long-term survival in acute SCAD settings is excellent, but the risk of recurrence and myocardial infarction is high in this patient population. [1] Daily low-dose aspirin is recommended for all patients, but dual antiplatelet therapy is reserved for patients with PCI.

Author	Year	Age	Sex	Location	Treatment	Imaging follow-up
Terzian et al. [10]	2019	34	F	LAD	Scoring balloon angioplasty	Coronary angiogram at 9 months
Kaya et al. [11]	2019	46	F	LAD	Cutting balloon angioplasty	Coronary CTA at 1 and 6 months
Sharma et al. [12]	2019	53	F	RCA	Cutting balloon angioplasty	NA
Main et al. [13]	2019	62	F	Large diagonal branch	Cutting balloon angioplasty	ECG in 6 weeks
Bresson et al. [14]	2019	36	F	Proximal LAD	Stenting and cutting balloon angioplasty	NA
McGrath et al. [15]	2018	51	F	LM, LAD, LCX	Stenting and cutting balloon angioplasty	NA
Noguchi et al. [16]	2018	42	M	LAD, LCX	Cutting balloon angioplasty and stenting	Coronary angiogram at 6 months
Ito et al. [17]	2017	46	F	LAD	Cutting balloon angioplasty	Coronary CTA at 3 months
Alkhoul et al. [18]	2016	50	F	LAD	Cutting balloon angioplasty and stenting	NA
Yumoto et al. [19]	2014	47	F	LAD	Cutting balloon angioplasty	Coronary angiogram at 6 months
Uema et al. [20]	2013	42	F	LAD	Cutting balloon angioplasty	NA

TABLE 1: Previous case reports in the literature describing cutting/scoring balloon angioplasty in SCAD treatment.

LAD, left anterior descending; CTA, computed tomography angiography; RCA, right coronary artery; ECG, electrocardiogram; LM, left main; LCX, left circumflex artery; SCAD, spontaneous coronary artery dissection

Conclusions

Balloon angioplasty using a cutting balloon for patients presenting with SCAD and TIMI score 0 flow can offer immediate and long-term flow patency of a coronary artery with no requirement for coronary stenting.

Additional Information

Disclosures

Human subjects: Consent was obtained or waived by all participants in this study. **Conflicts of interest:** In compliance with the ICMJE uniform disclosure form, all authors declare the following: **Payment/services info:** All authors have declared that no financial support was received from any organization for the submitted work. **Financial relationships:** All authors have declared that they have no financial relationships at present or within the previous three years with any organizations that might have an interest in the submitted work. **Other relationships:** All authors have declared that there are no other relationships or activities that could appear to have influenced the submitted work.

References

1. Tweet MS, Hayes SN, Pitta SR, et al.: Clinical features, management, and prognosis of spontaneous coronary artery dissection. *Circulation*. 2012, 126:579-588. [10.1161/CIRCULATIONAHA.112.105718](https://doi.org/10.1161/CIRCULATIONAHA.112.105718)
2. Saw J, Mancini GB, Humphries KH: Contemporary review on spontaneous coronary artery dissection. *J Am Coll Cardiol*. 2016, 68:297-312. [10.1016/j.jacc.2016.05.034](https://doi.org/10.1016/j.jacc.2016.05.034)
3. Nishiguchi T, Tanaka A, Ozaki Y, et al.: Prevalence of spontaneous coronary artery dissection in patients with acute coronary syndrome. *Eur Heart J Acute Cardiovasc Care*. 2016, 5:263-270. [10.1177/2048872613504310](https://doi.org/10.1177/2048872613504310)
4. Rashid HN, Wong DT, Wijesekera H, et al.: Incidence and characterisation of spontaneous coronary artery dissection as a cause of acute coronary syndrome--a single-centre Australian experience. *Int J Cardiol*. 2016, 202:336-338. [10.1016/j.ijcard.2015.09.072](https://doi.org/10.1016/j.ijcard.2015.09.072)
5. Elkayam U, Jalnapurkar S, Barakkat MN, Khatri N, Kealey AJ, Mehra A, Roth A: Pregnancy-associated acute

- myocardial infarction: a review of contemporary experience in 150 cases between 2006 and 2011. *Circulation*. 2014, 129:1695-1702. [10.1161/CIRCULATIONAHA.113.002054](https://doi.org/10.1161/CIRCULATIONAHA.113.002054)
6. Nakashima T, Noguchi T, Haruta S, et al.: Prognostic impact of spontaneous coronary artery dissection in young female patients with acute myocardial infarction: a report from the Angina Pectoris-Myocardial Infarction Multicenter Investigators in Japan. *Int J Cardiol*. 2016, 207:341-348. [10.1016/j.ijcard.2016.01.188](https://doi.org/10.1016/j.ijcard.2016.01.188)
 7. Saw J: Coronary angiogram classification of spontaneous coronary artery dissection. *Catheter Cardiovasc Interv*. 2014, 84:1115-1122. [10.1002/ccd.25293](https://doi.org/10.1002/ccd.25293)
 8. Tweet MS, Eleid MF, Best PJ, et al.: Spontaneous coronary artery dissection: revascularization versus conservative therapy. *Circ Cardiovasc Interv*. 2014, 7:777-786. [10.1161/CIRCINTERVENTIONS.114.001659](https://doi.org/10.1161/CIRCINTERVENTIONS.114.001659)
 9. Amsterdam EA, Wenger NK, Brindis RG, et al.: 2014 AHA/ACC guideline for the management of patients with non-ST-elevation acute coronary syndromes: a report of the American College of Cardiology/American Heart Association Task Force on Practice Guidelines. *J Am Coll Cardiol*. 2014, 64:139-228. [10.1016/j.jacc.2014.09.017](https://doi.org/10.1016/j.jacc.2014.09.017)
 10. Terzian Z, Demian H, Karrillon GJ, Aubry P: Fenestration of a spontaneous coronary hematoma with life-threatening dissection: a case of recurrent and multivessel spontaneous coronary artery dissections in a young female [Article in French]. *Ann Cardiol Angeiol (Paris)*. 2019, 68:382-388. [10.1016/j.ancard.2019.08.009](https://doi.org/10.1016/j.ancard.2019.08.009)
 11. Kaya E, Iwata H, Miyazaki S, et al.: Successful coronary flow restoration by stent-free strategy using the pull-back method of cutting balloon in spontaneous coronary artery dissection. *CJC Open*. 2019, 1:213-215. [10.1016/j.cjco.2019.05.008](https://doi.org/10.1016/j.cjco.2019.05.008)
 12. Sharma H, Vetrugno V, Khan SQ: Successful treatment of a spontaneous right coronary artery dissection with a 4-mm diameter cutting balloon: a case report. *Eur Heart J Case Rep*. 2019, 3:1-6. [10.1093/ehjcr/ytz212](https://doi.org/10.1093/ehjcr/ytz212)
 13. Main A, Lombardi WL, Saw J: Cutting balloon angioplasty for treatment of spontaneous coronary artery dissection: case report, literature review, and recommended technical approaches. *Cardiovasc Diagn Ther*. 2019, 9:50-54. [10.21037/cdt.2018.10.11](https://doi.org/10.21037/cdt.2018.10.11)
 14. Bresson D, Calcaianu M, Lawson B, Jacquemin L: Coronary artery fenestration as rescue management of intramural haematoma with luminal compression. *Catheter Cardiovasc Interv*. 2019, 94:17-19. [10.1002/ccd.28186](https://doi.org/10.1002/ccd.28186)
 15. McGrath BM, Vo MN: Novel use of cutting balloon to manage compressive subintimal hematoma during left main stenting in a patient with spontaneous coronary artery dissection. *Clin Case Rep*. 2018, 6:1291-1295. [10.1002/ccr5.1551](https://doi.org/10.1002/ccr5.1551)
 16. Noguchi M, Obunai K, Fukui Y, Okumura H, Watanabe H: Usefulness of cutting balloon angioplasty prior to stenting with intravascular ultrasound imaging guidance for spontaneous multi-vessel coronary artery dissection including the left main coronary artery. *Intern Med*. 2018, 57:1867-1871. [10.2169/internalmedicine.0177-17](https://doi.org/10.2169/internalmedicine.0177-17)
 17. Ito T, Shintani Y, Ichihashi T, Fujita H, Ohte N: Non-atherosclerotic spontaneous coronary artery dissection revascularized by intravascular ultrasonography-guided fenestration with cutting balloon angioplasty. *Cardiovasc Interv Ther*. 2017, 32:241-245. [10.1007/s12928-016-0397-x](https://doi.org/10.1007/s12928-016-0397-x)
 18. Alkhouli M, Cole M, Ling FS: Coronary artery fenestration prior to stenting in spontaneous coronary artery dissection. *Catheter Cardiovasc Interv*. 2016, 88:23-27. [10.1002/ccd.26161](https://doi.org/10.1002/ccd.26161)
 19. Yumoto K, Sasaki H, Aoki H, Kato K: Successful treatment of spontaneous coronary artery dissection with cutting balloon angioplasty as evaluated with optical coherence tomography. *JACC Cardiovasc Interv*. 2014, 7:817-819. [10.1016/j.jcin.2013.10.027](https://doi.org/10.1016/j.jcin.2013.10.027)
 20. Uema A, Araki M, Sonoda S, et al.: Successful coronary intervention for spontaneous coronary dissection in a patient with fibromuscular dysplasia. *J Cardiol Cases*. 2013, 8:158-160. [10.1016/j.jccase.2013.07.011](https://doi.org/10.1016/j.jccase.2013.07.011)