

35. Alloway KD, Rosenthal P, Burton H. Quantitative measurements of receptive field changes during antagonism of GABAergic transmission in primary somatosensory cortex of cats. *Exp Brain Res* 1989; 78(3):514–532.

## Supporting Data

Additional Supporting Information may be found in the online version of this article at the publisher's web-site.

# Magnetic Resonance-Guided Focused Ultrasound Thalamotomy for Focal Hand Dystonia: A Pilot Study

CME

Shiro Horisawa, MD,<sup>1</sup> Toshio Yamaguchi, PhD,<sup>2</sup> Keiichi Abe, PhD,<sup>1</sup> Hiroki Hori, PhD,<sup>2</sup> Atsushi Fukui, MD,<sup>1</sup> Mutsumi Iijima, MD,<sup>3</sup> Masatake Sumi, MD,<sup>1</sup> Kenichi Hodotsuka, MD,<sup>1</sup> Yoshiyuki Konishi, PhD,<sup>4</sup> Takakazu Kawamata, PhD,<sup>1</sup> and Takaomi Taira, PhD<sup>1\*</sup>

<sup>1</sup>Department of Neurosurgery, Neurological Institute, Tokyo Women's Medical University, Tokyo, Japan <sup>2</sup>Department of Radiology, Shinyurigaoka General Hospital, Kanagawa, Japan <sup>3</sup>Department of Neurology, Neurological Institute, Tokyo Women's Medical University, Tokyo, Japan <sup>4</sup>Faculty of Advanced Techno-Surgery, Institute of Advanced Biomedical Engineering & Science, Graduate School of Medicine, Tokyo, Japan

**ABSTRACT: Background:** The efficacy of magnetic resonance-guided focused ultrasound (MRgFUS) thalamotomy for the treatment of focal hand dystonia (FHD) is not well known.

This is an open access article under the terms of the Creative Commons Attribution License, which permits use, distribution and reproduction in any medium, provided the original work is properly cited.

\*Correspondence to: Dr. Takaomi Taira, Department of Neurosurgery, Neurological Institute, Tokyo Women's Medical University, Shinjuku-ku, Kawada-cho, 8-1, 162-8666, Tokyo, Japan; E-mail: ttaira@twmu.ac.jp

**Relevant conflicts of interest/financial disclosures:** The study protocol and deidentified participant data are available from the corresponding author on reasonable request.

**Funding Agencies:** None

**Received:** 5 January 2021; **Revised:** 6 March 2021; **Accepted:** 26 March 2021

Published online 29 May 2021 in Wiley Online Library (wileyonlinelibrary.com). DOI: 10.1002/mds.28613

**Objective:** We aimed to prospectively investigate the efficacy of MRgFUS thalamotomy for the treatment of FHD.

**Methods:** We performed MRgFUS thalamotomy of the ventro-oral (Vo) nucleus in 10 patients with FHD. We evaluated the scores of the Writer's Cramp Rating Scale (WCRS, 0–30; higher scores indicating greater severity), Tubiana Musician's Dystonia Scale (TMDS, 0–5; lower scores indicating greater severity), and Arm Dystonia Disability Scale (ADDS, 0%–100%; lower scores indicating greater disability) at baseline and 3 and 12 months post-treatment.

**Results:** WCRS, TMDS, and ADDS scores significantly improved from  $6.3 \pm 2.7$ ,  $1.4 \pm 0.5$ , and  $58.7\% \pm 14.3\%$  at baseline to  $1.6 \pm 3.1$  ( $P = 0.011$ ),  $5.0 \pm 0$  ( $P = 0.0001$ ), and  $81.6\% \pm 22.9\%$  ( $P = 0.0229$ ) at 12 months, respectively. There was one prolonged case of dysarthria at 12 months.

**Conclusion:** We show that MRgFUS Vo-thalamotomy significantly improved FHD. © 2021 The Authors. *Movement Disorders* published by Wiley Periodicals LLC on behalf of International Parkinson and Movement Disorder Society

**Key Words:** magnetic resonance-guided focused ultrasound thalamotomy; focal hand dystonia; ventro-oral nucleus

## Introduction

Focal hand dystonia (FHD) is an idiopathic, adult-onset disorder in most cases and manifests only while performing specific tasks.<sup>1</sup> Writer's cramp and musician's dystonia are the most well-known types of FHD, both of which cause dystonic muscle contractions in hand muscles only while writing or playing musical instruments. The prevalence of this condition is 1.2–1.5 per 100,000 persons.<sup>2–4</sup> In some specific populations, such as professional musicians or athletes, the prevalence is much higher than in the general population; approximately 1%–2% of professional musicians are affected by FHD.<sup>5,6</sup>

The ventro-oral (Vo) nucleus is one of the main output terminators from the basal ganglia, and lesioning or stimulation of this nucleus has been reported to improve FHD.<sup>7,8</sup> Magnetic resonance (MR)-guided focused ultrasound (MRgFUS) thalamotomy, which allows intracranial focal lesioning without an incision, has been reported to be an effective and less invasive procedure for the treatment of tremor and Parkinson's disease.<sup>9,10</sup> MRgFUS thalamotomy produces thermal lesions, similarly to radiofrequency thalamotomy, and is expected to have similar effects to radiofrequency Vo-thalamotomy on FHD. However, its efficacy for the treatment of FHD has been investigated in only two patients thus far.<sup>11,12</sup> Therefore, we prospectively

investigated the efficacy of MRgFUS Vo-thalamotomy in 10 patients with FHD.

## Patients and Methods

### Study Design

This was a prospective, open-label, non-controlled pilot study performed at the Tokyo Women's Medical University, Shinjuku, Tokyo, Japan, except for the FUS procedures, which were conducted at the Shin-Yurigaoka General Hospital, Kawasaki, Yokohama, Japan. The protocol was reviewed and approved by the University Hospital Medical Information Network Center and the Ethics Committees of both participating hospitals. All patients provided written informed consent before inclusion in this study.

### Patients

From April 2017 through May 2018, we enrolled 10 patients with FHD. Severe FHD was defined as a score of <3 on the Tubiana Musician's Dystonia Scale (TMDS) or > 8 on the Writer's Cramp Rating Scale (WCRS). The diagnosis of FHD was confirmed by a neurologist or a neurosurgeon specializing in movement disorders (T.T., S.H., M.I.). The exclusion criteria included the following: history of stereotactic surgery or cerebral stroke, diagnosis of an unstable cardiac or psychiatric disease, coagulopathy, skull density ratio of  $\leq 0.3$ , and cognitive impairment (a score of >24 [out of 30] on the Mini-Mental State Examination).

### Evaluations

The primary clinical endpoint was defined as a change in the WCRS score (0–30, with higher scores indicating greater severity) in writer's cramp or the TMDS score (1–5, with lower scores indicating greater severity) in musician's dystonia. The secondary clinical endpoint was the change in the score of the Arm Dystonia Disability Scale (ADDS; 0%–100%, with lower scores indicating greater disability).<sup>13</sup> Patients were assessed for these clinical endpoints and adverse events at baseline, 1 week, 1 month, 3 months, 6 months, and 12 months after treatment. Each assessment was videotaped. Adverse events were classified in relation to thalamotomy, stereotactic frame, sonication, and unrelated. Transient adverse events were defined as those resolving by the 12-month follow-up. Serious adverse events were those requiring hospital admission or prolonged hospitalization. Magnetic resonance imaging (MRI) was performed at baseline, 3 months, and 12 months after treatment.

### FUS Procedure

The stereotactic coordinates of the Vo nucleus were 1.0–1.5 mm posterior, 14–15 mm lateral, and 1.5–2.5 mm superior to the mid-commissural point, which corresponds to the junction between the ventro-oral anterior and posterior of the thalamus according to the stereotactic atlas of Schaltenbrand and Wahren.<sup>14</sup> The procedure was performed with 3-T MRI (GE Healthcare Technologies, Waukesha, WI) and ExAblate Neuro systems (Insightec, Tirat Carmel, Israel). At least two sonications above 55°C were administered to the target. Clinical assessment for dystonic symptoms and adverse events was performed after each sonication. After the procedure, the stereotactic frame was removed and the patients were discharged the following day.

### Statistical Analysis

The data did not follow a normal distribution. Friedman's test was used to determine the primary (change in TMDS and WCRS scores) and secondary clinical endpoints (change in ADDS score) across six study visits: at baseline, 1 week, 1 month, 3 months, 6 months, and 12 months after treatment. Wilcoxon's signed rank test was used to compare the primary and secondary endpoints between baseline and 12 months. Bonferroni's correction was used for multiple comparisons. Statistical analysis was performed using the JMP statistical package (version 13.0.0; SAS Institute, Cary, NC). All statistical tests were two tailed, and  $P < 0.05$  was considered to be statistically significant.

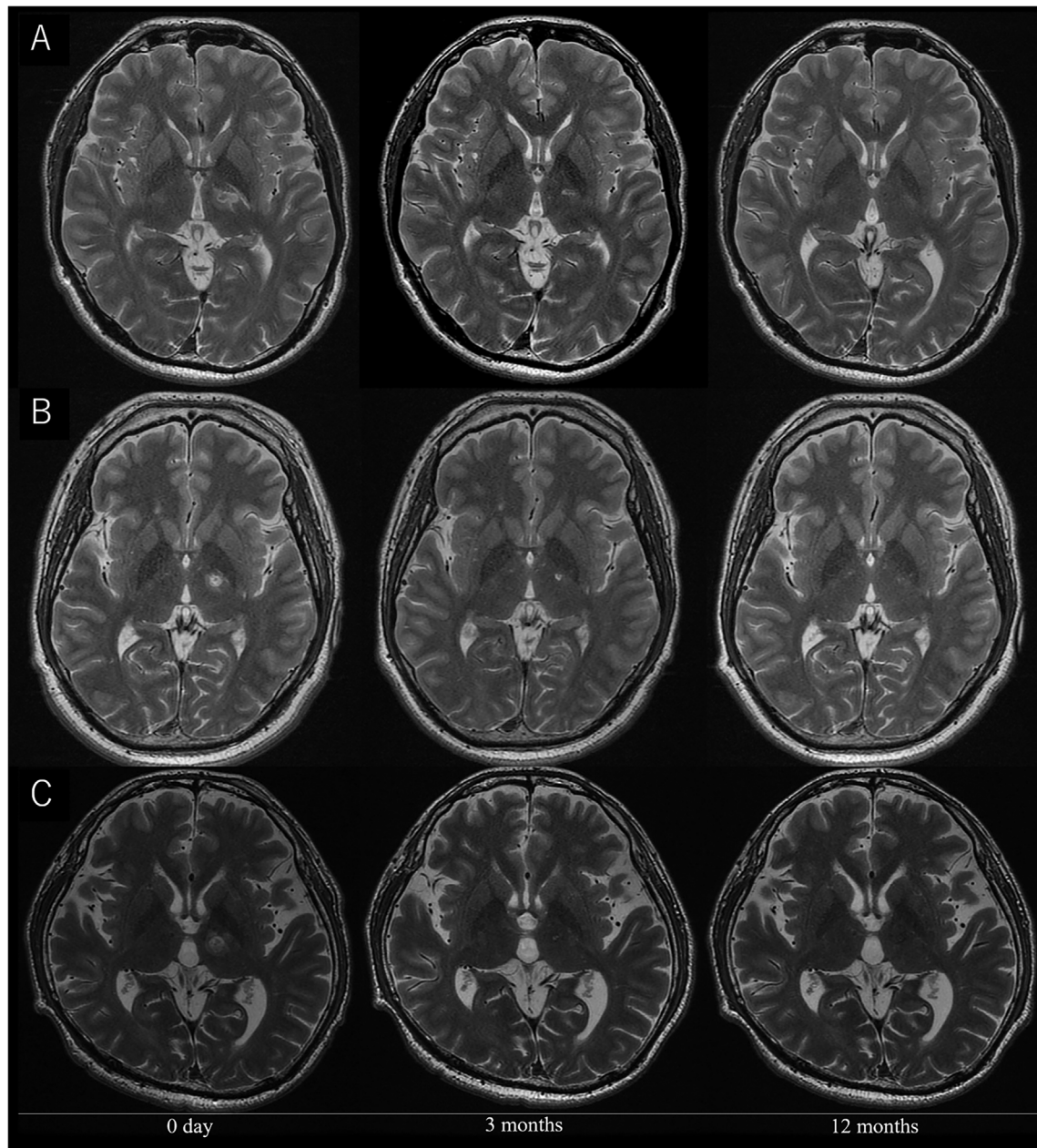
## Results

### Patients

We enrolled 10 patients with severe FHD: five with musician's dystonia (four were professional players), three with writer's cramp, and two patients with professional dart-related FHD. All five patients with musician's dystonia and one patient with dart-related FHD also manifested writer's cramp. One patient had isolated dart-related FHD. This patient's dystonic symptoms were severe; thus, we decided to enroll this patient in this study. The patients' baseline characteristics are shown in Table S1. Representative postoperative MRI scans are shown in Figure 1.

### Clinical Effects of MRgFUS

The group and individual scores of each clinical assessment are described in Table S1 and Figure 2. In nine patients with writer's cramp, the WCRS score was reduced by 71.4% (range: 0%–100%) at 12 months ( $6.1 \pm 2.9$  at baseline vs.  $1.8 \pm 3.3$  at 12 months,  $P = 0.011$ ). In five patients with musician's dystonia, the TMDS score was significantly improved from  $1.4 \pm 0.5$  (range: 1–2) at baseline to  $5.0 \pm 0$  (range: 5) at



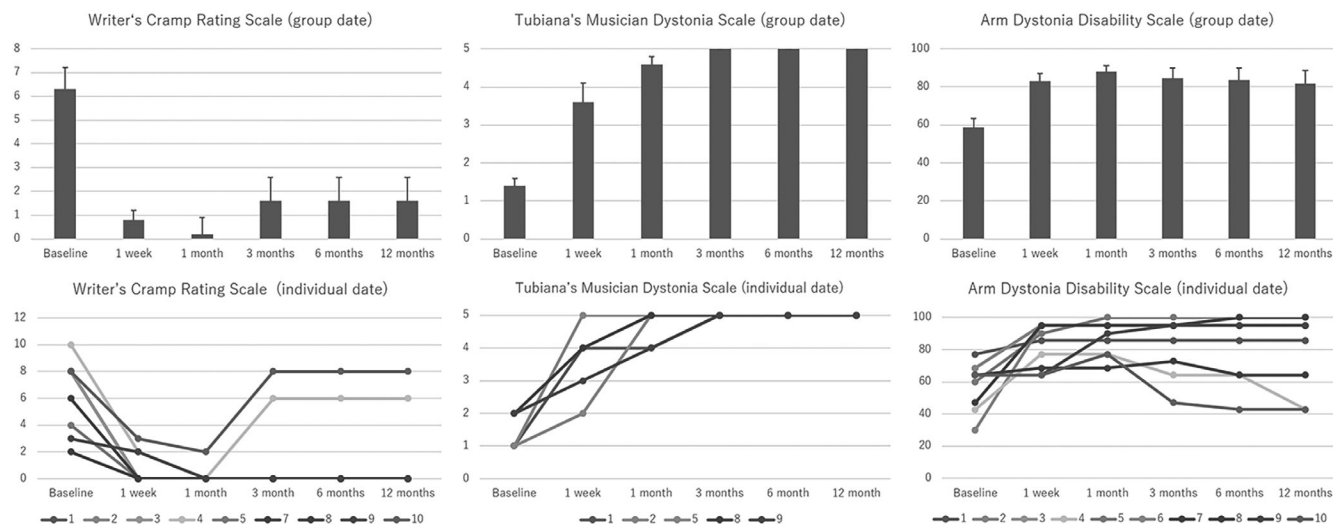
**FIG. 1.** Representative magnetic resonance images obtained before and after treatment. The lesion unexpectedly encroached on the posterior limb of the internal capsule (case 4: **A**, case 7: **B**). Case 9 (**C**) showing the precise lesion on the intended target.

12 months ( $P < 0.0001$ ). All patients were evaluated by the ADDS, and the score significantly improved from  $58.7\% \pm 14.3\%$  (range: 30.0%–77.1%) at baseline to  $81.6\% \pm 22.9\%$  (range: 42.9%–100%) at 12 months ( $P = 0.025$ ). Significant improvements were identified in the WCRS ( $P < 0.001$ ), TMDS ( $P = 0.001$ ), and ADDS ( $P = 0.001$ ) scores. Five patients (cases 2, 6, 7, 8, and 9) were not working at baseline due to the symptoms, and four (cases 2, 6, 8, and 9) of them had returned to work by the 12-month follow-up. One patient (case 7) remained unemployed with poor treatment results. The clinical course of representative cases in writer's cramp (case 3) and musician's dystonia (case 2) are shown in

videos S1 and S2. Symptom recurrence was noted in three patients (cases 4, 7, and 10), including the two with facial palsy, at the 3-month follow-up. The summary of the sonication can be found in Table S2.

### Adverse Events

All adverse events related to thalamotomy, stereotactic frame, and sonication were transient (Table SS3). There was one serious adverse event, a suicide attempt by drug overdose, which was not related to thalamotomy, stereotactic frame, and sonication. The patient recovered without any deficit after a 5-day hospitalization (case 7). The



**FIG. 2.** Changes in primary and secondary clinical endpoints during the study period. Primary clinical endpoints were the scores of the Writer's Cramp Rating Scale (WCRS; ranging from 0 to 30, with higher scores indicating greater severity) and Tubiana Musician's Dystonia Scale (TMDS; ranging from 1 to 5, with lower scores indicating greater severity), which evaluate dystonia severity. Secondary clinical endpoint was the score of the Arm Dystonia Disability Scale (ADDS; ranging from 0% to 100%, with lower scores indicating greater disability) to evaluate dystonia disability. Significant improvements were observed in the WCRS, TMDS, and ADDS scores throughout the study period in group data (upper row). Individual data are shown in the lower row. [Color figure can be viewed at [wileyonlinelibrary.com](http://wileyonlinelibrary.com)]

suicide attempt was made 2 months after the treatment, which led to the discovery that he intentionally concealed the history of repetitive suicide attempts and depression before enrollment in this trial. Three patients showed transient dysarthria (cases 5, 7, and 10), and dysarthria persisted at 12 months in one patient (case 4). Two patients had transient facial palsy. In both cases (cases 4 and 7), facial palsy developed by accidental lesion encroachment on the internal capsule (Fig. 1A,B) and resolved spontaneously within 3 months.

## Discussion

This open-label pilot study of 10 patients showed that unilateral MRgFUS Vo-thalamotomy significantly improved the symptoms of FHD, as measured by the WCRS, TMDS, and ADDS. No serious adverse events were observed, except for the suicide attempt in one patient. The only adverse event at 12 months was mild dysarthria in one patient.

Thalamotomy using FUS has been reported mainly in the treatment of tremors associated with essential tremor and Parkinson's disease.<sup>9,10,15</sup> Only two patients with FHD have been reported to be treated by FUS thalamotomy.<sup>11,12</sup> We have already reported several studies describing the efficacy of Vo-thalamotomy using radiofrequency and gamma knife.<sup>16-20</sup> In this study, the WCRS, TMDS, and ADDS scores significantly improved at 12 months compared to those at baseline. In our previous study investigating the results of radiofrequency Vo-thalamotomy in 171 patients, the task-specific FHD scores (1–5, with lower scores indicating greater severity), a scale that is almost the same as

TMDS, before surgery and at the last available follow-up (mean 47.36 months) were  $1.72 \pm 0.57$  and  $4.39 \pm 1.07$ , respectively, which are similar to the results of the present study.<sup>20</sup> In a limited number of cases, Vo-deep brain stimulation is also reported to be effective for hand dystonia.<sup>21,22</sup>

In this study, three patients experienced recurrence of the dystonic symptoms at 3 months after treatment. In radiofrequency Vo-thalamotomy, recurrence can also develop within 3 months after surgery in about 10% of patients with FHD, which results from insufficient or incorrect ablation over the entire Vo nucleus.<sup>20</sup> Until the edema surrounding the thermocoagulation, which covers the entire Vo nucleus, disappears, symptomatic improvements may persist. The postoperative MRI scans of patients with recurring symptoms showed that the lesion was situated laterally from where we intended, suggesting that misalignment of the target was a possible cause of the recurrence. Compared to the MRI scan on the day of the treatment in the successful case 9 (Fig. 1B), the recurrent case 4 (Fig. 1A) showed that the volume of the intrathalamic lesion volume was small. Lesion encroachment on the internal capsule (cases 4, 7, and 10) may be related to poor outcomes and adverse events. In the time course of ADDS, cases 4 and 7 showed at 12 months a score similar to that at baseline after initial improvement. Case 10 showed a worsening score at 12 months than that at baseline due to disease progression. Case 7 made a suicide attempt by drug overdose 2 months after the treatment. Whether the Vo nucleus lesion had an impact on his psychological deterioration is uncertain. However, the unsatisfactory result may have attributed to the worsening of his psychological condition, ultimately leading to the suicide attempt.

Despite the limitations, including a short follow-up period and small sample size, this pilot study suggests that FUS Vo-thalamotomy may be an alternative treatment option for patients with FHD. A randomized controlled study with a larger sample size and a longer follow-up period is warranted to elucidate the efficacy and safety of MRgFUS Vo-thalamotomy for FHD. ■

**Acknowledgments:** We thank Kaoru Shimizu from the Intelligent Clinical Research and Innovation Center at the Tokyo Women's Medical University for her invaluable assistance in the conduct of this study.

## References

1. Stahl CM, Frucht SJ. Focal task specific dystonia: a review and update. *J Neurol* 2017;264(7):1536–1541.
2. Williams L, McGovern E, Kimmich O, et al. Epidemiological, clinical and genetic aspects of adult onset isolated focal dystonia in Ireland. *Eur J Neurol* 2017;24(1):73–81.
3. Matsumoto S, Nishimura M, Shibasaki H, Kaji R. Epidemiology of primary dystonias in Japan: comparison with Western countries. *Mov Disord* 2003;18(10):1196–1198.
4. Group ESoDiEC. A prevalence study of primary dystonia in eight European countries. *J Neurol* 2000;247(10):787–792.
5. Jabusch H-C, Altenmüller E. Epidemiology, phenomenology and therapy of musician's cramp. *Music, Motor Control and the Brain* 2006;265–282. <https://doi.org/10.1093/acprof:oso/9780199298723.003.0017>.
6. Butler K, Rosenkranz K. Focal hand dystonia affecting musicians. Part I: an overview of epidemiology, pathophysiology and medical treatments. *Br J Hand Ther* 2006;11(3):72–78.
7. Doshi PK, Ramdasi RV, Karkera B, Kadlas DB. Surgical interventions for task-specific dystonia (writer's dystonia). *Ann Indian Acad Neurol* 2017;20(3):324–327.
8. Goto S, Tsuiki H, Soyama N, et al. Stereotactic selective Vo-complex thalamotomy in a patient with dystonic writer's cramp. *Neurology* 1997;49(4):1173–1174.
9. Martínez-Fernández R, Rodríguez-Rojas R, Del Álamo M, et al. Focused ultrasound subthalamotomy in patients with asymmetric Parkinson's disease: a pilot study. *Lancet Neurol* 2018;17(1):54–63.
10. Elias WJ, Lipsman N, Ondo WG, et al. A randomized trial of focused ultrasound thalamotomy for essential tremor. *N Engl J Med* 2016;375(8):730–739.
11. Horisawa S, Yamaguchi T, Abe K, et al. A single case of MRI-guided focused ultrasound ventro-oral thalamotomy for musician's dystonia. *J Neurosurg* 2018;131(2):384–386.
12. Fasano A, Llinas M, Munhoz RP, Hlasny E, Kucharczyk W, Lozano AM. MRI-guided focused ultrasound thalamotomy in non-ET tremor syndromes. *Neurology* 2017;89(8):771–775.
13. Fahn SJQond. Assessment of the primary dystonias. 1989: 241–270.
14. Schaltenbrand G. Atlas for stereotaxy of the human brain. Georg Thieme. Stuttgart, Germany: Georg Thieme Verlag KG; 1977.
15. Zaaroor M, Sinai A, Goldsher D, Eran A, Nassar M, Schlesinger I. Magnetic resonance-guided focused ultrasound thalamotomy for tremor: a report of 30 Parkinson's disease and essential tremor cases. *J Neurosurg* 2018;128(1):202–210.
16. Horisawa S, Kohara K, Kawamata T, Taira T. Successful treatment of task-specific lower extremity dystonia by ventro-oral thalamotomy. *Mov Disord* 2018;33(2):338–339.
17. Horisawa S, Sumi M, Akagawa H, Kawamata T, Taira T. Thalamotomy for paroxysmal kinesigenic dyskinesias in a multiplex family. *Eur J Neurol* 2017;24(10):e71–e72.
18. Horisawa S, Tamura N, Hayashi M, et al. Gamma knife ventro-oral thalamotomy for musician's dystonia. *Mov Disord* 2017;32(1):89–90.

19. Horisawa S, Taira T, Goto S, Ochiai T, Nakajima T. Long-term improvement of musician's dystonia after stereotactic ventro-oral thalamotomy. *Ann Neurol* 2013;74(5):648–654.
20. Horisawa S, Ochiai T, Goto S, et al. Safety and long-term efficacy of ventro-oral thalamotomy for focal hand dystonia: a retrospective study of 171 patients. *Neurology* 2019;92(4):e371–e377.
21. Mongardi L, Rispoli V, Scerrati A, et al. Deep brain stimulation of the ventralis oralis anterior thalamic nucleus is effective for dystonic tremor. *Parkinsonism Relat Disord* 2020;81:8–11.
22. Fukaya C, Katayama Y, Kano T, et al. Thalamic deep brain stimulation for writer's cramp. *J Neurosurg* 2007;107(5):977–982.

## Supporting Data

Additional Supporting Information may be found in the online version of this article at the publisher's web-site.

## Scoring Algorithm-Based Genomic Testing in Dystonia: A Prospective Validation Study

Michael Zech, MD,<sup>1,2\*</sup> Robert Jech, MD, PhD,<sup>3</sup> ID  
 Sylvia Boesch, MD,<sup>4</sup> Matej Škorvánek, MD, PhD,<sup>5,6</sup>  
 Ján Necpál, MD,<sup>7</sup> ID Jana Švantnerová, MD,<sup>8</sup>  
 Matias Wagner, MD,<sup>1,2</sup> ID Ariane Sadr-Nabavi, PhD,<sup>9,10,11</sup>  
 Felix Distelmaier, MD,<sup>12</sup> Martin Krenn, MD, PhD,<sup>2,13</sup>  
 Tereza Serranová, MD, PhD,<sup>3</sup> ID  
 Irena Rektorová, MD, PhD,<sup>14</sup> Petra Havránková, MD, PhD,<sup>3</sup>

-----  
 This is an open access article under the terms of the Creative Commons Attribution-NonCommercial-NoDerivs License, which permits use and distribution in any medium, provided the original work is properly cited, the use is non-commercial and no modifications or adaptations are made.

**\*Correspondence to:** Dr. Michael Zech, Institute of Neurogenomics, Helmholtz Zentrum München. Deutsches Forschungszentrum für Gesundheit und Umwelt (GmbH), Ingolstädter Landstraße 1, 85764 Neuherberg, Germany; E-mail: michael.zech@mri.tum.de

#These authors contributed equally to this work.

**Relevant conflicts of interest/financial disclosures:** Nothing to report.

**Funding agencies:** This study was funded by in-house institutional funding from Technische Universität München, Munich, Germany; Helmholtz Zentrum München, Munich, Germany; Medizinische Universität Innsbruck, Innsbruck, Austria; and Charles University, Prague, Czech Republic (PROGRES Q27). This study was also funded by the Czech Ministry of Education under grant AZV: NV19-04-00233 and under the frame of EJP RD, the European Joint Programme on Rare Diseases (EJP RD COFUND-EJP N° 825575), as well as the Slovak Grant and Development Agency under contract APVV-18-0547 and the Operational Programme Integrated Infrastructure, funded by the ERDF under No. ITMS2014+: 313011V455.

**Received:** 6 November 2020; **Revised:** 22 February 2021; **Accepted:** 26 March 2021

**Published online 5 May 2021 in Wiley Online Library**  
 (wileyonlinelibrary.com). DOI: 10.1002/mds.28614