

Available online at [www.sciencedirect.com](http://www.sciencedirect.com)

ScienceDirect

journal homepage: [www.elsevier.com/locate/radcr](http://www.elsevier.com/locate/radcr)

## Case Report

# Skull vault hemangioma mimicking neoplastic lesion on [<sup>68</sup>Ga]Ga-PSMA-11 PET/CT in a patient with glioblastoma: A case report <sup>☆,☆☆</sup>

Aurélie Moreau<sup>a,†</sup>, Edouard Marie<sup>a,b,†</sup>, Alice Bonneville-Levard<sup>a,††</sup>, Alexandre Basle<sup>a</sup>, David Kryza<sup>b,c,\*</sup>

<sup>a</sup>Centre Léon Bérard, Lyon, France

<sup>b</sup>Hospices Civils de Lyon, Lyon, France

<sup>c</sup>UNIV Lyon - Université Claude Bernard Lyon 1, Villeurbanne, France

## ARTICLE INFO

## Article history:

Received 28 August 2020

Revised 1 October 2020

Accepted 2 October 2020

## Keywords:

[<sup>68</sup>Ga]Ga-PSMA-11 PET/CT

[<sup>18</sup>F]-F-DOPA PET/CT

Calvarial hemangioma

Glioblastoma

## ABSTRACT

We present the case of a 47-year-old woman treated by radiochemotherapy for a glioblastoma which underwent a [<sup>68</sup>Ga]Ga-PSMA-11-PET/CT to distinguish postradiation changes from an evolutionary process. This demonstrated a weak homogeneous uptake surrounding the lesion. There was a focal and moderate uptake of a pseudo lytic skull diploe lesion near to the glioblastoma, finally attributed to a calvaria hemangioma. Calvaria hemangiomas are less frequent than vertebral hemangiomas and may demonstrate a modest PSMA uptake that one should keep in mind so as not to misinterpret the examination in patients followed for glioblastomas.

© 2020 The Authors. Published by Elsevier Inc. on behalf of University of Washington.

This is an open access article under the CC BY-NC-ND license

(<http://creativecommons.org/licenses/by-nc-nd/4.0/>)

## Introduction

The [<sup>68</sup>Ga]Ga-PSMA-11 PET/CT holds an important and growing place in the management of patients followed for prostate

cancers. This examination tends to replace [<sup>18</sup>F]-Fluorocholine positron emission tomography/computed tomography (PET/CT) thanks to a better performance, particularly in the exploration of biological recurrences with low PSA levels [1–4]. PSMA is a transmembrane glycoprotein which is overex-

Abbreviations: [<sup>68</sup>Ga]Ga-PSMA-11, Glu-CO-Lys(Ahx)-[[<sup>68</sup>Ga]Ga-(HBED-CC)]; [<sup>18</sup>F]F-DOPA, [<sup>18</sup>F]F-dihydroxyphenylalanine; PET/CT, positron emission tomography/computed tomography; SUVmax, maximum standard uptake value; MIP, Maximum Intensity Projection; SVH, Skull Vault Hemangioma; MRI, Magnetic resonance imaging.

<sup>☆</sup> Competing interest: The authors declare that they have no conflict of interest.

<sup>☆☆</sup> Acknowledgments: This research did not receive any specific grant from funding agencies in the public, commercial, or not-for-profit sectors.

\* Corresponding author at: Department of Nuclear medicine (LUMEN), 15 rue Gabriel Sarrazin, 69373 Lyon cedex 08, France.

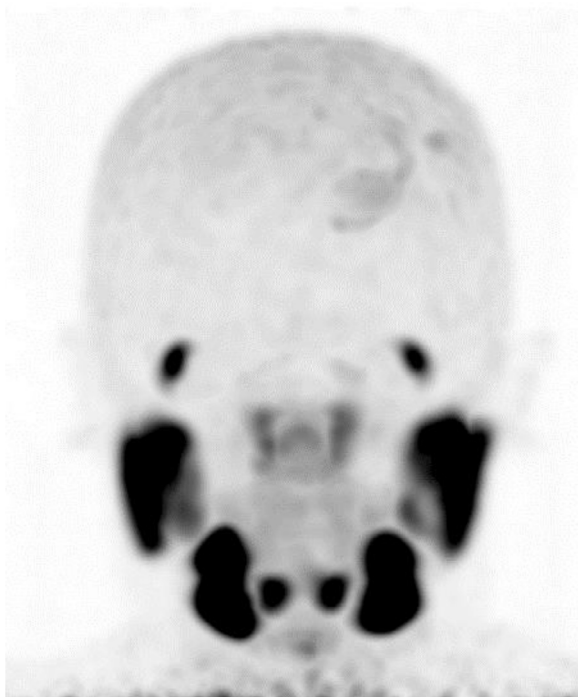E-mail address: [david.kryza@univ-lyon1.fr](mailto:david.kryza@univ-lyon1.fr) (D. Kryza).

<sup>†</sup> Department of Nuclear medicine, 15 rue Gabriel Sarrazin, 69373 Lyon cedex 08, France.

<sup>††</sup> Centre Léon Bérard, 28 Prom. Léa et Napoléon Bullukian, 69008 Lyon, France.

<https://doi.org/10.1016/j.radcr.2020.10.005>

1930-0433/© 2020 The Authors. Published by Elsevier Inc. on behalf of University of Washington. This is an open access article under the CC BY-NC-ND license (<http://creativecommons.org/licenses/by-nc-nd/4.0/>)



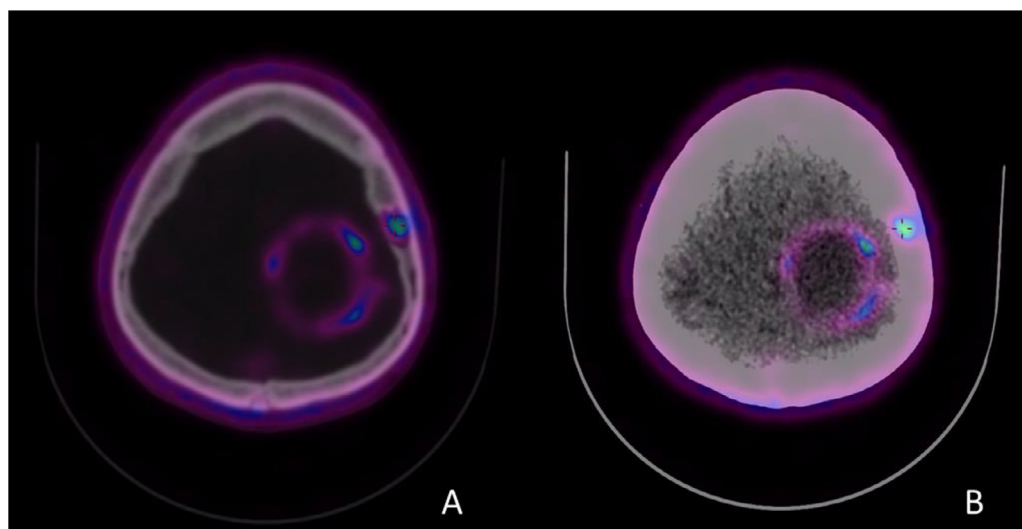
**Fig. 1 – Maximum intensity projection images with  $[^{68}\text{Ga}]\text{Ga-PSMA-11}$  PET revealed a low and homogeneous uptake surrounding the lesion, and a focal mild uptake near to the glioblastoma.**

pressed in prostate adenocarcinomas. It is also overexpressed by the endothelium of tumor-associated neovasculature such as glioblastomas multiform, but neither in malignant tumor cells themselves nor in normal vessels. A few articles have

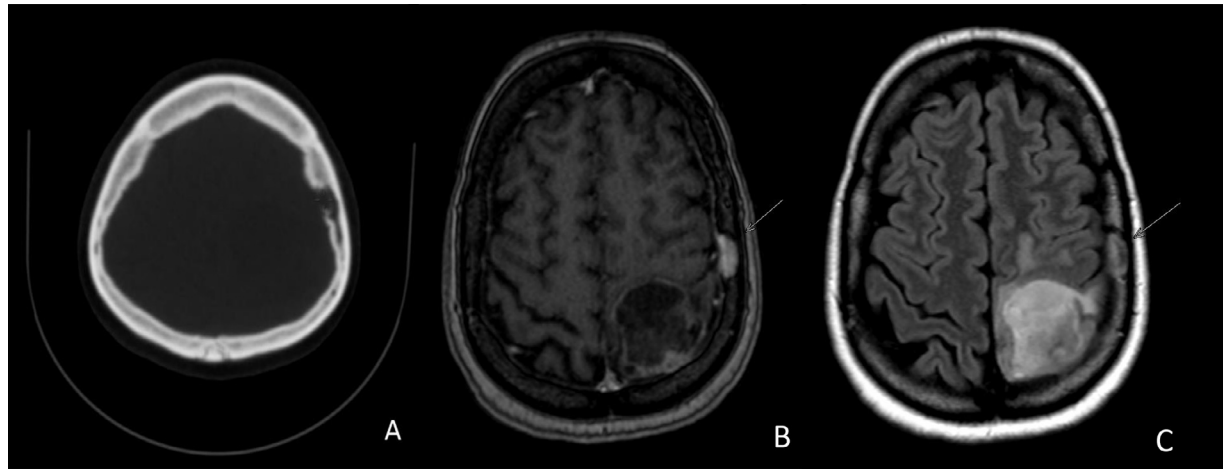
highlighted the possible role of  $[^{68}\text{Ga}]\text{Ga-PSMA-11}$  in glioma imaging [5,6]. We present here the case of an incidental discovery of a skull vault hemangioma (SVH) in a patient explored with  $[^{68}\text{Ga}]\text{Ga-PSMA-11}$  PET/CT for an irradiated glioblastoma.

### Case report

A 47-year-old woman was followed up for a nonoperated left fronto parietal glioblastoma treated by radiochemotherapy. The magnetic resonance imaging (MRI) performed 1 month after the end of chemotherapy concluded in morphological stability with a perilesional oedema enlargement. Clinically, there was a difficulty in achieving cortisone withdrawal which was associated with a symptoms recrudescence (paresthesias, dysesthesias, and right hemicorps clonies).  $[^{68}\text{Ga}]\text{Ga-PSMA-11}$  PET/CT was performed to assess the therapeutic response after radiochemotherapy to confirm inflammatory changes and to rule out an evolutionary process.  $[^{68}\text{Ga}]\text{Ga-PSMA-11}$  PET/CT was conducted to assess these lesions, 1 hour after the intravenous injection of 98MBq of  $[^{68}\text{Ga}]\text{Ga-PSMA-11}$ . The examination displayed a low and homogeneous uptake surrounding the lesion (Figs. 1 and 2) concurring with postradiation changes. There was also a focal mild uptake of what seemed like a parietal lytic skull diploe lesion (Fig. 3A) near to the glioblastoma (Figs. 1 and 2). This image was seen a posteriori on the MRI follow-up, stable appearing in continuity with skull vessels, demonstrating a hyperT2-FLAIR and homogenous enhancement (Figs. 3B and C). This was attributed to a SVH. The patient underwent Avastin (bevacizumab) as a test treatment for inflammatory changes, which was well tolerated, resulting in a partial clinical and imaging improvement at 3 months.



**Fig. 2 – The axial  $[^{68}\text{Ga}]\text{Ga-PSMA-11}$  PET/CT fusion images showed a focal mild uptake near to the glioblastoma (A, bone scanner) and a low and homogeneous uptake surrounding the lesion (B, tissular scanner).**



**Fig. 3 – The axial morphological examinations displayed a parietal lytic skull diploe lesion on bone scanner (part A: CT) and homogeneous enhancement on the MRI (part B: MRI axial T1 postgadolinium; Part C: MRI T2 Flair).**

## Discussion

This image was attributed to a SVH and not to a rare adjacent calvarial destruction [7]. Several benign lesion PSMA positives have been reported, such as splenic and vertebral hemangiomas [8], which are well described. SVH are lesions more rarely observed. SVH accounts for about 0.2% of all bone tumors and 10% of benign skull tumors. SVH consists of dilated blood vessels separated by fibrous tissue. The pathogenesis is not clearly elucidated [9]. Patients are rarely symptomatic (pain, mass effect) [10]. On the CT, SVH usually presents a well-delineated and limited intradiploid osteolytic lesion with sharp edges with a "honeycomb" appearance. It can sometimes demonstrate an erosion of the tables. On the MRI, SVH presents a hypersignal T2/FLAIR, a variable signal T1, and an enhancement after gadolinium injection. To our knowledge, this is the first PSMA-fixing SVH described. This case report is interesting for 2 reasons. First of all it reminds us that any bone lesion close to glioblastoma is not necessarily related to a contiguous bone lesion but may be related to a benign lesion such as a SVH. Moreover this benign hemangiomatous uptake could serve as a reference, to help defining the intensities of benign uptake due to inflammatory remodeling from pathological fixations related do recurrence. In our case, glioblastoma (white arrow) was the site of a modest homogeneous uptake (SUVmax 3.2), about the same intensity as the cranial vault hemangioma (SUVmax 3.3). Therefore, we considered the glioblastoma uptake as related to post radiation changes. Many articles have stressed the potential role of 18F- or 68Ga-radiolabeled PSMA in the evaluation of glioblastomas, especially in discriminating recurrences from postradiation changes [11]. But there is currently no threshold or validated interpretation criterion to define relapse from postradiation changes. Some authors have highlighted the over expression of PSMA by endothelial cells of reparative neovasculature and the moderate uptake of radionecrosis lesions [12,13]. Conversely, some authors have reported intense uptake of venous variants [14]. Thus, the uptake of inflammatory remodeling and benign vascular variants therefore appears to be variable.

The use of an uptake threshold based on vascular uptake to interpret the examination (postradiation changes vs relapse) seems contentious at this time. Other authors have used the Tumor-to-Background Ratio in addition to visual analysis to diagnose recurrences [15]. The interest of this ratio in exploring recurrence versus postradiation changes has not been investigated. Larger prospective studies have to be conducted in order to clarify the place of [68Ga]Ga-PSMA PET/CT in the distinction between evolutivity versus inflammatory changes and to better define the interpretation criteria. The therapeutic role should also be evaluated [16].

In conclusion, this clinical case highlights the possibility of false positives that can be encountered with [68Ga]Ga-PSMA-11 PET/CT as well as with 18F-FDG. This fact must be taken into consideration so as not to ignore possible rare and benign lesions such as SVH and not to confuse them with bone destruction due to contiguous glioblastoma, or with prostate cancer bone metastases. More generally, when interpreting a [68Ga]Ga-PSMA-11 PET/CT, one should keep in mind that every malignant, and less frequently benign, vascularized lesions may fix the tracer. This point may hinder the distinction between inflammatory post radiation changes and recurrences in patients treated with radiotherapy for glioblastoma.

## Authors statement

Written informed consent was obtained from the patient. This clinical image is part of a Clinical trial: "Cohort study assessing the feasibility of 68Ga-PSMA PET-CT and 18F-FDOPE PET-CT for identification of early recurrence in patients treated with radiotherapy for glioblastoma. EudraCT 2018-002271-17. ClinicalTrials.gov: NTC03903419

## Patient consent

Written informed consent was obtained from the patient.

## REFERENCES

- [1] Afshar-Oromieh A, Avtzi E, Giesel FL, Holland-Letz T, Linhart HG, Eder M, et al. The diagnostic value of PET/CT imaging with the <sup>68</sup>Ga-labelled PSMA ligand HBED-CC in the diagnosis of recurrent prostate cancer. *Eur J Nucl Med Mol Imaging* 2015;42:197–209.
- [2] Afshar-Oromieh A, Holland-Letz T, Giesel FL, Kratochwil C, Mier W, Haufe S, et al. Diagnostic performance of <sup>68</sup>Ga-PSMA-11 (HBED-CC) PET/CT in patients with recurrent prostate cancer: evaluation in 1007 patients. *Eur J Nucl Med Mol Imaging* 2017;44(8):1258–68.
- [3] Afshar-Oromieh A, Zechmann CM, Malcher A, Eder M, Eisenhut M, Linhart HG, et al. Comparison of PET imaging with a <sup>68</sup>Ga-labelled PSMA ligand and <sup>18</sup>F-choline-based PET/CT for the diagnosis of recurrent prostate cancer. *Eur J Nucl Med Mol Imaging* 2014;41(1):11–20.
- [4] Fendler WP, Eiber M, Beheshti M, Bomanji J, Ceci F, Cho S, et al. <sup>68</sup>Ga-PSMA PET/CT: joint EANM and SNMMI procedure guideline for prostate cancer imaging: version 1.0. *Eur J Nucl Med Mol Imaging* 2017;44(6):1014–24.
- [5] Sasikumar A, Joy A, Pillai MRA, Nanabala R, Anees K M, Jayaprakash PG, et al. Diagnostic value of <sup>68</sup>Ga PSMA-11 PET/CT imaging of brain tumors—Preliminary Analysis. *Clin Nuc Med* 2017;42(1):e41.
- [6] Sasikumar A, Kashyap R, Joy A, Charan Patro K, Bhattacharya P, Reddy Pilaka VK, et al. Utility of <sup>68</sup>Ga-PSMA-11 PET/CT in imaging of glioma—a pilot study. *Clin Nuc Med* 2018;43(9):e304.
- [7] Gheyi V, Hui FK, Doppenberg EM, et al. Glioblastoma multiforme causing calvarial destruction: an unusual manifestation revisited. *Am J Neuroradiol* 2004;25(9):1533–7.
- [8] Artigas C, Otte F-X, Lemort M, et al. Vertebral hemangioma mimicking bone metastasis in <sup>68</sup>Ga-PSMA ligand PET/CT. *Clin Nucl Med* 2017;42(5):368–70.
- [9] Yang Yi, Guan Jian, Ma Wenbin, et al. Primary intraosseous cavernous hemangioma in the skull. *Medicine (Baltimore)* 2016;95(11):e3069.
- [10] Escoda AP, Baudin PN, Mora P, et al. Imaging of skull vault tumors in adults. *Insights Imaging* 2020;11:23.
- [11] Sasikumar A, Kashyap R, Joy A, Charan Patro K, Bhattacharya P, Reddy Pilaka VK, et al. Utility of <sup>68</sup>Ga-PSMA-11 PET/CT in imaging of glioma—a pilot study. *Clin Nucl Med* 2018;43(9):e304–9.
- [12] Gordon IO, Tretiakova MS, Noffsinger AE, Hart J, Reuter VE, Al-Ahmadie HA. Prostate-specific membrane antigen expression in regeneration and repair. *Mod Pathol Off J U S Can Acad Pathol Inc* 2008;21(12):1421–7.
- [13] Salas Fragomeni RA, Pienta KJ, Pomper MG, Gorin MA, Rowe SP. Uptake of prostate-specific membrane antigen-targeted <sup>18</sup>F-DCFPyL in cerebral radionecrosis: implications for diagnostic imaging of high-grade gliomas. *Clin Nucl Med* 2018;43(11):e419–21.
- [14] Sgard B, Montravers F, Fourquet A, de la Taille A, Gauthé M. Pulmonary Vein varix mimicking prostate cancer metastasis on <sup>68</sup>Ga-prostate specific membrane antigen-11 PET/CT. *Clin Nucl Med* 2020;45(1):e39–40.
- [15] Kunikowska J, Kuliński R, Muylle K, Koziara H, Królicki L. <sup>68</sup>Ga-prostate-specific membrane antigen-11 PET/CT: a new imaging option for recurrent glioblastoma multiforme? *Clin Nucl Med*. 2020;45(1):11–18.
- [16] Kunikowska J, Charzyńska I, Kuliński R, Pawlak D, Maurin M, Królicki L. Tumor uptake in glioblastoma multiforme after IV injection of [<sup>177</sup>Lu]Lu-PSMA-617. *Eur J Nucl Med Mol Imaging* 2020;47(6):1605–6.