

## Tumors of the conjunctiva and cornea

Carol L Shields, Jerry A Shields

Tumors of the conjunctiva and cornea comprise a large and varied spectrum of conditions. These tumors are grouped into two major categories of congenital and acquired lesions. The acquired lesions are further subdivided based on origin of the mass into surface epithelial, melanocytic, vascular, fibrous, neural, histiocytic, myxoid, myogenic, lipomatous, lymphoid, leukemic, metastatic and secondary tumors. Melanocytic lesions include nevus, racial melanosis, primary acquired melanosis, melanoma, and other ocular surface conditions like ocular melanocytosis and secondary pigmentary deposition. The most frequent nonmelanocytic neoplastic lesions include squamous cell carcinoma and lymphoma, both of which have typical features appreciated on clinical examination. The caruncle displays a slightly different array of tumors compared to those elsewhere on the conjunctiva, as nevus and papilloma are most common, but oncocytoma and sebaceous gland hyperplasia, adenoma, and carcinoma can be found. In this report, we provide clinical description and illustration of the many conjunctival and corneal tumors and we discuss tumor management.

**Key words:** Conjunctiva, cornea, melanoma, tumor

## Access this article online

## Website:

www.ijo.in

## DOI:

10.4103/ijo.IJO\_2040\_19

## Quick Response Code:



This classic review article published in Survey of Ophthalmology is reprinted with permission from Elsevier. Copyright (2004). Shields CL, Shields JA. Tumors of the conjunctiva and cornea. Surv Ophthalmol 2004;49:3-24.

## General Considerations

Tumors of the conjunctiva and cornea occupy a large spectrum of conditions ranging from benign lesions such as limbal dermoid or myxoma to aggressive, life-threatening malignancies such as melanoma or Kaposi's sarcoma.<sup>[23,88]</sup> The clinical differentiation of these tumors is based on the patient's medical background as well as certain typical clinical features of the tumor. The recognition and proper management of such tumors requires an understanding of the anatomy of the conjunctiva and cornea and knowledge of general principles of tumor management, both of which are described below. The specific clinical and histopathologic features as well as the management of each tumor is discussed, based on the authors' personal experience with over 1,600 patients with conjunctival tumors during a 30-year period (Shields CL, submitted for publication). In this report, we review and illustrate the features of conjunctival and corneal tumors for the general ophthalmologist as well as the specialist who might occasionally examine an affected patient and want a quick reference for recognition and therapy.

## Anatomy

The conjunctiva is a continuous mucous membrane that covers the anterior portion of the globe. It extends from the eyelid margin onto the back surface of the eyelid (palpebral portion), into the fornix (forniceal portion), onto the surface of the globe (bulbar portion), and up to the corneoscleral

limbus (limbal portion). The conjunctiva is composed of epithelium and stroma. The epithelium consist of both stratified squamous and columnar epithelium.<sup>[89]</sup> The squamous pattern is found near the limbus and the columnar pattern is found near the fornix. The stroma is composed of fibrovascular connective tissue that thickens in the fornix and thins at the limbus.

Special regions of the conjunctiva include the plica semilunaris and caruncle. The plica semilunaris is a vertically oriented fold of conjunctiva, located in the medial portion of the bulbar conjunctiva. It is speculated that the plica semilunaris represents a remnant of the nictitating membrane found in certain animals. The caruncle is located in the medial canthus between the upper and lower punctum. It contains both conjunctival and cutaneous structures such as nonkeratinized stratified squamous epithelium overlying the stroma of fibroblasts, melanocytes, sebaceous glands, hair follicles, and striated muscle fibers.

Neoplasms can arise in the conjunctiva from both its epithelial and stromal structures. These are similar clinically and histopathologically to tumors that arise from other mucous membranes in the body. However, unlike other mucous membranes in the body, the conjunctiva is partially exposed to sunlight, which may be a factor in the development of some

Ocular Oncology Service, Wills Eye Hospital, Thomas Jefferson University, Philadelphia, Pennsylvania, USA

**Correspondence to:** Dr. Carol L Shields, Ocular Oncology Service, Wills Eye Hospital, Thomas Jefferson University, 840 Walnut Street, Suite 1440, Philadelphia, PA - 19107, United States. E-mail: carolshields@gmail.com

Received: 05-Nov-2019

Accepted: 05-Nov-2019

Published: 22-Nov-2019

This is an open access journal, and articles are distributed under the terms of the Creative Commons Attribution-NonCommercial-ShareAlike 4.0 License, which allows others to remix, tweak, and build upon the work non-commercially, as long as appropriate credit is given and the new creations are licensed under the identical terms.

**For reprints contact:** reprints@medknow.com

**Cite this article as:** Shields CL, Shields JA. Tumors of the conjunctiva and cornea. Indian J Ophthalmol 2019;67:1930-48.

tumors. Similarly, the cornea can develop epithelial tumors, but corneal stromal tumors are uncommon. The caruncle, with its unique composition of both mucous membrane and cutaneous structures, can generate tumors found both in mucosa and skin.

### Diagnostic approaches

Unlike many other mucous membranes in the body, the conjunctiva is readily visible. Thus, tumors and related lesions that occur in the conjunctiva are generally recognized at a relatively early stage. Because many of these tumors have typical clinical features, an accurate diagnosis can often be made by external ocular examination and slit-lamp biomicroscopy, provided that the clinician is familiar with their clinical characteristics. A diagnostic biopsy is not usually necessary in cases of smaller tumors ( $\leq 4$  clock hours limbal tumor or  $\leq 15$  mm basal dimension) that appear benign. If a smaller tumor does require a biopsy, it is often better to completely remove the lesion in one operation (excisional biopsy). In cases of larger lesions ( $> 4$  clock hour limbal tumor or  $> 15$  mm basal dimension), however, it may be appropriate to remove a portion of the tumor (incisional biopsy) to obtain a histopathologic diagnosis prior to embarking upon more extensive therapy, as conjunctival tumors are readily accessible to incisional biopsy. Occasionally, exfoliative cytology<sup>[90]</sup> and fine-needle aspiration biopsy can provide useful information on the basis of a few cells.

In addition to evaluation of the conjunctival lesion, meticulous slit-lamp examination of the cornea is essential in patients with suspected conjunctival tumors. Invasion of squamous cell carcinoma and melanoma into the peripheral cornea may appear as a subtle, gray surface opacity. It is important to completely outline such corneal involvement prior to surgery, because it is often less visible through the operating microscope than it is with slit-lamp biomicroscopy in the office.

### Management

Depending on the presumptive diagnosis and the size and extent of the lesion, management of a conjunctival tumor can consist of serial observation, incisional biopsy, excisional biopsy, cryotherapy, chemotherapy, radiotherapy, modified enucleation, orbital exenteration or various combinations of these methods.<sup>[1,78,79,80,86]</sup> If large areas of conjunctiva are removed, mucous membrane grafts from the conjunctiva of the opposite eye, buccal mucosa, or amniotic membrane may be necessary.<sup>[42,60]</sup>

#### Observation

Observation is generally the management of choice for most benign, asymptomatic tumors of the conjunctiva. Selected examples of lesions that can be observed without interventional treatment include pingueculum, dermolipoma, and nevus. External or slit-lamp photographs are advisable to document all lesions and are critical to follow-up of the more suspicious lesions. Most patients are examined every 6 to 12 months looking for evidence of growth, malignant change, or secondary effects on normal surrounding tissues.

#### Incisional biopsy

Incisional biopsy is reserved for extensive suspicious tumors that are symptomatic or suspected to be malignant. Examples include large squamous cell carcinoma, primary acquired melanosis, melanoma, and conjunctival invasion by sebaceous gland carcinoma. It should be understood that if tumors occupy 4 clock hours or less on the bulbar conjunctiva, excisional

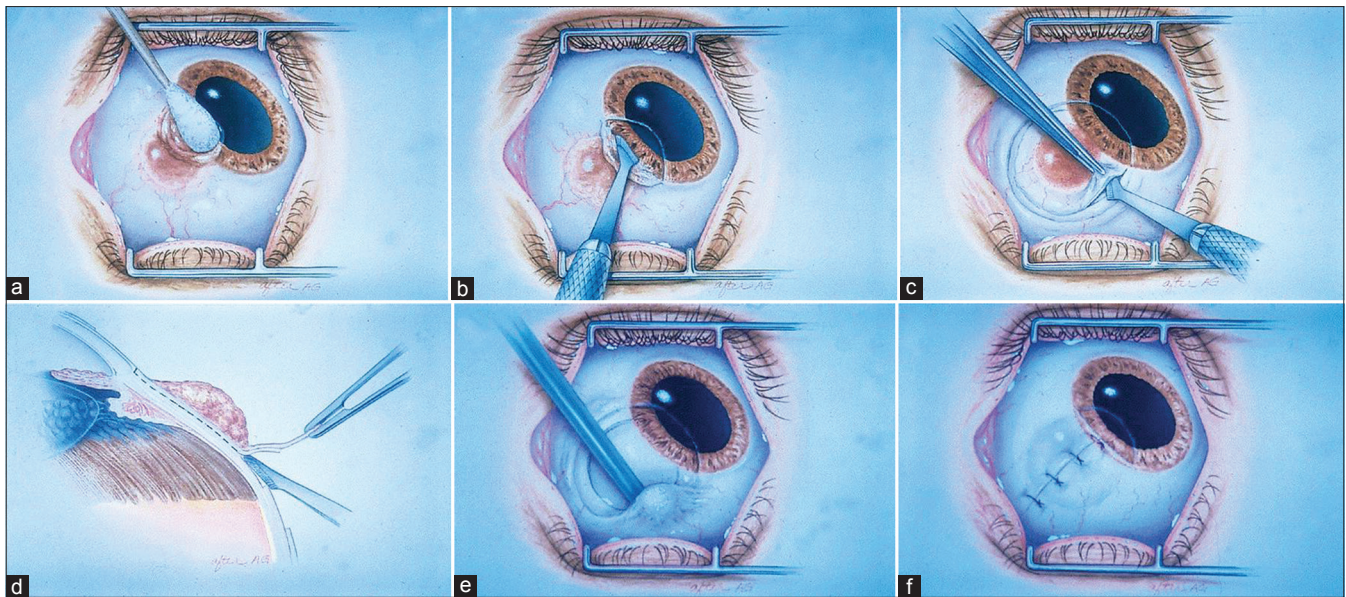
biopsy is generally preferable to incisional biopsy. However, larger lesions can be approached by incisional wedge biopsy or punch biopsy. Definitive therapy would then be planned based on the results of biopsy. Incisional biopsy is also appropriate for conditions that are ideally treated with radiotherapy, chemotherapy, or other topical medications. These lesions include lymphoid tumors, metastatic tumors, extensive papillomatosis, and some cases of squamous cell carcinoma and primary acquired melanosis. Incisional biopsy should generally be avoided for melanocytic tumors, especially melanoma, as this can increase the risk for numerous tumor recurrences.<sup>[64]</sup>

#### Excisional biopsy

Primary excisional biopsy is appropriate for relatively smaller tumors ( $\leq 4$  clock hours limbal tumor or  $\leq 15$  mm basal dimension) that are symptomatic or suspected to be malignant. In these situations, excisional biopsy is preferred over incisional biopsy to avoid inadvertent tumor seeding. Examples of benign and malignant lesions that are ideally managed by excisional biopsy include symptomatic limbal dermoid, epibulbar osseous choristoma, steroid-resistant pyogenic granuloma, squamous cell carcinoma, and melanoma. When such lesions are located in the conjunctival fornix they can be completely excised and the conjunctiva reconstructed primarily with absorbable sutures, sometimes with fornix deepening sutures or symblepharon ring to prevent adhesions. If the defect cannot be closed primarily, then a mucous membrane graft can be inserted.

Most primary malignant tumors of the conjunctiva, like squamous cell carcinoma and melanoma, arise in the interpalpebral area near the limbus and the surgical technique for limbal tumors is different than that for forniceal tumors.<sup>[72,78,79]</sup> Limbal neoplasms possibly can invade through the corneal epithelium and sclera into the anterior chamber and also through the soft tissues into the orbit. Thus, it is often necessary to remove a thin lamella of sclera to achieve tumor-free margins and to decrease the chance for tumor recurrence. In this regard, we employ a partial lamellar sclerokeratoconjunctivectomy with primary closure in for such tumors (Fig. 1). Because cells from these friable tumors can seed into adjacent tissues, a gentle technique without touching the tumor (*no touch technique*) is advised. Additionally, the surgery should be performed using microscopic technique and the operative field should be left dry so that cells adhere to the resected tissue. It is wise to avoid wetting the field with balanced salt solution until after the tumor is completely removed to minimize seeding of cells. There are no published comparative reports of the various surgical techniques for tumor excision, but discussions at the 1997 International Congress of Ocular Oncology in Jerusalem supported the above surgical principles.

The technique for resection of limbal tumors is shown in Fig. 1. Using retrobulbar anesthesia and the operating microscope, the corneal epithelial component is approached first and the conjunctival component is dissected second, with the goal of excising the entire specimen completely in one piece. Absolute alcohol soaked on an applicator is gently applied to the entire corneal component. This causes epithelial cellular devitalization and allows easier release of the tumor cells from Bowman's layer. A beaver blade is used to microscopically outline the malignancy within the corneal epithelium using a delicate epithelial incision or epitheliorex technique 2 mm outside the corneal component. The beaver blade is then used to sweep gently the affected corneal epithelium



**Figure 1:** Surgical excision of conjunctival malignancy using the “no touch” technique. (a) Absolute alcohol is applied by a cotton tip applicator to the involved cornea to allow for controlled corneal epitheliectomy. (b) The corneal epithelium is scrolled off using a controlled sweeping motion with a beaver blade. (c) The conjunctival incision is made approximately 4 mm outside the tumor margin. A beaver blade is used to create a thin lamella of tumor-free sclera underlying the limbal portion of the tumor. (d) The conjunctival malignancy is removed, along with tumor-free margins, including underlying sclera and limbal corneal epithelium. (e) Cryotherapy is applied to the conjunctiva at the site of resection. (f) Closure of the conjunctiva with absorbable sutures is performed

from the direction of the central cornea to limbus, into a scroll that rests at the limbus. Next, a pentagonal or circular conjunctival incision based at the limbus is made 4–6 mm outside the tumor margin. The incision is carried through the underlying Tenon’s fascia until the sclera is exposed so that full thickness conjunctiva and Tenon’s fascia is incorporated into the excisional biopsy. Cautery is applied to control bleeding. A second incision is then outlined by a superficial scleral groove approximately 0.2 mm in depth and 2.0 mm outside the base of the overlying adherent conjunctival mass. This groove is continued anteriorly to the limbus. The area outlined by the scleral groove is removed by flat dissection of 0.2-mm thickness within the sclera in an attempt to remove a superficial lamella of sclera, overlying Tenon’s fascia and conjunctiva with tumor, and the scrolled corneal epithelium. In this way, the entire tumor with tumor-free margins is removed in one piece without touching the tumor itself (no touch technique). The removed specimen is then placed flatly on a piece of thin cardboard from the surgical tray and then placed in fixative and submitted for histopathologic studies. This step prevents the specimen from folding and allows better assessment of the tumor margins histopathologically. The used instruments are then replaced with fresh instruments for subsequent steps, to avoid contamination of healthy tissue with possible tumor cells.

After excision of the specimen, cryotherapy is applied to the margins of the remaining bulbar conjunctiva. This is performed by freezing the surrounding bulbar conjunctiva as it is lifted away from the sclera using the cryoprobe. When the ice ball reaches a size of 4–5 mm, it is allowed to thaw and the cycle repeated once more. The cryoprobe is then moved to an adjacent area of the conjunctiva and the cycle is repeated until all of the margins have been treated by this method. It is not necessary to treat the corneal margins with cryoapplication. The tumor bed is treated with absolute alcohol wash on cotton tip applicator and bipolar cautery, avoiding cryotherapy directly to the sclera.

Using clean instruments, the conjunctiva is mobilized for closure of the defect by loosening the intermuscular septum with Steven’s scissor spreading and creation of transpositional conjunctival flaps. Closure is completed with interrupted absorbable 6-0 or 7-0 sutures. If the surgeon prefers, an area of bare sclera can be left near the limbus, but we prefer complete closure as this promotes better healing and allows for facility of further surgery if the patient should develop recurrence. The patient is treated with topical antibiotics and corticosteroids for two weeks and then followed at 3- to 6-month intervals.

#### *Cryotherapy*

In the management of conjunctival tumors, cryotherapy can be used as a supplemental treatment to excisional biopsy as described above. The advantages of cryotherapy include elimination of subclinical, microscopic tumor cells and prevention of recurrence of malignant tumors, including squamous cell carcinoma and melanoma.<sup>[14,64]</sup> It can also be used as a principal treatment for primary acquired melanosis and pagetoid invasion of sebaceous gland carcinoma. If cryotherapy can devitalize the malignant or potentially malignant cells in these instances, radical surgery like orbital exenteration can often be delayed or avoided. The disadvantages of cryotherapy include conjunctival chemosis that may last over one week and if the technique is misused and the globe is accidentally frozen, cataract, uveitis, scleral, and corneal thinning, and phthisis bulbi can occur.

#### *Chemotherapy*

Recent evidence has revealed that topical eyedrops comprised of mitomycin C, 5-fluorouracil, or interferon are effective in treating epithelial malignancies such as squamous cell carcinoma, primary acquired melanosis, and pagetoid invasion of sebaceous gland carcinoma.<sup>[19,20,32,38,53,56,57,96,97]</sup> Mitomycin C or 5-fluorouracil are employed most successfully for squamous cell carcinoma, especially after tumor recurrence following

previous surgery. This medication is prescribed topically 4 times daily for a 1-week period followed by a 1-week hiatus to allow the ocular surface to recover [Table 1]. This cycle is repeated once again so that most patients receive a total of two weeks of the chemotherapy topically. Both mitomycin C and 5-fluorouracil are most effective for squamous cell carcinoma and less effective for primary acquired melanosis and pagetoid invasion of sebaceous gland carcinoma. Caution should be used with this medication as it is most effective for intraepithelial disease and much less effective or ineffective for deeper disease. Toxicities include most commonly dry eye findings, superficial punctate epitheliopathy, and punctal stenosis. Corneal melt, scleral melt, and cataract can develop if these agents are used with open conjunctival wounds or used excessively. Topical interferon can be effective for squamous epithelial malignancies and is less toxic to the surface epithelium, but this medication may require many months of use to effect a result.<sup>[32]</sup>

*Radiotherapy*

Two forms of radiotherapy are employed for conjunctival tumors, namely external beam radiotherapy and custom-designed plaque radiotherapy. External beam radiotherapy to a total dose of 3,000–4,000 cGy is used to treat conjunctival lymphoma and metastatic carcinoma when they are too large or diffuse to excise locally. Side effects of dry eye, punctate epithelial abnormalities, and cataract should be anticipated.

Custom-designed plaque radiotherapy<sup>[65]</sup> to a dose of 3,000–4,000 cGy can be used to treat conjunctival lymphoma or metastasis. A higher dose of 6,000–8,000 cGy can be employed to treat the more radiation resistant melanoma and squamous cell carcinoma. In general, plaque radiotherapy is reserved for those patients who have diffuse tumors that are incompletely resected and for those who display multiple recurrences. The two designs for conjunctival custom plaque radiotherapy include a conformer plaque technique with six fractionated treatment sessions as an outpatient or a reverse plaque technique with the device sutured onto the episcleral as an inpatient. In unique instances, plaque radiotherapy to a low dose of 2,000 cGy is employed for benign conditions, including steroid resistant pyogenic granuloma that show recurrence after surgical resection.<sup>[26]</sup> This treatment should be performed by experienced radiation oncologists and ocular oncologists. There is no published report on a comparison of these radiotherapy techniques.

*Modified enucleation*

Modified enucleation is a treatment option for primary malignant tumors of the conjunctiva that have invaded through the limbal tissues into the globe, producing secondary

glaucoma. This occurrence is quite rare but can occasionally be found with squamous cell carcinoma and melanoma. The uncommon mucoepidermoid variant and spindle cell variant of squamous cell carcinoma of the conjunctiva has a greater tendency for intraocular invasion.<sup>[2,7,25]</sup> At the time of enucleation, it is necessary to remove the involved conjunctiva intact with the globe so as to avoid spreading tumor cells. Thus, the initial peritomy should begin at the limbus, but when the tumor is approached, the incision should proceed posteriorly from the limbus to surround the tumor-affected tissue by at least 3–4 mm. The tumor will remain adherent to the globe at the limbus. Occasionally, a suture is employed through the surrounding conjunctiva into the episclera to secure the tumor to the globe so that it will not be displaced during subsequent manipulation. The remaining steps of enucleation are gently performed and the globe is removed with tumor adherent after cutting the optic nerve from the nasal side. The margins of the remaining, presumed unaffected conjunctiva are treated with double freeze-thaw cryotherapy. Often this surgical technique leaves the patient with a limited amount of residual unaffected conjunctiva for closure. In these instances, a mucous membrane graft or amniotic membrane graft may be necessary for adequate closure and to provide fornices for a prosthesis. In some instances, a simple horizontal inferior forniceal conjunctival incision from canthus to canthus may suffice, as long as the conformer is constantly worn as a template so the new conjunctival fornix grows deep and around this structure.

*Orbital exenteration*

Orbital exenteration is probably the treatment of choice for primary malignant conjunctival tumors that have invaded the orbit or that exhibit complete involvement of the conjunctiva.<sup>[64,84,86]</sup> Either an eyelid-removing or eyelid-sparing exenteration is employed, depending on the extent of eyelid involvement. The eyelid-sparing technique is preferred in that the patients have better cosmetic appearance and heal within 2 or 3 weeks. Specifically, if the anterior lamella of the eyelid is uninvolved with tumor, an eyelid-sparing (eyelid-splitting) exenteration may be accomplished.<sup>[78,84,86]</sup> Other options to exenteration are radiotherapy using the external beam approach or the brachytherapy approach. There are too few cases in the literature to do a scientific comparison.

*Mucous membrane graft*

Mucous membrane grafts are occasionally necessary to replace vital conjunctival tissue after removal of extensive conjunctival tumors. The best donor sites include the forniceal conjunctiva of the ipsilateral or contralateral eye and buccal mucosa from the posterior aspect of the lower lip or lateral aspect of the mouth. Such grafts are usually removed by a freehand technique, fashioned to fit the defect, and secured into place with cardinal and running absorbable 6-0 or 7-0 sutures. Currently, in most instances, we employ a donor amniotic membrane graft to replace lost conjunctiva.<sup>[42,60]</sup> The tissue is delivered frozen and must be defrosted for 20 minutes. The fine, transparent material is carefully peeled off its cardboard surface, laid basement membrane side up, and sutured into place with absorbable sutures. Topical antibiotic and steroid ointments are applied following all conjunctival grafting procedures.

It is important that the surgeon use a minimal manipulation technique for tumor resection. For graft harvest and placement, we prefer to use clean, sterile instruments at both the donor

**Table 1: Protocol for Use of Mitomycin C for Conjunctival Squamous Cell Neoplasia and Primary Acquired Melanosis**

| Time   | Medication and Frequency   |
|--------|--|
| Week 1 | Slit-lamp biomicroscopy<br>Place upper and lower punctal plugs<br>Cycle 1: mitomycin C 0.04% qid to the affected eye                             |
| Week 2 | No medication  |
| Week 3 | Cycle 2: mitomycin C 0.04% qid to the affected eye   |
| Week 4 | No medication<br>Slit-lamp biomicroscopy<br>Prescribe more cycles if residual tumor exists<br>Remove punctal plugs after all medication complete |

and the recipient sites to avoid transfer and implantation of tumor cells into previously uninvolved areas.

## Congenital Lesions

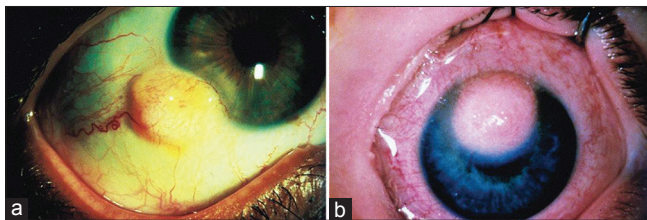
A variety of tumors and related conditions may be present at birth or become clinically apparent shortly after birth.<sup>[10,74]</sup> Most of the lesions to be considered here are choristomas, consisting of displaced tissue elements normally not found in these areas. A simple choristoma is comprised of one tissue element such as epithelium whereas a complex choristoma represents variable combinations of ectopic tissues like bone, cartilage, and lacrimal gland. Despite their presence at a young age, all of the conjunctival choristomas discussed herein are sporadic, without hereditary tendency.

### Dermoid

Conjunctival dermoid is a congenital well-circumscribed yellow-white solid mass that involves the bulbar conjunctiva or at the corneoscleral limbus.<sup>[10,11,49,72,74]</sup> It characteristically occurs near the limbus inferotemporally and often this tumor has fine white hairs, best seen with slit lamp biomicroscopy (Fig. 2). In rare cases, it can extend to the central cornea or be located in other quadrants on the bulbar surface. There are three types of dermoids, classified on the extent of involvement. The first type includes the small limbal dermoid, straddling the limbus and approximately 5 mm in diameter. The second type is larger, often involving the entire surface of the cornea, but not deeper than Descemet's membrane. The third type is most extensive and the dermoid involves the cornea, anterior chamber, and iris stroma and its posterior aspect is lined by the iris pigment epithelium. The various types are related to the time during fetal development in which the dermoid develops, with more severe types occurring earlier.

Conjunctival dermoid may occur as an isolated lesion or it can be associated with Goldenhar's syndrome. Hence, the patient should be evaluated for ipsilateral or bilateral preauricular skin appendages, hearing loss, eyelid coloboma, orbitoconjunctival dermolipoma, and cervical vertebral anomalies that comprise this nonheritable syndrome. Histopathologically, the conjunctival dermoid is a simple choristomatous malformation that consists of dense fibrous tissue lined by conjunctival epithelium with deeper dermal elements including hair follicles and sebaceous glands.

The management of an epibulbar dermoid includes simple observation if the lesion is small and visually asymptomatic. It is possible to excise the lesion for cosmetic reasons, but the remaining corneal scar is sometimes cosmetically unacceptable. Larger or symptomatic dermoids can produce visual loss



**Figure 2:** Epibulbar dermoid. (a) Limbal dermoid. (b) Central corneal dermoid

from astigmatism. These can be approached by lamellar keratosclerectomy with primary closure of overlying tissue if the defect is superficial or closure using corneal graft if the defect is deep or full thickness. It has been reported that the cosmetic appearance may improve, but the refractive and astigmatic error and visual acuity may not change.<sup>[49]</sup> When the lesion involves the central cornea, a lamellar or penetrating keratoplasty may be necessary and long-term amblyopia can be a problem.<sup>[72]</sup> Occasionally, extensive dermoids involve the lateral canthus and carefully planned excision with lateral canthal repair is necessary.

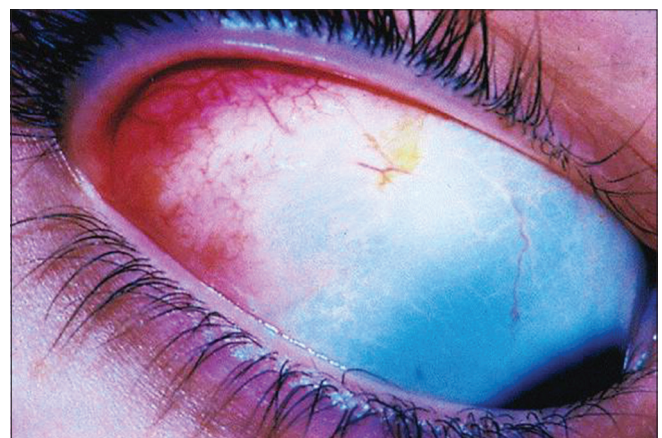
### Dermolipoma

Dermolipoma is believed to be congenital and present at birth, but it typically remains asymptomatic for years and may not be detected until adulthood when it protrudes from the orbit through the conjunctival fornix superotemporally (Fig. 3). It appears as a pale-yellow, soft, fluctuant, fusiform mass below the palpebral lobe of the lacrimal gland, best visualized with the eye in inferonasal gaze. It usually extends for a variable distance into the orbital fat and onto the bulbar conjunctiva, and occasionally it can extend anteriorly to reach the limbus. Unlike herniated orbital fat, dermolipoma can contain fine white hairs on its surface and it cannot be reduced with digital pressure into the orbit.

With computed tomography (CT) or magnetic resonance imaging (MRI), dermolipoma has features similar to orbital fat from which it may be indistinguishable. Histopathologically, it is lined by conjunctival epithelium on its surface and the subepithelial tissue has variable quantities of collagenous connective tissue and adipose tissue. Pilosebaceous units and lacrimal gland tissue may occasionally be present. The majority of dermolipomas require no treatment, but larger symptomatic ones or those that are cosmetically unappealing can be managed by excision of the entire orbitoconjunctival lesion through a conjunctival forniceal approach or by simply removing the anterior portion of the lesion in a manner similar to that used to remove prolapsed orbital fat.

### Epibulbar osseous choristoma

Epibulbar osseous choristoma is a rigid deposit of bone generally located in the bulbar conjunctiva superotemporally (Fig. 4).<sup>[70]</sup> It is believed to be congenital and typically remains undetected until personally palpated by the patient in the preteen years. It is clinically suspected due to its rock-hard



**Figure 3:** Dermolipoma in superotemporal conjunctival fornix

consistency on palpation, although fibrous tissue tumors can feel similar. The diagnosis can be confirmed with ultrasonography or computed tomography to illustrate the calcium component. This tumor is generally best managed by periodic observation. Occasionally patients report a foreign body sensation and symptomatic lesions can be excised with a circumtumoral conjunctival incision followed by dissection to bare sclera for full thickness conjunctival resection. For those tumors that might be adherent to the sclera, a superficial sclerectomy might be warranted.<sup>[70]</sup>

### Lacrimal gland choristoma

Lacrimal gland choristoma is a congenital lesion, discovered in young children as an asymptomatic pink stromal mass, typically in the superotemporal or temporal portion of the conjunctiva.<sup>[45]</sup> It is speculated that this lesion represents small sequestrations of the embryonic evagination of the lacrimal gland from the conjunctiva. The lacrimal gland choristoma can masquerade as a focus of inflammation due to its pink color. Rarely, a cystic appearance ensues from this secretory mass if there is no connection to the conjunctival surface. Excisional biopsy is usually performed to confirm the diagnosis.

### Respiratory choristoma

In unique instances, a cystic choristoma, appearing as congenital sclerocorneal ectasia, is found. In one report, this was found to manifest respiratory mucosa.<sup>[98]</sup>

### Complex choristoma

The conjunctival dermoid and epibulbar osseous choristoma are termed simple choristomas as they contain one tissue type such as skin or bone. A complex choristoma contains a greater variety of tissue like dermal appendages, lacrimal gland tissue, cartilage, bone, and occasionally other elements. Complex choristoma contains tissue derived from two germ layers. It is quite variable in its clinical appearance and may cover much of the epibulbar surface or it may form a circumferential growth pattern around the limbus (Fig. 5). For example, a tumor with extensive lacrimal tissue appears as a lobular pink mass whereas one with dermal tissue appears yellow and thick and one with cartilage displays a smooth blue-gray hue. The complex choristoma has a peculiar association with the linear nevus sebaceous of Jadassohn.<sup>[58,75,82]</sup> The nevus sebaceous of Jadassohn includes cutaneous features with sebaceous nevus

in the facial region and neurologic features including seizures, mental retardation, arachnoid cyst, and cerebral atrophy. The ophthalmic features of this syndrome include epibulbar complex choristoma and posterior scleral cartilage.<sup>[82]</sup>

The management of the complex choristoma depends upon the extent of the lesion. Observation or wide local excision with mucous membrane graft reconstruction are options. In the rare case of a very extensive lesion, where the lesion causes dense amblyopia with no hope for visual acuity, modified enucleation with ocular surface reconstruction may be necessary.

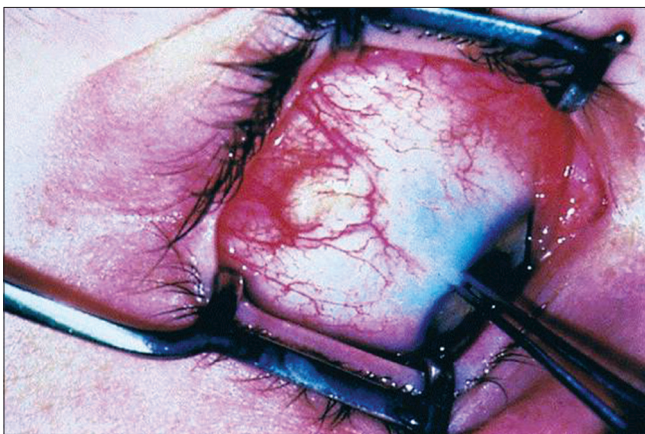
## Benign Tumors of Surface Epithelium

Several benign tumors and related conditions can arise from the squamous epithelium of the conjunctiva.

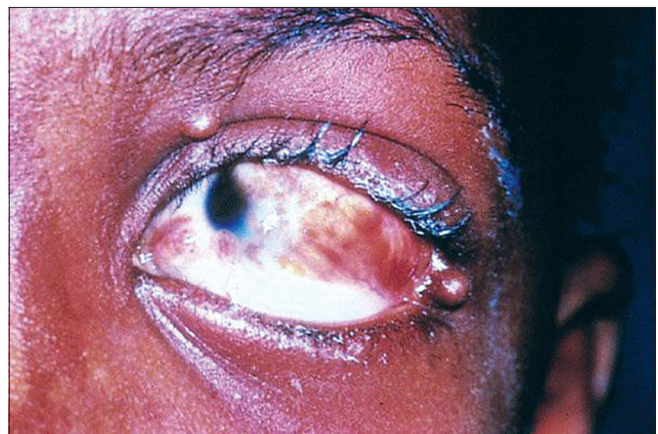### Papilloma

Squamous papilloma is a benign tumor, documented to be associated with human papillomavirus (subtypes 6, 11, 16, and 18) infection of the conjunctiva.<sup>[55,88]</sup> This tumor can occur in both children and adults. It is speculated that the virus is acquired through transfer from the mother's vagina to the newborn's conjunctiva as the child passes through the mother's birth canal. Papilloma appears as a pink fibrovascular frond of tissue arranged in a sessile or pedunculated configuration. The numerous fine vascular channels ramify through the stroma beneath the epithelial surface of the lesion. In children, the lesion is usually small, multiple, and located in the inferior fornix (Fig. 6). In adults, it is usually solitary, more extensive, and can often extend to cover the entire corneal surface simulating malignant squamous cell carcinoma. Histopathologically, the lesion shows numerous vascularized papillary fronds lined by acanthotic epithelium.

In the case of a small sessile papilloma in a child, there are several treatment options. Sometimes, periodic observation allows for slow spontaneous resolution of the viral-produced tumor. Larger or more pedunculated lesions are generally symptomatic with foreign body sensation, chronic mucous production, hemorrhagic tears, incomplete eyelid closure, and poor cosmetic appearance. These lesions are unlikely to show a favorable response to observation or steroids and are best managed by surgical excision. Complete removal



**Figure 4:** Epibulbar osseous choristoma on bulbar conjunctiva superotemporally, presenting as a firm, palpable mass



**Figure 5:** Epibulbar complex choristoma that was found histopathologically to have cartilage and ectopic lacrimal gland

of the mass without direction manipulation of the tumor (no touch technique) is generally advisable to avoid spreading of the tumor-related virus. Double freeze-thaw cryotherapy is applied to the remaining conjunctiva around the excised lesion in order to help prevent tumor recurrence. In some instances, the pedunculated tumor is frozen alone and allowed to slough off the conjunctival surface later. For some large unwieldy pedunculated tumors, complete cryotherapy of the mass down its stalk to its base is performed and excision while the mass is in the frozen state is achieved. This is especially important for large lesions to allow for traction on the tumor without force manipulation. Closure is completed with absorbable sutures. Topical interferon and mitomycin C have been employed for conjunctival papillomas.<sup>[27,47]</sup> For those lesions that show recurrence, oral cimetidine for several months can resolve the papilloma virus-related tumor by boosting the patient's immune system and stimulating regression of the mass (Fig. 6).<sup>[55]</sup>

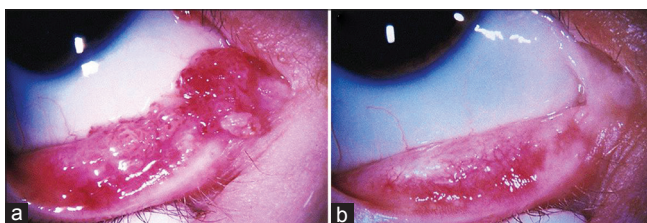
#### Keratoacanthoma

The conjunctiva can give rise to benign reactive inflammatory lesions that simulate carcinoma including pseudocarcinomatous hyperplasia and its variant, keratoacanthoma.<sup>[39]</sup> In some instances a distinct nodule is found. This lesion appears gelatinous or leukoplakic, similar to squamous cell carcinoma of the conjunctiva, but its onset may be more rapid. Massive acanthosis, hyperkeratosis and parakeratosis is found histopathologically.<sup>[39]</sup> Treatment is complete resection as this may be difficult to differentiate from carcinoma both clinically and histopathologically.

#### Hereditary benign intraepithelial dyskeratosis

Hereditary benign intraepithelial dyskeratosis (HBID) is a peculiar condition seen in an inbred isolate of white, African-American, and Native American (Haliwa Indians). This group resided initially in North Carolina. Hereditary benign intraepithelial dyskeratosis has subsequently been detected in several other parts of the United States. It is an autosomal dominant disorder characterized by bilateral elevated fleshy plaques on the nasal or temporal perilimbal conjunctiva (Fig. 7).<sup>[63]</sup> Similar plaques can occur on the buccal mucosa. It can remain relative asymptomatic or it can cause severe redness and foreign body sensation. In some instances it can extend onto the cornea. It has no known malignant potential. It is characterized histopathologically by acanthosis, dyskeratosis on the epithelial surface and deep within the epithelium, and prominent chronic inflammatory cells.

Hereditary benign intraepithelial dyskeratosis is a benign condition that does not usually require aggressive treatment. Smaller, less symptomatic lesions can be treated with ocular



**Figure 6:** Recurrent conjunctival papilloma in a child. (a) The fibrovascular mass caused bloody tears. (b) Following 3 months of oral cimetidine, the mass resolved

lubricants and judicious use of topical corticosteroids. Larger symptomatic lesions can be managed by local resection with mucous membrane grafting if necessary.

#### Epithelial inclusion cyst

Conjunctival cysts can occur spontaneously or following inflammation, surgery, or nonsurgical trauma. Histopathologically, they are lined by conjunctival epithelium and are filled with clear fluid that often contains desquamated cellular debris (Fig. 8). These cysts can be simply observed or they can be excised completely with primary closure of the conjunctiva.

#### Dacryoadenoma

Dacryoadenoma is a rare conjunctival tumor, noted in patients as a pink mass. In one report, this tumor was found in the inferior bulbar region of a 48-year-old woman.<sup>[30]</sup> It is uncertain if the lesion is congenital or acquired. This benign tumor appears to originate from the surface epithelium and proliferate into the stroma, forming glandular lobules similar to the lacrimal gland.

#### Keratotic plaque

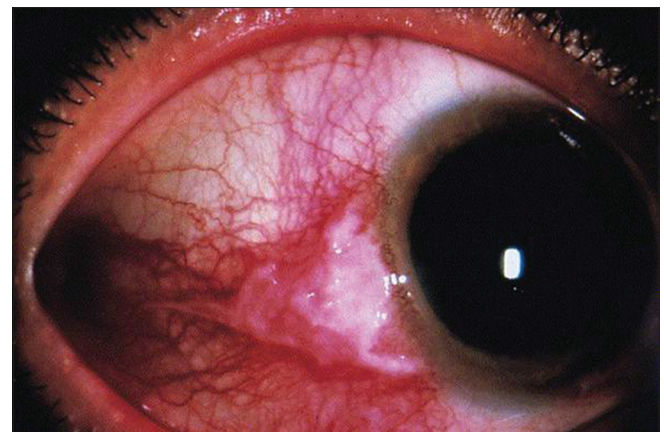
Keratotic plaque is a white limbal or bulbar conjunctival mass, usually in the interpalpebral region.<sup>[76]</sup> It is composed of acanthosis and parakeratosis with keratinization of the epithelium. It appears similar to squamous cell carcinoma with leukoplakia.

#### Actinic keratosis

Actinic keratosis is a frothy, white lesion usually located over a chronically inflamed pingueculum or pterygium.<sup>[76]</sup> It is also referred to as dysplasia, actinic keratosis variety. Histopathologically, it is composed of a proliferation of surface epithelium with keratosis. Clinically, it resembles squamous cell carcinoma of the conjunctiva.

### Malignant Lesions of Surface Epithelium

Squamous cell neoplasia can occur as a localized lesion confined to the surface epithelium (conjunctival intraepithelial neoplasia or dysplasia) or as a more invasive squamous cell carcinoma that has broken through the basement membrane and invaded the underlying stroma.<sup>[2,4,25,29,36,85,92]</sup> The former



**Figure 7:** Hereditary benign intraepithelial dyskeratosis in a young woman who was a descendent of a Haliwa Indian. The opposite eye had a similar lesion

has no potential to metastasize but the latter can gain access to the conjunctival lymphatics and occasionally metastasize to regional lymph nodes. It has been found that most squamous cell neoplasia is related to human papillomavirus infection of the conjunctival epithelium and this is most certain in those patients with bilateral squamous cell neoplasia and those immunosuppressed patients who develop this disease.<sup>[48]</sup>

The currently accepted term for the localized variety is conjunctival intraepithelial neoplasia (CIN), but others prefer the terms dysplasia (mild, moderate, or severe) and carcinoma-in-situ. When the abnormal cellular proliferation involves only partial thickness of the epithelium it is classified as mild CIN, a condition also called mild or moderate dysplasia. When it affects full thickness epithelium it is called severe CIN, a condition also called severe dysplasia. In these cases, there may be an intact surface layer of cells. Where there are no longer normal surface cells then the process is termed carcinoma-in-situ. It is stressed that these are histopathologic terms and the differential between CIN mild and CIN severe cannot be made clinically.

#### Conjunctival intraepithelial neoplasia (CIN)

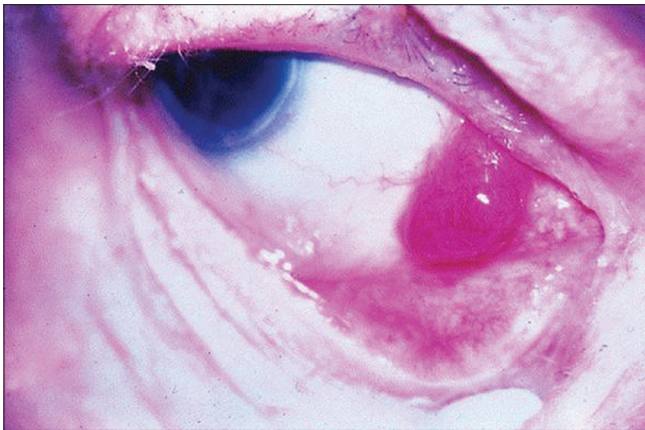
Clinically, CIN appears as a fleshy, sessile or minimally elevated lesion usually at limbus in the interpalpreal fissure and less commonly in the forniceal or palpebral conjunctiva (Fig. 9). The limbal lesion may extend for a variable distance into the epithelium of the adjacent cornea. A white plaque (leukoplakia) may occur on the surface of the lesion due to secondary hyperkeratosis.

Histopathologically, mild CIN (dysplasia) is characterized by a partial thickness replacement of the surface epithelium by abnormal epithelial cells that lack normal maturation. Severe CIN (severe dysplasia) is characterized by a nearly full-thickness replacement of the epithelium by similar cells. Carcinoma-in-situ represents full thickness replacement by abnormal epithelial cells.

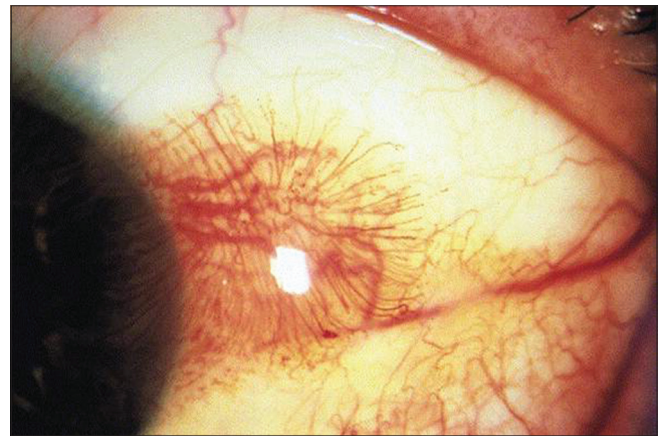#### Squamous cell carcinoma

Squamous cell carcinoma an extension of abnormal epithelial cells through the basement membrane to gain access to the conjunctival stroma. Clinically, invasive squamous cell carcinoma is generally larger and more elevated than CIN (Fig. 10). Leukoplakia may be variable. Uncommonly, lesions that are untreated or incompletely excised can invade through the corneoscleral lamella into the anterior chamber of the eye or they can transgress the orbital septum and invade the soft tissues of the orbit adjacent to the globe.<sup>[29,85]</sup> A rare variant of squamous cell carcinoma of the conjunctiva is the mucoepidermoid carcinoma. Clinically, this variant occurs in older patients and has a yellow globular cystic component due to the presence of abundant mucous-secreting cells within cysts. It tends to be more aggressive than the standard squamous cell carcinoma and, therefore, deserves wider excision and closer follow-up.<sup>[2,25]</sup> The spindle cell variant of squamous cell carcinoma is likewise aggressive.<sup>[7]</sup>

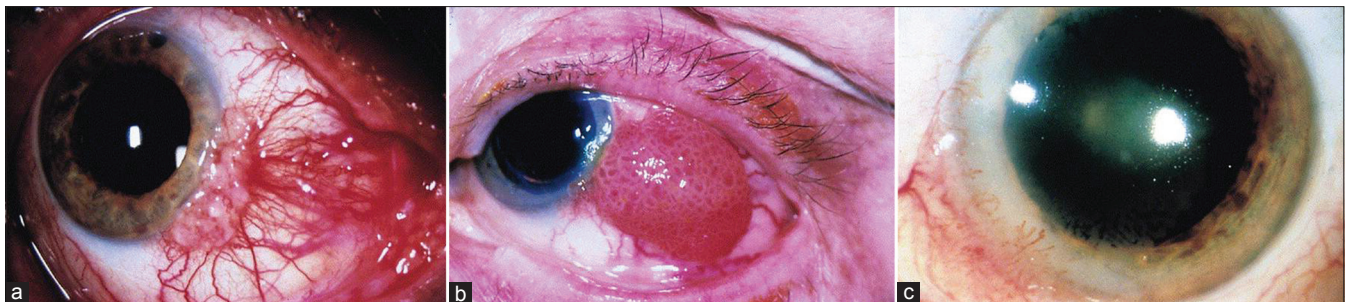
Histopathologically, invasive squamous cell carcinoma is characterized by malignant squamous cells that have violated



**Figure 8:** Epibulbar inclusion cyst with thick mucous from conjunctival glands



**Figure 9:** Conjunctival intraepithelial neoplasia (CIN; carcinoma-in-situ) with corneal involvement, displaying leukoplakia on both the conjunctiva and cornea



**Figure 10:** Invasive squamous cell carcinoma of the conjunctiva. (a) Gelatinous limbal squamous cell carcinoma. (b) Nodular squamous cell carcinoma. (c) Flat diffuse squamous cell carcinoma of the cornea



the basement membrane and have grown in sheets or cords into the stromal tissue. As mentioned above, the mucoepidermoid variant contains mucous-secreting cells that often produce mucous-containing cysts within the lesion. Even though the cells of invasive squamous cell carcinoma gain access to the blood vessels and lymphatic channels, regional and distant metastases are both rather uncommon. Patients who are medically immunosuppressed for organ transplantation or those with human immunodeficiency virus are at particular risk to develop conjunctival squamous cell carcinoma. In these cases, the risk for life-threatening metastatic disease is greater.<sup>[51]</sup>

The management of squamous cell carcinoma of the conjunctiva varies with the extent of the lesion. In general, the management of lesions in the limbal area involves alcohol epitheliectomy for the corneal component and partial lamellar scleroconjunctivectomy with wide margins for the conjunctival component followed by freeze-thaw cryotherapy to the remaining adjacent bulbar conjunctiva, similar to the method used for limbal conjunctival melanoma.<sup>[78-80]</sup> In some cases, microscopically controlled excision (Mohs surgery) is performed at the time of surgery to ensure tumor-free margins.<sup>[3]</sup> Those tumors in the forniceal region can be managed by wide local resection and cryotherapy. In cases where excessive conjunctiva is sacrificed, a mucous membrane graft or amniotic membrane graft may be employed for reconstruction. In all cases, the full conjunctival component along with the underlying Tenon's fascia should be excised using the no touch technique as mentioned previously. A thin lamella of underlying sclera should be removed with the tumor for those in the limbal region where the tumor is adherent to the globe. The surgical management of conjunctival squamous cell carcinoma is similar to the management of conjunctival melanoma and is discussed further in the subsequent section on melanoma.

For those patients with extensive tumors or those tumors that are recurrent, especially those with extensive corneal component, treatment with topical mitomycin C, 5-fluorouracil, or interferon is advised.<sup>[19,20,32,38,56,96,97]</sup> We generally use

mitomycin C for two cycles with close monitoring of the patient [Table 1].<sup>[56]</sup>

## Melanocytic Tumors

There are several lesions that arise from the melanocytes of the conjunctiva and episclera [Table 2]. The most important ones include nevus, racial melanosis, primary acquired melanosis, and malignant melanoma. Ocular melanocytosis should be included in this discussion as its scleral pigmentation can masquerade as conjunctival pigmentation.

### Nevus

The circumscribed nevus is the most common melanocytic tumor of the conjunctiva. It generally becomes clinically apparent in the first or second decade of life as a discrete variably pigmented, slightly elevated, sessile lesion that usually contains fine clear cysts on slit-lamp biomicroscopy (Fig. 11).<sup>[21,54]</sup> It is typically located in the interpalpebral bulbar conjunctiva near the limbus and remains relatively stationary throughout life with less than 1% risk for transformation into malignant melanoma.<sup>[21,54]</sup> The interpalpebral location is so classic that one should doubt the diagnosis of nevus if a patient presents with a forniceal or palpebral pigment mass and suspect primary acquired melanosis, racial melanosis, or malignant melanoma. Over time, a nevus can become more pigmented and the previously inapparent nonpigmented portions can acquire pigment, simulating growth.

Histopathologically, a conjunctival nevus is composed of nests of benign melanocytes in the stroma near the basal layers of the epithelium.<sup>[9]</sup> Like cutaneous nevus, it can be junctional, compound, or deep. The best management is usually periodic observation with photographic comparison and if growth is documented then local excision of the lesion should be considered. In some cases, excision for cosmetic reasons is desired. At the time of excision, the entire mass is removed using the no touch technique and, if it is adherent to the globe, then a thin lamella of underlying sclera is removed intact with the tumor.<sup>[78]</sup> Standard double freeze-thaw cryotherapy is applied to the remaining conjunctival margins.

**Table 2: Differential Diagnosis of Pigmented Epibulbar Lesions**

| Condition                        | Anatomical Location                      | Color           | Depth      | Margins      | Laterality                        | Other Features  | Progression   |
|----------------------------------|--|-----------------|------------|--------------|-----------------------------------|---|---|
| Nevus                            | Interpalpebral limbus usually            | Brown or yellow | Stroma     | Well defined | Unilateral                        | Cysts   | <1% progress to conjunctival melanoma   |
| Racial melanosis                 | Limbus bulbar palpebral conjunctiva      | Brown           | Epithelium | Ill defined  | Bilateral                         | Flat, no cysts  | Very rare progression to conjunctival melanoma                                    |
| Ocular melanocytosis             | Bulbar conjunctiva                       | Gray            | Episclera  | Ill defined  | Unilateral more so than bilateral | Congenital, usually 2 mm from limbus, often with periocular skin pigmentation | <1% progress to uveal melanoma  |
| Primary acquired melanosis (PAM) | Anywhere, but usually bulbar conjunctiva | Brown           | Epithelium | Ill defined  | Unilateral                        | Flat, no cysts  | Progresses to conjunctival melanoma in nearly 50% cases that show cellular atypia |
| Malignant melanoma               | Anywhere                                 | Brown or pink   | Stroma     | Well defined | Unilateral                        | Vascular nodule, dilated feeder vessels, may be non-pigmented                 | 32% develop metastasis by 15 years  |

See Figure 11, Figure 12, Figure 13, Figure 14, Figure 15 for clinical illustrations

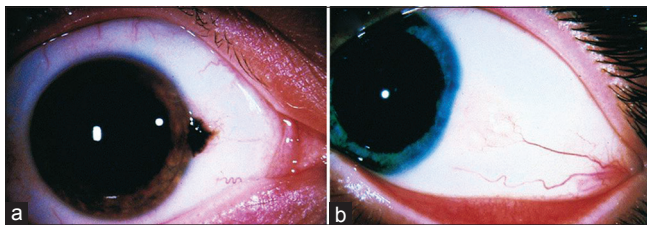
These precautions are employed to prevent recurrence of the nevus and also to prevent recurrence should the lesion prove to be a melanoma.

### Racial melanosis

Racial melanosis is a relatively common, bilateral condition of flat conjunctival pigmentation found in darkly pigmented individuals. This pigment is generally present at the limbus, often for 360°, and a variable amount of this pigment can be noted on the limbal cornea and bulbar conjunctiva (Fig. 12). Uncommonly, this pigment involves the fornix and rarely the palpebral conjunctiva. This pigmentation can occasionally be mottled with a patchy appearance. It is extremely rare for conjunctival melanoma to arise from racial melanosis. Histopathologically, the pigmented cells are benign melanocytes located in the basal layer of the epithelium. The recommended management is periodic observation.

### Ocular melanocytosis

Ocular melanocytosis is a congenital pigmentary condition of the periocular skin, sclera, orbit, meninges, and soft palate. Typically, there is no conjunctival pigment. However, this condition is commonly confused with primary acquired melanosis because of their similar appearance. In ocular melanocytosis, flat, gray-brown pigment scattered posterior to the limbus on the sclera is visualized through the thin overlying conjunctival tissue (Fig. 13). The entire uvea is also generally affected by similar increased pigment. This condition imparts a 1 in 400 risk for the development of uveal melanoma and not conjunctival melanoma.<sup>[87]</sup> Affected patients should be followed once or twice yearly for the development of uveal, orbital, or meningeal melanoma.



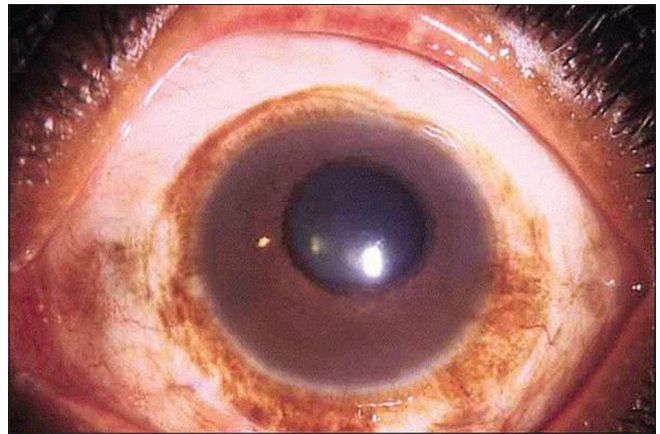
**Figure 11:** Conjunctival nevus. (a) Pigmented conjunctival nevus. (b) Nonpigmented conjunctival nevus

### Primary acquired melanosis (PAM)

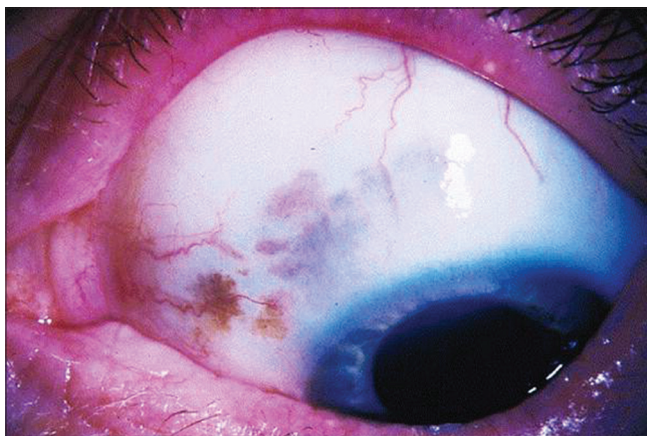
Primary acquired melanosis is an important benign conjunctival pigmented condition that can give rise to conjunctival melanoma. In contrast to conjunctival nevus, it is acquired in middle age and appears diffuse, patchy, flat, and noncystic [Fig. 14]. In contrast to ocular melanocytosis, the pigment is acquired, located within the conjunctiva, and appears brown, not gray, in color. The pigmentation can wax and wane over time.<sup>[17,18,53]</sup> In contrast to racial melanosis, PAM generally is found in fair-skinned individuals as a unilateral patchy condition.<sup>[22]</sup>

Histopathologically, PAM is characterized by the presence of abnormal melanocytes near the basal layer of the epithelium. Pathologists should attempt to classify the melanocytes as having atypia or no atypia based on nuclear features and growth pattern.<sup>[17,18]</sup> PAM with atypia carries nearly 50% risk for ultimate evolution into malignant melanoma whereas PAM without atypia carries nearly 0% risk for melanoma development [Table 3].<sup>[17,18]</sup>

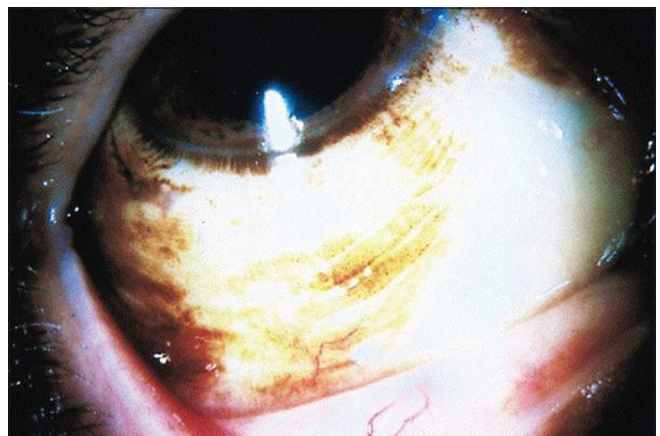
The management of PAM depends on the extent of involvement and the association with melanoma. If there is only a small region of PAM, occupying less than three clock hours of the conjunctiva, then periodic observation or complete



**Figure 12:** Racial melanosis found bilaterally in patient with dark skin complexion



**Figure 13:** Ocular melanocytosis with episcleral gray pigment, heavy uveal pigment, and little conjunctival pigment



**Figure 14:** Primary acquired melanosis of the conjunctiva, showing the characteristic irregular patchy flat pigmentation

excisional biopsy and cryotherapy are options.<sup>[78]</sup> If the PAM occupies more than three clock hours, then incisional map biopsy of all four quadrants is warranted, followed by double freeze-thaw cryotherapy to all affected pigmented sites. If the patient has a history of previous or current conjunctival or cutaneous melanoma or if there are areas of nodularity or vascularity within the presumed PAM that are suspicious for melanoma, then a more aggressive approach is warranted with complete excisional biopsy of the suspicious areas using the no touch technique as described previously. Additional small incisional map biopsies should be performed in the regions of flat PAM and even in the apparently uninvolved quadrants of the bulbar conjunctiva to determine if there are melanocytes with atypia. Cryotherapy should be applied to all remaining pigmented areas. We manage patients who have PAM associated with melanoma more aggressively than those with PAM alone. If there is recurrent PAM on follow-up, prompt excisional biopsy and cryotherapy in the operating room or in the outpatient clinic setting is provided. Topical mitomycin C can also be beneficial, especially if there is recurrent corneal PAM; however, mitomycin C is not as effective for PAM as it is for squamous epithelial neoplasia.

### Malignant melanoma

Malignant melanoma of the conjunctiva most commonly arises from PAM, but it can also arise from a pre-existing nevus or de novo.<sup>[50,64]</sup> It typically arises in adults at a median age of 62 years, but rare cases of conjunctival melanoma in children have been recognized.<sup>[64,91]</sup> Conjunctival melanoma shows considerable clinical variability. It is generally a pigmented or tan, elevated conjunctival lesion that can be located on the limbal, bulbar, forniceal, or palpebral conjunctiva (Fig. 15). Occasionally, the tumor shows predominance on the cornea, despite origin from the conjunctiva.<sup>[93]</sup> Often prominent feeder vessels and surrounding flat PAM are present. Conjunctival melanoma can show both local tumor recurrence and distant

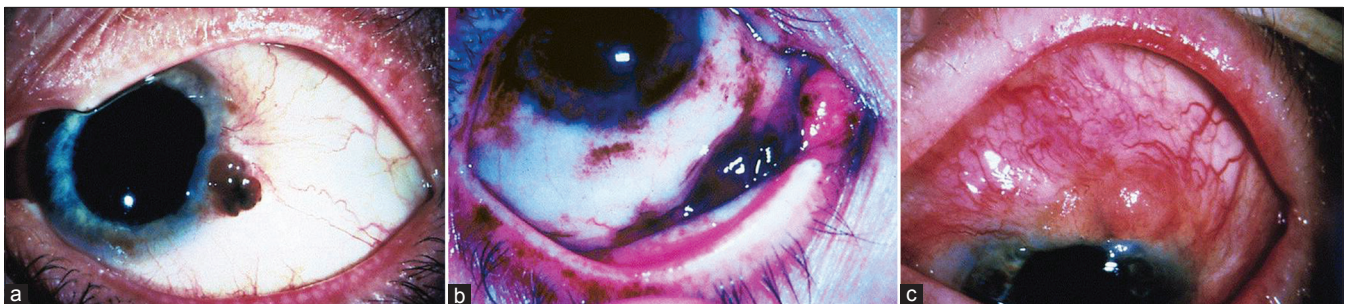
metastasis (Tables 4-6).<sup>[40,41,50,64]</sup> Multiple recurrences, especially those that occur within the orbit, frequently necessitate orbital exenteration.<sup>[40,64,84]</sup> Metastases to ipsilateral facial lymph nodes, brain, lung, and liver are the most common sites.<sup>[15,64]</sup> Histopathologically, conjunctival melanoma is composed of variably pigmented malignant melanocytes within the conjunctival stroma. There may be microscopic evidence of PAM or a nevus.

The management of conjunctival melanoma varies with the extent of the lesion.<sup>[52]</sup> This malignancy is particularly difficult to treat. Despite excellent microscopic excision of the mass, further disease can develop from associated PAM in 26% of patients by 5 years and 65% of patients by 15 years follow-up [Table 4].<sup>[64]</sup> Classic limbal tumors are removed by absolute alcohol epitheliectomy for the flat corneal component and wide no touch technique, partial lamellar scleroconjunctivectomy with 4 mm margins followed by double freeze-thaw cryotherapy for the conjunctival portion. Larger lesions that extend into the forniceal region or orbit may require more extensive excision, always with tumor free margins encapsulating the tumor and with no touch, dry technique (Fig. 1). Closure is achieved by primary apposition of conjunctiva or with conjunctival rotational flaps, mucous membrane graft from the opposite eye or buccal mucosa, or amniotic membrane transplantation.<sup>[60]</sup> Often, fornix deepening sutures or a symblepharon ring is required to reform the fornix. Lesions that extend into the globe may require a modified enucleation and those that extend into the orbit may require orbital exenteration as described above.<sup>[18,64,81,84]</sup> Paridaens and associates found that early exenteration did not improve life prognosis.<sup>[40]</sup> Shields and associates found tumor related death occurred in 7% of patients at 5 years and 13% at 8 years.<sup>[64]</sup> The risk factors for death using multivariate analysis included initial symptoms (lump) ( $p = 0.004$ ) and pathology findings (de novo melanoma without primary acquired melanosis) ( $p = 0.05$ ). The technique of initial surgery (using complete excisional biopsy

**Table 3: Histopathologic Classification of Primary Acquired Melanosis of the Conjunctiva and Risks for Evolution into Conjunctival Melanoma**

| General Classification  | Risk for Development of Conjunctival Melanoma |
|---|---|
| Primary acquired melanosis without atypia   | 0%  |
| Primary acquired melanosis with atypia  | 46%   |
| If atypical melanocytes in the epithelium located in other than the basal layer of the epithelium | 90%   |
| If atypical melanocytes showing epithelioid cellular features (abundant cytoplasm)                | 75%   |

From Folberg *et al.*<sup>17</sup> x17. Folberg, R., McLean, I.W., and Zimmerman, L.E. Primary acquired melanosis of the conjunctiva. *Hum Pathol.* 1985; 16: 136-143



**Figure 15:** Conjunctival melanoma. (a) Pigmented melanoma that arose de novo. (b) Pigmented melanoma that arose from primary acquired melanosis (left arrow). Note the flat extension of the melanoma into the cornea. (c) Nonpigmented melanoma, recurrent following previous excisions

with the no touch technique combined with cryotherapy to remaining tumor free margins) was shown to be an important factor in preventing eventual tumor recurrence ( $p = 0.07$ ), metastasis ( $p = 0.03$ ), and death ( $p = 0.006$ ) in the univariate analysis, but did not reach significance in the multivariate analysis.<sup>[64]</sup>

**Conditions that can simulate conjunctival melanocytic tumors**

There are several benign, non-neoplastic conditions that can resemble conjunctival PAM or melanoma and these include pingueculum, pterygium, Axenfeld’s nerve loops at the site of a scleral emissarial canal, mascara deposition in the inferior fornix, silver deposition on the entire conjunctival surface in patients who have used argyrol eyedrops, gunpowder deposition in patients exposed to gunpowder explosions, adrenochrome pigment in the inferior fornix in patients using epinephrine eyedrops, hemorrhagic conjunctival cyst following previous surgery, pigmented cells trapped within a non-melanocytic tumor (fellow travelers),<sup>[83]</sup> ochronosis pigmentation at the site of muscle insertion and in pingueculum in patients with alkaptonuria, and calcified Cogan’s scleral plaque at the horizontal rectus

**Table 4: Risks for Local Tumor Recurrence, Exenteration, Metastasis, and Death in Patients with Conjunctival Melanoma**

| Outcome          | Length of follow-up <sup>a</sup> |           |           |
|------------------|----------------------------------|-----------|-----------|
|                  | ±5 years                         | ±10 years | ±15 years |
| Recurrence (%)   | 26                               | 51        | 65        |
| Exenteration (%) | 8                                | 16        | 32        |
| Metastasis (%)   | 16                               | 26        | 32        |
| Death (%)        | 7                                | 13        | na        |

<sup>a</sup>Kaplan Meier life table analysis. na=not available. From Shields *et al.*<sup>[64]</sup> x 64. Shields, C.L., Shields, J.A., Gunduz, K. *et al.* Conjunctival melanoma: risk factors for recurrence, exenteration, metastasis, and death in 150 consecutive patients. *Arch Ophthalmol.* 2000; 118: 1497-1507

**Table 5: Clinical Factors Predictive of Local Tumor Recurrence Following Resection of Conjunctival Melanoma**

| Factor   | P    | Relative Risk |
|--|------|---------------|
| Tumor location extralimbal                               | 0.01 | 2.3           |
| Tumor extending to surgical margin (histopathologically) | 0.02 | 2.9           |

From Shields *et al.*<sup>[64]</sup> x 64. Shields, C.L., Shields, J.A., Gunduz, K. *et al.* Conjunctival melanoma: risk factors for recurrence, exenteration, metastasis, and death in 150 consecutive patients. *Arch Ophthalmol.* 2000; 118: 1497-1507

**Table 6: Clinical Factors Predictive of Tumor Metastasis from Conjunctival Melanoma**

| Factor   | P     | Relative Risk |
|--|-------|---------------|
| Tumor extending to surgical margin (histopathologically) | 0.005 | 5.7           |
| Tumor location extralimbal                               | 0.03  | 3.1           |

From Shields *et al.*<sup>[64]</sup> x 64. Shields, C.L., Shields, J.A., Gunduz, K. *et al.* Conjunctival melanoma: risk factors for recurrence, exenteration, metastasis, and death in 150 consecutive patients. *Arch Ophthalmol.* 2000; 118: 1497-1507

muscle insertions in older adults.<sup>[76]</sup> Understanding and recognition of these pseudomelanomas should be achieved by clinicians managing patients with conjunctival malignancies.

**Vascular Tumors**

**Pyogenic granuloma**

Pyogenic granuloma is a proliferative fibrovascular response to prior tissue insult by inflammation, surgery, or nonsurgical trauma. It is sometimes classified as a polypoid form of acquired capillary hemangioma.<sup>[16]</sup> It appears clinically as an elevated red mass, often with a florid blood supply. Microscopically, it is composed of granulation tissue with chronic inflammatory cells and numerous small caliber blood vessels (Fig. 16). Because the lesion is rarely pyogenic nor granulomatous, the term “pyogenic granuloma” may be a misnomer. Pyogenic granuloma will sometimes respond to topical corticosteroids but many cases ultimately require surgical excision. In bothersome recurrent cases, low-dose plaque radiotherapy can be applied.<sup>[26]</sup>

**Capillary hemangioma**

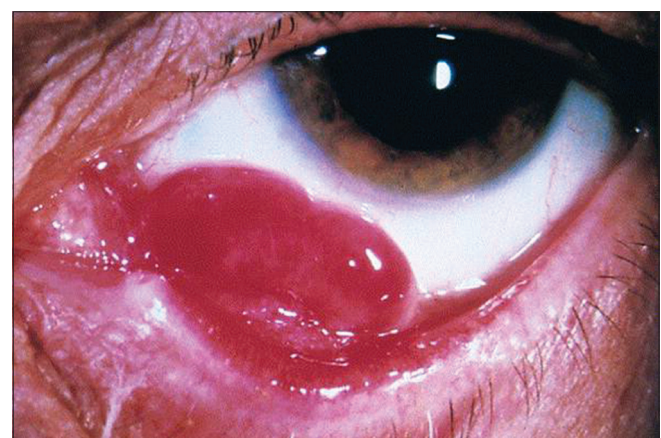Capillary hemangioma of the conjunctiva generally presents in infancy, several weeks following birth, as a red stromal mass, sometimes associated with cutaneous or orbital capillary hemangioma (Fig. 17). Similar to its cutaneous counterpart, the conjunctival mass might enlarge over several months and then spontaneously involute. Management includes observation most commonly, but surgical resection or local or systemic prednisone can be employed.

**Cavernous hemangioma**

Cavernous hemangioma of the conjunctiva is rare.<sup>[94]</sup> This benign tumor appears as a red or blue lesion usually in the deep stroma in young children (Fig. 18). It may be similar to the orbital cavernous hemangioma that is generally diagnosed in young adults. It can be managed by local resection.

**Racemose hemangioma**

Occasionally, dilated arteriovenous communication without intervening capillary bed (racemose hemangioma) is found in the conjunctiva. This appears as a loop or neatly wound monolayer of a dilated, noncrossing vessel in the stroma with no evident stimulus or planned direction. It can remain stable for years and is generally monitored conservatively. It is important to rule out Wyburn–Mason syndrome in these cases.



**Figure 16: Pyogenic granuloma**

### Lymphangioma

Conjunctival lymphangioma can occur as an isolated conjunctival lesion or, more often, it represents a superficial component of a deeper diffuse orbital lymphangioma.<sup>[95]</sup> It usually becomes clinically apparent in the first decade of life and appears as a multilobulated mass containing variable-sized clear dilated cystic channels (Fig. 19). In most instances, one sees blood in many of the cystic spaces. These have been called "chocolate cysts." The treatment of conjunctival lymphangioma is often extremely difficult because surgical resection or radiotherapy cannot completely eradicate the mass.

### Varix

Varix is a venous malformation that can be found in the orbit and rarely the conjunctiva. It is a mass of dilated venous channels that can enlarge with Valsalva maneuver. Some authorities believe that this condition is in the spectrum of lymphangioma. Treatment involves cautious observation. If clotted and painful, cold compresses and aspirin may be useful. Surgical resection should be cautiously employed due to the risk for prolonged bleeding at surgery.<sup>[71]</sup>

### Hemangiopericytoma

Hemangiopericytoma is a tumor composed of the pericytes that surround blood vessels.<sup>[24]</sup> It can show both benign and malignant cytological features. It appears as a red conjunctival

mass originating from the stroma. Wide surgical resection with tumor-free margins is advised.

### Kaposi's sarcoma

Kaposi's sarcoma is best known as a cutaneous malignancy that occurs in elderly immunosuppressed patients. With the advent of acquired immune deficiency syndrome (AIDS), this tumor has become more common and often affects mucous membranes, including conjunctiva. Clinically, it appears as one or more reddish vascular masses that may resemble a hemorrhagic conjunctivitis (Fig. 20). It is moderately responsive to chemotherapy and markedly responsive to low dose radiotherapy.<sup>[69]</sup>

### Fibrous Tumors

#### Fibroma

Fibroma is a rare conjunctival tumor that appears as a white stromal mass, either unifocal or multifocal.<sup>[31]</sup> Surgical resection is advised.

#### Fibrous histiocytoma

Fibrous histiocytoma is a rare mass of the conjunctiva and is comprised of fibroblasts and histiocytes. Clinically and histopathologically it resembles many other amelanotic stromal tumors. In the conjunctiva it can be benign, locally invasive, or malignant. Wide excision with tumor-free margins is advised.

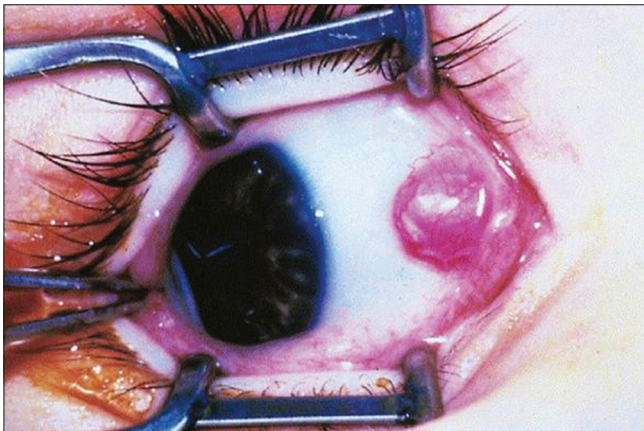


Figure 17: Capillary hemangioma of the conjunctiva in a newborn infant

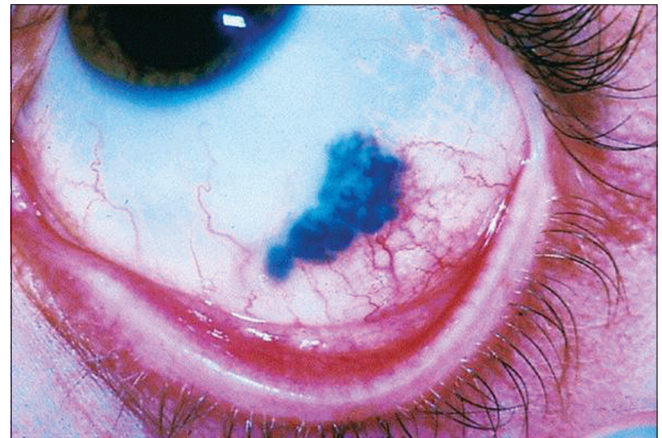


Figure 18: Cavernous hemangioma of the conjunctiva in a young child

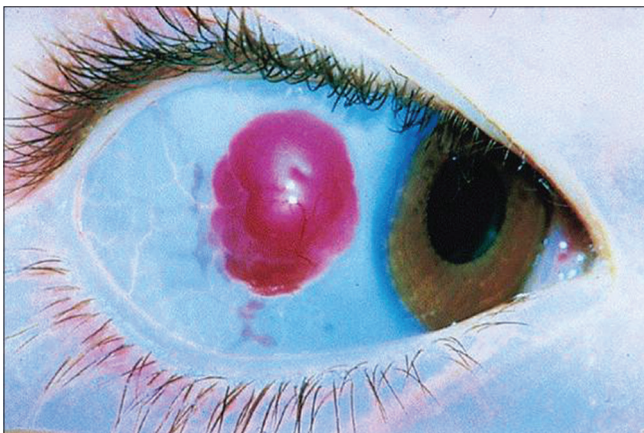


Figure 19: Lymphangioma of the conjunctiva

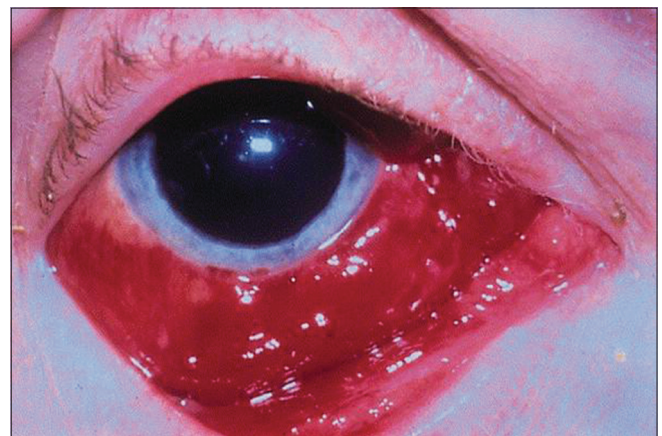

Figure 20: Kaposi's sarcoma of the conjunctiva with typical surrounding hemorrhage

### Nodular fasciitis

Nodular fasciitis is a benign proliferation of connective tissue that most commonly occurs in the skin and less commonly in the eyelid, orbit, and conjunctiva. Clinically and histopathologically it can resemble fibrosarcoma. The lesion appears as a solitary white mass in Tenon's fascia. Complete excision is advised as the lesion can recur.

### Neural Tumors

Neural tumors of the conjunctiva are rare. They tend to manifest a more yellow appearance than the fibrous tumors.

#### Neurofibroma

Neurofibroma can occur in the conjunctiva as a solitary mass or as a diffuse or plexiform variety. The former is not usually associated with systemic conditions and the latter is generally a part of von Recklinghausen's neurofibromatosis.<sup>[58,75]</sup> The solitary tumor is a slowly enlarging elevated stromal mass that is best managed by complete surgical resection. The plexiform type is more difficult to surgically excise and debulking procedures are often necessary.

#### Neurilemoma

Neurilemoma, also known as schwannoma, is a benign proliferation of Schwann cells that surround the peripheral nerves. This tumor more commonly arises in the orbit, but there are reports of similar rare tumor in the conjunctiva.<sup>[44]</sup> Clinically, this lesion is a yellowish-pink, nodular mass in the stroma. Complete excision is warranted to minimize recurrence.

#### Granular cell tumor

Granular cell tumor is a rare tumor and of disputed origin, but currently, most authorities speculate that it is of Schwann cell origin.<sup>[76]</sup> This benign tumor clinically appears smooth, vascular, and pink, and is located in the stroma or within Tenon's fascia. Histopathologically, it is comprised of large round cells with pronounced granularity to the cytoplasm. Complete excision is advised.

### Histiocytic Tumors

#### Xanthoma

Xanthoma most often occurs within the cutaneous dermis, near extensor surfaces and its location on the conjunctiva is exceptionally rare. Conjunctival xanthoma appears as a yellow subepithelial smooth mass affecting one or both epibulbar surfaces. Bilateral conjunctival involvement has been found in a condition termed xanthoma disseminatum. Histopathologically, subepithelial infiltrate of lipidized histiocytes, eosinophils, and Touton giant cells are seen.

#### Juvenile xanthogranuloma

Juvenile xanthogranuloma is a relatively common cutaneous condition that presents as painless, pink skin papules with spontaneous resolution, generally in children under the age of 2 years. Rarely, conjunctival, orbital, and intraocular involvement is noted. In the conjunctiva, the mass appears as an orange-pink stromal mass, typically in young adults (Fig. 21). If the classic skin lesions are noted, the diagnosis is established clinically and treatment with observation or topical steroid ointment is provided. Otherwise, biopsy is suggested and recognition of the typical histopathologic features of histiocytes admixed with Touton's giant cells confirms the diagnosis.

### Reticulohistiocytoma

Reticulohistiocytoma is a rare tumor, often found as part of a systemic multicentric reticulohistiocytosis. Clinically, the tumor appears as a pink, vascular limbal mass in an adult. Histopathologically, it is comprised of large histiocytes with granular cytoplasm.<sup>[13]</sup>

### Myxoid Tumors

#### Myxoma

Myxoma is a rare conjunctival tumor that appears as an orange-pink mass within the stroma. The tumors are slow growing, freely movable solitary lesions located usually in the temporal bulbar conjunctiva. Histologically, they are hypocellular and were composed of stellate and spindle-shaped cells interspersed in a loose stroma.<sup>[43,68,77]</sup>

### Myogenic Tumors

#### Rhabdomyosarcoma

Ophthalmic rhabdomyosarcoma is generally regarded as a primary orbital tumor; however, it can occur primarily in the conjunctiva and even within the globe.<sup>[66]</sup> Conjunctival rhabdomyosarcoma appears as a pink, vascular mass with rapid growth, usually over 1 to 2 months. Complete excisional biopsy is advised and adjunctive therapy with chemotherapy and possibly radiotherapy is warranted depending on many factors.<sup>[66]</sup>

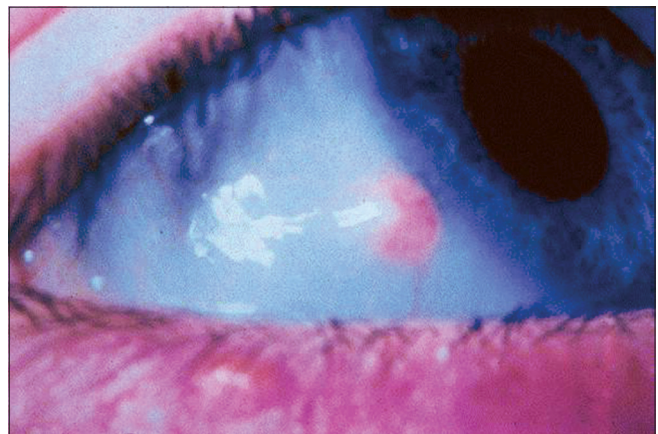
### Lipomatous Tumors

#### Lipoma

Conjunctival lipoma is quite rare and generally is found in adults as a yellowish-pink stromal mass.<sup>[68,77]</sup> They are generally of pleomorphic type with large lipid vacuoles surrounded by stellate cells.

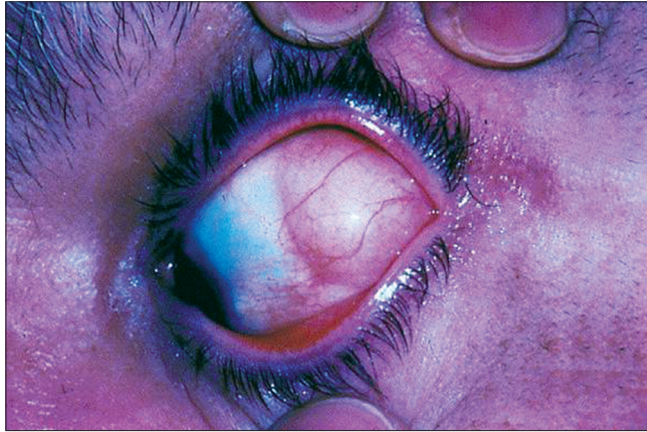#### Herniated orbital fat

Occasionally, orbital fat presents in the conjunctiva as a herniation from the superotemporal orbit. The condition is often bilateral and represents deficiency in the orbital connective tissue to maintain the proper location of the normal orbital fat. Clinically, the mass is deep to Tenon's fascia and is most prominent on inferonasal gaze (Fig. 22). Digital reposition of the fat into the orbit can be performed, but is only temporary. Management

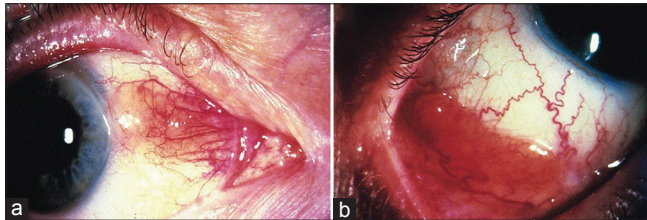


**Figure 21:** Juvenile xanthogranuloma of the conjunctiva in a child

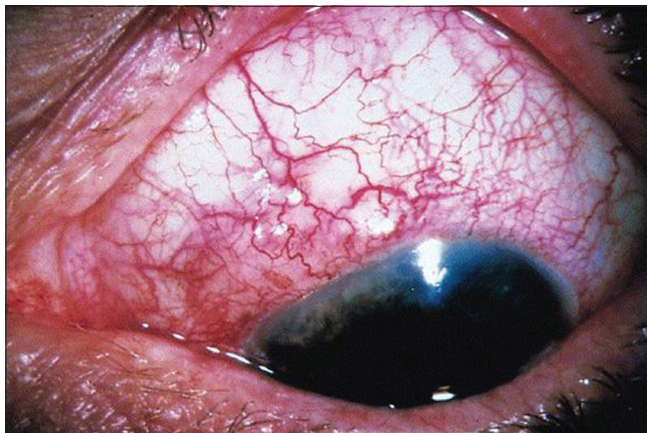
is observation, unless the condition causes symptoms of dry eye from eyelid malposition. In these cases, resection of the herniated fat and resuspension of the orbit position of the fat is advised. Histopathologically, the tissue comprises large lipid



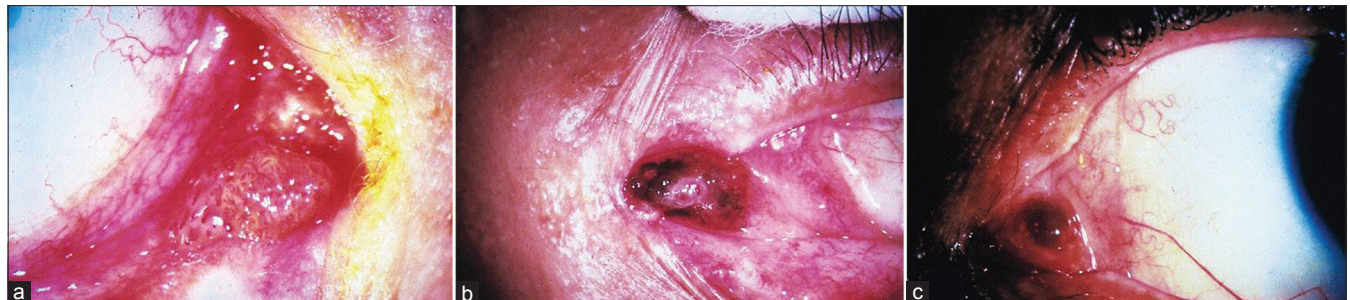**Figure 22:** Herniated orbital fat



**Figure 23:** Conjunctival lymphoma. (a) Limbal tumor. (b) Forniceal tumor



**Figure 24:** Metastatic breast carcinoma to the conjunctiva



**Figure 25:** Caruncular tumors. (a) Papilloma of the caruncle. (b) Nevus of the caruncle. (c) Oncocyoma of the caruncle

cells. Daniel and coauthors recently described six patients with typical herniated orbital fat that proved on histopathology to have pleomorphic lipoma, with large pleomorphic cells within the adipose tissue arranged in a floret-like pattern.<sup>[12]</sup> They noted the clinical overlap between these two conditions.

### Liposarcoma

Liposarcoma of the conjunctiva has been rarely recognized and shows clinical features similar to lipoma. Histopathologically, neoplastic stellate lipid cells and signet-ring type cells have been observed.<sup>[77]</sup>

### Lymphoid Tumors

Lymphoid tumors can occur in the conjunctiva as isolated lesions or they can be a manifestation of systemic lymphoma.<sup>[6,8,34,37,61]</sup> Clinically, the lesion appears as a diffuse, slightly elevated pink mass located in the stroma or deep to Tenon's fascia, most commonly in the fornical region (Fig. 23). This appearance is similar to that of smoked salmon; hence it is termed the "salmon patch."<sup>[61]</sup> It is not usually possible to differentiate clinically between a benign and malignant lymphoid tumor. Therefore, biopsy is necessary to establish the diagnosis and a systemic evaluation should be done in all affected patients to exclude the presence of systemic lymphoma [Table 7]. Histopathologically, sheets of lymphocytes are found and classified as reactive lymphoid hyperplasia or malignant lymphoma. Most are B cell lymphoma (non-Hodgkin's type). Rarely, T cell lymphoma is noted.<sup>[62]</sup> Treatment of the conjunctival lesion should include chemotherapy if the patient has systemic lymphoma or external beam irradiation (2,000–4,000 cGy) if the lesion is localized to the conjunctiva. Other options include excisional biopsy and cryotherapy,<sup>[14]</sup> local interferon injections, or observation.

### Leukemia

Leukemia generally manifests in the ocular region as hemorrhages from associated anemia and thrombocytopenia rather than leukemic infiltration.<sup>[46]</sup> However, leukemic infiltration can be found with chronic lymphocytic leukemia. In these cases, the tumor appears as a pink smooth mass within the conjunctival stroma either at the limbus or the fornix, similar to a lymphoid tumor. Biopsy reveals sheets of large leukemic cells. Treatment of the systemic condition is advised with secondary resolution of the conjunctival infiltration.

### Metastatic Tumors

Metastatic tumors rarely occur in the conjunctiva but conjunctival metastasis can occur from breast carcinoma,

cutaneous melanoma, and other primary tumors.<sup>[33]</sup> Metastatic carcinoma appears as one or more fleshy pink vascularized conjunctival stromal tumors (Fig. 24). Metastatic melanoma to the conjunctiva usually is pigmented.<sup>[33]</sup>

### Secondary Conjunctival Involvement from Adjacent Tumors

The conjunctiva can be secondarily involved by tumors of adjacent structures, particularly by direct extension from tumors of the eyelids. The most important tumor to exhibit this behavior is sebaceous gland carcinoma of the eyelid.<sup>[5,28]</sup> This tumor can exhibit pagetoid invasion and extend directly into the conjunctival epithelium. This can result in a clinical picture compatible with chronic unilateral blepharoconjunctivitis. Uveal melanoma in the ciliary body region can extend extrasclerally into the subconjunctival tissues, simulating a primary conjunctival tumor. Rhabdomyosarcoma of the orbit, a tumor typically found in children, occasionally presents first with its conjunctival component before the mass is discovered in the orbit.<sup>[66,73]</sup>

### Caruncular Tumors and Cysts

The caruncle is a unique anatomic structure that contains elements of both conjunctiva and skin. The tumors and related lesions that develop in the caruncle are similar to those that occur in mucous membranes and cutaneous structures. By histopathologic analysis, 95% of caruncular tumors are benign and 5% are malignant.<sup>[35]</sup> The most common lesions include papilloma and nevus [Table 8] (Fig. 25).<sup>[35,67]</sup> Other caruncular lesions include pyogenic granuloma, inclusion cyst, sebaceous hyperplasia, and sebaceous adenoma, and oncocytoma.<sup>[59]</sup> Malignant tumors such as squamous cell carcinoma, melanoma, lymphoma, and sebaceous carcinoma are relatively rare in the caruncle. The oncocytoma is a benign tumor that occurs more commonly in the lacrimal or salivary glands. In the caruncle it probably arises from accessory lacrimal gland tissue and often has a blue cystic appearance (Fig. 25). The treatment of most caruncular masses is either observation or local resection, depending on the final diagnosis.

### Miscellaneous Lesions that can Simulate Conjunctival Neoplasms

A number of non-neoplastic conditions can simulate neoplasms. These include pingueculum, pterygium, foreign body, inflammatory granuloma, amyloidosis, and others.<sup>[76]</sup> In most instance, the history and clinical findings should make the diagnosis obvious. In some instances, however, excision of the mass may be necessary in order to exclude a neoplasm.

**Table 7: Risks for the Development of Systemic Lymphoma in Patients who Present with Conjunctival Lymphoid Infiltrate and No Sign of Systemic Lymphoma**

|   | Development of Systemic Lymphoma |          |           |
|---|----------------------------------|----------|-----------|
|   | ±1 years                         | ±5 years | ±10 years |
| Generally, if conjunctival lymphoid tumor (%) | 7                                | 15       | 28        |
| Specifically, if conjunctival lymphoma (%)    | 12                               | 38       | 79        |

From Shields *et al.*<sup>61</sup> x 61. Shields, C.L., Shields, J.A., Carvalho, C. *et al.* Conjunctival lymphoid tumors: clinical analysis of 117 cases and relationship to systemic lymphoma. *Ophthalmology*. 2001; 108: 979-984

### Method of Literature Search

A comprehensive literature search over the past 30 years was derived from PubMed using general search words *conjunctiva, cornea, caruncle, tumor, neoplasia, cancer, and malignancy*. Additional search words were input for each of the 47 specific diagnostic entities listed in the outline from *dermoid* to *liposarcoma* to *caruncle tumor*. The search words *conjunctiva tumor* yielded 77 pages of 1,536 references. The search words *conjunctiva neoplasia* yielded 74 pages of 1,473 references, *conjunctiva melanoma* yielded 19 pages of 364 references, and *conjunctiva squamous cell carcinoma* produced 13 pages of 249 references. Additional references were gathered from published articles that provided a literature review of a topic. References used in this report included those that represented the first or second report in the literature of an entity or treatment of an entity, those that represented substantial case series of certain entities, and those that were

**Table 8: Types and Frequency of Tumors of the Caruncle: Comparison of Two Major Survey**

| Lesions (%)                   | Luthra <i>et al.</i> <sup>35</sup><br>(n=112) | Shields <i>et al.</i> <sup>67</sup> (n=57) |
|-------------------------------|---|--|
| Papilloma                     | 13  | 32   |
| Nevus                         | 43  | 24   |
| Pyogenic granuloma            | 3   | 9  |
| Epithelial inclusion cyst     | 4   | 7  |
| Chronic inflammation          | 4   | 7  |
| Oncocytoma                    | 4   | 4  |
| Normal caruncle               | 0   | 4  |
| Sebaceous gland hyperplasia   | 8   | 2  |
| Sebaceous gland adenoma       | 0   | 2  |
| Lipogranuloma                 | 0   | 2  |
| Seborrheic keratosis          | 1   | 2  |
| Lymphangiectasia              | 0   | 2  |
| Histiocytic lymphoma          | 0   | 2  |
| Squamous cell carcinoma       | 0   | 2  |
| Basal cell carcinoma          | 0   | 2  |
| Reactive lymphoid hyperplasia | 4   | 0  |
| Foreign body granuloma        | 3   | 0  |
| Malignant melanoma            | 2   | 0  |
| Capillary hemangioma          | 2   | 0  |
| Senile keratosis              | 1   | 0  |
| Freckle                       | 1   | 0  |
| Adrenochrome pigment          | 1   | 0  |
| Cavernous hemangioma          | 1   | 0  |
| Dermoid                       | 1   | 0  |
| Granular-cell myeloblastoma   | 1   | 0  |
| Plasmacytoma                  | 1   | 0  |
| Apocrine hydrocystoma         | 1   | 0  |
| Pilar cyst                    | 1   | 0  |
| Sebaceous gland carcinoma     | 1   | 0  |
| Ectopic lacrimal gland        | 1   | 0  |

From Luthra, C.L., Doxanas, M.T., and Green, W.R. Lesions of the caruncle. A clinicopathologic study. *Surv Ophthalmol*. 1978; 23: 183-195 and Shields, C.L., Shields, J.A., White, D., and Augsburger, J.J. Types and frequency of lesions of the caruncle. *Am J Ophthalmol*. 1986; 102: 771-778



particularly well-written, well-illustrated, or recent publication. English literature articles were used and non-English articles were included if they met the above criteria.

### Financial support and sponsorship

Nil.

### Conflict of interest

There are no conflict of interest.

## References

- Anastassiou, G., Heiligenhaus, A., Bechrakis, N. *et al.* Prognostic value of clinical and histopathological parameters in conjunctival melanomas: a retrospective study. *Br J Ophthalmol.* 2002; 86: 163–167
- Brownstein, S. Mucoepidermoid carcinoma of the conjunctiva with intraocular invasion. *Ophthalmology.* 1981; 88: 1126–1130
- Buus, D.R., Tse, D.T., Folberg, R., and Buus, D.R. Microscopically controlled excision of conjunctival squamous cell carcinoma. *Am J Ophthalmol.* 1994; 117: 97–102
- Cha, S.B., Shields, C.L., Shields, J.A. *et al.* Massive precorneal extension of squamous cell carcinoma of the conjunctiva. *Cornea.* 1993; 12: 537–540
- Chao, A.N., Shields, C.L., Krema, H., and Shields, J.A. Outcome of patients with periocular sebaceous gland carcinoma with and without conjunctival intraepithelial invasion. *Ophthalmology.* 2001; 108: 1877–1883
- Cockerham, G.C. and Jakobiec, F.A. Lymphoproliferative disorders of the ocular adnexa. *Int Ophthalmol Clin.* 1997; 37: 39–59
- Cohen, B.H., Green, R., and Iliff, N.T. Spindle cell carcinoma of the conjunctiva. *Arch Ophthalmol.* 1980; 98: 1809–1813
- Coupland, S.E., Hummel, M., and Stein, H. Ocular adnexal lymphomas: five case presentations and a review of the literature. *Surv Ophthalmol.* 2002; 47: 470–490
- Crawford, J.B., Howes, E.L. Jr., and Char, D.H. Combined nevi of the conjunctiva. *Arch Ophthalmol.* 1999; 117: 1121–1127
- Cunha, R.P., Cunha, M.C., and Shields, J.A. Epibulbar tumors in childhood. A survey of 283 biopsies. *J Pediatr Ophthalmol.* 1987; 24: 249–254
- Dailey, E.B. and Lubowitz, R.M. Dermoids of the limbus and cornea. *Am J Ophthalmol.* 1962; 53: 661–665
- Daniel, C.S., Beaconsfield, M., and Rose, G.R. Pleomorphic lipoma of the orbit: a case series and review of literature. *Ophthalmology.* 2003; 110: 101–105
- Eagle, R.C. Jr., Penne, R.A., and Hneleski, I.S. Jr. Eyelid involvement in multicentric reticulohistiocytosis. *Ophthalmology.* 1995; 102: 426–430
- Eichler, M.D. and Fraunfelder, F.T. Cryotherapy for conjunctival lymphoid tumors. *Am J Ophthalmol.* 1994; 118: 463–467
- Esmaeli, B., Eicher, S., Popp, J. *et al.* Sentinel lymph node biopsy for conjunctival melanoma. *Ophthal Plast Reconstr Surg.* 2001; 17: 436–442
- Ferry, A.P. Pyogenic granulomas of the eye and ocular adnexa: a study of 100 cases. *Trans Am Ophthalmol Soc.* 1989; 87: 327–347
- Folberg, R., McLean, I.W., and Zimmerman, L.E. Primary acquired melanosis of the conjunctiva. *Hum Pathol.* 1985; 16: 136–143
- Folberg, R. and McLean, I.W. Primary acquired melanosis and melanoma of the conjunctiva; terminology, classification, and biologic behavior. *Hum Pathol.* 1986; 17: 652–654
- Frucht-Pery, J. and Rozenman, Y. Mitomycin C therapy for corneal intraepithelial neoplasia. *Am J Ophthalmol.* 1994; 117: 164–168
- Frucht-Pery, J., Sugar, J., Baum, J. *et al.* Mitomycin C treatment for conjunctival-corneal intraepithelial neoplasia: a multicenter experience. *Ophthalmology.* 1997; 104: 2085–2093
- Gerner, N., Norregaard, J.C., Jensen, O.A., and Prause, J.U. Conjunctival naevi in Denmark 1960–1980. A 21-year follow-up study. *Acta Ophthalmol Scand.* 1996; 74: 334–337
- Gloor, P. and Alexandrakis, G. Clinical characterization of primary acquired melanosis. *Invest Ophthalmol Vis Sci.* 1995; 36: 1721–1729
- Grossniklaus, H.E., Green, W.R., Luckenbach, M., and Chan, C.C. Conjunctival lesions in adults. A clinical and histopathologic review. *Cornea.* 1987; 6: 78–116
- Grossniklaus, H.E., Green, W.R., Wolff, S.M., and Iliff, N.T. Hemangiopericytoma of the conjunctiva. Two cases. *Ophthalmology.* 1986; 93: 265–267
- Gunduz, K., Shields, C.L., Shields, J.A. *et al.* Intraocular neoplastic cyst from mucoepidermoid carcinoma of the conjunctiva. *Arch Ophthalmol.* 1998; 116: 1521–1523
- Gunduz, K., Shields, C.L., Shields, J.A., and Zhao, D. Plaque radiotherapy for recurrent conjunctival pyogenic granuloma. *Arch Ophthalmol.* 1998; 116: 538–539
- Hawkins, A.S., Yu, J., Hamming, N.A., and Rubenstein, J.B. Treatment of recurrent conjunctival papillomatosis with mitomycin C. *Am J Ophthalmol.* 1999; 128: 638–640
- Honavar, S.G., Shields, C.L., Maus, M. *et al.* Primary intraepithelial sebaceous gland carcinoma of the palpebral conjunctiva. *Arch Ophthalmol.* 2001; 119: 764–767
- Iliff, W.J., Marback, R., and Green, W.R. Invasive squamous cell carcinoma of the conjunctiva. *Arch Ophthalmol.* 1975; 93: 119–122
- Jakobiec, F.A., Perry, H.D., Harrison, W., and Krebs, W. Dacryoadenoma. A unique tumor of the conjunctival epithelium. *Ophthalmology.* 1989; 96: 1014–1020
- Jakobiec, F.A., Sacks, E., Lisman, R.L., and Krebs, W. Epibulbar fibroma of the conjunctival substantia propria. *Arch Ophthalmol.* 1988; 106: 661–664
- Karp, C.L., Moore, J.K., and Rosa, R.H. Jr. Treatment of conjunctival and corneal intraepithelial neoplasia with topical interferon alpha-2b. *Ophthalmology.* 2001; 108: 1093–1098
- Kiratli, H., Shields, C.L., Shields, J.A., and DePoter, P. Metastatic tumours to the conjunctiva: report of 10 cases. *Br J Ophthalmol.* 1996; 80: 5–8
- Knowles, D.M. II and Jakobiec, F.A. Ocular adnexal lymphoid neoplasms: clinical, histopathologic, electron microscopic, and immunologic characteristics. *Hum Pathol.* 1982; 123: 148–162
- Luthra, C.L., Doxanas, M.T., and Green, W.R. Lesions of the caruncle. A clinicopathologic study. *Surv Ophthalmol.* 1978; 23: 183–195
- McKelvie, P.A., Daniell, M., McNab, A. *et al.* Squamous cell carcinoma of the conjunctiva: a series of 26 cases. *Br J Ophthalmol.* 2002; 86: 168–173
- McKelvie, P.A., McNab, A., Francis, I.C. *et al.* Ocular adnexal lymphoproliferative disease: a series of 73 cases. *Clin Exp Ophthalmol.* 2001; 29: 387–393
- Midena, E., Angeli, C.D., Valenti, M. *et al.* Treatment of conjunctival squamous cell carcinoma with topical 5-fluorouracil. *Br J Ophthalmol.* 2000; 84: 268–272
- Munro, S., Brownstein, S., and Liddy, B. Conjunctival keratoacanthoma. *Am J Ophthalmol.* 1993; 116: 654–655
- Paridaens, A.D., McCartney, A.C., Minassian, D.C., and Hungerford, J.L. Orbital exenteration in 95 cases of primary conjunctival malignant melanoma. *Br J Ophthalmol.* 1994; 78: 520–528
- Paridaens, A.D., Minassian, D.C., McCartney, A.C., and Hungerford, J.L. Prognostic factors in primary malignant melanoma of the conjunctiva: a clinicopathological study of 256 cases. *Br J Ophthalmol.* 1994; 78: 252–259
- Paridaens, D., Beekhuis, H., van Den Bosch, W. *et al.* Amniotic

- membrane transplantation in the management of conjunctival malignant melanoma and primary acquired melanosis with atypia. *Br J Ophthalmol.* 2001; 85: 658–661
43. Peer, J. and Hidayat, A.A. Myxomas of the conjunctiva. *Am J Ophthalmol.* 1986; 102: 80–86
  44. Perry, H.D. Isolated episcleral neurofibroma. *Ophthalmology.* 1982; 89: 1095–1098
  45. Pfaffenbach, D.D. and Green, W.R. Ectopic lacrimal gland. *Int Ophthalmol Clin.* 1971; 11: 149–159
  46. Schachat, A.P., Markowitz, J.A., Guyer, D.R. *et al.* Ophthalmic manifestations of leukemia. *Arch Ophthalmol.* 1989; 107: 697–700
  47. Schechter, B.A., Rand, W.J., Velazquez, G.E. *et al.* Treatment of conjunctival papillomata with topical interferon Alfa-2b. *Am J Ophthalmol.* 2002; 134: 268–270
  48. Scott, I.U., Karp, C.L., and Nuovo, G.J. Human papillomavirus 16 and 18 expression in conjunctival intraepithelial neoplasia. *Ophthalmology.* 2002; 109: 542–547
  49. Scott, J.A. and Tan, D.T. Therapeutic lamellar keratoplasty for limbal dermoids. *Ophthalmology.* 2001; 108: 1858–1867
  50. Seregard, S. Conjunctival melanoma. *Surv Ophthalmol.* 1998; 42: 321–350
  51. Shelil, A.E., Shields, C.L., Shields, J.A., and Eagle, R.C. Aggressive conjunctival squamous cell carcinoma in a liver transplant patient. *Arch Ophthalmol.* 2003; 121: 280–282
  52. Shields, C.L. Conjunctival melanoma. *Br J Ophthalmol.* 2002; 86: 127
  53. Shields, C.L., Demirci, H., Shields, J.A., and Spanich, C. Dramatic regression of conjunctival and corneal acquired melanosis with topical mitomycin C. *Br J Ophthalmol.* 2002; 86: 244–245
  54. Shields CL, Fasiuddin A, Mashayekhi A: Clinical features and natural course of 417 conjunctival nevi. *Arch Ophthalmol* 2003, in press.
  55. Shields, C.L., Lally, M.R., Singh, A.D. *et al.* Oral cimetidine (Tagamet) for recalcitrant, diffuse conjunctival papillomatosis. *Am J Ophthalmol.* 1999; 128: 362–364
  56. Shields, C.L., Naseripour, M., and Shields, J.A. Topical mitomycin C for extensive, recurrent conjunctival-corneal squamous cell carcinoma. *Am J Ophthalmol.* 2002; 133: 601–606
  57. Shields, C.L., Naseripour, M., Shields, J.A., and Eagle, R.C. Jr. Topical Mitomycin C for conjunctival pagetoid invasion of sebaceous gland carcinoma. *Ophthalmology.* 2002; 109: 2129–2133
  58. Shields, C.L. and Shields, J.A. Phakomatoses. in: C.D. Regillo, G.C. Brown, H.W. Flynn Jr. (Eds.) *Vitreoretinal Disease. The Essentials.* Thieme Medical Publishers, Inc, New York; 1999: 377–390
  59. Shields, C.L., Shields, J.A., and Arbizio, V. Oncocytoma of the caruncle. *Am J Ophthalmol.* 1986; 102: 315–319
  60. Shields, C.L., Shields, J.A., and Armstrong, T. Management of conjunctival and corneal melanoma with combined surgical excision, amniotic membrane allograft, and topical chemotherapy. *Am J Ophthalmol.* 2001; 132: 576–578
  61. Shields, C.L., Shields, J.A., Carvalho, C. *et al.* Conjunctival lymphoid tumors: clinical analysis of 117 cases and relationship to systemic lymphoma. *Ophthalmology.* 2001; 108: 979–984
  62. Shields, C.L., Shields, J.A., and Eagle, R.C. Rapidly progressive T-cell lymphoma of the conjunctiva. *Arch Ophthalmol.* 2002; 120: 508–509
  63. Shields, C.L., Shields, J.A., and Eagle, R.C. Hereditary benign intraepithelial dyskeratosis. *Arch Ophthalmol.* 1987; 105: 422–423
  64. Shields, C.L., Shields, J.A., Gunduz, K. *et al.* Conjunctival melanoma: risk factors for recurrence, exenteration, metastasis, and death in 150 consecutive patients. *Arch Ophthalmol.* 2000; 118: 1497–1507
  65. Shields, C.L., Shields, J.A., Gunduz, K. *et al.* Radiation therapy for uveal malignant melanoma. *Ophthalmic Surg Lasers.* 1998; 29: 397–409
  66. Shields, C.L., Shields, J.A., Honavar, S.G., and Demirci, H. Clinical spectrum of primary orbital rhabdomyosarcoma. *Ophthalmology.* 2001; 108: 2284–2292
  67. Shields, C.L., Shields, J.A., White, D., and Augsburger, J.J. Types and frequency of lesions of the caruncle. *Am J Ophthalmol.* 1986; 102: 771–778
  68. Shields, J.A. Lipomatous and myxomatous tumors. in: J.A. Shields (Ed.) *Diagnosis and Management of Orbital Tumors.* Saunders Co, Philadelphia, PA; 1989: 236–238
  69. Shields, J.A., De Potter, P., Shields, C.L., and Komarnicky, L.T. Kaposi sarcoma of the eyelids: response to radiotherapy. *Arch Ophthalmol.* 1992; 110: 1689
  70. Shields, J.A., Eagle, R.C., Shields, C.L., DePotter, P., and Schnell, B.M. Epibulbar osseous choristoma. Computed tomography and clinicopathologic correlation. *Ophthalmic Pract.* 1997; 15: 110–112
  71. Shields, J.A., Eagle, R.C. Jr., Shields, C.L. *et al.* Orbital varix presenting as a subconjunctival mass. *Ophthalm Plast Reconstr Surg.* 1995; 11: 37–38
  72. Shields, J.A., Laibson, P.R., Augsburger, J.J., and Michon, C.A. Central corneal dermoid. A clinicopathologic correlation and review of the literature. *Can J Ophthalmol.* 1986; 21: 23–26
  73. Shields, J.A. and Shields, C.L. Rhabdomyosarcoma: review for the ophthalmologist. *Surv Ophthalmol.* 2003; 48: 39–57
  74. Shields, J.A. and Shields, C.L. Pediatric ocular and periocular tumors. *Pediatr Ann.* 2001; 30: 491–501
  75. Shields, J.A. and Shields, C.L. Systemic hamartomas (phakomatoses). in: J.A. Shields, C.L. Shields (Eds.) *Intraocular Tumors. A Text and Atlas.* W.B. Saunders, Philadelphia, PA; 1992: 513–539
  76. Shields, J.A. and Shields, C.L. Tumors and pseudotumors of the conjunctiva. in: J.A. Shields, C.L. Shields (Eds.) *Atlas of Eyelid and Conjunctival Tumors.* Lippincott Williams and Wilkins Co, Philadelphia, PA; 1999: 199–334
  77. Shields, J.A. and Shields, C.L. Lipomatous and myxomatous tumors. in: J.A. Shields, C.L. Shields (Eds.) *Atlas of Orbital Tumors.* Lippincott Williams and Wilkins Co, Philadelphia, PA; 1999: 143–152
  78. Shields, J.A. and Shields, C.L. Management of conjunctival tumors. in: J.A. Shields, C.L. Shields (Eds.) *Atlas of Eyelid and Conjunctival Tumors.* Lippincott Williams and Wilkins Co, Philadelphia, PA; 1999: 332–334
  79. Shields, J.A., Shields, C.L., and De Potter, P. Surgical management of circumscribed conjunctival melanomas. *Ophthalm Plast Reconstr Surg.* 1998; 14: 208–215
  80. Shields, J.A., Shields, C.L., and De Potter, P. Surgical management of conjunctival tumors. The 1994 Lynn B. McMahan Lecture. *Arch Ophthalmol.* 1997; 115: 808–815
  81. Shields, J.A., Shields, C.L., Demirci, H. *et al.* Experience with eyelid-sparing orbital exenteration. The 2000 Tullio O. Coston Lecture. *Ophthalm Plast Reconstr Surg.* 2001; 17: 355–361
  82. Shields, J.A., Shields, C.L., Eagle, R.C. Jr. *et al.* Ophthalmic features of the organoid nevus syndrome. *Ophthalmology.* 1997; 104: 549–557
  83. Shields, J.A., Shields, C.L., Eagle, R.C. Jr. *et al.* Pigmented conjunctival squamous cell carcinoma simulating a conjunctival melanoma. *Am J Ophthalmol.* 2001; 132: 104–106
  84. Shields, J.A., Shields, C.L., Gunduz, K., and Cater, J. Clinical features predictive of orbital exenteration for conjunctival melanoma. *Ophthalm Plast Reconstr Surg.* 2000; 16: 173–178
  85. Shields, J.A., Shields, C.L., Gunduz, K., and Eagle, R.C. Jr. The 1998 Pan American Lecture. Intraocular invasion of conjunctival

- squamous cell carcinoma in five patients. *Ophthal Plast Reconstr Surg.* 1999; 15: 153–160
86. Shields, J.A., Shields, C.L., Suvarnamani, C. *et al.* Orbital exenteration with eyelid sparing: Indications, technique and results. *Ophthalmic Surg.* 1991; 22: 292–297
  87. Singh, A.D., DePotter, P., Fijal, B.A. *et al.* Lifetime prevalence of uveal melanoma in white patients with oculo (dermal) melanocytosis. *Ophthalmology.* 1998; 105: 195–198
  88. Sjo, N.C., Heegaard, S., Prause, J.U. *et al.* Human papillomavirus in conjunctival papilloma. *Br J Ophthalmol.* 2001; 85: 785–787
  89. Spencer, W. Conjunctiva. in: W. Spencer (Ed.) *Ophthalmic Pathology. An Atlas and Textbook.* WB Saunders Co, Philadelphia, PA; 1996: 40–42
  90. Spinak, M. and Friedman, A.H. Squamous cell carcinoma of the conjunctiva. Value of exfoliative cytology in diagnosis. *Surv Ophthalmol.* 1977; 21: 351–355
  91. Strempel, I. and Kroll, P. Conjunctival malignant melanoma in children. *Ophthalmologica.* 1999; 213: 129–132
  92. Tunc, M., Char, D.H., Crawford, B., and Miller, T. Intraepithelial and invasive squamous cell carcinoma of the conjunctiva: analysis of 60 cases. *Br J Ophthalmol.* 1999; 83: 98–103
  93. Tuomaala, S., Aine, E., Saari, K.M., and Kivela, T. Corneally displaced malignant conjunctival melanomas. *Ophthalmology.* 2002; 109: 914–919
  94. Ullman, S.S., Nelson, L.B., Shields, J.A. *et al.* Cavernous hemangioma of the conjunctiva. *Orbit.* 1988; 6: 261–265
  95. Wright, J.E., Sullivan, T.J., Garner, A. *et al.* Orbital venous anomalies. *Ophthalmology.* 1997; 104: 905–913
  96. Yamamoto, N., Ohmura, T., Suzuki, H., and Shirasawa, H. Successful treatment with 5-fluorouracil of conjunctival intraepithelialneoplasia refractive to mitomycin-C. *Ophthalmology.* 2002; 109: 249–252
  97. Yeatts, R.P., Engelbrecht, N.E., Curry, C.D. *et al.* 5-Fluorouracil for the treatment of intraepithelial neoplasia of the conjunctiva and cornea. *Ophthalmology.* 2000; 107: 2190–2195
  98. Young, T.L., Buchi, E.R., Kaufman, L.M. *et al.* Respiratory epithelium in a cystic choristoma of the limbus. *Arch Ophthalmol.* 1990; 108: 1736–1739

## Outline

### I. General Considerations

- A. Anatomy
- B. Diagnostic Approaches
- C. Management
  1. Observation
  2. Incisional biopsy
  3. Excisional biopsy
  4. Cryotherapy
  5. Chemotherapy
  6. Radiotherapy
  7. Modified enucleation
  8. Orbital exenteration
  9. Mucous membrane graft

### II. Congenital Tumors

- A. Dermoid
- B. Dermolipoma
- C. Epibulbar osseous choristoma
- D. Lacrimal gland choristoma
- E. Respiratory choristoma
- F. Complex choristoma

### III. Benign Tumors of Surface Epithelium

- A. Papilloma
- B. Keratoacanthoma
- C. Hereditary benign intraepithelial dyskeratosis
- D. Epithelial inclusion cyst
- E. Dacryoadenoma
- F. Keratotic plaque
- G. Actinic Keratosis

### IV. Malignant Tumors of Surface Epithelium

- A. Conjunctival intraepithelial neoplasia (CIN)
- B. Invasive squamous cell carcinoma (SCC)

### V. Melanocytic Tumors

- A. Nevus
- B. Racial melanosis
- C. Ocular melanocytosis
- D. Primary acquired melanosis (PAM)
- E. Malignant melanoma
- F. Conditions that can simulate melanocytic tumors

### VI. Vascular Tumors

- A. Pyogenic granuloma
- B. Capillary hemangioma
- C. Cavernous hemangioma
- D. Racemose hemangioma
- E. Lymphangioma
- F. Varix
- G. Hemangiopericytoma
- H. Kaposi's sarcoma

### VII. Fibrous Tumors

- A. Fibroma
- B. Fibrous histiocytoma
- C. Nodular fasciitis

### VIII. Neural Tumors

- A. Neurofibroma
- B. Neurilemoma
- C. Granular cell tumor

### IX. Histiocytic Tumors

- A. Xanthoma
- B. Juvenile xanthogranuloma
- C. Reticulohistiocytoma

### X. Myxoid Tumors

- A. Myxoma

### XI. Myogenic

- A. Rhabdomyosarcoma

### XII. Lipomatous Tumors

- A. Lipoma
- B. Herniated orbital fat
- C. Liposarcoma

### XIII. Lymphoid Tumors

### XIV. Leukemia

### XV. Metastatic Tumors

### XVI. Secondary Tumors

### XVII. Caruncular Tumors and Cysts

### XVIII. Miscellaneous Lesions that Can Simulate Conjunctival Neoplasms

### XIX. Method of Literature Search