



Cervical Single-Level Pincer Stenosis Causing Myelopathy: A Technical Note and Medium-term Results of a One-Session Microsurgical 360-Degree Treatment

Luca Papavero¹  Markus Pietrek¹ Carlos J. Marques²  Gregor Schmeiser¹

¹Schoen Clinic Hamburg Eilbek, Academic Hospital of the Eppendorf University Medical Center - Clinic for Spine Surgery, Hamburg, Germany

²Science Office of the Orthopedic and Joint Replacement Department, Schoen Clinic Hamburg Eilbek, Academic Hospital of the Eppendorf University Medical Center – 2, Hamburg, Germany

Address for correspondence Luca Papavero, MD, PhD, Schoen Clinic Hamburg Eilbek, Academic Hospital of the Eppendorf University Medical Center - Clinic for Spine Surgery, Hamburg, Germany (e-mail: luca.papavero@yahoo.de).

J Neurol Surg A Cent Eur Neurosurg 2022;83:187–193.

Abstract

Background and Study Aims Single-level circumferential or pincer stenosis (PS) affects few patients with degenerative cervical myelopathy (DCM). The surgical technique and medium-term results of a one-session microsurgical 360-degree (m360°) procedure are presented.

Patients Between 2013 and 2018, the data of 23 patients were prospectively collected out of 371 patients with DCM. The m360° procedure comprised a microsurgical anterior cervical decompression and fusion (ACDF), with additional plate fixation, followed by flipping the patient and performing a microsurgical posterior bilateral decompression via a unilateral approach in crossover technique.

Results The mean age of the patients was 72 years (range: 50–84); 17 patients were males. The mean follow-up time was 12 months (range: 6–31). The patients filled in the patient-derived modified Japanese Orthopaedic Association (P-mJOA) questionnaire on average 53 months after surgery. One patient received a two-level ACDF. Lesions were mostly (92%) located at the C3/C4 (8/24), C4/C5 (7/24), and C5/C6 (7/24) levels. Functional X-rays showed segmental instability in 10 of 23 patients (44%). All preoperative T2-weighted magnetic resonance imaging (MRI) showed an intramedullary hyperintensity. The median preoperative mJOA score was 13 (range 3), and it improved to 16 (range 3) postoperatively. The mean improvement rate in the mJOA score was 73%. When available, postoperative MRI confirmed good circumferential decompression with persistent intramedullary hyperintensity. There were two complications: a long-lasting radicular paresthesia at C6 and a transient C5 palsy. No revision surgery was required.

Conclusion The one-session m360° procedure was found to be a safe surgical procedure for the treatment of PS, and the medium-term clinical outcome was satisfactory.

Keywords

- ▶ degenerative cervical myelopathy
- ▶ cervical spondylotic myelopathy
- ▶ over-the-top decompression
- ▶ modified Japanese Orthopaedic Association score
- ▶ pincer stenosis

received
June 27, 2020
accepted after revision
October 28, 2020
published online
October 6, 2021

DOI <https://doi.org/10.1055/s-0041-1723811>.
ISSN 2193-6315.

© 2021. The Author(s).

This is an open access article published by Thieme under the terms of the Creative Commons Attribution-NonDerivative-NonCommercial-License, permitting copying and reproduction so long as the original work is given appropriate credit. Contents may not be used for commercial purposes, or adapted, remixed, transformed or built upon. (<https://creativecommons.org/licenses/by-nc-nd/4.0/>)

Georg Thieme Verlag KG, Rüdigerstraße 14, 70469 Stuttgart, Germany

Introduction

Degenerative cervical myelopathy (DCM) is the most common cervical spine disease among older individuals.¹ Typically, the lower cervical levels are involved in DCM, and the spondylotic changes are multisegmental. However, a small group of patients with myelopathy present with single-level circumferential stenosis (so-called pincer stenosis [PS]), located mostly between C3 and C6. The preoperative magnetic resonance imaging (MRI) typically shows an anterior impingement of the spinal cord by osteophytes and/or a calcified disk protrusion and/or ligament. Dorsally, the spinal cord is compressed by a thickened, sometimes calcified, buckling yellow ligament.² The explanation is that the lower cervical segments are fixed, due to degenerative changes, and they do not impinge on the spinal cord intermittently. In contrast, the mobile middle cervical spine (C3/C6), rostral to the fixed segments, pinches the spinal cord with each flexion/extension.^{3–5} Similar to other progressive DCM conditions, PS requires surgical decompression of the neural structures, the best possible realignment of the index segment, and fixation.

The anterior approach (e.g., anterior cervical decompression and fusion [ACDF] with plating) provides an effective direct anterior decompression and postulates an indirect posterior decompression by distraction and a flattening of the wrinkled yellow ligament.⁶ However, that may become difficult, when the yellow ligament has become extremely thick or calcified.² Furthermore, when an effective anterior decompression requires wedge-shaped drilling of the vertebral endplates, a cage may not distract the disk space sufficiently to stretch the yellow ligament adequately.

A solely posterior decompression and fixation (e.g., a laminectomy and four lateral mass screws) may not always permit a sufficient dorsal shift of the spinal cord over the short distance. Other limitations of the dorsal approach are a contraindication with a kyphotic cervical spine; the traumatization of the neck muscles, which causes postoperative pain; and a postoperative reduction in the range of motion (ROM).⁷

In theory, the most effective treatment is a one-session 360-degree decompression, segmental realignment, and fixation. However, the conventional technique of this treatment is associated with a high incidence of complications, a long surgical time, and high costs.^{8,9} The aim of the present study was to investigate whether a combined anterior decompression with plate fixation along with a dorsal bilateral decompression of the spinal cord via a unilateral approach, microsurgical from skin to skin (microsurgical 360-degree [m360°] procedure), would result in a reduced surgical traumatization. Furthermore, we also investigate if this technique could achieve a satisfactory improvement of the modified Japanese Orthopaedic Association (mJOA) score.

Patients

Between 2013 and 2018, 371 patients with DCM underwent surgery in a single center. Of these, 23 patients underwent an

m360° procedure for PS. Inclusion criteria for this treatment were the following:

- Clinical symptoms and signs of progressive cervical myelopathy in accordance with PS shown by MRI, which usually was the first imaging. Interestingly, MRI showed in all patients an intramedullary signal hyperintensity at the stenotic level.
- Partial/complete calcification of the buckled yellow ligament shown by computed tomography (CT). This finding reduced considerably the number of included patients. It also suggested the need for an additional dorsal decompression as indirect decompression due to ligamentotaxy was hardly to be expected.
- (optional) Segmental instability of the target level shown by functional X-ray films.

Exclusion criteria were previous surgery at the index level and traumatic or neoplastic disease of the cervical spine. We retrospectively analyzed data that were prospectively collected on these 23 patients. On the admission day, all patients provided informed consent to allow evaluations of anonymized or pseudonymized clinical data for research purposes.

Comprehensive preoperative imaging was conducted with flexion/extension X-rays, CT scans, and MRI. The m360° procedure was a one-session surgery. Via an anterolateral approach, the index spinal level was exposed. After the distraction screws were inserted, the disk space was cleared with the aid of the microscope. Then, dorsal osteophytes and, the sometimes calcified, posterior longitudinal ligament were meticulously resected. At the end of extensive decompression, the disk space was slightly wedge shaped. A polyetheretherketone (PEEK) cage, filled with local bone, and, more recently, a titanium cage, created with additive manufacturing, provided the necessary lordotic realignment of the cervical segment. An anterior plate, which is not routinely used in single-level ACDFs, was used to fix the spinal segment, in view of the dorsal decompression. The patient was turned to the so-called Concorde position, and the head was secured with a Mayfield clamp. The target spinal level, which typically corresponded to the cage, was labeled fluoroscopically, followed by draping. The decision of whether to approach on the left or the right side was determined as follows, in descending order of importance: (1) the dominant symptomatic side, (2) the dominant imaging side, or (3) the dominant handedness of the patient. A 3-cm, slightly paramedian skin incision was performed under a microscope. The fascia was hinged toward the midline with some holding sutures. A blunt dissection of the muscles led to the target hemilamina–facet junction. A miniature, table-fixed speculum was inserted. After fluoroscopic confirmation of the target level, a diamond dust–coated drill burr was used to decompress the dural sac in crossover technique, similarly to the more popular lumbar variant. However, the cervical crossover decompression requires more advanced technical skills from the surgeon than in the lumbar spine. We have to always be aware of the spinal cord and avoid any pressure application on the dura during bone and ligament removal. When necessary, the root canal was enlarged, and the root was decompressed. After surgery, no drain was inserted, and no

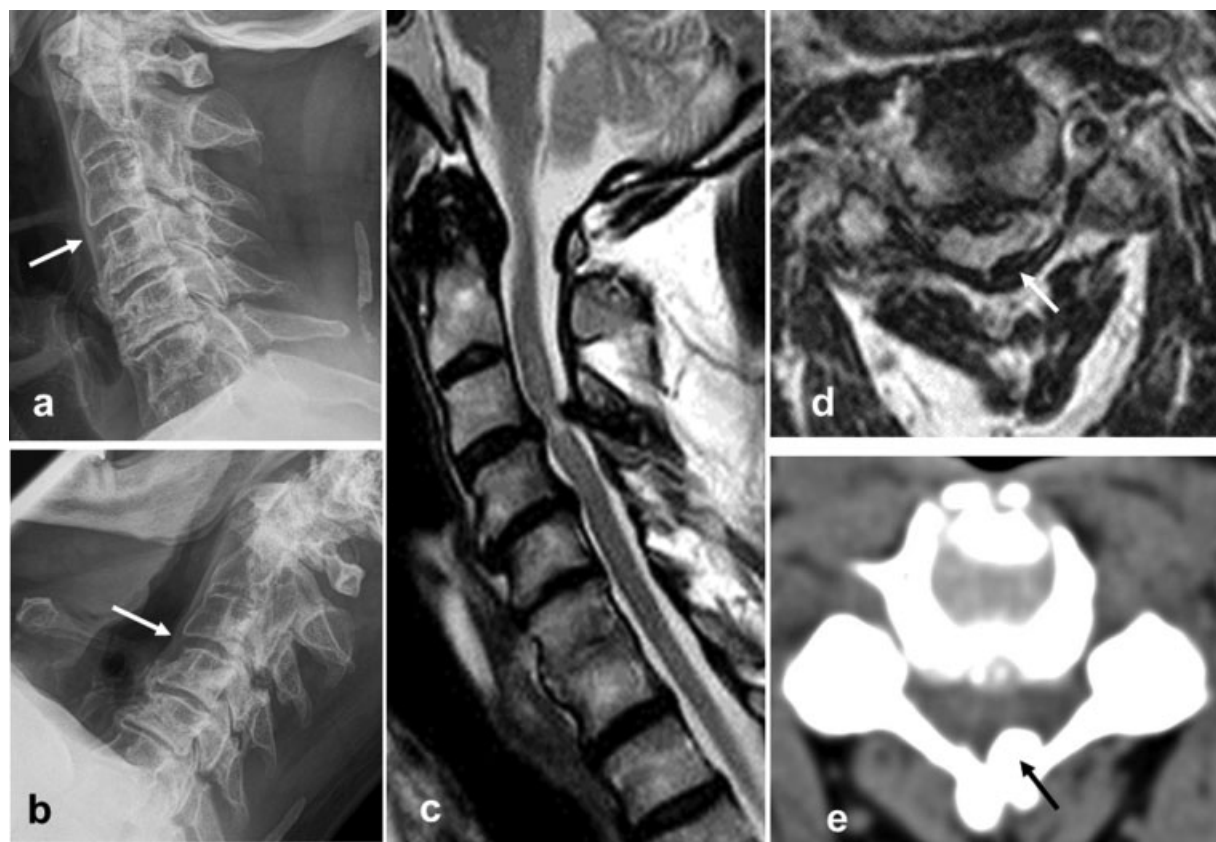


Fig. 1 Clinical case: A 64-year-old man with a modified Japanese orthopaedic association (mJOA) score of 12.5. X-ray images show the neck (a) in extension, alignment of C3 on C4 (arrow), and (b) in flexion, mild ventral slip of C3 on C4 (arrow). (c) Magnetic resonance imaging (MRI) of pincer stenosis at C3/C4, with intramedullary signal hyperintensity. (d) MRI shows the spinal cord, pinched between the bulging anterior disk and the thickened yellow ligament, on the left side (arrow). (e) MRI shows localized calcification of the yellow ligament (arrow).

collar was worn. Immediate postoperative mobilization was encouraged. Postoperatively, a biplanar cervical X-ray was routinely performed. Some patients consented to CT and MRI scans for study purposes (—Figs. 1–3). The clinical examination at follow-up focused on the rate of improvement in the mJOA score, calculated as follows: improvement rate (%) = (postoperative mJOA score – preoperative mJOA score) /

(17 – preoperative score) × 100.¹⁰ On average, 4.4 years after surgery, the patients filled in the patient-derived, self-administered questionnaire (P-mJOA). The good correlation between the mJOA scale and the P-mJOA has been demonstrated by Rhee et al.¹¹ Furthermore, the patients rated their satisfaction with the surgical procedure. Ethical approval was waived by the Ethics Committee of the Federal State of Hamburg in view

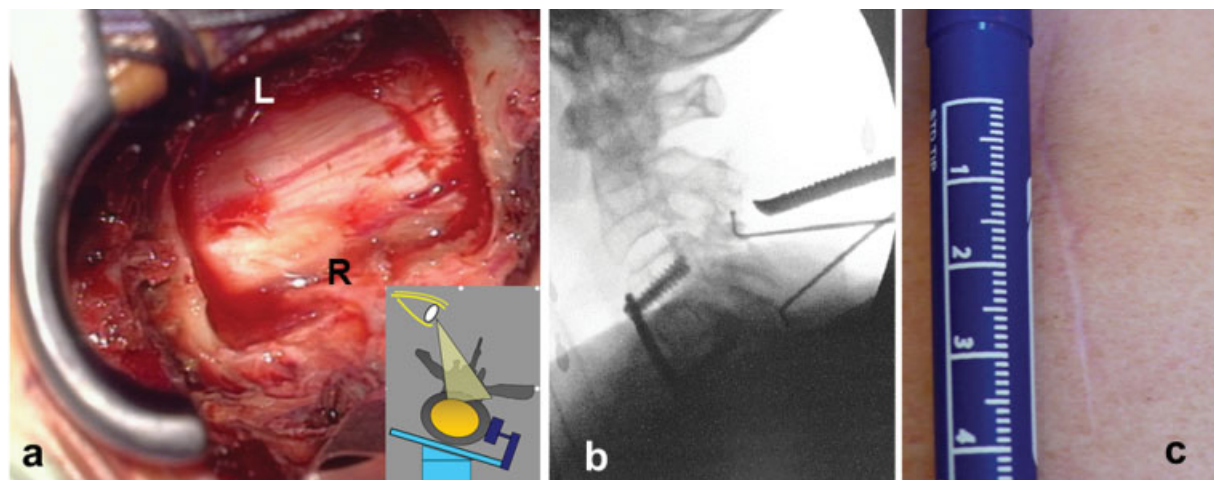


Fig. 2 Crossover decompression. (a) Dorsal view of the dural sac (R, right border; L, left border) after crossover decompression was completed. The graph shows the oblique line of sight. (b) Fluoroscopy shows how the up-down adequacy of dorsal decompression is checked with two hooks. (c) A 3- to 4-cm scar after dorsal crossover decompression.

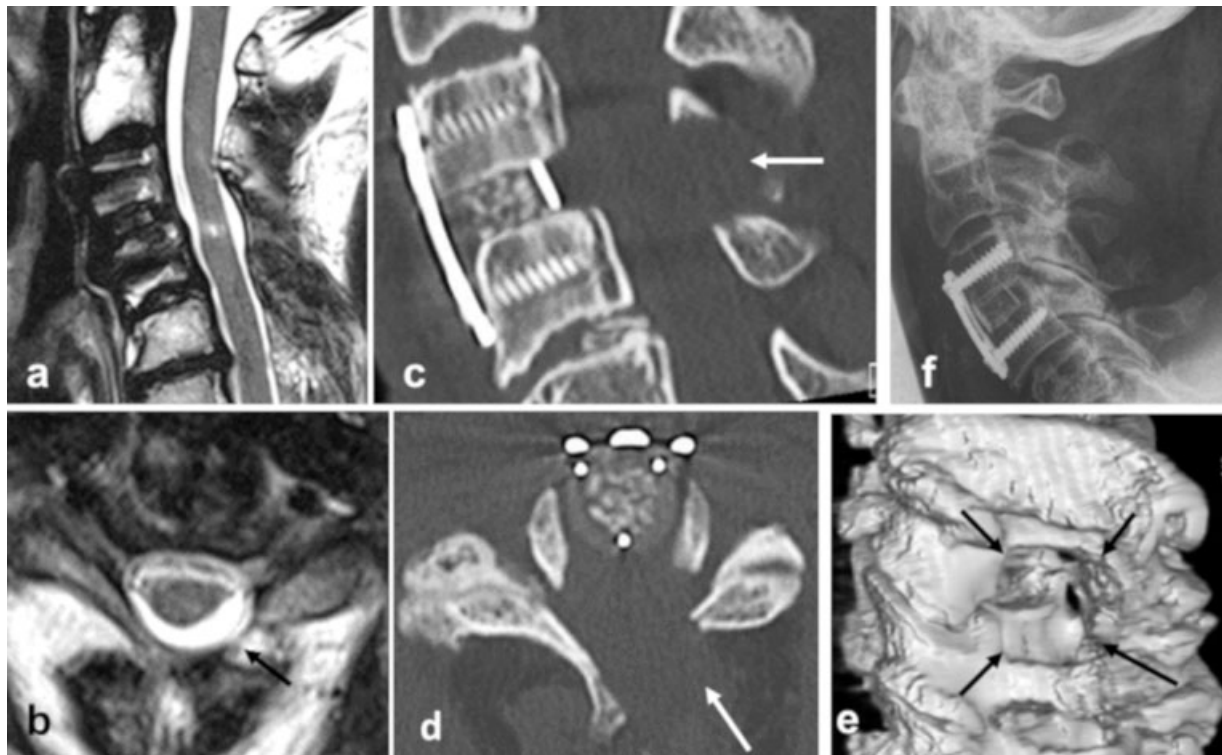

Fig. 3 Postoperative imaging of a microsurgical 360-degree procedure (m360°). (a) Magnetic resonance imaging (MRI) shows adequate decompression at C3/C4, with persistent intramedullary signal hyperintensity. Nevertheless, the modified Japanese orthopaedic association (mJOA) score improved to 16.5. (b) MRI shows the left-sided approach (arrow) of the crossover decompression. Reformatted computed tomography (CT) scans show (c) the cage filled with autologous bone, the anterior plate, and the dorsal bone window (arrow) and (d) the left-sided laminar window (arrow). (e) 3D-CT shows the extent of the bone window (four arrows). (f) X-ray image shows the postoperative lordotic alignment of the index level.

of the retrospective nature of the study and all the procedures being performed were part of the routine care (File PV 5767).

Statistics

The normal distribution of the mJOA scores in each follow-up was verified by means of histograms and with the use of the Kolmogorov–Smirnov test. Since the null hypothesis of normal distribution was rejected, nonparametric tests were used. Friedman’s analysis of variance (ANOVA) was used to test for significant differences between the median scores across the three measurements. Post hoc analysis was performed with Wilcoxon signed-rank test with a Bonferroni correction of α , resulting in a significance level set at $p < 0.017$. We report the median and the range. All statistical analyses were performed using IBM SPSS software version 21 for Macintosh (IBM Corp., Armonk, New York, United States).

Results

Twenty-three patients with PS underwent the m360° procedure. The mean age was 72 years (range: 50–84). Seventeen patients were males. The first follow-up was a clinical examination on average 12 months (range: 6–31) after surgery. At the second follow-up, an interview 4.4 years after surgery, 20 of 23 patients filled in the P-mJOA questionnaire and rated their satisfaction with the operation. One patient underwent a two-level ACDF. PS was located in 92% of patients at the upper

cervical levels: C3/C4 (8/24 levels), C4/C5 (7/24 levels), and C5/C6 (7/24 levels). Functional X-rays documented segmental instability in 10 of 23 patients (44%). In three patients the flexion/extension X-ray films were missing. The preoperative T2-weighted MRI scans of all patients showed an intramedullary hyperintensity, mostly caudal, at the level of the PS. The average surgical time was influenced by the experience of the surgeon and the time needed to flip the patient. It ranged from a mean of 243 minutes (range: 210–285, in 13 procedures) to 187 minutes (range: 148–200, in 10 procedures). The average blood loss was 92 ± 13 mL. The mean American Society of Anaesthesiologists (ASA) score was 2.6 ± 0.5 and the length of hospital stay (LOS) was 5.4 ± 1.5 days.

The median mJOA scores are presented in **Table 1**. Median (range) mJOA scores were 13 (4), 16 (3), and 16 (7). There was a statistically significant difference in median mJOA scores across the three follow-up times, $X^2_{(2)} = 19.4$,

Table 1 Influence of surgery on median mJOA scores

Follow-up		Median	(Minimum, maximum)	Range
mJOA	Preoperative	13	(10, 14)	4
	12 mo	16	(14, 17)	3
	53 mo ^a	16	(10, 17)	7

Abbreviations: mJOA, modified Japanese orthopaedic association score
^aPatient-derived mJOA (P-mJOA).

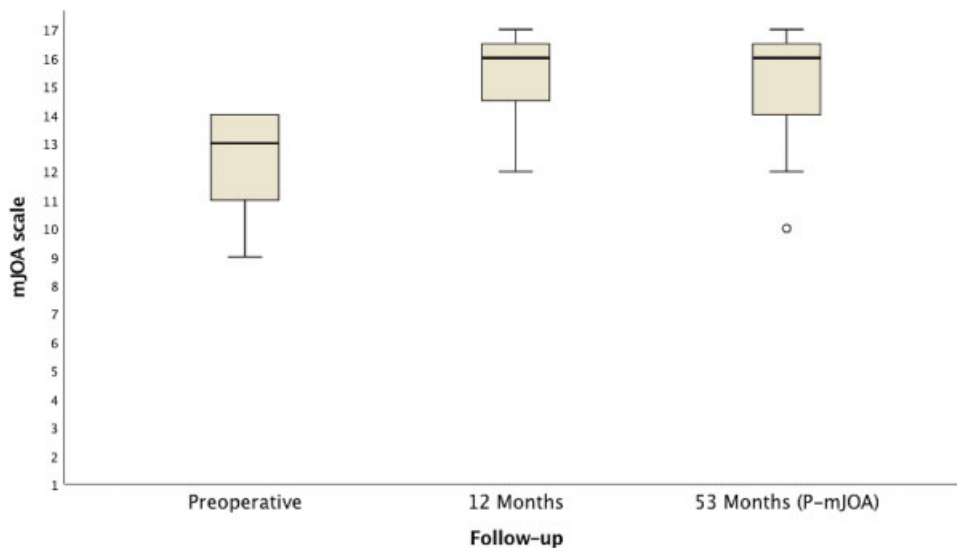


Fig. 4 Medium-term outcome after a microsurgical 360-degree procedure (m360°). Fifty-three months after surgery, 15 of 20 patients improved compared with the preoperative status, 2 remained unchanged, and 3 worsened following a temporary improvement (°, outlier). In all the patients who worsened, the magnetic resonance imaging (MRI) did not show a recurrent stenosis.

$p < 0.001$. Post hoc analysis revealed that the three-point mJOA score increase between preoperative and 12 months was statistically significant ($Z = 3.9$; $p < 0.001$). The mean improvement rate was 73%. Twenty patients filled in the P-mJOA questionnaire 4.4 years after surgery: 15 showed signs of improvement compared with the preoperative status, 2 remained unchanged, and 3 worsened following a temporary improvement (► **Fig. 4**). However, MRI did not show a recurrent stenosis in any of the patients whose condition worsened. There was no statistically significant difference between the median mJOA score at 12 months and the P-mJOA score at 53 months ($Z = -1.47$; $p = 0.13$). Nineteen patients would opt for the surgical procedure again, as 11 were very satisfied, 8 somewhat satisfied, and 1 somewhat dissatisfied with the clinical outcome.

The postoperative MRI confirmed good circumferential decompression with unchanged intramedullary hyperintensity, except in two patients, who showed a reduced intensity signal. There were two complications: a persisting radicular paresthesia at C6 and a transient C5 palsy (► **Table 2**). No revision surgery was needed. In our setting, a cervical cage and an anterior plate cost 40% of the sum spent for four polyaxial lateral mass screws with two rods. Therefore, the m360° procedure was less expensive than the dorsal conventional surgical option.

Discussion

The clinical and imaging data collected up to now showed that a combined microsurgical anteroposterior decompression and additional anterior fixation is a feasible less invasive treatment for PS.

Cervical multisegmental circumferential stenosis is a common cause of DCM. Mechanical factors, like ossification of the ligaments, osteophytic spurs, or disk degeneration, and dynamic elements, like flexion or extension of a possibly misaligned

cervical spine, prompt a cascade of neuroinflammatory changes, which eventually lead to cervical myelopathy.¹² When the cervical spine is in lordotic alignment, it can be treated with either a laminectomy with fixation¹³ or laminoplasty.¹⁴ In cases of severe kyphotic malalignment, a combined conventional surgical approach is recommended.¹⁵

In our view, PS is not the “short variant” of the more common multisegmental disease. Instead, these conditions differ in several ways. PS mostly affects the middle cervical spine (C3–C6). An in vivo three-dimensional analysis of the kinematics of the cervical spine showed that maximum axial rotation, and maximum degree of coupled lateral bending and extension, occurs in the middle cervical region.⁴ Neck extension induces a buckling in the yellow ligament, and the laminae slide over each other. The spinal cord is “pinched” between the inferior surface of the cranial vertebra and the lamina or the ligamentum flavum of the caudal vertebra.^{16,17} In flexion, the spinal cord is stretched over a bulging disk or dorsal osteophytes, which can lead to an intramedullary ischemic injury, due to the increased axial tension.¹⁸ In our patient cohort, these pathophysiologic mechanisms corresponded to the following clinical features: a high prevalence (44%) of frank segmental instability, shown by functional X-ray imaging, and a constant (100%) intramedullary hyperintense signal in T2-weighted MR images.

If we accept the notion that PS is a specific pattern of DCM, then we should also consider a specifically tailored surgical treatment. A solely posterior decompression (e.g., a laminectomy with lateral mass screw fixation) might not always provide adequate dorsal shifting of the spinal cord; in contrast, sufficient shifts can be achieved with this technique in a multisegmental DCM pattern. Alternatively, a solely anterior approach (e.g., an ACDF with a plate) might not always distract a thickened, fibrotic degenerated, or even partially calcified yellow ligament to provide indirect dorsal spinal cord relief. Thus, only a 360° approach might completely address the

Table 2 Patients' data and postoperative improvement rate

Patient no.	Gender	Age (y)	Level	Instability	Complications	mJOA pre-op	mJOA FU (mo)	mJOA IR (%)	P-mJOA (mo)	Final IR (%)
1	F	82	C3/C4	unknown	no	10	14 (6)	57	16 (82)	86 (↑)
2	M	59	C5/C6	no	no	11	16 (6)	83	n.a.	n.a.
3	M	71	C3/C4	yes	no	13	14 (6)	25	17 (76)	100 (↑)
4	M	77	C5/C6	no	no	9.5	14 (12)	60	16 (75)	87 (↑)
5	M	74	C2/C3	no	no	9	14 (12)	63	16 (75)	88 (↑)
6	M	58	C4/C5	no	no	6.5	12 (6)	52	n.a.	n.a.
7	F	71	C5/C6	no	no	10	15 (12)	86	10 (69)	0 (→)
8	M	78	C5/C6	unknown	no	14	14 (6)	0	14 (66)	0 (→)
9	M	71	C5/C6	no	C6 paresthesia	14	16 (14)	67	16 (66)	67 (↑)
10	M	50	C5/C6	no	no	10	16 (10)	86	16 (61)	86 (↑)
11	M	78	C4/C5	Yes	C5 palsy	14	16 (12)	67	13 (58)	-25 (↓)
12	M	68	C4/C5	no	no	13	16 (23)	75	n.a.	n.a.
13	F	75	C4/C5	no	no	13	17 (31)	100	17 (54)	100 (↑)
14	F	84	C4/C5	yes	no	14	17 (19)	100	15 (50)	25 (↑)
15	M	76	C3/C5	yes	no	14	16 (12)	67	12 (49)	-40 (↓)
16	F	75	C5/C6	no	no	13	17 (13)	100	14 (48)	25 (↑)
17	F	68	C3/C4	yes	no	13	16 (12)	75	16 (48)	75 (↑)
18	M	81	C3/C4	yes	no	13	17 (6)	100	15 (43)	50 (↑)
19	M	55	C7/D1	yes	no	11	16 (6)	83	17 (41)	100 (↑)
20	M	82	C4/C5	yes	no	14	16 (15)	67	13 (37)	-25 (↓)
21	M	67	C3/C4	yes	no	14	17 (12)	100	17 (29)	100 (↑)
22	M	68	C3/C4	no	no	13	17 (12)	100	16 (23)	75 (↑)
23	M	67	C3/C4	yes	no	13	16 (12)	75	17 (23)	100 (↑)

Abbreviations: FU, follow-up; IR, improvement rate; mJOA, modified Japanese orthopaedic association score; n.a., not available; P-mJOA, patient-derived mJOA.

specific features of PS. Historically, a combined multisegmental surgery has been associated with a higher incidence of complications, such as excessive bleeding, wound infection, and postoperative sequelae.¹⁹ Here, the anterior decompression and the complete posterior procedure were performed with the aid of the microscope. With this approach, together with the limited unilateral dissection of the neck muscles, and the single-session timing, we reduced the invasiveness of the procedure and shortened the patient recovery time. We concede that the prolonged surgical time is the most obvious disadvantage of the m360° procedure, although the incidence of complications did not increase probably due to the limited surgical invasiveness.

This study has several limitations. First, a single cohort that underwent a single surgical strategy was followed prospectively. Therefore, it was not possible to perform a direct comparison of treatment results obtained with the different surgical techniques (e.g., ACDF plus a laminectomy, implemented with lateral mass screws, or only a posterior decompression with fixation). Second, the number of patients was relatively small, because the m360° approach was indicated in only 5% of the patients with DCM.

Conclusion

Cervical, single-level, circumferential spinal stenosis, known as PS, presented specific features that required a combined surgical decompression. The one-session m360° procedure was found to be a safe surgical procedure and showed satisfactory clinical outcome.

Conflicts of interest

None declared.

References

- Klineberg E. Cervical spondylotic myelopathy: a review of the evidence. *Orthop Clin North Am* 2010;41(02):193-202
- Guo JJ, Luk KD, Karppinen J, Yang H, Cheung KM. Prevalence, distribution, and morphology of ossification of the ligamentum flavum: a population study of one thousand seven hundred thirty-six magnetic resonance imaging scans. *Spine* 2010;35(01):51-56
- Imajo Y, Hiiragi I, Kato Y, Taguchi T. Use of the finite element method to study the mechanism of spinal cord injury without radiological abnormality in the cervical spine. *Spine* 2009;34(02):E83-E87

- 4 Ishii T, Mukai Y, Hosono N, et al. Kinematics of the subaxial cervical spine in rotation in vivo three-dimensional analysis. *Spine* 2004;29(24):2826–2831
- 5 Morishita Y, Maeda T, Naito M, Ueta T, Shiba K. The pincers effect on cervical spinal cord in the development of traumatic cervical spinal cord injury without major fracture or dislocation. *Spinal Cord* 2013;51(04):331–333
- 6 Peng D, Ma Y, Lei B. Clinical and radiological outcomes of anterior approach microscopic surgery for the pincer mechanism in cervical spondylotic myelopathy. *BioMed Res Int* 2019;2019:9175234
- 7 Minamide A, Yoshida M, Yamada H, et al. Efficacy of posterior segmental decompression surgery for pincer mechanism in cervical spondylotic myelopathy: a retrospective case-controlled study using propensity score matching. *Spine* 2015;40(23):1807–1815
- 8 Veeravagu A, Connolly ID, Lamsam L, et al. Surgical outcomes of cervical spondylotic myelopathy: an analysis of a national, administrative, longitudinal database. *Neurosurg Focus* 2016;40(06):E11
- 9 Zhou X, Cai P, Li Y, Wang H, Xia S, Wang X. Posterior or single-stage combined anterior and posterior approach decompression for treating complex cervical spondylotic myelopathy coincident multilevel anterior and posterior compression. *Clin Spine Surg* 2017;30(10):E1343–E1351
- 10 Hirabayashi K, Miyakawa J, Satomi K, Maruyama T, Wakano K. Operative results and postoperative progression of ossification among patients with ossification of cervical posterior longitudinal ligament. *Spine* 1981;6(04):354–364
- 11 Rhee JM, Shi WJ, Cyriac M, et al. The P-mJOA: a patient-derived, self-reported outcome instrument for evaluating cervical myelopathy: comparison with the mJOA. *Clin Spine Surg* 2018;31(02):E115–E120
- 12 Parke WW. Correlative anatomy of cervical spondylotic myelopathy. *Spine* 1988;13(07):831–837
- 13 Sekhon LH. Posterior cervical decompression and fusion for circumferential spondylotic cervical stenosis: review of 50 consecutive cases. *J Clin Neurosci* 2006;13(01):23–30
- 14 Kurokawa R, Kim P. Cervical laminoplasty: the history and the future. *Neurol Med Chir (Tokyo)* 2015;55(07):529–539
- 15 Yeh KT, Lee RP, Chen IH, et al. Laminoplasty instead of laminectomy as a decompression method in posterior instrumented fusion for degenerative cervical kyphosis with stenosis. *J Orthop Surg Res* 2015;10:138
- 16 Fehlings MG, Skaf G. A review of the pathophysiology of cervical spondylotic myelopathy with insights for potential novel mechanisms drawn from traumatic spinal cord injury. *Spine* 1998;23(24):2730–2737
- 17 White AA III, Panjabi MM. Biomechanical considerations in the surgical management of cervical spondylotic myelopathy. *Spine* 1988;13(07):856–860
- 18 Breig A, Turnbull I, Hassler O. Effects of mechanical stresses on the spinal cord in cervical spondylosis. A study on fresh cadaver material. *J Neurosurg* 1966;25(01):45–56
- 19 Wang T, Tian XM, Liu SK, Wang H, Zhang YZ, Ding WY. Prevalence of complications after surgery in treatment for cervical compressive myelopathy: a meta-analysis for last decade. *Medicine (Baltimore)* 2017;96(12):e6421