


CASE REPORT

High-risk Trans-Catheter Aortic Valve Replacement in a Failed Freestyle Valve with Low Coronary Height: A Case Report

Ashkan Karimi  · Negiin Pourafshar · George Dibu ·
Thomas M. Beaver · Anthony A. Bavry

Received: February 2, 2017 / Published online: March 28, 2017
© The Author(s) 2017. This article is an open access publication

ABSTRACT

A 55-year-old male with a history of two prior cardiac surgeries presented with decompensated heart failure due to severe bioprosthetic aortic valve insufficiency. A third operation was viewed prohibitively high risk and valve-in-valve trans-catheter aortic valve replacement was considered. There were however several high-risk features and technically challenging aspects including low coronary ostia height, poor visualization of the aortic sinuses, and difficulty in identification of the coplanar view due to severe aortic insufficiency, and a highly mobile aortic valve mass. After meticulous

peri-procedural planning, trans-catheter aortic valve replacement was carried out with a SAPIEN 3 balloon-expandable valve without any complication. Strategies undertaken to navigate the technically challenging aspects of the case are discussed.

Keywords: Trans-catheter aortic valve replacement; Freestyle aortic root; Bioprosthesis; Edwards SAPIEN 3 valve; Valve-in-valve

Enhanced content To view enhanced content for this article go to <http://www.medengine.com/Redeem/E8F7F0605B873386>.

A. Karimi · G. Dibu · A. A. Bavry (✉)
Division of Cardiovascular Medicine, Department of
Medicine, University of Florida, Gainesville, FL, USA
e-mail: anthony.bavry@va.gov

N. Pourafshar
Division of Nephrology, Department of Medicine,
University of Virginia, Charlottesville, VA, USA

T. M. Beaver
Division of Thoracic and Cardiovascular Surgery,
Department of Surgery, University of Florida,
Gainesville, FL, USA

A. A. Bavry
North Florida/South Georgia Veterans Health
System, Gainesville, FL, USA

INTRODUCTION

Trans-catheter aortic valve replacement (TAVR) technology has seen exponential growth in its utilization and astounding innovation in its design over the past few years. Steadfast improvement in its outcomes has quickly expanded testing this technology from inoperable and high-risk surgical patients to intermediate-risk and recently low-risk profile patients. In these studies, only patients with pure and clear-cut aortic stenosis are randomized and patients with complicating features such as mixed aortic valve disease with >3+ aortic insufficiency, intracardiac evidence of mass, thrombus or vegetation, and low coronary ostia height are excluded (supplementary appendix PARTNER trial) [1]. Nonetheless, in real life practice, there are patients with severe aortic

valve disease who have these complicating features but are also at prohibitively high risk for surgical aortic valve replacement (SAVR) and TAVR, although associated with higher procedural risk, would be the only treatment option. This case report illustrates a patient with a combination of these complicating features who underwent successful and uneventful TAVR after appropriate steps were taken to predict, prevent, and react to possible complications.

CASE REPORT

The patient is a 55-year-old male with history of bicuspid aortic valve who had undergone SAVR with a 27-mm Freestyle stentless aortic root bioprosthesis (Medtronic Inc., Minneapolis, MN, USA) by modified subcoronary technique 10 years prior to current presentation and subsequently three-vessel coronary artery bypass graft (CABG) 3 years ago. He presented to an outside hospital with chest pain and shortness of breath for a few days. Cardiac enzymes were elevated and he was found to be in acute decompensated heart failure and acute renal failure. Trans-thoracic echocardiogram (TTE) revealed new mild left ventricular (LV) systolic dysfunction with an ejection fraction of 40–45%, moderate LV dilation with LV end diastolic diameter of 65 mm, severe aortic insufficiency with a pressure-half time of 122 ms, and diastolic flow reversal in the descending and abdominal aorta. There was also a 20 × 4-mm elongated highly mobile density associated with the bioprosthetic aortic valve (video 1). The systolic velocity and gradient across the Freestyle root were also elevated with peak velocity of 3.6 m/s and mean gradient of 26 mmHg. He also underwent left heart catheterization. Aortogram also showed severe aortic insufficiency. Left coronary artery (LCA) angiogram showed the left anterior descending (LAD) has 80% proximal stenosis and there was competitive flow into an obtuse marginal (OM) branch. The left internal mammary artery (LIMA) graft to the left anterior descending (LAD) and the saphenous vein graft (SVG) to an OM branch

were patent, but the SVG to the right coronary artery (RCA) had 90% mid-segment stenosis and the native RCA had two tandem 75% mid-segment stenosis (video 2). He was medically treated and evaluated by a surgeon at the referring institution but was found to be a poor surgical candidate for third-time sternotomy for redo CABG and AVR and was referred to our institution for a second opinion. He provided informed consent to receive treatment at our institution. He was admitted to the intensive care unit and was medically treated for severe aortic insufficiency with nitroglycerin infusion and was empirically treated with broad-spectrum antibiotics for possible endocarditis. His STS risk score was calculated as 16.6% for operative mortality. His case was discussed at our weekly valve meeting and two surgeons concurred that open CABG and AVR would be extremely high risk; additionally, the surgeons were concerned about severe adhesions commonly present between a stentless valve and the native aortic root which requires total aortic root replacement in over 60% of these patients and adds to the complexity of the surgery [2]. His blood cultures remained negative, antibiotics were discontinued, and the mobile density on the bioprosthesis was thought to be either a healed vegetation or degenerative valve leaflet prolapse. There was a lot of trepidation to offer TAVR, mainly because of the presence of the highly mobile density associated with the bioprosthetic valve and the risk of its embolization; nonetheless, because he was critically ill and TAVR seemed to be the only bailout and given his relative young age, the decision was made to complete TAVR work-up. Computed tomography angiography (CTA) was performed and the images were analyzed with the 3mensio software (3mensio Medical Imaging BV, Bilthoven, The Netherlands). The CTA showed low coronary ostia height with right coronary height of 6.7 mm and left coronary height of 7.9 mm (Fig. 1a). The aortic sinuses of Valsalva were relatively small: left coronary sinus = 25 mm, right coronary sinus = 23 mm, and non-coronary sinus = 24 mm (Fig. 1b). This was partially due to the subcoronary technique used to implant the freestyle root, which entails

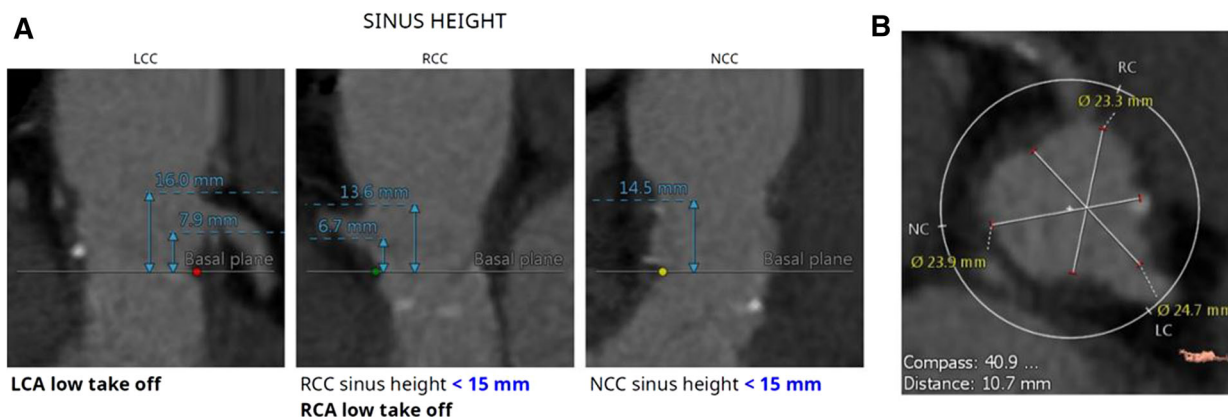


Fig. 1 CT angiogram. CTA shows low origin of the right and left coronary arteries with LCA ostium height of 7.9 mm, and RCA ostium height of 6.7 mm (a). The aortic sinuses of Valsalva are also relatively small (b)

trimming of the sinuses. The Coplanar view was not well visualized on the CT scan because of severe aortic insufficiency and poor visualization of the aortic sinuses. The bioprosthesis and the aortic valve annulus were minimally calcified. The aortic annular area was measured as 405 mm² and the perimeter-derived annulus diameter was calculated as 22.7 mm. The lower extremity vessel diameters were large enough to allow a transfemoral approach. The complex nature of TAVR and the risk of embolization, stroke, and coronary occlusion were discussed with the patient and his family, but since the alternative was medical treatment and hospice, he decided to proceed with TAVR. We decided to perform TAVR with the Edwards SAPIEN 3 valve (Edwards Lifesciences Inc., Irvine, CA, USA). The CoreValve (Medtronic, Minneapolis, MN, USA) requires greater manipulation during deployment and in our opinion would be more likely to cause embolization of the aortic valve mass; additionally, the sinuses of Valsalva were too small for a CoreValve. Pre-procedural CT measured the aortic valve annular area to be 405 mm², which corresponds to a 23-mm SAPIEN 3; however, a 27-mm freestyle root has a internal diameter of 25 mm and based on the valve-in-valve mobile application a 29-mm SAPIEN 3 valve was recommended. In valve-in-valve TAVRs, when the type and size of the degenerative bioprosthetic surgical valve are known, we size the TAVR valve based on the known inner diameter of the bioprosthetic

valve and not CT scan or trans-esophageal echocardiography (TEE) measurements since non-invasive measurements can be inaccurate in this setting [3]. We are particularly concerned about undersizing in stentless valve-in-valve TAVR because there is not a stent scaffold to anchor the valve and undersizing imposes additional risk for valve embolization. The other challenge facing us was low coronary ostia height, which, in combination with small sinuses of Valsalva, increased the risk of coronary obstruction. Additionally, the presence of the elongated 20-mm mobile mass on the right coronary cusp posed additional risk for RCA occlusion. Although prior studies have shown that self-expandable valves are associated with lower risk of coronary occlusion [4], as discussed earlier, we chose the Edwards SAPIEN 3 valve because of concern over potential embolization of the mass and also due to the small size of the sinuses. Despite previous CABG and bypass of the distal left anterior descending artery and an obtuse marginal branch, we still felt that occlusion of the left coronary system would be a catastrophic event, and although the RCA was bypassed distally, both the native RCA and the graft to the RCA had significant disease and occlusion of the RCA could also cause significant ischemia. Therefore, we decided to protect both coronaries. A JL4 guide catheter was used to engage the left main and a JR guide catheter was used to engage the RCA. Both vessels were wired

with 0.014" prowater. A 3.5 × 8-mm Xience stent (Abbott Vascular, Santa Clara, CA, USA) was positioned into the left circumflex artery and a 2.5 mm × 23-mm stent was positioned in the mid RCA, ready to be retracted and deployed in case of coronary occlusion. Both guide catheters were then pulled back prior to valve deployment. As shown in the root angiogram prior to the valve deployment (video 3A), another technical challenge was poor visualization of the aortic sinuses due to severe aortic insufficiency and lack of landmark for accurate valve positioning since the Free-style root does not possess a radiopaque ring marker or visible posts. We used the position of the pigtail in the aortic sinus as a crude marker for the base of the aortic sinuses and guidewires in the right and left coronary artery served as landmarks to position the top of the SAPEIN 3 valve below this level to avoid coronary occlusion. After the 29-mm SAPIEN 3 valve was positioned at the desired location, rapid ventricular pacing was performed and the valve was deployed without immediate complication (video 3B). Subsequently, left (video 3C) and right (video 3D) coronary angiograms showed that the coronary ostia were not covered. The left coronary artery wire and undeployed stent were removed. The mid RCA stenosis was treated with a 2.5 × 23-mm Xience stent and a 3.0 × 15-mm Xience stent was slightly overlapped with the first stent to cover the more proximal RCA stenosis. Post-dilation was performed with a 3 × 20-mm NC Trek™ balloon (Abbott Vascular, Santa Clara, CA, USA) with resolution of the mid RCA stenosis (video 3E). Final root angiogram showed no evidence of aortic insufficiency (video 3F). Intra-operative TEE showed good valve position with no para-valvular leak (video 4) with peak velocity of 2.1 m/s and mean gradient of 6 mmHg across the TAVR valve. The aortic regurgitation index increased from 0.15 prior to TAVR to 0.47 post-TAVR. He tolerated the surgery well and was discharged 6 days later with no peri-operative complication or embolic event. He was subsequently seen in follow-up at 1 month and the TAVR valve was functioning normally. He has since been following up with his local cardiologist.

DISCUSSION

Valve-in-valve TAVR for high-risk patients with bioprosthetic aortic valve degeneration is a niche application of TAVR. This case report illustrates TAVR in an inoperable patient with significant bioprosthetic aortic valve insufficiency in the presence of several technically challenging aspects and high-risk features including low coronary ostia height, poor visualization of the aortic sinuses, and the coplanar view due to severe aortic insufficiency, and a highly mobile aortic valve mass. The main risk in our patient was the risk of coronary occlusion given the low coronary ostia height, small sinuses, and bulky aortic valve mass. Previously reported risk factors for coronary obstruction during TAVR include valve-in-valve procedure especially in bioprostheses with internal stent frame or as in our case with no stent frame, low coronary ostia height, high leaflet profile with bulky leaflet calcification especially at the tips, and narrow sinuses of Valsalva [5, 6]. Aortogram during balloon inflation can be used as a strategy to assess the potential for coronary occlusion prior to TAVR [5], but in our case because of the presence of a large mobile AV mass and risk of its embolization, we decided not to utilize this technique in order to minimize the number of balloon inflations across the aortic valve. Wiring the coronaries and delivering stents prior to valve deployment is a safe bailout strategy, and if coronary occlusion occurs, the stent can be readily pulled back and deployed [7]. Additionally, in our case the wires in the coronaries served as landmarks to deploy the valve below their level and avoid coronary occlusion. The other risky feature of our case was the risk of embolization of the aortic valve mass. TAVR has been rarely attempted in the presence of a mobile aortic valve mass. Our literature search in PubMed for TAVR in the setting of mobile aortic valve mass yielded only one case report in which a 78-year-old man underwent TAVR with the CoreValve system in the presence of a 1 × 0.4-cm mobile aortic valve mass. He suffered immediate peri-procedural stroke and the embolized valve tissue was extracted with endovascular technique [8].

Although none of the embolic protection devices are currently FDA-approved, and we did not have experience in using these devices, their usage should be considered in experienced centers in the presence of mobile aortic valve mass, and we found a case report in which the Claret CE Pro™ (Claret Medical, Inc. Santa Rosa, CA, USA) embolic protection device was utilized in Europe in a patient with a mobile mass at the tip of the aortic valve leaflet and TAVR was performed without peri-procedural stroke [9].

CONCLUSIONS

High-risk anatomical features should not dissuade experienced operators from offering TAVR to inoperable patients in whom TAVR is the only viable option and the alternative is medical therapy, which carries a dire prognosis in severe AV disease; nevertheless, the patient needs to have a clear understanding of the increased risk of the procedure. TAVR can still be carried out in these patients if there is meticulous procedural planning, potential complications are anticipated, and appropriate preparations are made to avoid them or to deal with them if they occur.

ACKNOWLEDGEMENTS

No funding or sponsorship was received for this study or publication of this article. All named authors meet the International Committee of Medical Journal Editors (ICMJE) criteria for authorship for this manuscript, take responsibility for the integrity of the work as a whole, and have given final approval for the version to be published.

Disclosures. Anthony Bavry is a contractor for the American College of Cardiology and has received travel support from Edwards. Ashkan Karimi, Negiin Pourafshar, George Dibu, and Thomas Beaver do not have any financial disclosure relevant to the content of this case report.

Compliance with Ethics Guidelines. Informed consent was obtained from the patient for being included in the study.

Open Access. This article is distributed under the terms of the Creative Commons Attribution-NonCommercial 4.0 International License (<http://creativecommons.org/licenses/by-nc/4.0/>), which permits any noncommercial use, distribution, and reproduction in any medium, provided you give appropriate credit to the original author(s) and the source, provide a link to the Creative Commons license, and indicate if changes were made.

REFERENCES

1. Supplementary appendix of the PARTNER Trial. http://www.nejm.org/doi/suppl/10.1056/NEJMoa1103510/suppl_file/nejm103510_appendix.pdf. Accessed 12 Dec 2016.
2. Borger MA, Prasongsukarn K, Armstrong S, Feindel CM, David TE. Stentless aortic valve reoperations: a surgical challenge. *Ann Thorac Surg.* 2007;84(3):737–43 (discussion 43–4).
3. Bapat VN, Attia R, Thomas M. Effect of valve design on the stent internal diameter of a bioprosthetic valve: a concept of true internal diameter and its implications for the valve-in-valve procedure. *JACC Cardiovasc Interv.* 2014;7(2):115–27.
4. Ribeiro HB, Nombela-Franco L, Urena M, et al. Coronary obstruction following transcatheter aortic valve implantation: a systematic review. *JACC Cardiovasc Interv.* 2013;6(5):452–61.
5. Dvir D, Leipsic J, Blanke P, Ribeiro HB, et al. Coronary obstruction in transcatheter aortic valve-in-valve implantation: preprocedural evaluation, device selection, protection, and treatment. *Circ Cardiovasc Interv.* 2015;8(1):e002079.
6. Ribeiro HB, Webb JG, Makkar RR, et al. Predictive factors, management, and clinical outcomes of coronary obstruction following transcatheter aortic valve implantation: insights from a large multicenter registry. *J Am Coll Cardiol.* 2013;62(17):1552–62.
7. Abramowitz Y, Chakravarty T, Jilaihawi H, et al. Clinical impact of coronary protection during transcatheter aortic valve implantation: first reported series of patients. *EuroIntervention.* 2015;11(5):572–81.

-
8. Anuwatworn A, Raizada A, Kelly S, Stys T, Jonsson O, Stys A. Stroke with valve tissue embolization during transcatheter aortic valve replacement treated with endovascular intervention. *JACC Cardiovasc Interv.* 2015;8(9):1261–3.
 9. Roy J, Byrne J, MacCarthy P. A mobile echodense mass on pre-TAVI echocardiography: strategies for stroke prevention. 2016. <https://www.pronline.com/Cases-resources-images/Cases/Read-share-cases>. Accessed 10 Dec 2016.