

Influence of Small, Midi, Medium and Large Fields of View on Accuracy of Linear Measurements in CBCT Imaging: Diagnostic Accuracy Study

Hanaa Elshenawy^{1*}, Wessam Aly¹, Nashwa Salah², Sherine Nasry¹, Enas Anter³, Khalid Ekram²

¹Department of Surgery and Oral Medicine, National Research Center, Cairo, Egypt; ²Oral Radiology Department, Faculty of Oral and Dental Medicine, Cairo University, Cairo, Egypt; ³Faculty of Oral and Dental Medicine, Cairo University, Cairo, Egypt

Abstract

Citation: Elshenawy H, Aly W, Salah N, Nasry S, Anter E, Ekram K. Influence of Small, Midi, Medium and Large Fields of View on Accuracy of Linear Measurements in CBCT Imaging: Diagnostic Accuracy Study. Open Access Maced J Med Sci. 2019 Mar 30; 7(6):1037-1041. <https://doi.org/10.3889/oamjms.2019.232>

Keywords: Fields of view; Linear Measurements; CBCT; Diagnostic Accuracy

***Correspondence:** Hanaa Elshenawy, Department of Surgery and Oral Medicine, National Research Center, Cairo, Egypt. E-mail: dr.hanaa.shenawy@gmail.com

Received: 03-Feb-2019; **Revised:** 21-Mar-2019; **Accepted:** 22-Mar-2019; **Online first:** 29-Mar-2019

Copyright: © 2019 Hanaa Elshenawy, Wessam Aly, Nashwa Salah, Sherine Nasry, Enas Anter, Khaled Ekram. This is an open-access article distributed under the terms of the Creative Commons Attribution-NonCommercial 4.0 International License (CC BY-NC 4.0)

Funding: This research did not receive any financial support

Competing Interests: The authors have declared that no competing interests exist

AIM: This study aimed to assess the effect of changing the field of view on the dimensional accuracy of CBCT imaging.

METHODS: The implant-bone models were randomly numbered from 1 to 13 by the principal researcher, and then on each model at the incisors region three positions were selected and marked on the model with a permanent blue marker. Then at each marked position three radio-opaque 'RO' markers "gutta-percha pieces" were glued on the model surfaces as following; two pieces on the facial surface one occlusally (at the alveolar crest) and one apically (at the inferior border of the model) both were on the same vertical line and perpendicular to the horizontal plane, while the third one was placed on the lingual surface opposing the occlusally placed buccal piece. CBCT examinations of each bone model were performed using Cranex3Dx CBCT (Helsinki, Finland) machine. Each model was scanned four times with standardised tube current and voltage of 12.5 mA and 90 kVp respectively at four different FOVs. The FOVs used were as following: Small FOV: 50 x 50 mm with voxel size 200 µm, Midi FOV: 61 x 78 mm with voxel size 300 µm, Medium FOV: 78 x 78 mm with voxel size 300 µm, Large FOV: 78 x 150 mm with voxel size 350 µm. The reference standard in this study was the real linear measurements that were obtained directly on the implant-bone models using high precision sliding electronic digital calliper with 0-150 mm internal and external measuring range and 0.01 mm resolution accuracy. The index test in the current study was the CBCT linear measurements obtained from CBCT images of implant-bone models using small, midi, medium and large FOVs.

RESULTS: The results of this study showed that both medium and large FOVs showed a statistically significant difference, which could be translated into clinical relevance only in thickness measurements.

CONCLUSION: The interpretation of these results leads to the assumption that increasing the FOV size together with voxel size could adversely affect the accuracy of CBCT linear measurements, especially when small distances are to be assessed.

Introduction

Accurate and reliable linear measurements are considered very important issue in the field of oral and maxillofacial medicine, as almost all the dentists depend on such measurements in diagnosing, treatment planning and treatment outcome monitoring for multitude of cases in different dental specialities, of which, dental implantology, endodontics, forensic dentistry, orthodontics and orthognathic. CBCT was found to provide high resolution, distortion-free and

accurate images for craniofacial structures without the magnification or superimposition problems of 2D images. Regarding the accuracy of linear measurements, CBCT was reported by several studies to be beneficial as it provides accurate and reliable measurements. However, a question mark is still posed regarding the radiation dose CBCT delivers to the patient as, despite its considerable merits, CBCT creates a great problem because of the higher patient's radiation dose compared to 2D radiography [1], [2], [3].

Materials

The study was performed on thirteen implant bone models obtained from Nissin Dental Products, Procedures of the study including implant bone models preparations, marking of the measurement's sites and measurements of the gold standard were performed in the Oral and Maxillofacial Radiology department, Faculty of Dentistry, Cairo University while Procedures of the study including imaging process, software manipulation of the resultant images and CBCT measurements were performed at a private radio-diagnostic centre.

The implant-bone models were randomly numbered from 1 to 13 by the principal researcher, and then on each model at the incisors region, three positions were selected and marked on the model with a permanent blue marker.

Then at each marked position three radio-opaque 'RO' markers "gutta-percha pieces" were glued on the model surfaces as following; two pieces on the facial surface one occlusally (at the alveolar crest) and one apically (at the inferior border of the model) both were on the same vertical line and perpendicular to the horizontal plane, while the third one was placed on the lingual surface opposing the occlusally placed buccal piece. The RO markers were obtained by cutting gutta-percha cones size 60 using sharp scissors into small pieces of nearly 1-1.5 mm length, and the cut pieces were glued to the selected landmarks using a cyanoacrylate gel. CBCT examinations of each bone model were performed using Cranex3Dx CBCT (Helsinki, Finland) machine. Each bone model was properly positioned in the machine with the help of the laser beam indicators of the machine such that the vertical laser beam coincided with the mid-sagittal plane (perpendicular to the floor) and the horizontal laser beam coincided with the occlusal plane (parallel to the floor).

Each model was scanned four times with standardised tube current and voltage of 12.5 mA and 90 kVp respectively at four different FOVs.

The FOVs used were as following;

Small FOV: 50 x 50 mm with voxel size 200 μm

Midi FOV: 61 x 78 mm with voxel size 300 μm .

Medium FOV: 78 x 78 mm with voxel size 300 μm .

Large FOV: 78 x 150 mm with voxel size 350 μm .

The reference standard in this study was the real linear measurements that were obtained directly on the implant-bone models using high precision sliding electronic digital calliper with 0-150 mm

internal and external measuring range and 0.01 mm resolution accuracy.

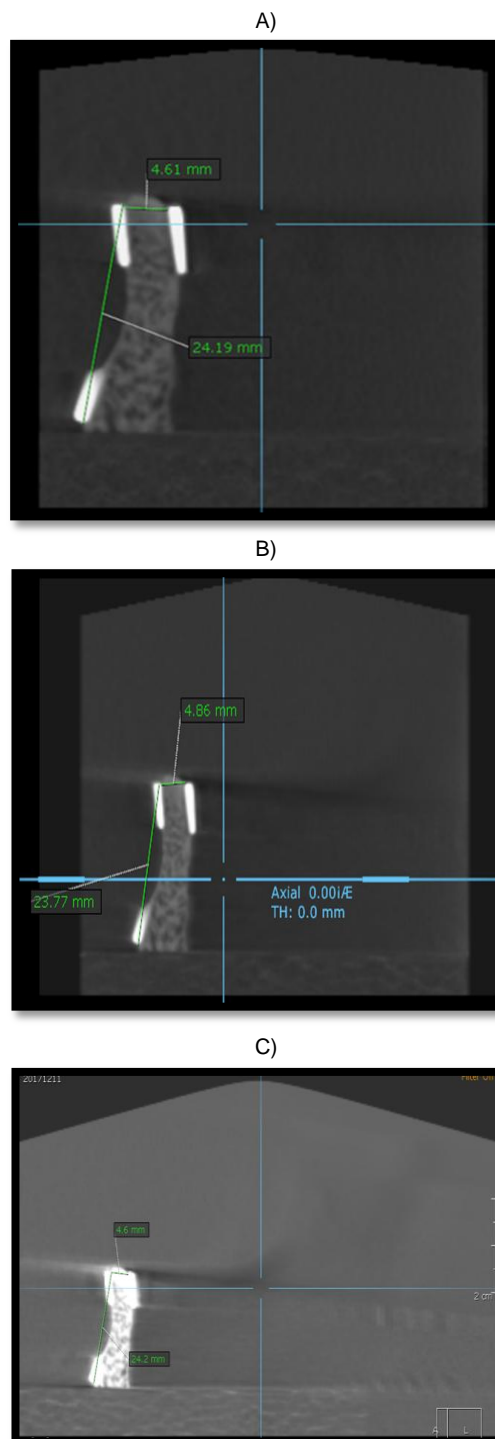


Figure 1: A) CBCT linear measurement of bone height & thickness on Small FOV CBCT images; B) CBCT linear measurement of bone height & thickness on Medium FOV CBCT images; C) CBCT linear measurement of bone height & thickness on Large FOV CBCT images

On each model at the three predetermined and marked positions the following linear measurements were taken:

Bone Height: this was measured on the facial surface of the model as the distance between the

superior end of the occlusal placed gutta-percha piece, and inferior end of the apically placed one.

Bucco-lingual “BL” Bone Thickness: this was measured as the distance from the superior end of the occlusal placed facial gutta-percha piece to the superior end of the gutta-percha piece placed on the lingual surface.

Mesio-Distal “MD” Bone Width: This was measured as the distance between the superior ends of two adjacent gutta-percha pieces on the facial surface.

CBCT DICOM files were exported to third-party software OnDemand3d[®] for CBCT linear measurements to be taken on a personal computer (13.3-inch LED-backlit display; 2560 x 1600 native resolution at 227 pixels/inch), where the CBCT scans were displayed on MPR screen [displaying the volumetric data set in axial, coronal, and sagittal image slices]. The CBCT linear measurements were taken in each of the marked areas as the image slices with the radio-opaque markers best visible were used for linear measurements using distance icon on the tool bar, in each area bone height, BL thickness, and MD width measurements were made exactly like those made on the bone model with the digital calliper. Both height and thickness measurements were taken on the corrected sagittal images (Figure 1A, 1B and 1C), while width measurements were taken on the corrected axial images (Figure 2A, 2B, 2C, and 2D).

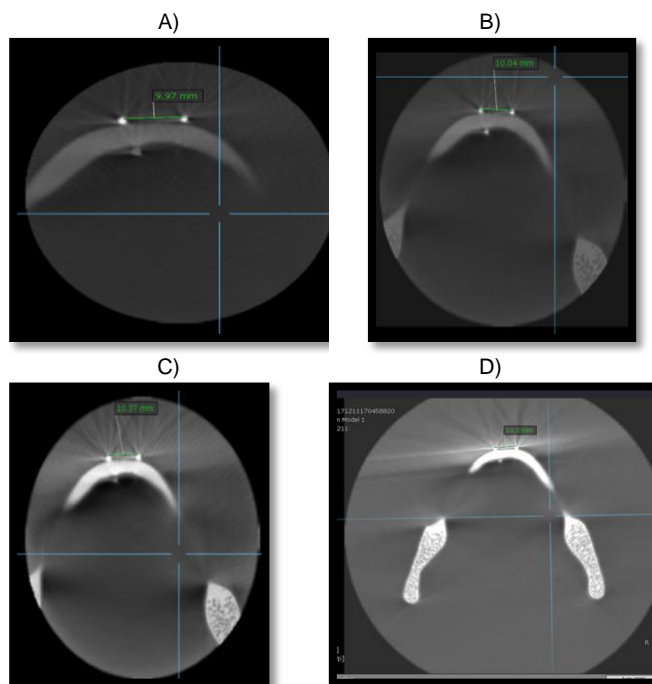


Figure 2: A) CBCT linear measurement of bone width on Small FOV CBCT images; B) CBCT linear measurement of bone width on Midi FOV CBCT images; C): CBCT linear measurement of bone width on Medium FOV CBCT images; D) CBCT linear measurement of bone width on Large FOV CBCT images

Results

Numerical data, including all the measurements taken from the gold standard (GS) and CBCT measurements in the four FOVs, were explored for normality by checking the data distribution using Kolmogorov-Smirnov and Shapiro-Wilk tests, all measurements showed normal (parametric) distribution. Data were presented as Mean ± Standard Deviation (SD), Minimum and Maximum.

Table 1: AME, and APE

	Small FOV		Midi FOV		Medium FOV		Large FOV		P-value
	Mean	SD	Mean	SD	Mean	SD	Mean	SD	
AME (mm)	0.18 ^B	0.09	0.11 ^B	0.07	0.20 ^A	0.18	0.42 ^A	0.28	<0.001*
APE (%)	0.73 ^B	0.36	0.44 ^B	0.40	0.82 ^A	0.79	1.67 ^A	1.16	<0.001*

*: Significant at P ≤ 0.05, Different superscripts in the same row are statistically significantly different.

Checking data distribution for error measurements and percentage of error measurements showed non-normal (non-parametric) distribution. Data were presented as mean, median, standard deviation (SD), minimum, maximum and 95% Confidence Interval (95% CI) for the mean values.

Table 2: Measurement errors

	Small FOV		Midi FOV		Medium FOV		Large FOV		P-value
	Mean	SD	Mean	SD	Mean	SD	Mean	SD	
Absolute Measurement error (mm)	0.11 ^B	0.04	0.14 ^B	0.04	0.3 ^A	0.15	0.40 ^A	0.21	<0.001*
Measurement error (%)	2.39 ^B	1.01	3.03 ^B	1.13	6.42 ^A	3.49	8.37 ^A	4.89	<0.001*

*: Significant at P ≤ 0.05, Different superscripts in the same row are statistically significantly different.

For parametric data; Paired t-test was used to compare between FOV measurements and the standard reference. For non-parametric data; Friedman’s test was used to compare between measurement errors as well as the percentage of error measurements of the four FOV. Dunn’s test was used for pair-wise comparisons when Friedman’s test is significant.

The significance level was set at P ≤ 0.05. Statistical analysis was performed with IBM, SPSS Statistics Version 20 for Windows.

A. Mean, standard deviation (SD) values and results of Friedman’s test for the comparison between errors of height measurements by the four CBCT FOVs.

B. Mean, standard deviation (SD) values and results of Friedman’s test for the comparison between errors of BL depth measurements by the four FOV.

Discussion

The first one was reported in 2010 [5]. Unlike the results of our study, they concluded that changes in FOV did not affect measurement accuracy, although they assessed small linear distances in their study (diameter & depth of chemically created periapical lesions). They utilised only two different FOVs and voxel sizes (6 inches & 9 inches FOVs using voxel sizes 0.11 & 0.19 mm³ respectively). They reported that the difference between measurement errors in the two used FOVs was non-significant statistically, however on revising their measurements error values, high percentage error that exceeded the clinically acceptable level were found in both FOVs, as they reported that error values for 6 inches FOV ranged from -0.68 to 0.80 mm, (-11.46% to 17.03%) for diameter measurements, and from -0.73 to 0.53 mm (-13.51% to 10.82) for depth measurements, while for the larger FOV (9 inches), the error values ranged from -0.64 to 0.81 mm, (-12.41% to 16.95%) for diameter measurements, and from -0.72 to 0.52 mm (-13.50% to 10.63%) for depth measurements.

Comparing the results of the previous study [5] with ours, showed that the level of CBCT linear measurements accuracy reported in their study is much lower than ours, although both voxel sizes utilised in their study was smaller than the smallest voxel size we used. However, their FOVs used were larger than the largest FOV we used. Moreover they assessed much smaller distances than we did.

The second study found was conducted in 2014 [6]; it aimed to assess the effect of FOV on both identification and measurements (linear & volumetric) of peri-implant bone defects with different sizes. Again, they concluded that the three utilised CBCT FOVs (40 × 40, 60 × 60 and 100 × 100 mm, with voxel sizes 0.08, 0.125, 0.25 mm³ respectively) yielded measurements that were strongly correlated to the actual real measurements; however, they didn't report the error values in their study! On the other hand, similar to the results of this study, they reported that both the detection ability and measurements accuracy were higher in larger defects, and smaller FOVs.

Again, in 2016 Ganguly et al., [7] study concluded that the reduction of FOV and Voxel size is not associated with greater accuracy of CBCT linear measurements. This study was differing from ours and other similar studies in utilizing two different CBCT machines, as each of the four cadavers used in the study was imaged twice by iCAT machine with FOV 13 × 16 cm (once with voxel sizes 0.2 mm³ & once with 0.3 mm³) then was imaged again by Planmeca Promax 3D machine with FOV 5 × 8 cm and 0.16 mm³ voxel size. These scans were named as protocols 1, 2 and 3 respectively. Their mean CBCT AME values were 1.10 ± 1.3 mm, 1.2 ± 1.5 mm, and 1.1 ± 1.4 mm for protocols 1, 2, and 3 respectively. Although their error values were larger than those reported in our

study, but this could be attributed to the fact that they did their study on cadaver heads with presence of soft tissues that add more radiation scatter, while ours was made on bone models with increased contrast between the external surface of the model and the surrounding air making it easier to identify landmarks and thereby explaining the higher accuracy of measurements. Contradicting our findings, Ganguly et al., [7] reported that as the measurements became larger, larger discrepancies were found between the measurements.

The last study found was published in 2016 by Anter et al., [8], who also concluded that changing the FOV doesn't affect CBCT linear measurements accuracy, this study utilized three FOVs (small 80 × 80 mm, medium 100 × 100 mm and large 200 × 100 mm) and unlike the similar studies they standardized the voxel size to be 0.2 mm in the three FOVs. Their reported mean CBCT measurement errors for the small, medium and large FOVs were 0.23 ± 0.09 mm, 0.24 ± 0.10 mm and 0.21 ± 0.09 mm respectively, which are very close to those reported in our study. However, they recommended the usage of smaller FOVs whenever possible to reduce the patient's radiation dose. The previous study was the only one that assessed the effect of FOV solely which is ideally relating the resultant effectiveness to the examined variable, however in clinical situations, most of the available CBCT machines don't allow for usage of small voxel sizes with large FOVs, and even when it is possible, it results in very high patient radiation dose.

Finally, the contradiction found between our results and those of other researchers could be attributed to any of multiple factors like difference in purposes with a resultant difference in the technical parameters used, type of the CBCT machine and type of CBCT images used for measurements. There were also differences in the qualifications and the numbers of observers who interpreted the radiographic data in the different studies.

From the results of this study, we can conclude that CBCT scans made with smaller FOVs and voxel sizes are associated with higher linear measurements accuracy than those made with larger FOVs and voxel sizes. For the same voxel size, smaller FOVs are associated with higher CBCT linear measurements accuracy than those made with larger FOVs. The shorter the distances measured, the greater is the effect of FOV and voxel size on the reported CBCT measurement accuracy.

References

1. Gupta S, Patil N, Solanki J, Singh R, Laller S. Oral Implant Imaging: A Review. The Malaysian Journal of Medical Sciences: MJMS. 2015; 22:7-17. PMID:26715891 PMCID:PMC4681716

2. Chuenchompoonut V, Ida M, Honda E, Kurabayashi T, Sasaki T. Accuracy of panoramic radiography in assessing the dimensions of radiolucent jaw lesions with distinct or indistinct borders. *Dentomaxillofac Radiol.* 2003; 32:80-6. <https://doi.org/10.1259/dmfr/29360754> PMID:12775660
3. Nagarajan A, Perumalsamy R, Thyagarajan R, Namasivayam A. Diagnostic Imaging for Dental Implant Therapy. *Journal of Clinical Imaging Science.* 2014; 4:4. <https://doi.org/10.4103/2156-7514.143440> PMID:25379354 PMCID:PMC4220422
4. Tarazona-Álvarez P, Romero-Millán J, Pe-arrocha-Oltra D, Fuster-Torres MÁ, Tarazona B, Pe-arrocha-Diago M. Comparative study of mandibular linear measurements obtained by cone beam computed tomography and digital calipers. *Journal of clinical and experimental dentistry.* 2014; 6:e271. <https://doi.org/10.4317/jced.51426> PMID:25136429 PMCID:PMC4134857
5. Kamburoğlu K, Kiliç C, Özen T, Horasan S. Accuracy of chemically created periapical lesion measurements using limited cone beam computed tomography. *Dentomaxillofacial Radiology.* 2010; 39:95-9. <https://doi.org/10.1259/dmfr/85088069> PMID:20100921 PMCID:PMC3520198
6. Kamburoğlu K, Murat SE, Kılıç C, Yüksel S, Avsever H, Farman A, Scarfe WC. Accuracy of CBCT images in the assessment of buccal marginal alveolar peri-implant defects: effect of field of view. *Dentomaxillofacial Radiology.* 2014; 43:20130332. <https://doi.org/10.1259/dmfr.20130332> PMID:24645965 PMCID:PMC4082260
7. Ganguly R, Ramesh A, Pagni S. The accuracy of linear measurements of maxillary and mandibular edentulous sites in cone-beam computed tomography images with different fields of view and voxel sizes under simulated clinical conditions. *Imaging science in dentistry.* 2016; 46:93-101. <https://doi.org/10.5624/isd.2016.46.2.93> PMID:27358816 PMCID:PMC4925656
8. Anter E, Zayet MK, El-Dessouky SH. Effect of Field of View On the Accuracy of Cone Beam Computed Tomographic Assessment of Alveolar Bone Loss in Periodontal Defects. *Egyptian Dental Journal.* 2016; 62:814.