

Available online at www.sciencedirect.com

ScienceDirect

journal homepage: www.elsevier.com/locate/ihj

Case Report

Removal of the broken part of implantable cardioverter-defibrillator's electrode causing pulmonary embolism via femoral vein



Cemil Zencir ^{a,*}, Mithat Selvi ^a, Huseyin Elbi ^b, Mustafa Cetin ^c,
Hasan Gungor ^a, Cagdas Akgullu ^a, Muharrem Ismail Badak ^d

^a Adnan Menderes University, School of Medicine, Department of Cardiology, Turkey

^b Celal Bayar University, School of Medicine, Department of Family Medicine, Turkey

^c Adiyaman University, School of Medicine, Department of Cardiology, Turkey

^d Adnan Menderes University, School of Medicine, Department of Cardiovascular Surgery, Turkey

ARTICLE INFO

Article history:

Received 26 February 2015

Accepted 4 June 2015

Available online 22 December 2015

Keywords:

Infective endocarditis

Electrode

Pulmonary embolism

ABSTRACT

A 66-year-old patient with idiopathic dilated cardiomyopathy underwent transvenous extraction of an implantable cardioverter-defibrillator. The distal part of the electrode was broken during manual traction through the left subclavian vein. In the present case, we showed a rare complication of transvenous lead extraction and its management.

© 2015 Cardiological Society of India. Published by Elsevier B.V. All rights reserved.

1. Introduction

With the growing number of recently published studies, the number of cardiac pacemaker implantations has also dramatically increased.^{1–3} This increase has also been related with higher rate of device-related infections (0.8–5.7%) and so necessitates its removal.⁴ Treatment of infective endocarditis includes extraction of the device and initiation of relevant antibiotics.⁵ According to various case series, extraction of pacemaker electrodes is related with various complications, including myocardial and vascular injuries, acute pericardial tamponade, hemothorax, and tricuspid valve injury.^{6,7}

Pulmonary embolism of the lead or broken part of lead materials is so rare. In this case report, we present an implantable cardioverter-defibrillator (ICD) extraction process and management of pulmonary lead embolism.

2. Case report

>A 66-year-old woman, who has an ICD implanted anterior to the left pectoral muscle by left subclavian vein entry-site approach on May 2012 with active fixation, was consulted to our clinic because of high fever and changes of mental status while preparing preoperatively for prolapsed uterine in the

* Corresponding author at: Adnan Menderes University, School of Medicine, Department of Cardiology, 09000, Aydin, Turkey. Tel.: +90 555 2786521; fax: +90 256 2144086.

E-mail address: drczencir@hotmail.com (C. Zencir).

0019-4832/\$ – see front matter © 2015 Cardiological Society of India. Published by Elsevier B.V. All rights reserved.

<http://dx.doi.org/10.1016/j.ihj.2015.06.004>

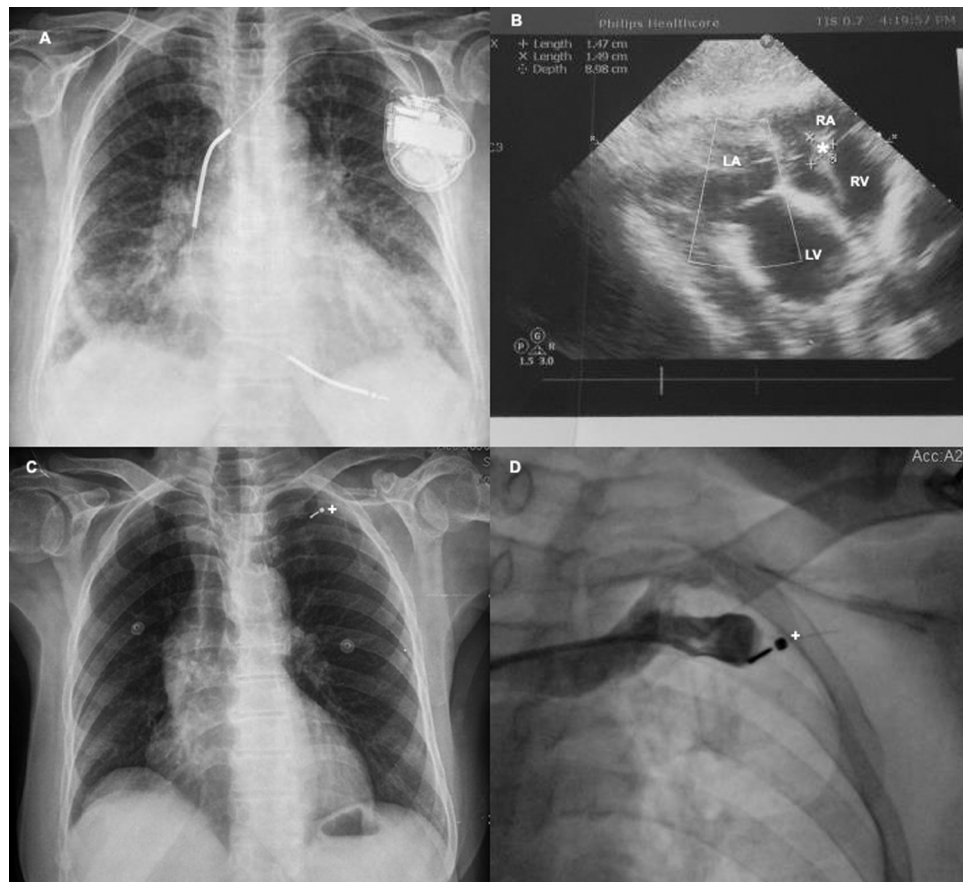


Fig. 1 – Chest X-ray image in the usual ICD (A), echocardiographic image of vegetation on the electrode (B), chest X-ray image in the regular electrode fragment (C), and left subclavian venography preventing passage opaque appearance as electrode fragment (D). RA, right atrium; RV, right ventricle; LA, the left atrium; LV, left ventricle; *, vegetation with thrombus; +, an electrode fragment.

obstetrics and gynecology clinic. As viewed by the chest X-ray, placement of ICD and electrode was normal (Fig. 1A). On the transthoracic echocardiography (TTE), there was endocarditis vegetation with dimensions of 1.5 cm × 2 cm on electrocatheter leads, especially in the level of the tricuspid valve (Fig. 1B). Subsequently, the patient was taken to intensive care unit with a diagnosis of infective endocarditis. Antibiotherapy was started. During the follow-up period, blood cultures were taken; however, there were no reproductions of microorganisms. After a week, there was no improvement in clinical situation of patient, and vegetation size did not change on TTE. Therefore, the patient underwent the transvenous extraction of whole system. Lead body dwelling time is 21 months. Currently, three different techniques have been used for electrode extraction: surgical extraction, percutaneous extraction by a superior approach, or percutaneous extraction by an inferior approach. Percutaneous extraction by superior approach procedure was performed with fluoroscopy in the catheterization laboratory. First, ICD battery was extracted. However, the distal part of the electrode was broken during manual traction through the left subclavian vein. Distal broken electrode fragment was left in the subclavian vein (Fig. 1C). Left subclavian venography revealed a broken electrode fragment

and thrombus formation, which was placed in the mid-subclavian vein (Fig. 1D, Video 1). Then, it was decided to extract the broken electrode fragment through the femoral approach. The broken electrode fragment was captured in subclavian vein with 25 mm snare (Amplatzer GooseNeck Snare, Covidien Co, MN, USA). The captured electrode fragment was embolized to the left pulmonary artery at the level of the right atrium (Fig. 2A). Pulmonary angiography showed embolized electrode fragment in branches of the left pulmonary artery and was captured once again by the help of the snare (Fig. 2B, Video 2). While the electrode fragment was pulling back at the level of the main pulmonary artery, it was fled to the right branch of pulmonary artery over again (Fig. 2C, Video 3). The broken electrode fragment was captured again with the snare in the right branch of pulmonary artery and was drawn up to the femoral vein. It was pulled to the right femoral vein. The fragment was greater than sheath diameter, and to avoid dissecting the scar tissue about the lead, it was removed by exploration of the femoral vein; afterwards, femoral vein was closed by cardiovascular surgery using primary suture with local anesthesia in the operating room. The broken electrode fragment was removed successfully and there were no residual fragments (Fig. 2D).

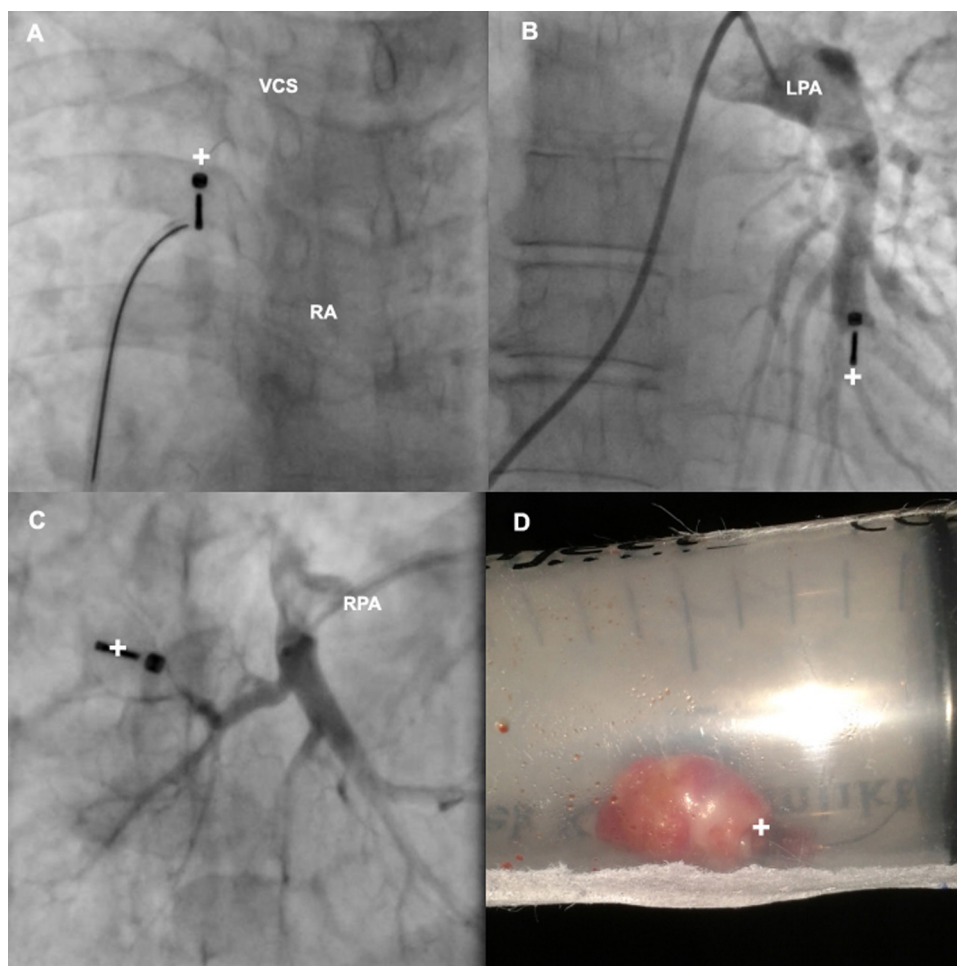


Fig. 2 – Snare caught up with the level of the right atrium severed electrode fragment (A), electrode fragment in the left pulmonary artery branch (B), electrode fragment in the right pulmonary artery branch (C), and electrode fragment (D). VCS, the superior vena cava; RA, right atrium; LPA, left pulmonary artery; RPA, right pulmonary artery; +, an electrode fragment.

3. Discussion

Infections and thrombosis that originate from cardiac pacemaker systems are rare, but are potentially lethal complications. They are responsible for significant raised morbidity and mortality. Infection of the cardiac pacemaker is the most important indication for requirement of the pacemaker-system extraction.⁸ Complications ranging from major bleeding to cardiac perforation may occur during the extraction by reason of the adhesions of the electrode.⁹ Electrode breakage and embolism is one of the rarest complications that could have occurred during the whole-system extraction. In this case, we present an extraction process of a broken electrode in subclavian vein and twice embolization to the pulmonary vascular system.

In recent literature, there are described case reports about the femoral vein approach, for the extraction of the pacemaker electrode by using a snare.^{10,11} The femoral vein approach for the extraction is anatomically known, safe, and most of the ligaments that hold the heart above does not create additional risks compared to traction due to the subclavian vein.

In the present case, as is rarely in literature, distal part of electrode was broken in subclavian vein. Then, it was successfully extracted with the femoral approach, although with twice embolization. The given messages to the clinicians of the present case report are as follows. During the extraction of pacemaker, any part of the system could break at any part of the vascular system. Each embolization may prolong the process duration and be related with the increased risk of morbidity and mortality.

4. Conclusion

In conclusion, transvenous extraction of pacemaker systems is a process that must be administered carefully and clinicians should be aware of the complications that may develop.

Conflicts of interest

The authors have none to declare.

Appendix A. Supplementary data

Supplementary data associated with this article can be found, in the online version, at [doi:10.1016/j.ihj.2015.06.004](https://doi.org/10.1016/j.ihj.2015.06.004).

REFERENCES

1. Moss AJ, Hall WJ, Cannom DS, et al. for the MADIT-CRT Investigators. Cardiac resynchronization therapy for the prevention of heart-failure events. *N Engl J Med*. 2009;361:1329–1338.
2. St. John Sutton M, Ghio S, Plappert T, et al. REsynchronization reVERses Remodeling in Systolic left vEntricular dysfunction (REVERSE) Study Group. Cardiac resynchronization induces major structural and functional reverse remodeling in patients with New York Heart Association class I/II heart failure. *Circulation*. 2009;120:1858–1865.
3. Tang AS, Wells GA, Talajic M, et al. Resynchronization-Defibrillation for Ambulatory Heart Failure Trial Investigators. Cardiac-resynchronization therapy for mild-to-moderate heart failure. *N Engl J Med*. 2010;363:2385–2395.
4. Duval X, Selton-Suty C, Alla F, et al. Endocarditis in patients with a permanent pacemaker: a 1-year epidemiological survey on infective endocarditis due to valvular and/or pacemaker infection. *Clin Infect Dis*. 2004;39:68–74.
5. Koneru JN, Ellenbogen KA. Detection of transvenous pacemaker and ICD lead vegetations: the ICE cold facts. *J Am Coll Cardiol*. 2013;2:1406–1408;ĆBongiorni MG, Soldati E, De Lucia R, et al. Techniques for transvenous leads extraction. *Minerva Cardioangiol*. 2007;55:771–781.
6. Korkeila PJ, Saraste MK, Nyman KM, et al. Transesophageal echocardiography in the diagnosis of thrombosis associated with permanent transvenous pacemaker electrodes. *Pacing Clin Electrophysiol*. 2006;29:1245–1250.
7. Kratz JM, Toole JM. Pacemaker and internal cardioverter defibrillator lead extraction: a safe and effective surgical approach. *Ann Thorac Surg*. 2010;90:1411–1417.
8. Farooqi FM, Talsania S, Hamid S, et al. Extraction of cardiac rhythm devices: indications, techniques and outcomes for the removal of pacemaker and defibrillator leads. *Int J Clin Pract*. 2010;64:1140–1147.
9. Lelakowski J, Kutarski A, Małeczka B, et al. Complex percutaneous extraction of a 15-year-old atrial lead dislodged into the subclavian vein. *Arch Med Sci*. 2011;7:164–167.
10. Bordachar P, Defaye P, Peyrouse E, et al. Extraction of old pacemaker or cardioverter-defibrillator leads by laser sheath versus femoral approach. *Circ Arrhythm Electrophysiol*. 2010;3:319–323.
11. Starck CT, Caliskan E, Klein H, et al. Impact of a femoral snare approach as a bailout procedure on success rates in lead extractions. *Interact Cardiovasc Thorac Surg*. 2014;18:551–555.