

This article is licensed under the Creative Commons Attribution-NonCommercial 4.0 International License (CC BY-NC) (<http://www.karger.com/Services/OpenAccessLicense>). Usage and distribution for commercial purposes requires written permission.

Case Report

Complete Recovery from Blindness in Case of Compressive Optic Neuropathy due to Unruptured Anterior Cerebral Artery Aneurysm

Yurie Fukiyama^a Hidehiro Oku^a Yusuke Hashimoto^a Yuko Nishikawa^a
Masahiro Tonari^a Jun Sugawara^a Shigeru Miyachi^b Tsunehiko Ikeda^a

^aDepartment of Ophthalmology, Osaka Medical College, Osaka, Japan; ^bDepartment of Neurosurgery, Osaka Medical College, Osaka, Japan

Keywords

Compressive optic neuropathy · Hemianopic visual field defects · Anterior cerebral artery aneurysm

Abstract

It is not common for an isolated visual symptom to be the first indication of an aneurysm compressing the optic nerve. The compression can lead to blindness, and a recovery from the blindness is rare. We report a female with a left painless optic neuropathy caused by an unruptured anterior cerebral artery aneurysm. The patient had a temporal hemianopic visual field defect, which progressed to blindness in the left eye, while the right visual function was not affected. A coil embolization of the aneurysm completely restored her visual acuity to 20/20. These findings suggest that aneurysmal lesions should be ruled out in case of unilateral optic neuropathy with hemianopic visual field defects and progressive visual loss.

© 2017 The Author(s)
Published by S. Karger AG, Basel

Introduction

Because the optic nerve is located near the anterior cerebral artery, anterior communicating artery, ophthalmic artery, internal carotid artery, and the supraclinoid portion of the internal carotid artery, aneurysms of these arteries may cause compressive optic neuropathy [1]. Thus, an aneurysmal lesion should be considered as a possible cause of optic neuropathy associated with a progressive visual deterioration [2]. However, it is extremely rare that a patient visits a hospital due to visual symptoms caused by an aneurysmal compression of the optic nerve. A recovery of the blindness caused by the compression has been rarely reported [3, 4].

Aneurysms originating from the proximal segment (A1) of the anterior cerebral artery are rare and comprise <1% of all intracranial aneurysms [5]. Aneurysms in the A1 segment are usually small but tend to rupture at a smaller size than those from other arteries [5]. We report a case of unilateral compressive optic neuropathy caused by an unruptured A1 aneurysm. This case is unusual because the A1 aneurysm was found by the visual symptoms, but not headaches, before its rupture. In addition, the visual function was fully recovered from blindness by coil embolization.

Case Presentation

A 54-year-old female complained of visual disturbances in the left eye, which was first noted 2 weeks prior to her visit to our hospital. The visual symptom began with photophobia due to bright objects in the central visual field. She reported that she had not had any traumatic injury, vaccination, or infection before the onset. She was not diabetic or hypertensive, but she had undergone mitral valve surgery 5 years earlier.

At the initial examination, her visual acuity was 20/20 OD and 20/500 OS. She did not complain of headaches, retrobulbar pain, or orbital pain. Visual field testing revealed a temporal hemianopic visual field defect in the left eye, while the visual field in the right eye was normal (Fig. 1a). Fundus examination showed no remarkable changes of the optic disc of both eyes. A relative afferent pupillary defect was present in the left eye. The intraocular pressure was 16 mm Hg OU. These findings suggested that the left retrobulbar optic nerve was impaired, and she was immediately hospitalized.

Steroid pulse therapy was started, but the left visual acuity in the left eye decreased to blindness on the next day. MRI and time-of-flight MR angiography were performed 2 days after the initial visit.

MRI with gadolinium enhancement revealed a round, space-occupying lesion with a diameter of 11.5 mm that was located at the suprasellar cistern which compressed the left optic nerve near the chiasma (Fig. 2). The inside of the space-occupying lesion showed a partial high-intensity signal with iso- to low-intensity signals by T1-weighted images and iso- to low-intensity signals by T2-weighted images. Gadolinium enhancement was positive in the region with the iso- to high-intensity signals on the T1 weighted images. This heterogeneous intensity pattern with partial gadolinium enhancement suggested a development of a thrombus in the aneurysm. The MR angiography and digital subtraction angiography suggested that the aneurysm protruded from the A1 segment of the anterior cerebral artery near the anterior communicating artery (Fig. 3). She was transferred to the Department of Neurosurgery, and coil embolization was successfully performed without significant complications.

Three days after the surgery, her visual acuity had improved from blindness to 20/667 OS, and the visual field was slightly enlarged from the initial examination (Fig. 1b, left). One month after the surgery, her visual acuity was further improved to 20/20 OS, and the relative afferent pupillary defect was absent on the left side. The left visual field was improved, and neither the scotoma nor the enlargement of the blind spot remained (Fig. 1b, right).

Discussion

The findings in our case suggest that a painless unilateral optic neuropathy with temporal hemianopic visual field defects can be caused by a compression of the optic nerve by an unruptured aneurysm of the proximal anterior cerebral artery at its juncture with the anterior communicating artery. In addition, a surgical decompression of the aneurysm can lead to a complete recovery from the blindness.

Aneurysms of the anterior communicating artery or the anterior cerebral artery at its junction with the anterior communicating artery usually rupture before becoming large enough to compress the visual pathways [2]. Thus, in cases with an aneurysm of these arteries, visual impairments are usually caused by subarachnoid hemorrhages [6]. Our case was unusual because it presented with an acute isolated optic neuropathy [7].

The patient did not complain of retrobulbar pain, which is reported in the majority of cases of optic neuritis [8]. In addition, hemianopic visual field defects are also uncommon in cases of optic neuritis [8]. However, a differential diagnosis of optic neuritis associated with neuromyelitis optica spectrum disorders is difficult because painless and hemianopic visual field defect can be present in neuromyelitis optica spectrum disorders [9]. Thus, we began intravenous corticosteroid soon after hospitalization.

The pattern of visual field defects caused by aneurysmal compressive optic neuropathy is varied, but a hemianopic visual field defect is often detected [2]. Headaches and orbital pain are also common, and dementia or personality changes are reported in some cases [2]. These symptoms were not present in our case, but the patient complained of photophobia as an initial symptom of the visual alterations. This positive visual phenomenon has been reported in cases with aneurysmal compressive optic neuropathy [10]. However, photophobia is also present in cases of optic neuritis [8]. Thus, the hemianopic visual field defect and progressive visual deterioration were the signs and symptoms that characterized our case.

It is well established that some patients with compressive optic neuropathy caused by tumors can have their visual function restored after removal of the tumor [1, 11]. Similarly, decompression surgery for an aneurysm compressing the optic nerve can achieve full visual recovery even from blindness [3, 4]. These observations suggest that a compression of the optic nerve can cause visual impairments through the blockage of conduction and demyelination, and the retinal ganglion cells can survive for some time. The time required for visual recovery is reported to vary from days [3, 4] to months [12]. In this regard, it has been suggested that relief of the compression may contribute to the rapid recovery, but remyelination may take a longer recovery time [13]. A longer duration of the visual impairment probably affects the prognosis [11]. However, successful decompression does not always lead to good recovery of visual function from the acute visual loss [14, 15]. Thus, vascular insufficiency of the optic nerve has been suggested to be the reason for the different visual outcomes. In our case, a complete recovery was achieved after the 2-weeks of visual deterioration to blindness. However, this is a single case report, and our findings cannot be generalized in compressive optic neuropathy due to aneurysms.

In conclusion, neuroimaging needs to be performed in cases of optic neuropathy with unusual visual field defects, e.g., hemianopic visual field defects, or with a progressive visual deterioration to rule out aneurysmal lesions even in cases with painless optic neuropathy.

Acknowledgement

The authors thank Professor Emeritus Duco Hamasaki, Bascom Palmer Eye Institute, University of Miami School of Medicine, for discussions and editing the manuscript.

Statement of Ethics

The authors have no ethical conflicts to disclose.

Disclosure Statement

There are no conflicts of interest or commercial interest to disclose for all authors.

References

- 1 Volpe NJ: Compressive and infiltrative optic neuropathies; in Miller NR, Walsh FB, Hoyt WF (eds): Walsh and Hoyt's Clinical Neuro-Ophthalmology (ed 6). Philadelphia, Lippincott Williams & Wilkins, 2005, pp 385–429.
- 2 Peiris JB, Ross Russell RW: Giant aneurysms of the carotid system presenting as visual field defect. *J Neurol Neurosurg Psychiatry* 1980;43:1053–1064.
- 3 Striph GG, Slamovits TL, Burde RM: Visual recovery following prolonged amaurosis due to compressive optic neuropathy. *J Clin Neuroophthalmol* 1984;4:189–195.
- 4 Tajima A, Ito M, Ishii M: Complete recovery from monocular blindness caused by aneurysmal compression to optic nerve – report of two cases. *Neurol Med Chir (Tokyo)* 1993;33:19–23.
- 5 Dashti R, Hernesniemi J, Lehto H, et al: Microneurosurgical management of proximal anterior cerebral artery aneurysms. *Surg Neurol* 2007;68:366–377.
- 6 Chan JW, Hoyt WF, Ellis WG, Gress D: Pathogenesis of acute monocular blindness from leaking anterior communicating artery aneurysms: report of six cases. *Neurology* 1997;48:680–683.
- 7 Claes C, Milea D, Bodaghi B, Tran TH, LeHoang P, Blanc R: Acute retrobulbar optic neuropathy due to rupture of an anterior communicating artery aneurysm. *Acta Ophthalmol Scand* 2006;84:145–146.
- 8 Pau D, Al Zubidi N, Yalamanchili S, Plant GT, Lee AG: Optic neuritis. *Eye (Lond)* 2011;25:833–842.
- 9 Nakajima H, Hosokawa T, Sugino M, et al: Visual field defects of optic neuritis in neuromyelitis optica compared with multiple sclerosis. *BMC Neurol* 2010;10:45.
- 10 Hagihara N, Abe T, Yoshioka F, Watanabe M, Tabuchi K: Photophobia as the visual manifestation of chiasmal compression by unruptured anterior communicating artery aneurysm. Case report. *Neurol Med Chir (Tokyo)* 2009;49:159–161.
- 11 Rosenberg LF, Miller NR: Visual results after microsurgical removal of meningiomas involving the anterior visual system. *Arch Ophthalmol* 1984;102:1019–1023.
- 12 Durston JH, Parsons-Smith BG: Blindness due to aneurysm of anterior communicating artery. With recovery following carotid ligation. *Br J Ophthalmol* 1970;54:170–176.
- 13 McDonald WI: The symptomatology of tumours of the anterior visual pathways. *Can J Neurol Sci* 1982;9:381–390.
- 14 Craenen G, Brown SM, Freedman KA, Windisch TR, Corona J: Rapid, painless unilateral vision loss in a 37-year-old healthy woman. *Surv Ophthalmol* 2004;49:343–348.
- 15 Chang JH, Lee DK, Kim BT, Ohn YH: Computed tomographic angiogram of an anterior communicating artery aneurysm causing acute retrobulbar optic neuropathy: a case report. *Korean J Ophthalmol* 2011;25:366–368.

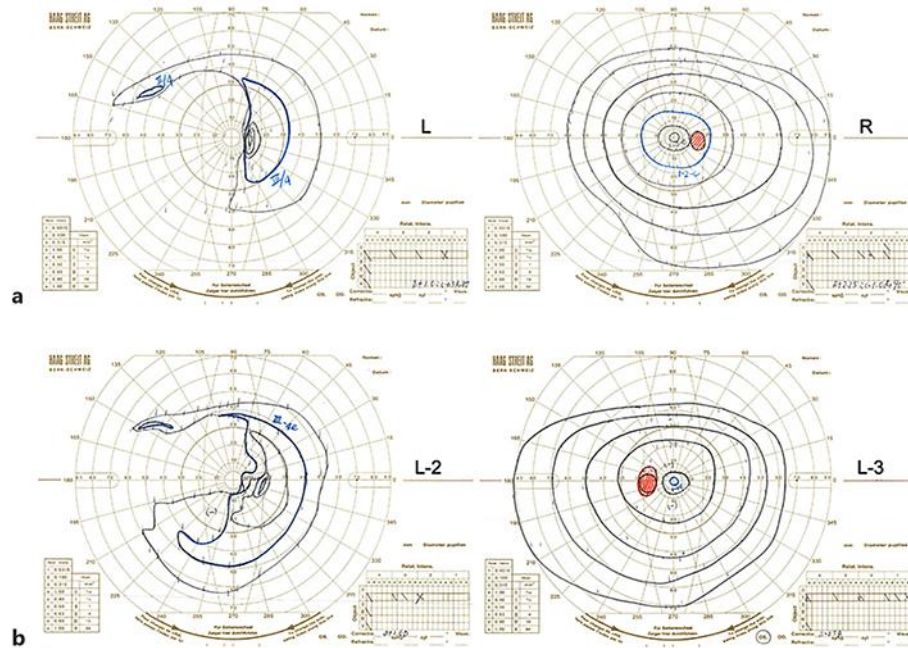


Fig. 1. Visual field changes of a patient with severe reduction of vision in the left eye. **a** Findings at the initial examination. A temporal hemianopia respecting the vertical midline is present in the left eye, while the visual field of the right eye is not affected. **b** Three days after the endovascular surgery. The left visual field is larger than that at the initial examination with blindness (left). One month after the surgery, the left visual field recovers to the normal size (right).

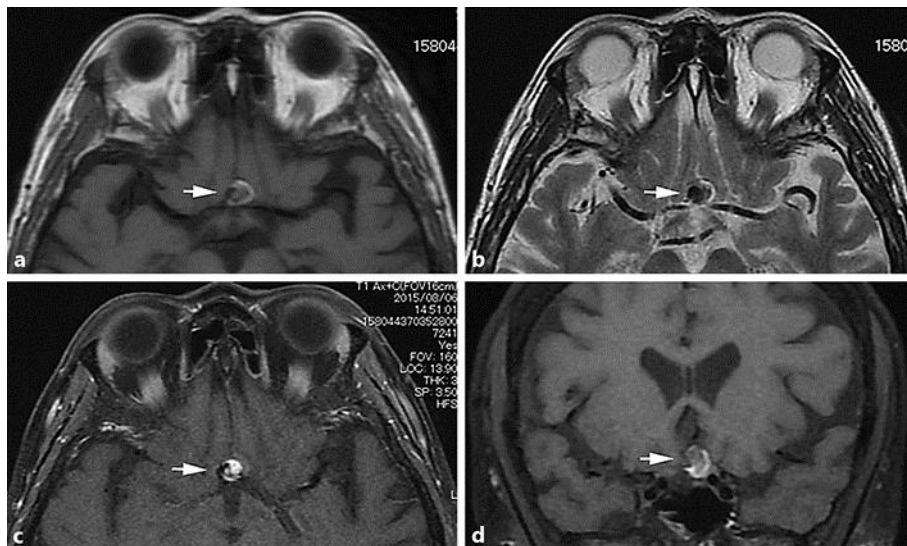


Fig. 2. Axial T1-weighted (a) and axial T2-weighted (b) magnetic resonance images, axial T1-weighted magnetic resonance images with gadolinium enhancement (c), and coronal T1-weighted magnetic resonance images with gadolinium enhancement (d). Inside the aneurysm (indicated by an arrow in each image), a heterogeneous pattern of intensities exists with partial gadolinium enhancement.

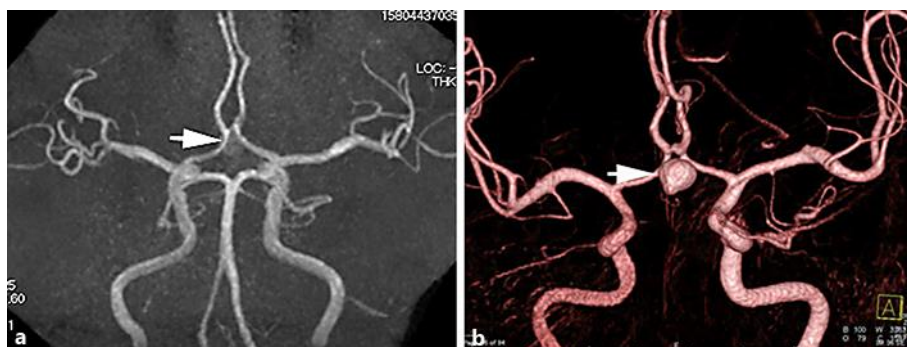

Fig. 3. Magnetic resonance angiography (a) and digital subtraction angiography (b). The aneurysm is indicated by an arrow in each image.