





Perspective

Choroidal arteriovenous anastomoses: a hypothesis for the pathogenesis of central serous chorioretinopathy and other pachychoroid disease spectrum abnormalities

Joost Brinks,¹  Elon H. C. van Dijk,¹  Onno C. Meijer,²  Reinier O. Schlingemann^{3,4} and Camiel J. F. Boon^{1,3} 

¹Department of Ophthalmology, Leiden University Medical Centre, Leiden, The Netherlands

²Department of Medicine, Division of Endocrinology and Metabolism, Leiden University Medical Centre, Leiden, The Netherlands

³Department of Ophthalmology, Amsterdam University Medical Centres, University of Amsterdam, Amsterdam, The Netherlands

⁴Department of Ophthalmology, University of Lausanne, Jules-Gonin Eye Hospital, Fondation Asile des Aveugles, Lausanne, Switzerland

ABSTRACT. The pachychoroid disease spectrum (PDS) includes several chorioretinal diseases that share specific choroidal abnormalities. Although their pathophysiological basis is poorly understood, diseases that are part of the PDS have been hypothesized to be the result of venous congestion. Within the PDS, central serous chorioretinopathy is the most common condition associated with vision loss, due to an accumulation of subretinal fluid in the macula. Central serous chorioretinopathy is characterized by distinct risk factors, most notably a high prevalence in males and exposure to corticosteroids. Interestingly, sex differences and corticosteroids are also strongly associated with specific types of arteriovenous anastomoses in the human body, including dural arteriovenous fistula and surgically created arteriovenous shunts. In this manuscript, we assess the potential of such arteriovenous anastomoses in the choroid as a causal mechanism of the PDS. We propose how this may provide a novel unifying concept on the pathophysiological basis of the PDS, and present cases in which this mechanism may play a role.

Key words: arteriovenous anastomoses – arteriovenous fistula – corticosteroids – pachychoroid disease spectrum – sex differences – venous congestion

#These authors contributed equally.

This research was supported by the following foundations: Stichting Macula Fonds; Retina Nederland Onderzoek Fonds; Stichting Blinden-Penning; Algemene Nederlandse Vereniging ter Voorkoming van Blindheid; Landelijke Stichting voor Blinden en Slechtzienden, which contributed through UitZicht (Delft, The Netherlands); Rotterdamse Stichting Blindenbelangen (Rotterdam, The Netherlands); Stichting Leids Oogheelkundig Ondersteuningsfonds (Leiden, The Netherlands); Stichting Blindenhulp (The Hague, The Netherlands); Stichting Ooglijders (Rotterdam, The Netherlands); ZonMw 'MKMD' grant; International Foundation for Ethical Research (IFER) Graduate Fellowship Program and Stichting Oogfonds Nederland. These funding organizations provided unrestricted funding and had no role in the design or conduct of the study; the collection, management, analysis or interpretation of the data; the preparation, review or approval of the manuscript; or the decision to submit the manuscript for publication.

No conflicting relationship exists for any author.

Acta Ophthalmol. 2022; 100: 946–959

© 2022 The Authors. Acta Ophthalmologica published by John Wiley & Sons Ltd on behalf of Acta Ophthalmologica Scandinavica Foundation.

This is an open access article under the terms of the Creative Commons Attribution-NonCommercial-NoDerivs License, which permits use and distribution in any medium, provided the original work is properly cited, the use is non-commercial and no modifications or adaptations are made.

doi: 10.1111/aos.15112

Introduction

The pachychoroid disease spectrum (PDS) is an 'umbrella term' used for chorioretinal conditions that have specific choroidal abnormalities in common (Dansingani et al. 2016; Cheung et al. 2019; Spaide 2021; Spaide et al. 2021). Key features of the PDS are a thickened choroid (pachychoroid) in combination with dilated choroidal veins in Haller's layer (pachyvessels), which can be observed on both optical coherence tomography (OCT) and indocyanine green angiography (ICGA) (Fig. 1A–C) (Prünte 1995; Spaide et al. 2008; Dansingani et al. 2016; Cheung et al. 2019; van Rijssen et al. 2019; Spaide et al. 2021). Indocyanine green angiography is essential to establish the diagnosis of these diseases, typically showing dilated choroidal vessels and irregular hyperfluorescent areas with indistinct borders during mid-phase angiography, indicating vascular hyperpermeability, another key aspect of the PDS (Fig. 1D) (Prünte 1995; van Rijssen et al. 2019). These signs are strongly suggestive for venous overload, and this is believed to lie at the basis of the chorioretinal abnormalities that are characteristic for the PDS, such as subretinal fluid accumulation (SRF) in the case of central serous chorioretinopathy (CSC) (Dansingani et al. 2016;

Spaide et al. 2021). The aetiology of this venous congestion is poorly understood, and this may impede the development of effective therapeutic strategies. The current manuscript postulates and discusses a novel concept on the potential origin of the venous overload that characterizes the PDS: choroidal arteriovenous anastomoses (AVAs). First, we outline the unique functional and anatomical features of the choroidal vascular labyrinth, as well as the current state of literature on AVAs in the human choroid. Next, various types of AVAs across the human body are discussed, as well as their classification by their physiological (i.e. anastomoses), pathological (i.e. fistula) or surgical (i.e. shunt) origin. In the sections thereafter, we discuss striking analogies between specific types of AVAs in the human body and features of the PDS. Furthermore, we speculate on how potential choroidal AVAs may represent a unifying causal factor for the venous overload that is a key feature of the PDS. In addition, we discuss whether these choroidal AVAs may represent a dysregulated physiological phenomenon arising from pre-existent AVAs, or a primarily pathological phenomenon which is referred to as arteriovenous fistulas (AVFs).

Functional and Anatomical Features of the Choroidal Vascular Labyrinth

The human choroid is a highly specialized vascular tissue localized between

the retinal pigment epithelium (RPE)/Bruch's membrane complex and the sclera. An important function of the choroid is to provide nourishment to the outer neuroretina, where the highly metabolically active photoreceptors are located (Nickla & Wallman 2010; Brinks et al. 2021b). The choroid also plays a role in ocular development, thermoregulation and immunology (Parver 1991; Mochizuki et al. 2013; Luty & McLeod 2018; Brinks et al. 2021b). The vasculature of the choroid is organized as a layered dense sheet of arteries and veins (Fig. 2). The most outer part of the choroid contains the largest choroidal blood vessels and is referred to as Haller's layer. The medium-sized choroidal blood vessels are located in the intermediate Sattler's layer, while the choriocapillaris is the innermost layer of the choroid, comprising a dense meshwork of capillaries optimally orientated to facilitate a high rate of nutrient transport and processing of metabolic waste. In contrast to the larger blood vessels in Sattler's and Haller's layer, the choriocapillaris contains fenestrations, which are small 'pores' in the cellular membranes of the choroidal endothelial cells that facilitate rapid transcellular transport (Schlingemann et al. 1985; Bosma et al. 2018; Brinks et al. 2021b). The basal lamina of the endothelial cells in the choriocapillaris is part of Bruch's membrane, which is also the site where most exchange of gasses, nutrients and clearance of metabolic waste occurs (Nickla & Wallman 2010; Brinks et al. 2021b).

The posterior choroid is supplied by the short posterior ciliary arteries (SPCAs), which enter the eye around the macular region (Fig. 2) (Hayreh 2004). Typically, there are 6–12 SPCAs, and anatomical variations are common. Each SPCA supplies a wedge-shaped segment of the posterior pole, with distinct watershed zones between these areas (Hayreh 1975). As such, the choroidal arterial blood supply is considered to be highly segmental. This has been confirmed by numerous studies using dye-based imaging and by clinical studies in which inflammatory, ischaemic and malignant pathological processes have been shown to adhere to the watershed zones of the arterial choroidal blood supply (Hayreh 1975; Hayreh 1990; Hayreh 2004). Venous choroidal blood exits the eye near the equator through the vortex veins, which usually occur at 4–6 exiting points at the sclera through a structure termed the ampulla (Fig. 3). Vortex vein areas are segmented and have watershed zones between these areas, following a distribution pattern that is different from the watershed zones of the arterial circulation (Paula et al. 2013; Jung et al. 2020; Spaide 2020). In contrast to the gradually increasing lumen size of the choroidal arterial system, the large choroidal veins traverse the posterior pole for a long parallel distance until they reach the ampulla. This has been proposed to serve as a 'buffer' for venous blood as part of a Starling's resistor mechanism, in which choroidal veins in Haller's layer and the ampulla

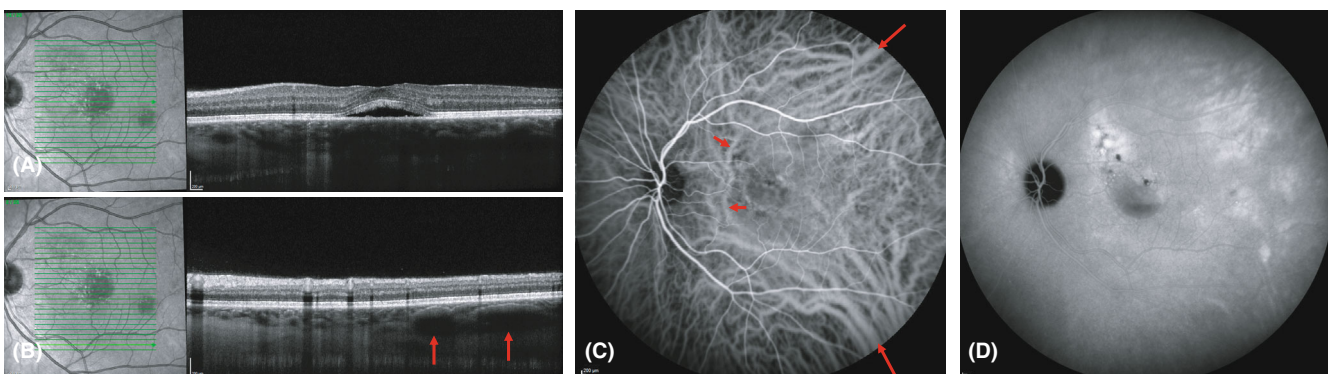


Fig. 1. Thirty-three-year-old man with central serous chorioretinopathy showing typical aspects of the pachychoroid disease spectrum. Foveal optical coherence tomography (A) revealed subretinal fluid accumulation. Pachyvessels with apparent attenuation of the overlying choriocapillaris were also observed on optical coherence tomography (B; red arrowheads). Indocyanine green angiography shows a prominent appearance of pachyvessels that appear to adhere to vortex vein quadrants (C; red arrowheads), as well as intervortex vein anastomoses nasal to the macula (C; red arrowheads). Mid-phase indocyanine green angiography (D) showed hypofluorescent and hyperfluorescent areas with indistinct borders that are typical for diseases that are part of the pachychoroid disease spectrum.

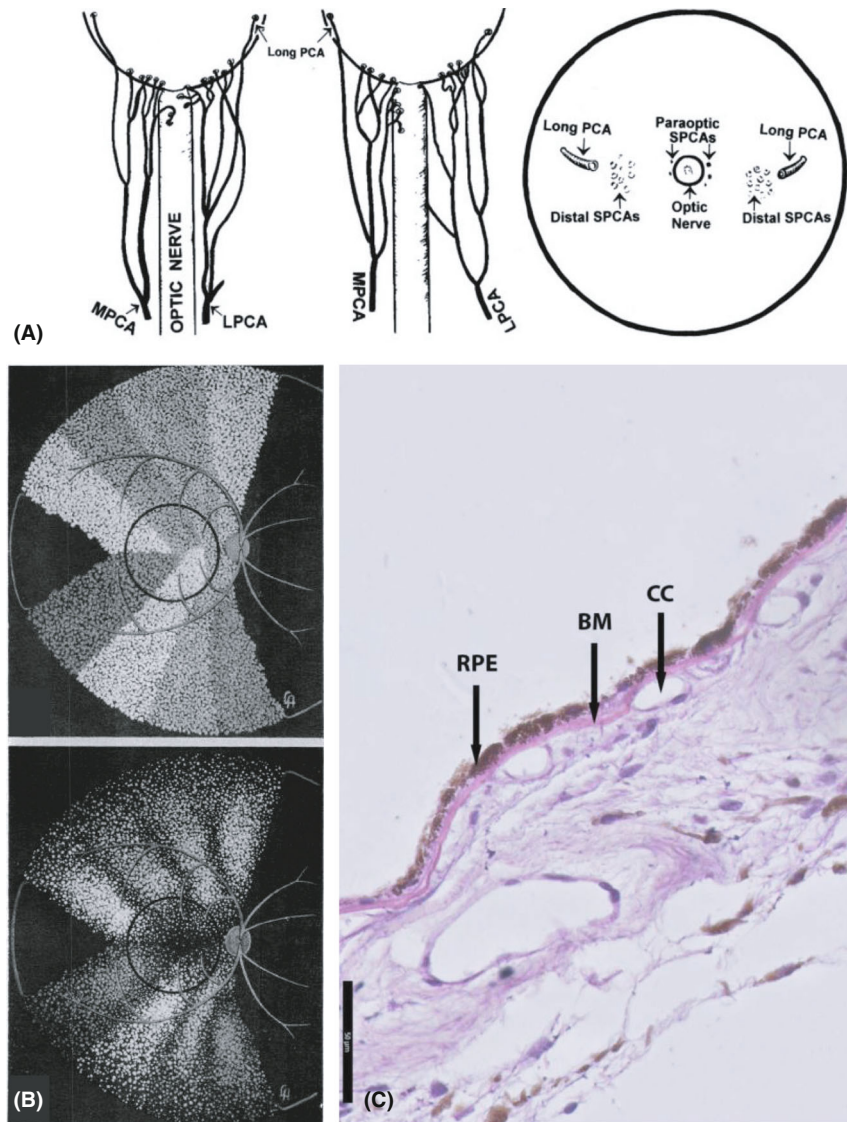


Fig. 2. Overview of the anatomy of the choroid. (A) Reproduced with permission from Hayreh (2004). Schematic representation of the branching pattern of medial and lateral posterior ciliary arteries in 2 eyes (illustrations at the left and the middle) and of the site of entry of the various branches of the posterior ciliary arteries, as seen at the back of the eye (illustration at the right). (B) Reproduced with permission from Hayreh (1975). Schematic representation of distribution of choriocapillaris supplied by various temporal short posterior ciliary arteries. (Left) Normal pattern. (Right) Postulated pattern caused by generalized chronic ischaemic disorder of the choroid, with reduction in choriocapillaris most marked in macular region and equatorial choroid. (C) A haematoxylin and eosin staining of a cross section of the human choroid showing the retinal pigment epithelium (RPE), Bruch's membrane (BM) and the choriocapillaris (CC). In the deeper layers, the lumen of a large vessel and the presence of other cell types resident in the choroid, such as melanocytes, can be observed. Scale bar = 50 µm.

passively participate in maintaining a stable choroidal perfusion, which has to act under intraocular pressure within the rigid sclera that encloses the globe (Spaide 2020).

The posterior human choroid is considered to be an end-arterial system with a segmental anatomy (Hayreh 1975; Zouache et al. 2016; Lee et al. 2017; Spaide 2020). Hayreh visualized this segmentation of the choroidal arterial system using dye-based imaging, showing wedge-shaped filling patterns delineated by their respective watershed zones (i.e. the border between two areas

of vascular supply), arising from individual SPCAs (Fig. 2B) (Hayreh 1975). This explains why ischaemic choroidal diseases may adhere to apparent anatomical borders (Hayreh 1990; Hayreh 2004). Nonetheless, within sectors of SPCAs, anastomotic connections between smaller arterioles within the same sector have been described (Lee et al. 2017). Around the 1950s, it was postulated that the human choroid also may contain AVAs, supposedly regulating blood flow by 'shunting': blood flow from arteries to veins bypassing the capillary bed (Loewenstein 1949;

Wybar 1954; Hayreh 2004). Part of these studies involved post-mortem casts of human choroidal tissue (Wybar 1954), in which apparent anastomotic connections were considered by some authors to be artefacts because the tissue was filled under high pressure, which may have led to opening of lumina that are either non-existent or not patent *in vivo* (Hayreh 2004). Still, Loewenstein also described so-called 'glomus cells' in the human choroid, the specific cell types surrounding an AVA, described in a variety of vasculatures within the human body, which are




Fig. 3. Reproduced with permission from Jung et al. (2020). Representative mid-phase ultra-widefield indocyanine green angiography images (Optos California; Optos, Inc., Dunfermline, UK) after removal of imaging artefacts from a left eye diagnosed with chronic central serous chorioretinopathy. Vortex vein ampullas are indicated with orange arrowheads.

presumed to be involved in regulating opening and closure of AVAs (Loewenstein 1949). However, convincing histological evidence showing the full length of a choroidal AVA was not provided in these studies due to technical limitations (Loewenstein 1949). Taken together, while it is well-known that the human choroid follows a predominantly segmental vascular anatomy, the potential presence of physiological AVAs within these anatomical borders is highly controversial and still a relatively understudied topic (Loewenstein 1949; Bhutto & Amemiya 2001; Hayreh 2004; Lee et al. 2017; Spaide 2020). In addition, pathological variants of AVAs that are acquired during life, which are termed AVFs, are virtually unexplored within the human choroid. Although speculative, AVFs may for instance form at sites of arteriovenous crossings in the human choroid, where arteries and veins are found in an intimate spatial relationship (Yoneya & Tso 1987; Cheung et al. 2021). In this manuscript, the possible presence of physiological AVAs and/or pathological AVFs in the choroid is discussed in the context of the mysterious origins of the PDS.

The Pachychoroid Disease Spectrum: Venous Overload of Mysterious Origin

Conditions that are part of the PDS include uncomplicated pachychoroid (Siedlecki et al. 2019), pachychoroid pigment epitheliopathy (Warro

et al. 2013), CSC (van Rijssen et al. 2019), pachychoroid aneurysmal type 1 choroidal neovascularization (also known as polypoidal choroidal vasculopathy) (Siedlecki et al. 2019), pachychoroid neovascularopathy (Dansingani et al. 2016) and peripapillary pachychoroid syndrome (PPS) (Phasukkijwatana et al. 2018). All of these conditions are characterized by signs of venous overload: pachychoroid, pachyvessels and vascular hyperpermeability (Dansingani et al. 2016; Cheung et al. 2019; Spaide et al. 2021). CSC is the most well-known member of the PDS. Patients with this disease often experience sudden-onset vision loss due to an accumulation of SRF in the macula. The localization of the SRF often correlates with hyperfluorescent changes on ICGA, which are presumed to reflect vascular hyperpermeability of the choriocapillaris (Prünte 1995; Teussink et al. 2015; van Dijk & Boon 2021; van Rijssen et al. 2021a). Therefore, the occurrence of SRF in CSC is presumed to be the result of choriocapillaris hyperpermeability due to increased intraluminal pressure caused by venous overload. This causes damage to the outer blood–retina barrier of the RPE, with subsequent fluid leakage from the choroid, through the RPE defect, to the subretinal space (Prünte 1995; van Rijssen et al. 2019; Kaye et al. 2020; Spaide et al. 2021). The areas of focal leakage through the RPE can be visualized well with fluorescein angiography (FA). Other observations from ICGA studies on CSC patients include an arterial filling delay and areas of hypofluorescence with indistinct borders, indicating dysfunction of choroidal blood flow (Prünte 1995; Prünte & Flammer 1996; Komatsu et al. 2010; Kishi et al. 2018; van Rijssen et al. 2019). On OCT angiography, irregular choriocapillaris flow patterns have been described in CSC, with areas suggestive of both ischaemia (flow voids) and hyperperfusion (Teussink et al. 2015).

Despite this knowledge on the clinical signs of CSC and the other diseases that are part of the PDS, the pathogenic mechanisms underlying pachychoroid, pachyvessels and vascular hyperpermeability remain poorly understood. The term pachychoroid comes from the observation of a thicker-than-average choroid on OCT, although a clear cut-off value in clinical practice is a topic of debate

(Dansingani et al. 2016; Spaide 2021; Brinks et al. 2021b). Perhaps more accurately, a ‘potentially pathological pachychoroid’ typically entails pachyvessels, which are dilated veins in Haller’s layer, increasing the total choroidal thickness (Dansingani et al. 2016; Cheung et al. 2019). On OCT, these pachyvessels have been described to compress the overlying choriocapillaris, with possible obstruction of blood flow in the capillary lumens (Baek et al. 2019b), and one or more areas of hyperfluorescence on ICGA consistent with leakage from choriocapillaris dysfunction (van Rijssen et al. 2021a). Pachyvessels can also be observed in the frontal plane on *en face* OCT images and ICGA as prominently dilated veins that adhere to a quadrant drained by a vortex vein (Fig. 1C) (Dansingani et al. 2016; Cheung et al. 2019). With the introduction of ultra-widefield ICGA, anastomotic connections between the pachyvessels in vortex vein quadrants have been described in several pachychoroid spectrum diseases, termed intervortex vein anastomoses (Matsumoto et al. 2019; Jung et al. 2020; Spaide et al. 2020; Matsumoto et al. 2020b; Spaide et al. 2021). Intervortex vein anastomoses have been proposed to alleviate venous congestion in existing pachyvessels (Jung et al. 2020; Spaide et al. 2020; Matsumoto et al. 2020b; Spaide et al. 2021) and may therefore be a consequence of choroidal venous congestion rather than the primary cause. Pulsations in choroidal veins have also been described in pachychoroid spectrum diseases, but it is unknown whether this may be the result of either venous outflow obstruction, pressure gradients between anastomosed vortex veins or direct arteriovenous connections (Bischoff et al. 1996; Cheung et al. 2021; Matsumoto et al. 2021; Spaide et al. 2021). Regarding the potential origin of pachyvessels, an increased scleral thickness, either leading to narrowing of the passage of the ampulla through the sclera or a decreased permeability of the sclera to fluids, has been proposed to play a role (Fernández-Vigo et al. 2021; Lee et al. 2021; Spaide et al. 2021; Imanaga et al. 2021a, 2021b). However, the current imaging techniques are limited in their ability to obtain a detailed image of the sclera and the anatomy of the venous outflow of the posterior eye. Direct evidence that scleral abnormalities fully explain the origin of venous

overload in the pachychoroid spectrum is therefore currently lacking. To explore an alternative hypothesis, this manuscript focusses on choroidal AVAs or AVFs as a potentially causative mechanism underlying the venous overload observed in the PDS and aimed to integrate this perspective into existing studies and hypotheses on the pathophysiological mechanisms involved in PDS (Fig. 4).

Physiological and Pathological Vascular Shortcuts: Arteriovenous Anastomoses in the Human Body

An AVA is the medical definition of a direct connection between an artery and a vein that bypasses the capillary bed (Sappey 1874; Lovering et al. 2015). It can be of either physiological origin or pathological origin (fistula), or surgically created to facilitate haemodialysis (shunt). Physiological AVAs in humans have been described in the penile erectile tissue, lungs, episcleral vasculature, spinal cord and cutaneous tissue of the external ear, digits, toes and

nose (Loewenstein 1949; Daniel & Prichard 1956; Bergersen 1993; Bergersen et al. 1997; Midttun 2000; Laurie et al. 2012; Lovering et al. 2015; Lee et al. 2019). In the lung, AVAs play an important role in the regulation of blood flow. Intrapulmonary AVAs open during exercise or upon hypoxia, increasing pulmonary blood flow to comply with systemic oxygen demand (Lovering et al. 2015). In digits, AVAs play a role in thermoregulation (Bergersen et al. 1997). In response to cold, closure of AVAs occurs, dramatically decreasing the perfusion rate of the extremities to maintain a stable core body temperature (Vanggaard et al. 2012). Dysfunction of these AVAs is observed during the ischaemic phase of Raynaud’s phenomenon, which is a condition characterized by a strongly decreased blood flow to the fingers due to blood vessel spasms (Nuzzaci et al. 1988). In the eye, the episcleral vasculature is known for its extensive network of AVAs, which are thought to play a role in regulating the rate of aqueous humour production and even intraocular pressure (Selbach et al. 2005; Lee et al. 2019). Remarkably, AVAs have been described to be

richly innervated and to contain vascular smooth muscle cells, which is referred to as the functional unit of a ‘glomus body’ that is under control of the autonomous nervous system, which may actively regulate AVA opening and closure (Daniel & Prichard 1956; Funk et al. 1994; Parke 2004; Selbach et al. 2005; Donadio et al. 2006; Walløe 2016). Based on the observation of histological characteristics of such structures, AVAs have also been described in the human choroid (Loewenstein 1949), but their potential physiological relevance, and even their existence, is controversial (Loewenstein 1949; Wybar 1954; Shimizu & Ujiie 1978; Castro-Correia 1995; Hayreh 2004). Nonetheless, it is interesting to note that AVAs elsewhere in the body do have relevant physiological functions, including the regulation of oxygen demand and temperature, which both are functions also attributed to the choroid in the regulation of ocular homeostasis (Parver 1991; Brinks et al. 2021b). Based on these analogies in physiological relevance of AVAs elsewhere in the human body, it may be speculated that choroidal AVAs also exist and can be of physiological

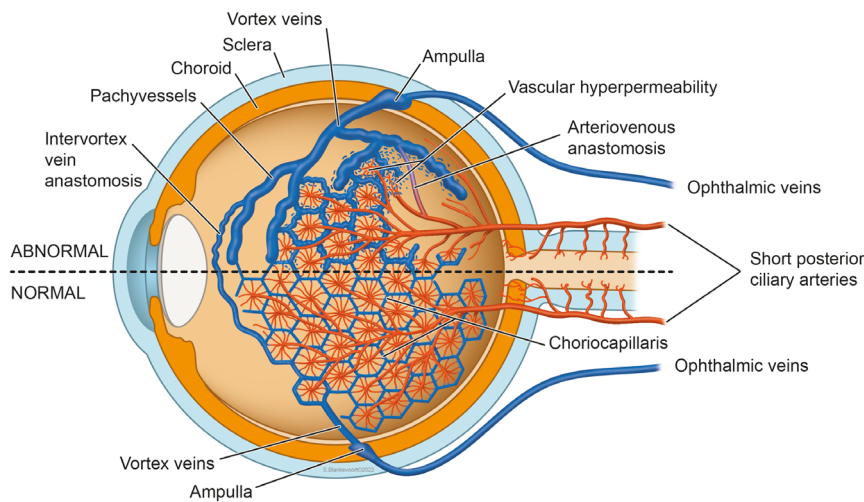


Fig. 4. Illustration of the hypothesis presented in this manuscript, in which choroidal arteriovenous anastomoses are proposed to play a central role in the pathogenesis of pachychoroid spectrum diseases. In a normal situation (bottom half of the illustration), circulation of the choroid starts in short posterior ciliary arteries, which branches into smaller arterioles that eventually feed choriocapillaris lobules. The choriocapillaris is drained by collector venules which merge into vortex veins and exit the eye at the ampulla, through the sclera and continue as ophthalmic veins. In the abnormal situation (upper half of the illustration), a choroidal arteriovenous anastomosis is formed, either as a result of a dysregulated physiological anastomosis or due to a primarily pathological fistula. In the case of such an abnormal choroidal arteriovenous anastomosis, shunting of blood flow occurs from arteries directly into choroidal veins, bypassing the capillary bed. Without the dampening effect of the choriocapillaris on blood pressure, choroidal veins will be affected due to the direct arterial filling, which now become pachyvessels. Consequently, additional signs of venous overload emerge. This includes (1) congestion of blood flow from the ‘upstream’ choriocapillaris resulting in vascular hyperpermeability; (2) venous dilatation of other choroidal veins within the same vortex vein quadrant due to congestion of blood flow at the ampulla; and (3) the manifestation of intervortex vein anastomosis which cross watershed zones and shunt blood from overloaded vortex vein quadrants to neighbouring vortex vein quadrants. This can eventually affect the barrier function of the retinal pigment epithelium overlying these choroidal abnormalities, leading to subretinal fluid accumulation.

significance in the human choroid, particularly given the knowledge gaps in our understanding of the regulation of choroidal blood flow (Nickla & Wallman 2010; Reiner et al. 2018). Dysregulation of such physiological AVAs may contribute to the pathophysiology of the PDS.

Next to malfunctioning physiological AVAs, the primarily pathological variant of AVAs – AVFs – may also play a role in the aetiology of the PDS. Strictly speaking, an AVF is also an AVA, although an AVF is classified as an arteriovenous malformation, *that is* an acquired abnormal arteriovenous connection. AVFs can manifest virtually anywhere in the body and – by definition – never have a physiological function (Allison & Kennedy 1991). Although most AVFs are designated as idiopathic, they have also been described to occur after triggering events such as trauma, inflammation, thrombosis and previous surgery (Allison & Kennedy 1991; Brothers et al. 1995; Gandhi et al. 2012). The degree of shunting is determined by the size of the arteries and veins between which an AVF is formed, and thereby the clinical severity of its signs and symptoms (Allison & Kennedy 1991). A common type of AVF is the dural AVF, which can occur not only cranially, spinally, but also near the cavernous sinus (carotid-cavernous sinus fistula), therewith severely affecting orbital venous outflow (Harbison et al. 1978; Gandhi et al. 2012; Henderson & Miller 2018; Inam et al. 2019). Patients with a carotid-cavernous sinus fistula may present not only with proptosis, ophthalmoplegia, decreased visual acuity, but also with choroidal dysfunction reminiscent of diseases that are part of the PDS (Harbison et al. 1978; Henderson & Miller 2018; Inam et al. 2019; Spaide et al. 2021). However, diseases that are part of the PDS initially present with localized disturbances in the choroidal circulation, rather than abnormalities in the entire choroidal circulation (Dansingani et al. 2016). Although AVFs have not been described thus far in the human choroid, the densely packed vascular network of the choroid may be considered prone to AVF formation, for instance at the site of arteriovenous crossings, which may explain the segmental changes observed in the PDS (Yoneya & Tso 1987; Cheung et al. 2021).

Corticosteroids and Sex Differences are Associated with both Arteriovenous Fistula and Central Serous Chorioretinopathy

Central serous chorioretinopathy is associated with several intriguing risk factors, of which exposure to corticosteroids is the most well-known exogenous risk factor (Daruich et al. 2015; van Rijssen et al. 2019; Kaye et al. 2020). Moreover, the male sex is a strong risk factor, because 80–90% of CSC cases are males, who mostly develop the disease around 40–50 years of age (Kitzmann et al. 2008). Interestingly, specific risk factors of dural AVFs show striking similarities to CSC risk factors. Dural AVFs are pathologic connections between dural arteries and veins that lack a parenchymal nidus (i.e. a mass of malformed blood vessels) (Gandhi et al. 2012). These AVFs are associated with tortuous vessel dilatation, venous hypertension, flow voids, haemorrhage and oedema, being strikingly reminiscent of choroidal abnormalities in pachychoroid spectrum diseases (Gandhi et al. 2012; Laakso & Hernesniemi 2012; Nasr et al. 2017; Spaide et al. 2021). Intriguingly, after administration of corticosteroids, dural AVFs have been observed to induce (sub)acute worsening of neurological complaints (DiSano et al. 2017; Nasr et al. 2017; Peethambar et al. 2019; Le Goueff et al. 2020). This phenomenon has been described in multiple case reports of neurological patients that were initially misdiagnosed with for example an auto-immune neurological disorder, for which corticosteroids were prescribed. The neurological decline attributed to pathological effects of corticosteroids on the AVF was irreversible in some cases (Nasr et al. 2017). It was speculated that the corticosteroids may have caused a transient fluid retention in the venous outflow of the dural AVF due to steroid-induced hypervolemia (DiSano et al. 2017; Nasr et al. 2017). A retrospective review evaluated 21 consecutive cases of a delayed diagnosis of spinal dural AVF who initially received corticosteroid treatment, out of which as many as 7 experienced (sub)acute worsening of the neurological complaints (Nasr

et al. 2017). Although this retrospective study included a relatively small number of patients, it may be interesting to note that 15 patients (71%) were found to be male, whereas there was no male predilection among the 7 patients who developed acute clinical worsening after receiving intravenous methylprednisolone (3 males and 4 females). Interestingly, specifically in corticosteroid-associated CSC, no or less male predilection has been seen, in contrast to non-steroid-associated CSC (Araki et al. 2019).

Sex differences have also been described in surgically created arteriovenous shunts, which are created as an access site for haemodialysis in kidney disease (Waheed et al. 2020). After surgery, these shunts require a period of maturation, and these may fail for instance due to thrombosis. Of note, shunt maturation is much more likely to be successful in males compared with females (Miller et al. 2003; Waheed et al. 2020; Chan et al. 2021; MacRae et al. 2021). In a study that evaluated the outcomes of 230 surgically created shunts, the adequacy for dialysis was 31% in females compared with 51% in males ($p = 0.001$), despite routine pre-operative mapping and interventions to rescue immature fistulas (Miller et al. 2003). The exact cause of these substantial sex differences is not known. In a study by Kudze and colleagues, using a mouse model for sex differences in surgically created AVFs, female mice showed lower magnitudes of laminar shear stress and an increased wall thickness compared with males, which may explain the less successful maturation of dialysis shunts in females (Kudze et al. 2020). Although likely to be complex at the biomolecular level, in this study, it was observed that only male mice showed an increase in endothelial nitric oxide synthase (eNOS) in the vascular wall of the AVF. eNOS is a critical mediator of vasodilatation that may therefore aid in successful shunt maturation (Kudze et al. 2020).

The sex differences and idiosyncratic sensitivity to corticosteroids in the context of specific AVFs may also be of interest regarding the pathophysiology of CSC. Both dural AVFs and CSC are most prevalent in males, and can (sub)acutely be triggered by corticosteroids (Nasr et al. 2017; Kaye et al. 2020). In both diseases, the male predilection appears to be attenuated in the specific context of corticosteroids-induced

cases (Nasr et al. 2017; Araki et al. 2019). This is in line with a recent paper by our group, in which we described a range of cortisol-regulated genes in human choroidal endothelial cell cultures derived from 5 males and 5 females (Brinks et al. 2021a). The most potentially induced gene found in this study was *ZBTB16*, which has been described to enhance the activation of eNOS *in vitro* (Hsu et al. 2012). Of note, we observed a similar induction between the sexes of *ZBTB16* and other cortisol-regulated genes related to endothelial cell dysfunction, suggesting that corticosteroids can trigger endothelial cell dysfunction with equal odds in both sexes – although we did not recapitulate sex-specific hormonal conditions in our study (Brinks et al. 2021a). Although speculative, the peculiar sensitivity to corticosteroids in CSC and dural AVFs may rather be explained by sex differences in the tendency to develop an AVF, instead of intrinsic sex differences in cortisol sensitivity. Thus, combining our experimental observations with the clinical analogies between CSC and dural AVFs, it may be speculated that corticosteroids trigger these diseases particularly in the specific context of a pre-existent choroidal AVF, which consists of already dysfunctional endothelium. As such, it may be hypothesized that these sex differences originate from context-specific differences on the biomolecular level (e.g. dysfunctional endothelium in AVFs), for example in the regulation of eNOS and accompanied nitric oxide production. Such mechanisms involving eNOS have been shown to play a role in mouse AVF models that are used to study sex differences in the maturation of surgically created shunts (essentially AVFs) in humans (Kudze et al. 2018; Kudze et al. 2020). Taken together, pathological effects of corticosteroids may thus be exerted via already dysfunctional endothelium within an AVF, ultimately causing venous overload by yet poorly understood mechanisms.

Arteriovenous Anastomoses and Fistula in the Pachychoroid Disease Spectrum

Based on the analogies between CSC and the different forms of AVAs,

pathological AVFs and surgically created shunts, we propose that choroidal arteriovenous connections could play a causal role in the pathogenesis of CSC. Here, we speculate on how this hypothesis could explain specific aspects of several diseases that are part of the PDS. In addition, 3 patients with CSC are discussed in Figs 5 and 6 and as a video in File S1. In these figures, findings on multimodal imaging are described, in cases which we considered suspect for a potential choroidal AVA or AVF.

The clinical severity and macular localization of central serous chorioretinopathy

Subretinal fluid accumulation accumulation in CSC mostly occurs in the macular area, where choroidal blood flow and shear stress is highest. This region contains the highest vascular density, where arteries and veins are in an intimate spatial relationship. As such, the macula is the most likely area in the choroid where AVAs could exist or where an AVF could manifest. Interestingly, in 1949, Loewenstein observed ‘glomus cells’, which are cell types considered to be part of an AVA, more frequently in the macular region (Loewenstein 1949). The clinical severity of CSC often varies substantially between patients (Mohabati et al. 2018, 2020b). This may be explained by the localization and lumen size of a choroidal AVA or AVF. As such, the order of the arterial branch and the venous branch involved could be a limiting factor for the degree of shunting. Subsequently, the degree of shunting in this scenario determines the extent and severity of consequent venous overload and choriocapillaris dysfunction, and thereby the clinical severity in terms of damage to the overlying RPE and neuroretina. If an abnormal direct arteriovenous connection involves filling of a large choroidal vein under ‘arterial pressure’, this subsequently ‘overloaded’ vein may now become a ‘pachyvessel’. Furthermore, not only this specific vein may locally suffer from venous overload, but also the ‘upstream’ choroidal veins and choriocapillaris, and ‘downstream’ vortex veins. In theory, this could include the choriocapillaris that is drained by this vein and even other choroidal veins within the same vortex vein area, as all choroidal veins merge at the level of the ampulla before exiting

the eye through the sclera. Interestingly, we observed asymmetrical filling of choroidal veins within the same vortex vein area (Fig. 5). This may indeed indicate that some choroidal veins fill earlier than expected due to arteriovenous shunting of blood, leading initially to venous overload in a primary pachyvessel, with subsequent filling of the other pachyvessels of the respective vortex vein drainage area due to congestion at the site of the ampulla. A corresponding phenomenon of slow filling of choroidal veins has been described by Spaide and colleagues in CSC patients using ultra-widefield ICGA (Spaide et al. 2021). In addition, the earlier described phenomenon of an arterial filling delay in CSC may be explained by delayed filling of the upstream choriocapillaris lobules that drain into these congested choroidal veins (Prünke & Flammer 1996). Ultimately, as a result of venous overload caused by choroidal AVAs, intervortex vein anastomoses can manifest and shunt venous blood towards adjacent vortex vein areas, causing a more widespread disturbance in venous outflow in the posterior pole of the eye (Figs 5 and 6, Supplementary File S1).

Acute versus chronic central serous chorioretinopathy

The classification of CSC is subject of variation and controversy, and several novel attempts are made to achieve a refined classification (Chhablani & Behar-Cohen 2020, 2021). However, a general distinction is made between acute and chronic CSC (van Rijssen et al. 2019). Acute CSC is considered a self-limiting disease due to the frequently occurring spontaneous SRF resolution and focal FA abnormalities, accompanied by focal or multifocal abnormalities on ICGA (van Rijssen et al. 2019; Mohabati et al. 2020a; van Dijk & Boon 2021). Chronic CSC commonly shows multifocal leakage and more widespread RPE abnormalities on FA compared with acute CSC, as well as more extensive multifocal choroidal abnormalities on ICGA (van Rijssen et al. 2019; Mohabati et al. 2020a). Given the widespread and persistent abnormalities in chronic CSC, chronic CSC patients generally require treatment (Hanumunthadu et al. 2018; van Rijssen et al. 2019). Acute CSC has been described to lead to chronic CSC only in

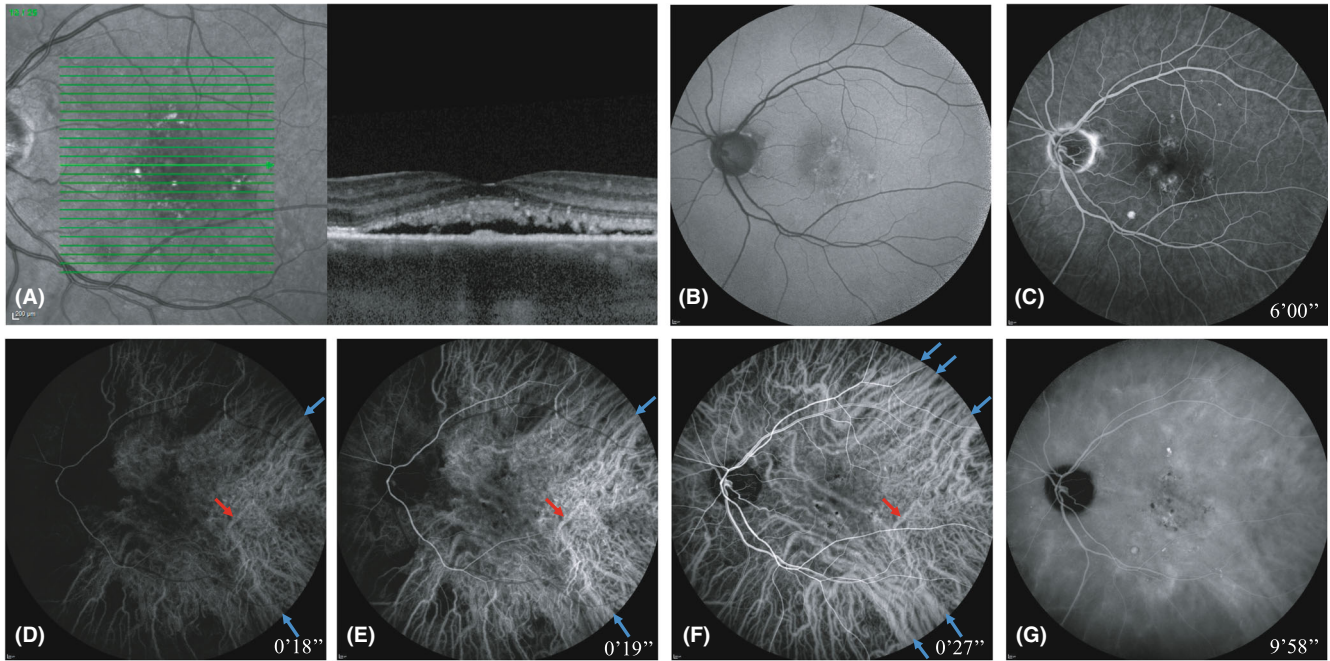


Fig. 5. Multimodal imaging of a patient with unilateral central serous chorioretinopathy. Multimodal imaging (A–G) of the left eye of a 56-year-old man patient with complaints of central vision loss. The complaints started after a stressful period. Medical history of this patient included hypertension and asthma, for which fluticasone was prescribed. The foveal optical coherence tomography (OCT) scan (A) revealed subretinal fluid (SRF) and a subfoveal choroidal thickness of 364 μm . The OCT also showed pachyvessels with attenuation of the overlying choriocapillaris. Fundus autofluorescence (B) mainly showed mild hypo- and hyperautofluorescent changes in the macular region. On mid-phase fluorescein angiography (C), several ‘hot spots’ of leakage were observed in the macula. The arterial phase of indocyanine green angiography at 18 s (D) revealed filling of several vessels with a large lumen suspect for choroidal veins (blue arrowheads). There appears to be a delayed arterial filling of the nasal side compared with the temporal side (E). Several seconds later, complete vortex vein quadrants containing pachyvessels became visible (F), suggestive for asymmetrical venous filling (blue arrowheads E compared with F). In addition, intervortex vein anastomoses emerge which cross the horizontal watershed zone through the macular region (F). Mid-phase indocyanine green angiography (G) showed hyperfluorescent areas with indistinct borders, typical for central serous chorioretinopathy.

a minority of patients (Mohabati et al. 2020a). These differences between acute and chronic CSC may suggest a difference in pathophysiology or rather pathophysiological severity. Considering that choroidal AVAs may prove to be an important pathophysiological mechanism in CSC, acute CSC may be caused by a single AVA that frequently occludes spontaneously, leading to complete SRF resolution. Interestingly, dural AVFs have also been described to frequently resolve spontaneously and sometimes recur, like episodes of CSC (Gandhi et al. 2012). In chronic CSC, the AVA could either be persistent or multiple AVAs may be involved, causing more widespread damage over time due to the consequences of chronic venous overload.

Genetic associations in central serous chorioretinopathy and their potential association with arteriovenous anastomoses

Considering choroidal AVAs as a potential pathogenic mechanism for CSC, it is interesting to speculate on

the potential involvement of specific genetic variations linked to CSC. This includes a variety of genetic variations such as *ARMS2*, *C4B*, *CFH*, *CDH5*, *GATA5*, *NR3C2*, *PTPRB*, *SLC7A5*, *TNFRSF10A* and *VIPR2*, which have been previously reviewed in detail (van Rijssen et al. 2019; Kaye et al. 2020; Brinks et al. 2021b). Interestingly, most of these genetic variations play a role in vascular remodelling, thrombosis, inflammation, cellular migration or angiogenesis, but the exact role in the pathogenesis of CSC is unclear. However, it is known that most of these genes are particularly expressed in endothelial cells, vascular smooth muscle cells and/or the extracellular matrix (Kaye et al. 2020; Brinks et al. 2021b), which all play an important role in vascular dysfunction and malformation (Chan et al. 2021). Therefore, it may be of interest to study not only the role of these CSC-associated genes in the specific context of vascular dysfunction, but of AVA formation in particular. To date, no genetic variations have been described to be specifically associated

with AVAs. However, mutations in the *EPHB4* and the *RASA1* gene have been linked to arteriovenous malformations in general, which encompass a wide spectrum of vascular (developmental) anomalies (Revenu et al. 2013; Amyere et al. 2017). To date, the function of these genes has not been studied in the human choroid, although expression of *EPHB4* and *RASA1* has been described in human choroidal endothelial cells (Voigt et al. 2019).

Half-dose photodynamic therapy specifically targets dysfunctional endothelial cell

Based on strong evidence from the PLACE and SPECTRA prospective randomized clinical trials, as well as other large retrospective studies, photodynamic therapy (PDT) with reduced settings is the most successful treatment option for CSC (Maruko et al. 2010; Lim et al. 2014; van Dijk et al. 2018; van Rijssen et al. 2021b). Interestingly, the hypothesis that AVAs may play an important role in the pathogenesis of

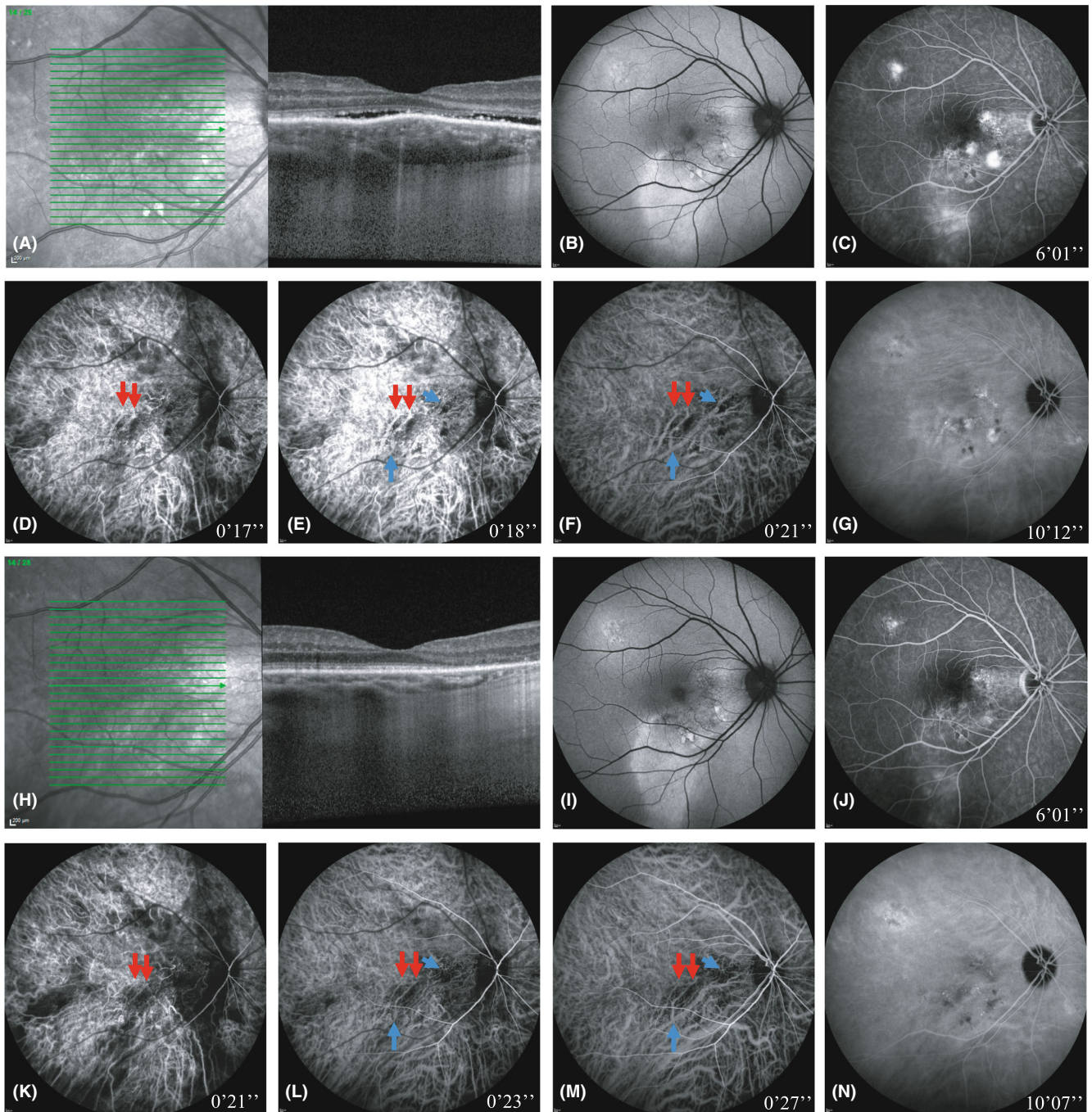


Fig. 6. Multimodal imaging of the right eye of a patient with bilateral central serous chorioretinopathy before (A–G) and after (H–N) treatment with half-dose photodynamic therapy. This 46-year-old male patient presented with complaints of central vision loss and micropsia. Medical history included a burn-out 8 years ago, although there was no reported stress in the period of onset of the complaints. The patient did not use corticosteroids or any other type of medication. The foveal optical coherence tomography (OCT) scan (A) revealed subretinal fluid (SRF) and a subfoveal choroidal thickness of 425 μm . The OCT also showed pachyvessels with attenuation of the overlying choriocapillaris. Fundus autofluorescence (B) mainly showed extensive hyperautofluorescent changes and several spots of hypo-autofluorescence. The mid-phase fluorescein angiography (C) revealed extensive windows defects and hyperfluorescent areas representing active leakage. The arterial phase of indocyanine green angiography at 17 s (D) showed filling of two vessels in the macular region suggestive to be of arterial origin. One second later, filling of choroidal veins started (E; blue arrowheads). Several seconds later, choroidal veins reminiscent of pachyvessels became visible (F; blue arrowheads), which appeared to be directly connected to the arteries (F; red arrowheads) that emerged a few seconds earlier (D; red arrowheads). Mid-phase indocyanine green angiography (G) showed mainly hyperfluorescent changes with indistinct borders, typical for central serous chorioretinopathy, as well as some choroidal folds. The patient received half-dose photodynamic therapy, and multimodal imaging was performed 6 weeks after this treatment (H–N). A complete resolution of subretinal fluid was observed (H), as well as a reduction in hyperfluorescent abnormalities on both fluorescein angiography (J) and indocyanine green angiography (N). Strikingly, signs of vascular remodelling may be observed on the early phase of indocyanine green angiography (K–L), which appeared to show a notable reduction in some of the pachyvessels after half-dose photodynamic therapy (M; top blue arrowheads) compared with the imaging before treatment (F; top blue arrowheads), as well as a general decrease in previous abnormal hyperfluorescence (N). Moreover, the degree of filling of the apparent pachyvessels during the arterial phase in the macular region appeared to be diminished after treatment with half-dose photodynamic therapy (K–M compared with D–F; red arrowheads).

CSC in the current paper could explain the high efficacy of PDT as a treatment for CSC. PDT is a laser treatment designed to target abnormal tissue with high metabolic activity, such as malignant tumours (Chan et al. 2010; Brinks et al. 2021b). This is achieved by intravenous administration of the photosensitizing compound verteporfin, prior to laser application. Endothelial cells have a high rate of lipoprotein endocytosis compared with other cell types and therefore also a high rate of verteporfin ingestion, which makes endothelium sensitive to PDT (Schmidt-Erfurth & Hasan 2000). Moreover, PDT is specifically selective to dysfunctional endothelial cells, because of their abnormally high rate of endocytosis and thus verteporfin ingestion, such as choroidal endothelial cells within choroidal neovascularization or within the arteriovenous malformations of a choroidal haemangioma (Schmidt-Erfurth & Hasan 2000; Verbraak et al. 2003; Eales et al. 2018). As such, the high success rates of PDT in CSC may be explained, at least partially, by selective targeting of dysfunctional choroidal endothelial cells that constitute a choroidal AVA or AVF, inducing closure of such a vascular structure, for example via thrombosis. This would stop or decrease arteriovenous shunting and thereby alleviate venous overload and associated vascular hyperpermeability. Indeed, PDT has shown to often lead to a complete resolution of SRF and also reduces choroidal thickness and the areas of hyperfluorescence detected on mid-phase ICGA (Maruko et al. 2010; van Rijnssen et al. 2019; van Rijnssen et al. 2021a). Of note, this decrease in choroidal thickness could also occur due to 'generic' effects of PDT on the vascular choroidal tissue. A chronic CSC case in which choroidal vascular remodelling appeared to occur after PDT is shown in Fig. 6.

Peripapillary pachychoroid syndrome

Peripapillary pachychoroid syndrome is a distinct entity within the PDS in which a pachychoroid, pachyvessels and SRF are observed specifically in the peripapillary region. Although many features overlap with CSC, including male predilection and the use of corticosteroids as a risk factor, the diseases have been argued to have different pathophysiological mechanisms mainly because

of the specific localization of the choroidal abnormalities (Phasukkijwatana et al. 2018). Interestingly, the peripapillary region of the choroid has been described to have a venous outflow that is separate from the vortex vein system, which is formed by the choroidopial veins (Ruskell 1997). Theoretically, this may suggest that an AVA or AVF in the central choroid results in CSC, while an AVA or AVF connecting a choroidal artery to a choroidopial vein results in PPS. Baek and colleagues proposed a similar pathophysiological mechanism of arteriovenous shunting in eyes with peripapillary polypoidal choroidal vasculopathy (Baek et al. 2019a). PDT has been shown to be effective in PPS in a recent pilot study that included 25 eyes of 23 patients (Iovino et al. 2021). Similar to the proposed effects of PDT described above for CSC, the efficacy of PDT in PPS may involve closure of arteriovenous shunting, between a choroidal artery and choroidopial vein instead of a choroidal vein.

Recent insights and limitations of current choroidal imaging techniques

In the past decades, more in-depth knowledge has been gained on the choroid using multimodal imaging techniques. It is known that ICGA characteristics of CSC show signs of venous overload, including tortuous vessels, flow voids and delayed filling, which are also angiographic features of AVAs and AVFs (Prünke 1995; Komatsu et al. 2010; Gandhi et al. 2012; Kishi et al. 2018; van Rijnssen et al. 2019). The hyperfluorescent areas seen on ICGA in CSC are often reminiscent of areas supplied by medium- to large-sized arteries and veins. Given the lumen size of these blood vessels, this may be considered a suitable level at which a choroidal AVAs or AVFs could have pathological consequences, for instance between an arteriole in Sattler's layer and a larger vein in Haller's layer. The fact that the choroid consists of a high-density vascular meshwork with a very close spatial relationship between numerous arteries and veins, it can be challenging to detect such lesions on even multimodal imaging, especially in deeper choroidal layers, because most imaging modalities have a limited resolution and superimposed choroidal layers obscure detailed imaging of deeper layers (van Rijnssen et al. 2019; Brinks et al. 2021b).

Moreover, if, for example, an AVF would occur at the level of an arteriovenous crossing, it is doubtful whether an actual 'lumen' of an AVF may exist, as the arterial and venous vessel walls are virtually directly adjacent to each other (Yoneya & Tso 1987; Cheung et al. 2021). These limitations in the resolution of imaging also make it hard to determine whether a potentially CSC-causing choroidal AVA is the result of either a physiological AVA that becomes dysfunctional or of an acquired AVF triggered by an event such as trauma, ischaemia or inflammation.

Conclusions and Perspectives

The PDS encompasses an intriguing range of clinical manifestations characterized by choroidal thickening and dysfunction, in combination with venous overload (Fig. 1). In this manuscript, we formulate a hypothesis on the potential of choroidal AVAs or AVFs as a causal and unifying mechanism of the pathophysiological cascade underlying the PDS. In this hypothesis, we aimed to integrate clinical, anatomical, functional, genetic and biomolecular aspects of the PDS. In addition, we present CSC cases with potential evidence of such choroidal AVAs on multimodal imaging (Figs 5 and 6, Supplementary File S1). This manuscript may provide a basis for future studies focusing on the origin of the PDS and the potential role of either AVAs or AVFs. Of note, disease-causing AVFs elsewhere in the human body, such as dural AVFs, show striking similarities to clinical signs of the PDS, including tortuous vessel dilatation, venous overload, vascular hyperpermeability, flow voids and oedema (Gandhi et al. 2012; Laakso & Hernessniemi 2012; Nasr et al. 2017; Spaide et al. 2021), and their response to corticosteroids. As such, we propose that choroidal AVAs or AVFs may be the initial event leading to the manifestations of the choroidal venous overload that are characteristic of the PDS.

If a choroidal AVA or AVF would cause excessive and/or uncontrolled shunting of blood from arteries to veins, bypassing the intermediary capillary bed, the subsequent venous overload can secondarily lead to the manifestation of typical PDS characteristics, such

as pachychoroid, pachyvessels and vascular hyperpermeability (Fig. 4). Moreover, intervortex vein anastomoses, which are venous–venous connections between choroidal veins crossing watershed zones (Spaide et al. 2020; Matsumoto et al. 2020b), can thus be a consequence of venous overload in a vortex vein quadrant, rather than a primary cause of the PDS. Nonetheless, such intervortex vein anastomoses can also be involved in the vascular hyperpermeability that is characteristic of the PDS, as has also been described by Spaide et al. (2021) (Fig. 1C). A potential explanation could be that these blood vessels are not suited to function as mature choroidal veins and therefore leak more easily. Other factors associated with the PDS, such as an increased scleral thickness axial length, and variations in the vortex vein anatomy (Spaide et al. 2021; Imanaga et al. 2021a), may be additional risk factors instead of primary causative mechanisms, as these factors may secondarily contribute to the severity of venous overload, which we hypothesize to be primarily caused by choroidal AVAs. Particularly interesting is the fact that myopia rarely coincides with pachychoroid spectrum diseases, while a short axial length is a risk factor for CSC (Terao et al. 2020; Ravenstijn et al. 2021). Although this may not be directly explained by choroidal AVAs, it may reflect an anatomical feature associated with axial length that modulates the risk to develop choroidal venous overload in case of a choroidal AVA (Terao et al. 2020; Ravenstijn et al. 2021; Spaide et al. 2021).

It is unclear whether the origin of these postulated choroidal arteriovenous shunts may concern a dysregulated primarily physiological AVA, or a primarily pathological AVF that is acquired during life. Of note, elsewhere in the human body, opening and closure of physiological AVAs are known to be actively regulated by vascular smooth muscle cells and/or the autonomous nervous system, and this can serve as the basis for vascular diseases (Daniel & Prichard 1956; Nuzzaci et al. 1988; Parke 2004; Walløe 2016). Likewise, dysfunctional regulation of physiological AVAs in the choroid could be involved in the origin of the PDS. On the contrary, clinical and experimental data from AVFs in other organ systems are surprisingly

reminiscent of peculiar disease aspects of CSC, which are an idiosyncratic sensitivity to corticosteroids and an extraordinarily male preponderance (Kitzmann et al. 2008; Nasr et al. 2017; Kaye et al. 2020; Le Goueff et al. 2020; Waheed et al. 2020). Obviously, this requires detailed anatomical studies of the human choroid, using modern techniques. Moreover, we propose that AVAs or AVFs can be involved in all diseases that are part of the PDS, because of the shared disease characteristics pointing towards venous overload (Spaide et al. 2021). Notwithstanding, it requires further investigation to elucidate the pathophysiological differences between, for example CSC and polypoidal choroidal vasculopathy, and other diseases that are part of the pachychoroid spectrum.

Several approaches can be considered for follow-up studies that could provide more solid evidence for the presence of AVAs or AVFs in the human choroid. It should be noted that most studies on the anatomy of the human choroid were performed decades ago and used FA, conventional histology techniques and post-mortem casts, which all had their limitations in studying the choroidal vascular anatomy in detail (Loewenstein 1949; Wybar 1954; Hayreh 1975). The introduction of detailed spectral-domain ICGA greatly improved knowledge on studying haemodynamics of the choroid and abnormalities in the choroidal vasculature (Prünte 1995; Yannuzzi 2011; Verma et al. 2020), but this technique also has its limitations. For example, it is challenging to delineate single blood vessels due to limitations in resolution and the fact that all vascular layers of the choroid are always imaged simultaneously. Advances in OCT techniques can be useful to overcome part of these limitations. Using enhanced-depth imaging OCT of the choroid, it is possible to distinguish the choroidal vascular layers (Spaide et al. 2008), and with swept-source OCT a reconstruction of choroidal vascular layers can be made in the frontal plane (Dansingani et al. 2016), although the current resolution of this imaging technique may not be sufficient to reliably identify potential AVAs or AVFs. Furthermore, conventional OCT images do not image haemodynamics, which would be key to further assess whether artery-to-vein shunting occurs. Haemodynamics can be studied with

OCT angiography, relying on erythrocyte motion in contrast to fluorescence-based imaging (Ferrara et al. 2016). Currently, the imaging depth of OCT angiography in healthy choroidal tissue is largely limited to the retinal vasculature and the choriocapillaris (Ferrara et al. 2016), but further improvements in this technique may allow for more detailed imaging of the deeper choroidal vascular layers and potential AVAs or AVFs. Interestingly, the novel and experimental technique laser Doppler holography may be suitable to detect potential choroidal AVAs (Puyo et al. 2019a). This technique provides a contrast that is comparable to ICGA and OCT, but has the advantage of separating arteries from veins in deeper choroidal vascular layers based on power Doppler spectral analysis (Puyo et al. 2019a). Still, with this technique, it is difficult to assess the macular region, due to noise in the Doppler signal which may be due to the high density of RPE and photoreceptors in the macula (Puyo et al. 2019a). Another approach to detect potential AVAs or AVFs may be oximetry which can be performed using a non-invasive spectrophotometric oximeter (Kristjansdottir et al. 2013). However, the decline in oxygen concentration between choroidal arteries and veins is known to be only 3%, and therefore, it may be challenging to detect arteriovenous shunting on these narrow margins (Kristjansdottir et al. 2013). Further advancements in the resolution and imaging depth of choroidal imaging techniques will be important to thoroughly assess the potential existence and characteristics of choroidal AVAs or AVFs.

Despite the described limitations, using conventional multimodal imaging, the CSC cases presented in this study are suggestive of the presence of either an abnormally functioning AVA or an AVF (Figs 5 and 6, File S1). The effect of PDT appears to be mediated via targeting of such structures (Fig. 6). In addition to limitations in imaging techniques, the biomolecular aspects of the formation of AVAs and how these structures could cause disease are still poorly understood, and are unexplored in the context of choroidal endothelium. Therefore, it would be of interest to explore the specific aspects of male and female human choroidal endothelium in the context of either AVAs or AVFs, and compare the endothelial features in

AVAs or AVFs to other types of endothelium (Cai et al. 2020; Kudze et al. 2020; Chan et al. 2021). This may also include studies to the effects of corticosteroids on endothelium, vascular smooth muscle cells or local autonomous nervous system activity as a pathological stimulus, as the biomolecular mechanisms underlying the associations between corticosteroids and CSC, and between corticosteroids and dural AVFs, are unknown (Nasr et al. 2017; Brinks et al. 2021a). We have recently described the transcriptome of cultured human choroidal endothelial cells after cortisol exposure in both males and females (Brinks et al. 2021a, 2021b). Although the functional implications are yet to be fully unravelled, cortisol-regulated genes included a range of genes that are potentially relevant in the pathogenesis of the PDS, such as genes involved in vasodilatation mediated by nitric oxide (e.g. *ZBTB16*) and genes involved in barrier function (e.g. *ANGPTL4*) (Brinks et al. 2021a, 2021b). Regarding these studies, particularly, the nitric oxide pathway may be of interest, as this pathway has been shown to be affected in a mouse model for AVF specifically in males (Kudze et al. 2018, 2020).

In conclusion, this manuscript discusses novel perspectives that could improve our understanding of the complex pathophysiology of the PDS. We propose that abnormal arteriovenous shunting in the choroid is a key event preceding pathological changes in pachychoroid spectrum diseases, which is complementary to earlier formulated hypotheses on the PDS (Dansingani et al. 2016; Kishi et al. 2018; Baek et al. 2019a; Jung et al. 2020; Kaye et al. 2020; Cheung et al. 2021; Matsumoto et al. 2021; Spaide et al. 2021; van Dijk & Boon 2021; Brinks et al. 2021b). Future experimental and clinical studies are warranted to confirm that choroidal either AVAs or AVFs are a key feature at the basis of the PDS.

References

- Allison DJ & Kennedy A (1991): Peripheral arteriovenous malformations. *BMJ: Br Med J* **303**: 1191–1194.
- Amyere M, Revencu N, Helaers R et al. (2017): Germline loss-of-function mutations in *EPHB4* cause a second form of capillary malformation-arteriovenous malformation (CM-AVM2) deregulating RAS-MAPK signaling. *Circulation* **136**: 1037–1048.
- Araki T, Ishikawa H, Iwahashi C et al. (2019): Central serous chorioretinopathy with and without steroids: a multicenter survey. *PLoS One* **14**: e0213110.
- Baek J, Dansingani KK, Lee JH, Lee WK & Freund KB (2019a): Choroidal morphology in eyes with peripapillary polypoidal choroidal vasculopathy. *Retina* **39**: 1571–1579.
- Baek J, Kook L & Lee WK (2019b): Choriocapillaris flow impairments in association with pachyvessel in early stages of pachychoroid. *Sci Rep* **9**: 1–6.
- Bergersen TK (1993): A search for arteriovenous anastomoses in human skin using ultrasound Doppler. *Acta Physiol Scand* **147**: 195–201.
- Bergersen TK, Eriksen M & Walloe L (1997): Local constriction of arteriovenous anastomoses in the cooled finger. *Am J Physiol Regul Integr Comp Physiol* **273**: R880–R886.
- Bhutto IA & Amemiya T (2001): Microvascular architecture of the rat choroid: corrosion cast study. *Anat Rec* **264**: 63–71.
- Bischoff P, Niederberger H & Weinacht S (1996): Observations of choroid pulsation. *Klin Monbl Augenheilkd* **208**: 318–320.
- Bosma EK, van Noorden CJF, Schlingemann RO & Klaassen I (2018): The role of plasmalemma vesicle-associated protein in pathological breakdown of blood-brain and blood-retinal barriers: potential novel therapeutic target for cerebral edema and diabetic macular edema. *Fluids Barriers CNS* **15**: 24.
- Brinks J, van Dijk EHC, Kiebaso SM et al. (2021a): The cortisol response of male and female choroidal endothelial cells: implications for central serous chorioretinopathy. *J Clin Endocrinol Metab* **107**: 512–524.
- Brinks J, van Dijk EHC, Klaassen I et al. (2021b): Exploring the choroidal vascular labyrinth and its molecular and structural roles in health and disease. *Prog Retin Eye Res*: 1–47. <https://doi.org/10.1016/j.preteyeres.2021.100994>
- Brothers TE, Stanley JC & Zelenock GB (1995): Splenic arteriovenous fistula. *Int Surg* **80**: 189–194.
- Cai C, Kilari S, Singh AK, Zhao C, Simeon ML, Misra A, Li Y & Misra S (2020): Differences in transforming growth factor- β 1/BMP7 signaling and venous fibrosis contribute to female sex differences in arteriovenous fistulas. *J Am Heart Assoc* **9**: e017420.
- Castro-Correia J (1995): Understanding the choroid. *Int Ophthalmol* **19**: 135–147.
- Chan WM, Lim T-H, Pece A, Silva R & Yoshimura N (2010): Verteporfin PDT for non-standard indications—a review of current literature. *Graefes Arch Clin Exp Ophthalmol* **248**: 613–626.
- Chan SM, Weininger G, Langford J, Jane-Wit D & Dardik A (2021): Sex differences in inflammation during venous remodeling of arteriovenous fistulae. *Front Cardiovasc Med* **8**: 715114–715114.
- Cheung CMG, Lee WK, Koizumi H, Dansingani K, Lai TY & Freund KB (2019): Pachychoroid disease. *Eye* **33**: 14–33.
- Cheung GCM, Chong Teo KY & Spaide R (2021): Pulsatile filling of dilated choroidal vessels in macular watershed zones. *Retina* **41**: 2370–2377.
- Chhablani J & Behar-Cohen F (2020): Multimodal imaging-based central serous chorioretinopathy classification. *Ophthalmol Retina* **4**: 1043–1046.
- Chhablani J & Behar-Cohen F (2021): Validation of central serous chorioretinopathy multimodal imaging-based classification system. *Graefes Arch Clin Exp Ophthalmol*: 1–9. <https://doi.org/10.1007/s00417-021-05452-1>
- Daniel PM & Prichard MM (1956): Arteriovenous anastomoses in the external ear. *Quarter J Exp Physiol Cognate Med Sci: Transl Integr* **41**: 107–123.
- Dansingani KK, Balaratnasingam C, Naysan J & Freund KB (2016): En face imaging of pachychoroid spectrum disorders with swept-source optical coherence tomography. *Retina* **36**: 499–516.
- Daruich A, Matet A, Dirani A, Bousquet E, Zhao M, Farman N, Jaisser F & Behar-Cohen F (2015): Central serous chorioretinopathy: recent findings and new physiopathology hypothesis. *Prog Retin Eye Res* **48**: 82–118.
- van Dijk EHC & Boon CJF (2021): Serous business: delineating the broad spectrum of diseases with subretinal fluid in the macula. *Prog Retin Eye Res* **84**: 100955.
- van Dijk EHC, Fauser S, Breukink MB et al. (2018): Half-dose photodynamic therapy versus high-density subthreshold micropulse laser treatment in patients with chronic central serous chorioretinopathy: the PLACE trial. *Ophthalmology* **125**: 1547–1555.
- DiSano MA, Cerejo R & Mays M (2017): Acute paraparesis and sensory loss following intravenous corticosteroid administration in a case of longitudinally extensive transverse myelitis caused by spinal dural arteriovenous fistula: case report and review of literature. *Spinal Cord Ser Cases* **3**: 17025.
- Donadio V, Nolano M, Provitera V, Stancanelli A, Lullo F, Liguori R & Santoro L (2006): Skin sympathetic adrenergic innervation: an immunofluorescence confocal study. *Ann Neurol* **59**: 376–381.
- Eales KL, Wilkinson EA, Cruickshank G, Tucker JH & Tennant DA (2018): Verteporfin selectively kills hypoxic glioma cells through iron-binding and increased production of reactive oxygen species. *Sci Rep* **8**: 1–12.
- Fernández-Vigo JI, Moreno-Morillo FJ, Shi H, Ly-Yang F, Burgos-Blasco B, Güemes-Villahoz N, Donate-López J & García-Feijóo J (2021): Assessment of the anterior scleral thickness in central serous chorioretinopathy patients by optical coherence tomography. *Jpn J Ophthalmol* **65**: 796–776.
- Ferrara D, Waheed NK & Duker JS (2016): Investigating the choriocapillaris and

- choroidal vasculature with new optical coherence tomography technologies. *Prog Retin Eye Res* **52**: 130–155.
- Funk RH, Mayer B & Wörl J (1994): Nitrgic innervation and nitrgic cells in arteriovenous anastomoses. *Cell Tissue Res* **277**: 477–484.
- Gandhi D, Chen J, Pearl M, Huang J, Gemmete JJ & Kathuria S (2012): Intracranial dural arteriovenous fistulas: classification, imaging findings, and treatment. *Am J Neuroradiol* **33**: 1007–1013.
- Hanumunthadu D, Tan ACS, Singh SR, Sahu NK & Chhablani J (2018): Management of chronic central serous chorioretinopathy. *Indian J Ophthalmol* **66**: 1704–1714.
- Harbison JW, Guerry D & Wiesinger H (1978): Dural arteriovenous fistula and spontaneous choroidal detachment: new cause of an old disease. *Br J Ophthalmol* **62**: 483–490.
- Hayreh SS (1975): Segmental nature of the choroidal vasculature. *Br J Ophthalmol* **59**: 631–648.
- Hayreh SS (1990): In vivo choroidal circulation and its watershed zones. *Eye* **4**: 273–289.
- Hayreh SS (2004): Posterior ciliary artery circulation in health and disease the Weisenfeld lecture. *Invest Ophthalmol Vis Sci* **45**: 749–757.
- Henderson AD & Miller NR (2018): Carotid-cavernous fistula: current concepts in aetiology, investigation, and management. *Eye* **32**: 164–172.
- Hsu YH, Chen YC, Chen TH, Sue YM, Cheng TH, Chen JR & Chen CH (2012): Far-infrared therapy induces the nuclear translocation of PLZF which inhibits VEGF-induced proliferation in human umbilical vein endothelial cells. *PLoS One* **7**: e30674.
- Imanaga N, Terao N, Nakamine S, Tamashiro T, Wakugawa S, Sawaguchi K & Koizumi H (2021a): Scleral thickness in central serous chorioretinopathy. *Ophthalmol Retina* **5**: 285–291.
- Imanaga N, Terao N, Sawaguchi S, Tamashiro T, Wakugawa S, Yamauchi Y & Koizumi H (2021b): Clinical factors related to loculation of fluid in central serous chorioretinopathy. *Am J Ophthalmol* **20**: 197–203.
- Inam O, Arat YO, Yavas GF & Arat A (2019): Retinal and Choroidal optical coherence tomography findings of carotid cavernous fistula. *Am J Ophthalmol* **206**: 264–273.
- Iovino C, Peiretti E, Tatti F et al. (2021): Photodynamic therapy as a treatment option for peripapillary pachychoroid syndrome: a pilot study. London: Eye.
- Jung JJ, Yu DJG, Ito K, Rofagha S, Lee SS & Hoang QV (2020): Quantitative assessment of asymmetric choroidal outflow in pachychoroid eyes on ultra-widefield indocyanine green angiography. *Investig Ophthalmol Vis Sci* **61**: 50–50.
- Kaye R, Chandra S, Sheth J, Boon CJF, Sivaprasad S & Lotery A (2020): Central serous chorioretinopathy: an update on risk factors, pathophysiology and imaging modalities. *Prog Retin Eye Res* **79**: 100865.
- Kishi S, Matsumoto H, Sonoda S, Hiroe T, Sakamoto T & Akiyama H (2018): Geographic filling delay of the choriocapillaris in the region of dilated asymmetric vortex veins in central serous chorioretinopathy. *PLoS One* **13**: e0206646.
- Kitzmann AS, Pulido JS, Diehl NN, Hodge DO & Burke JP (2008): The incidence of central serous chorioretinopathy in Olmsted County, Minnesota, 1980–2002. *Ophthalmology* **115**: 169–173.
- Komatsu H, Young-Devall J, Peyman GA & Yoneya S (2010): Choriocapillary blood propagation in normal volunteers and in patients with central serous chorioretinopathy. *Br J Ophthalmol* **94**: 289–291.
- Kristjansdottir JV, Hardarson SH, Harvey AR, Olafsdottir OB, Eliasdottir TS & Stefánsson E (2013): Choroidal oximetry with a non-invasive spectrophotometric oximeter. *Invest Ophthalmol Vis Sci* **54**: 3234–3239.
- Kudze T, Isaji T, Ono S, Hashimoto T, Yatsula B, Hu H, Liu H & Dardik A (2018): Are there sex-specific differences in arteriovenous fistula maturation? Arteriosclerosis, Thrombosis, and Vascular Biology **38**: A280–A280.
- Kudze T, Ono S, Fereydooni A et al. (2020): Altered x during arteriovenous fistula remodeling leads to reduced fistula patency in female mice. *JVS Vasc Sci* **1**: 42–56.
- Laakso A & Hernesniemi J (2012): Arteriovenous malformations: epidemiology and clinical presentation. *Neurosurg Clin N Am* **23**: 1–6.
- Laurie SS, Elliott JE, Goodman RD & Lovering AT (2012): Catecholamine-induced opening of intrapulmonary arteriovenous anastomoses in healthy humans at rest. *J Appl Physiol* **113**: 1213–1222.
- Le Goueff A, Mavroudakakis N, Mine B, De Witte O & Remiche G (2020): Acute paraparesis after epidural corticosteroid injection revealing spinal dural arteriovenous fistula in a HIV patient. *Eur J Case Rep Intern Med* **7**: 001673.
- Lee JE, Ahn KS, Park KH, Pak KY, Kim HJ, Byon IS & Park SW (2017): Functional end-arterial circulation of the choroid assessed by using fat embolism and electric circuit simulation. *Sci Rep* **7**: 1–9.
- Lee SS, Robinson MR & Weinreb RN (2019): Episcleral venous pressure and the ocular hypotensive effects of topical and intracameral prostaglandin analogs. *J Glaucoma* **28**: 846.
- Lee YJ, Lee YJ, Lee JY & Lee S (2021): A pilot study of scleral thickness in central serous chorioretinopathy using anterior segment optical coherence tomography. *Sci Rep* **11**: 5872.
- Lim JJ, Glassman AR, Aiello LP, Chakravarthy U, Flaxel CJ & Spaide RF (2014): Collaborative retrospective macula society study of photodynamic therapy for chronic central serous chorioretinopathy. *Ophthalmology* **121**: 1073–1078.
- Loewenstein A (1949): Glomus cells in the human choroid as the basis of arteriovenous anastomoses. *Am J Ophthalmol* **32**: 1651–1659.
- Lovering AT, Duke JW & Elliott JE (2015): Intrapulmonary arteriovenous anastomoses in humans—response to exercise and the environment. *J Physiol* **593**: 507–520.
- Lutty GA & McLeod DS (2018): Development of the hyaloid, choroidal and retinal vasculatures in the fetal human eye. *Prog Retin Eye Res* **62**: 58–76.
- MacRae JM, Clarke A, Ahmed SB et al. (2021): Sex differences in the vascular access of hemodialysis patients: a cohort study. *Clin Kidney J* **14**: 1412–1418.
- Maruko I, Iida T, Sugano Y, Ojima A, Ogasawara M & Spaide RF (2010): Subfoveal choroidal thickness after treatment of central serous chorioretinopathy. *Ophthalmology* **117**: 1792–1799.
- Matsumoto H, Kishi S, Mukai R & Akiyama H (2019): Remodeling of macular vortex veins in pachychoroid neovascularopathy. *Sci Rep* **9**: 14689.
- Matsumoto H, Hoshino J, Mukai R, Nakamura K, Kikuchi Y, Kishi S & Akiyama H (2020b): Vortex vein anastomosis at the watershed in pachychoroid spectrum diseases. *Ophthalmol Retina* **4**: 938–945.
- Matsumoto H, Hoshino J, Mukai R, Nakamura K, Kishi S & Akiyama H (2021): Pulsation of anastomotic vortex veins in pachychoroid spectrum diseases. *Sci Rep* **11**: 14942.
- Midttun M (2000): Blood flow rate in arteriovenous anastomoses: from the cradle to the grave. *Clinical Physiology* **20**: 360–365.
- Miller CD, Robbin ML & Allon M (2003): Gender differences in outcomes of arteriovenous fistulas in hemodialysis patients. *Kidney Int* **63**: 346–352.
- Mochizuki M, Sugita S & Kamoi K (2013): Immunological homeostasis of the eye. *Prog Retin Eye Res* **33**: 10–27.
- Mohabati D, van Dijk EHC, van Rijssen TJ et al. (2018): Clinical spectrum of severe chronic central serous chorioretinopathy and outcome of photodynamic therapy. *Clin Ophthalmol* **12**: 2167–2176.
- Mohabati D, Boon CJF & Yzer S (2020a): Risk of recurrence and transition to chronic disease in acute central serous chorioretinopathy. *Clin Ophthalmol* **14**: 1165–1175.
- Mohabati D, Schellevis RL, van Dijk EHC et al. (2020b): Genetic risk factors in severe, nonsevere and acute phenotypes of central serous chorioretinopathy. *Retina* **40**: 1734–1741.
- Nasr DM, Brinjikji W, Rabinstein AA & Lanzino G (2017): Clinical outcomes following corticosteroid administration in patients with delayed diagnosis of spinal arteriovenous fistulas. *J Neurointerv Surg* **9**: 607–610.
- Nickla DL & Wallman J (2010): The multifunctional choroid. *Prog Retin Eye Res* **29**: 144–168.
- Nuzzaci G, Pesciullesi E, Lucarelli F, Lucente E, Ferri P, Tonarelli AP, Righi D & Mangoni N (1988): Arteriovenous anastomoses’ function and Raynaud’s phenomenon. *Angiology* **39**: 812–818.
- Parke WW (2004): Arteriovenous glomeruli of the human spinal cord and their possible

- functional implications. *Clin Anat* **17**: 558–563.
- Parver LM (1991): Temperature modulating action of choroidal blood flow. *Eye* **5**: 181–185.
- Paula KY, Tan PE, Cringle SJ, McAllister IL & Yu D-Y (2013): Phenotypic heterogeneity in the endothelium of the human vortex vein system. *Exp Eye Res* **115**: 144–152.
- Peethambar GA, Whittam DH, Huda S, Alusi S, Puthuran M, Chandran A, Eldridge PR & Jacob A (2019): Intracranial dural arteriovenous fistula mistaken as cervical transverse myelitis. *Pract Neurol* **19**: 264–267.
- Phasukkijwatana N, Freund KB, Dolz-Marco R et al. (2018): Peripapillary pachychoroid syndrome. *Retina* **38**: 1652–1667.
- Prünte C (1995): Indocyanine green angiographic findings in central serous chorioretinopathy. *Int Ophthalmol* **19**: 77–82.
- Prünte C & Flammer J (1996): Choroidal capillary and venous congestion in central serous chorioretinopathy. *Am J Ophthalmol* **121**: 26–34.
- Puyo L, Paques M, Fink M, Sahel J-A & Atlan M (2019a): Choroidal vasculature imaging with laser Doppler holography. *Biomed Opt Express* **10**: 995–1012.
- Ravenstijn M, van Dijk EHC, Haarman AEG et al. (2021): Myopic presentation of central serous chorioretinopathy. *Retina* **41**: 2472–2478.
- Reiner A, Fitzgerald MEC, Del Mar N & Li C (2018): Neural control of choroidal blood flow. *Prog Retin Eye Res* **64**: 96–130.
- Revenu N, Boon LM, Mendola A et al. (2013): RASA 1 mutations and associated phenotypes in 68 families with capillary malformation–arteriovenous malformation. *Hum Mutat* **34**: 1632–1641.
- van Rijssen TJ, van Dijk EHC, Yzer S et al. (2019): Central serous chorioretinopathy: towards an evidence-based treatment guideline. *Prog Retin Eye Res* **73**: 100770.
- van Rijssen TJ, Hahn LC, van Dijk EHC et al. (2021a): Response of choroidal abnormalities to photodynamic therapy versus micro-pulse laser in chronic central serous chorioretinopathy: PLACE trial report no. 4. *Retina* **41**: 2122–2131.
- van Rijssen TJ, van Dijk EHC, Tsonaka R et al. (2021b): Half-dose photodynamic therapy versus eplerenone in chronic central serous chorioretinopathy (SPECTRA): a randomized controlled trial. *Am J Ophthalmol* **233**: 101–110.
- Ruskell GL (1997): Peripapillary venous drainage from the choroid: a variable feature in human eyes. *Br J Ophthalmol* **81**: 76–79.
- Sappey PC (1874): *Traité d'anatomie descriptive*, Vol. 4. Paris: A. Delahaye.
- Schlingemann RO, Dingjan GM, Blok J, Emeis JJ, Warnaar SO & Ruiter DJ (1985): Monoclonal antibody PAL-E specific for endothelium. *Lab Invest* **52**: 71–76.
- Schmidt-Erfurth U & Hasan T (2000): Mechanisms of action of photodynamic therapy with verteporfin for the treatment of age-related macular degeneration. *Surv Ophthalmol* **45**: 195–214.
- Selbach JM, Rohen JW, Steuhl K-P & Lütjens-Drecoll E (2005): Angioarchitecture and innervation of the primate anterior episclera. *Curr Eye Res* **30**: 337–344.
- Shimizu K & Ujiie K (1978): Structure of ocular vessels. Tokyo: Igaku-Shoin Medical Publishers.
- Siedlecki J, Schworm B & Priglinger SG (2019): The pachychoroid disease spectrum—and the need for a uniform classification system. *Ophthalmol Retina* **3**: 1013–1015.
- Spaide RF (2020): Choroidal blood flow: review and potential explanation for the choroidal venous anatomy including the vortex vein system. *Retina* **40**: 1851–1864.
- Spaide RF (2021): The ambiguity of pachychoroid. *Retina* **41**: 231–237.
- Spaide RF, Koizumi H & Pozonni MC (2008): Enhanced depth imaging spectral-domain optical coherence tomography. *Am J Ophthalmol* **146**: 496–500.
- Spaide RF, Ledesma-Gil G & Cheung G (2020): Intervortex venous anastomosis in pachychoroid-related disorders. *Retina* **41**: 997–1004.
- Spaide RF, Cheung CMG, Matsumoto H et al. (2021): Venous overload choroidopathy: a hypothetical framework for central serous chorioretinopathy and allied disorders. *Prog Retin Eye Res* **86**: 100973.
- Terao N, Koizumi H, Kojima K et al. (2020): Short axial length and hyperopic refractive error are risk factors of central serous chorioretinopathy. *Br J Ophthalmol* **104**: 1260–1265.
- Teussink MM, Breukink MB, van Grinsven MJ, Hoyng CB, Klevering BJ, Boon CJF, de Jong EK & Theelen T (2015): OCT angiography compared to fluorescein and indocyanine green angiography in chronic central serous chorioretinopathy. *Invest Ophthalmol Vis Sci* **56**: 5229–5237.
- Vangaard L, Kuklane K, Holmer I & Smolander J (2012): Thermal responses to whole-body cooling in air with special reference to arteriovenous anastomoses in fingers. *Clin Physiol Funct Imaging* **32**: 463–469.
- Verbraak FD, Schlingemann RO, Keunen JEE & De Smet MD (2003): Longstanding symptomatic choroidal hemangioma managed with limited PDT as initial or salvage therapy. *Graefes Arch Clin Exp Ophthalmol* **241**: 891–898.
- Verma A, Maram J, Alagorie AR et al. (2020): Distribution and location of vortex vein ampullae in healthy human eyes as assessed by ultra-widefield indocyanine green angiography. *Ophthalmology Retina* **4**: 530–534.
- Voigt AP, Mulfaul K, Mullin NK et al. (2019): Single-cell transcriptomics of the human retinal pigment epithelium and choroid in health and macular degeneration. *Proc Natl Acad Sci* **116**: 24100–24107.
- Waheed A, Masengu A, Skala T, Li G, Jastrzebski J & Zalunardo N (2020): A prospective cohort study of predictors of upper extremity arteriovenous fistula maturation. *J Vasc Access* **21**: 746–752.
- Walløe L (2016): Arterio-venous anastomoses in the human skin and their role in temperature control. *Temperature (Austin)* **3**: 92–103.
- Warrow DJ, Hoang QV & Freund KB (2013): Pachychoroid pigment epitheliopathy. *Retina* **33**: 1659–1672.
- Wybar KC (1954): Vascular anatomy of the choroid in relation to selective localization of ocular disease. *Br J Ophthalmol* **38**: 513–517.
- Yannuzzi LA (2011): Indocyanine green angiography: a perspective on use in the clinical setting. *Am J Ophthalmol* **151**(745–751): e1.
- Yoneya S & Tso MO (1987): Angioarchitecture of the human choroid. *Arch Ophthalmol* **105**: 681–687.
- Zouache MA, Eames I, Klettner CA & Luthert PJ (2016): Form, shape and function: segmented blood flow in the choriocapillaris. *Sci Rep* **6**: 1–13.

Received on January 24th, 2022.

Accepted on January 26th, 2022.

Correspondence:

Camiel J. F. Boon, MD, PhD

Department of Ophthalmology

Amsterdam University Medical Centres

University of Amsterdam

Meibergdreef 9

1105 AZ Amsterdam

The Netherlands

Tel: +31 205 663 100Email:

camiel.boon@amsterdamumc.nl

Supporting Information

Additional Supporting Information may be found in the online version of this article:

File S1. Indocyanine green angiography of the right eye of a 62-year-old man with bilateral central serous chorioretinopathy. This patient presented with central vision loss and metamorphopsia. The patient did not have a medical history, although he described his work as stressful. Indocyanine green angiography video revealed pulsatile filling of an apparent choroidal artery (indicated with a red circle in slow motion), superonasally to the macular region. As filling of the choroidal vasculature progresses, the artery that shows pulsatile filling appears to be a directly communicating lumen with intervortex vein anastomosis that cross the nasal macular region and feed an extensive network of pachyvessels inferior to the macula.