

Case Report

Diagnosis of Hydatid Cyto-Biliary Disease by Intraductal Ultrasound (With Video)

Randa Akel¹, Walid Faraj^{2,3}, Ali Haydar^{3,4}, Omar Masri¹, Nadim El-Majzoub⁵, Mohamad J. Khalife^{2,3}, Mohamad A. Eloubeidi^{1,3*}

¹Division of Gastroenterology and Hepatology, Department of Medicine, ²Division of GI Surgery, ³Department of Diagnostic Radiology, ⁴Hepato-biliary and Liver transplant Unit, ⁵Department of Pathology and Laboratory Medicine, The American University of Beirut School of Medicine, Beirut, Lebanon

Abstract

Hydatid disease is one of the relatively common infections in the Middle Eastern countries. It is seen in areas where dogs are used to raise livestock. In humans, the majority of *Echinococcus* cysts tends to develop in the liver (70%) and is asymptomatic. The two most common complications of hydatid cysts are abscess formation and rupture. Furthermore, in 5-25% of patients, rupture occurs into the biliary tract and patients may present with cholangitis, jaundice, abscess, or bilio-cutaneous fistula after surgery. Intraductal ultrasound (IDUS) is reportedly superior to conventional endoscopic ultrasound for the depiction of bile duct obstruction owing to its additional capability of providing higher resolution images due to the use of higher frequency transducers. Unfortunately IDUS is rarely used, possibly due to the limited availability of appropriate IDUS equipment, cost of the procedure and interventional endoscopists trained in its interpretation. IDUS with wire-guided, thin-caliber, high-frequency probes is a promising imaging modality, yet no previous reports discuss its usefulness in hydatid disease investigation. We hereby present the first report of biliary hydatid disease being diagnosed by IDUS.

Keywords: biliary disease; hydatid disease; intraductal ultrasound

Akel R, Faraj W, Haydar A, Masri O, El-Majzoub N, Khalife MJ, Eloubeidi MA. Diagnosis of Hydatid Cyto-Biliary Disease by Intraductal Ultrasound (With Video). *Endosc Ultrasound* 2013; 2(4): 225-227.

INTRODUCTION

Hydatid disease is one of the relatively common infections in the Middle Eastern countries including Iraq, Jordan, Syria and Lebanon. This disease is particularly seen in areas where dogs are used to raise livestock. Dogs and other carnivores are the definitive hosts of this parasite, while humans among other mammals are the intermediate hosts who acquire the disease through the accidental ingestion of *Echinococcus* eggs. In humans, the majority of *Echinococcus* cysts tend to develop in the liver (70%) and are asymptomatic.¹⁻³ The two most common complications of hydatid cysts are abscess formation and rupture. Furthermore, in 5%-25% of patients

rupture occurs into the biliary tract and patients may present with cholangitis, jaundice, abscess, or bilio-cutaneous fistula after surgery.⁴

Patients presenting with suspected biliary obstruction tend to primarily undergo imaging with computed tomography (CT), magnetic resonance imaging (MRI), or ultrasonography (US). In case no mass lesion is apparent, then the next diagnostic test recommended is endoscopic ultrasonography (EUS). However in clinical practice physicians tend to perform endoscopic retrograde cholangiopancreatography (ERCP) instead for both diagnosis and therapy.⁵ Intraductal ultrasound (IDUS) is reportedly superior to conventional EUS for the depiction of bile duct obstruction;⁶ but it is rarely used, possibly due to the limited availability of appropriate IDUS equipment and interventional endoscopists trained in IDUS interpretation.

IDUS with wire-guided, thin-caliber, high-frequency probes is a promising imaging modality, yet no previous reports discuss its usefulness in hydatid disease investigation. We present the first report of biliary hydatid disease being diagnosed by IDUS.

Video Available on: www.eusjournal.com

*To whom correspondence should be addressed.

E-mail: me75@aub.edu.lb

Received: 2013-06-11; Accepted: 2013-08-11

DOI: 10.4103/2303-9027.121246

CASE REPORT

We report a case of a 34-year-old Iraqi male patient presented to the American University of Beirut Medical Center with a fifteen day history of right upper quadrant pain, fever, drenching night sweats, chills and jaundice. Pertinent history was negative for similar episodes, but positive for surgical liver lesion excision four years ago. Upon presentation patient had no altered level of consciousness, vomiting, diarrhea or oliguria. The initial working diagnosis was Klatskin tumor versus post-operative stricture since imaging (MRI/CT/US) revealed 4 cm × 4 cm × 4 cm lesion in the right lobe segment VI with intra-hepatic and common hepatic duct (CHD) dilation and normal distal common bile duct (CBD). ERCP attempt in Iraq failed to cannulate the CBD. On presentation and exam, patient was hemodynamically stable (BP 140/80 mm Hg), afebrile (37°C) and jaundiced with a negative Murphy sign. Leukocytosis (15,300/cu.mm) with eosinophilia (30%) was noted on peripheral smear. Liver function tests were abnormally high (serum glutamic oxaloacetic transaminase [SGOT], 140 units/L; serum glutamic pyruvate transaminase, 512 units/L; gamma glutamyl transpeptidase (GT), 1519 units/L; alkaline phosphatase, 713 units/L; total bilirubin, 13.5 mg/dL; direct bilirubin, 10.2 mg/dL). Other routine hematological and biochemical tests were within the normal ranges. Tumor marker CA 19-9 was elevated (1506 U/mL). Triphasic CT (Fig. 1) revealed dilatation of the CHD and the intra-hepatic biliary tree, to the level of the hilum of the cystic and hepatic ducts with an area of wall thickening and enhancement along the anterior aspect of the CHD and adjacent abrupt decrease in the caliber of the duct. A cystic lesion measuring 4.3 cm × 4.3 cm × 5.7 cm was seen in the posterior aspect of the right lobe (spanning segments VI and VII), showing continuity with a dilated branch of the right hepatic duct. In addition, there was thick material within the proximal CHD and the CBD was not visualized and probably strictured. Once hydatid serology was positive (hydatid indirect hemagglutinin 1:32,768) patient was started on Albendazole and Tazocin. Patient then underwent ERCP revealing the stricture and filling defect seen in Fig. 2. In order to further investigate the stricture and during ERCP in the same setting, IDUS (over the wire UM-G20-29R Miniprobe, scanning at 20 MHz) demonstrated hyperechoic membranes consistent with hydatid disease (Videos 1, 2 and Fig. 3). Stenting was then preformed with a 7 Fr 12 cm stent with improvement in his cholangitis and resolution of jaundice. Patient then underwent surgery where the hydatid cyst of the liver was injected with citramide, followed by aspiration of all the fluids and daughter cysts. The wall of the cyst was cut and removed with identification of the biliary-cystic fistula, which was cannulated with a small feeding tube and repetitive irrigation with normal saline was performed. The fistula was then sutured and the cyst edges were marsupialized with vicryl sutures. A cholecystectomy

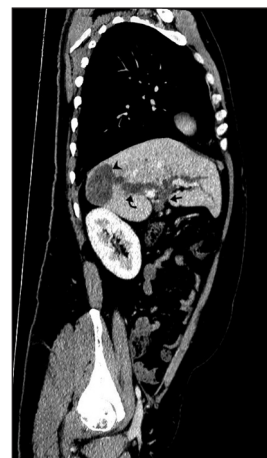

Figure 1. Curved reformatted computed tomography with intravenous contrast showing the hydatid cyst (arrow head) communicating with the dilated biliary tree (curved arrow) and dense material in the proximal hepatic duct indicating the daughter cyst (solid arrow)

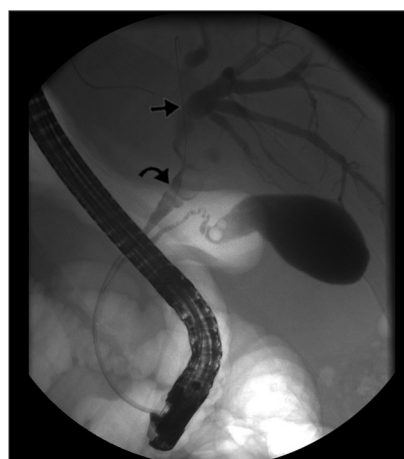

Figure 2. Endoscopic retrograde cholangiopancreatography showing contrast within dilated biliary tree (solid arrow) and daughter cyst within proximal hepatic duct (curved arrow)

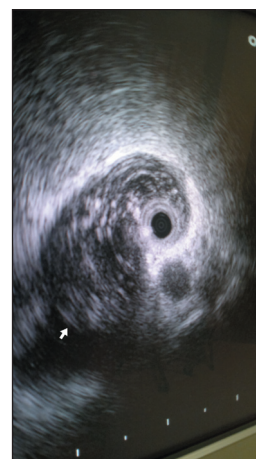

Figure 3. Intraductal ultrasound revealed a hyperechoic filling defect most consistent with hydatid disease and not infiltrating tumor thus ruling out cholangiocarcinoma

was also done. On follow-up 1-month later, his jaundice resolved and laboratory findings normalized (SGOT, 27 units/L; gamma GT, 139 units/L; alkaline phosphatase, 91 units/L; total bilirubin, 0.3 mg/dL; direct bilirubin, <0.1 mg/dL; eosinophils, 1%; CA 19-9, 16 U/mL). ERCP 1-month later showed a decrease in the intra-hepatic biliary ductal dilatation, the CHD was no longer dilated and the stent was then removed (Fig. 4). At 1 year follow-up, the patient was doing well without any recurrence.

DISCUSSION

The most common complication of hepato-biliary hydatid disease is cholestasis secondary to rupture of hepatic cysts into the biliary tree. It has been shown that parasitic cyst walls are quite fragile and proximity of the cyst to biliary ducts leads to the rupture of the cyst into the biliary tree. Patients will present with symptoms of jaundice and possibly abdominal pain, thus requiring work-up for suspected biliary obstruction principally ruling out malignant versus benign causes of obstruction. The majority of isolated extra-hepatic strictures are considered malignant until proven otherwise, particularly in patients with no history of biliary surgery.⁷ In clinical practice many physicians go directly to ERCP for diagnosis and therapy; however CT, MRI and US have all been recommended for preliminary diagnosis and if no mass lesion is evident then EUS is the next recommended diagnostic test.

Moreover, a promising imaging modality that is reportedly superior to conventional EUS for the depiction of bile duct obstruction is IDUS with wire-guided, thin-caliber, high-frequency probes.⁶ IDUS allows clear evaluation of the bile duct wall and structures in its immediate vicinity. Compared with EUS, it not only allows examination of the proximal bile ducts, but also provides higher resolution images due to the use of higher frequency transducers.⁸

To the best of our knowledge EUS has been used in the investigation of extra-hepatic hydatid disease, but IDUS has not. As is evident in the above figures and videos the appearance of hyperechoic membranes using IDUS was highly suggestive of hydatid disease. Using this available modality in the endoscopy unit, we were able to rule out cholangiocarcinoma or klaskin tumor on the spot. This further goes to prove that it might be beneficial to perform IDUS during the same assessment of biliary strictures by ERCP to provide information adjunctive to the endoscopic, cholangiographic and cytologic findings thus providing more reliable and precise information.^{3,9} In fact certain experts report that IDUS appears to be superior to ERCP in defining the nature of the biliary stricture.⁷

IDUS has not always been very popular due to the limited availability of appropriate IDUS equipment in endoscopic

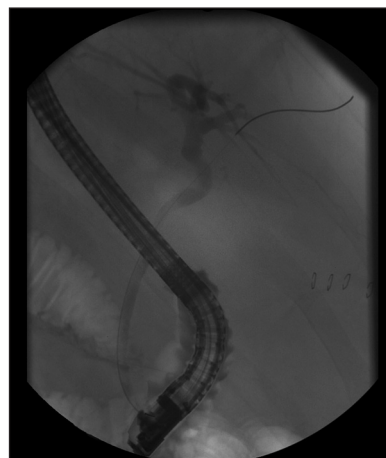


Figure 4. One month follow-up endoscopic retrograde cholangiopancreatography showing no dilation of biliary tree and no evidence of filling defect within hepatic duct

units, cost of the procedure and the insufficient training of interventional endoscopists in IDUS interpretation. However given the added benefit of its use for diagnosis and management of biliary disease, there is an increasing trend today towards adopting this emerging imaging modality in our endoscopic units.

REFERENCES

1. Raptou G, Pliakos I, Hytioglou P, et al. Severe eosinophilic cholangitis with parenchymal destruction of the left hepatic lobe due to hydatid disease. *Pathol Int* 2009; 59: 395-8.
2. Simşek H, Ozaslan E, Sayek I, et al. Diagnostic and therapeutic ERCP in hepatic hydatid disease. *Gastrointest Endosc* 2003; 58: 384-9.
3. Smiljanic L, Papic N, Patrlj L, et al. Education and imaging. Hepatobiliary and pancreatic: Biliary rupture of an hydatid cyst. *J Gastroenterol Hepatol* 2010; 25: 431.
4. Khoshbaten M, Farhang S, Hajavi N. Endoscopic retrograde cholangiopancreatography for intrabiliary rupture of hydatid cyst. *Dig Endosc* 2009; 21: 277-9.
5. Krishna NB, Saripalli S, Safdar R, et al. Intraductal US in evaluation of biliary strictures without a mass lesion on CT scan or magnetic resonance imaging: Significance of focal wall thickening and extrinsic compression at the stricture site. *Gastrointest Endosc* 2007; 66: 90-6.
6. Farrell RJ, Agarwal B, Brandwein SL, et al. Intraductal US is a useful adjunct to ERCP for distinguishing malignant from benign biliary strictures. *Gastrointest Endosc* 2002; 56: 681-7.
7. Jha R, Al-Kawas FH. How good is IDUS in patients with isolated biliary strictures? *Am J Gastroenterol* 2004; 99: 1690-1.
8. Lee JH, Salem R, Aslanian H, et al. Endoscopic ultrasound and fine-needle aspiration of unexplained bile duct strictures. *Am J Gastroenterol* 2004; 99: 1069-73.
9. Domagk D, Wessling J, Reimer P, et al. Endoscopic retrograde cholangiopancreatography, intraductal ultrasonography, and magnetic resonance cholangiopancreatography in bile duct strictures: A prospective comparison of imaging diagnostics with histopathological correlation. *Am J Gastroenterol* 2004; 99: 1684-9.