

# Localized nasopharyngeal amyloidosis mimicking malignancy

## A case report

Jong Seung Kim, MD<sup>a,b</sup>, Sam Hyun Kwon, MD, PhD<sup>a,b,\*</sup>

### Abstract

**Rationale:** Nasopharyngeal amyloidosis is a benign, slowly progressive disease that is characterized by extracellular eosinophilic deposition.

**Patient Concerns:** We report a rare case of localized nasopharyngeal amyloidosis.

**Diagnoses:** The initial chief complaint of this patient was frequent epistaxis and right aural fullness. The initial diagnosis was nasopharyngeal tumor.

**Interventions:** There is no universally effective medical treatment for nasopharyngeal amyloidosis but surgery can be an option. We performed careful observation with regular follow-up by nasopharyngoscopy and radiologic study.

**Outcomes:** The patient reported no further complaints at 1-year follow-up and the lesion from nasopharyngeal amyloidosis was still present.

**Lessons:** Although it is rare, nasopharyngeal amyloidosis should be considered in the differential diagnosis of epistaxis, nasal obstruction, and otitis media with effusion, which are the main symptoms of nasopharyngeal carcinoma. In the absence of systemic disease, localized nasopharyngeal amyloidosis may be treated conservatively.

**Abbreviation:** MRI = magnetic resonance imaging.

**Keywords:** amyloidosis, case report, nasal cavity, nasopharynx

## 1. Introduction

Amyloidosis is a benign, slowly progressive disease that is characterized by extracellular eosinophilic deposition of insoluble polymeric fibrillar proteins in tissues and organs.<sup>[1]</sup> It is currently classified into 2 main forms, systemic and localized, with marked differences in prognosis between the 2 forms. The prognosis of systemic amyloidosis is worse than that for the localized form.<sup>[2]</sup> Currently, the majority of types of systemic amyloidosis have no universally effective treatment.<sup>[3]</sup> Nasopharyngeal amyloidosis, a type of localized amyloidosis, is a very rare

condition with few cases reported in the English scientific literature.

We describe a patient with primary localized nasopharyngeal amyloidosis whose endoscopic finding mimicked a malignant mass on both torus tubarius.

This study was approved by the institutional review board of Chonbuk National University Hospital. Informed consent was given by the patient.

## 2. Case report

A 73-year-old man presented to our otolaryngology clinic with the chief complaint of frequent epistaxis and right aural fullness. Subsequent head and neck examination revealed middle ear effusion in the right ear. Nasopharyngoscopy revealed a nasopharyngeal mass on both torus tubarius with no evidence of complete obstruction of the Eustachian tube (Fig. 1A and B). Pure tone audiometry showed conductive hearing loss on the right side. Otherwise, there were no remarkable findings in other parts of the body.

Biopsy of this lesion demonstrated amorphous eosinophilic deposits (Fig. 2A) which showed apple-green birefringence on Congo red staining (Fig. 2B). Axial, sagittal, and coronal cuts from magnetic resonance imaging (MRI) (Fig. 3A, B–D) demonstrated a localized lesion in the nasopharynx at the torus tubarius with no evidence of destructive or invasive behavior. Serum immunofixation electrophoresis and urine protein electrophoresis showed no evidence of monoclonal gammopathy or proteinuria. Biopsy of abdominal fat and rectal samples showed no evidence of amyloid infiltration. Bone marrow biopsy showed no evidence of infiltration or tumor.

Editor: Jagdeep Thakur.

Funding: This paper was supported by Fund of Biomedical Research Institute, Chonbuk National University Hospital.

The authors have no conflicts of interest to disclose.

<sup>a</sup> Department of Otolaryngology-Head and Neck Surgery, Chonbuk National University Hospital, <sup>b</sup> Research Institute of Clinical Medicine Chonbuk National University, Jeonju, Republic of Korea.

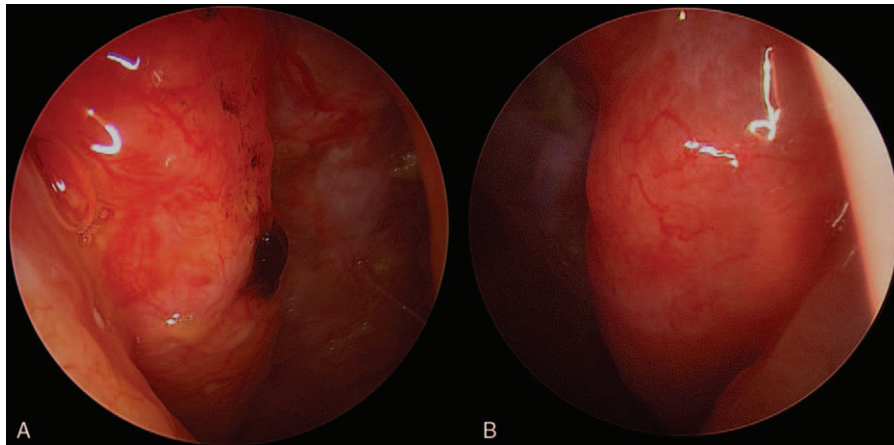
\* Correspondence: Sam Hyun Kwon, Department of Otolaryngology-Head and Neck Surgery, Chonbuk National University Medical School, Jeonju, Korea (e-mail: shkwon@jbnu.ac.kr).

Copyright © 2017 the Author(s). Published by Wolters Kluwer Health, Inc. This is an open access article distributed under the terms of the Creative Commons Attribution-Non Commercial License 4.0 (CCBY-NC), where it is permissible to download, share, remix, transform, and buildup the work provided it is properly cited. The work cannot be used commercially without permission from the journal.

Medicine (2017) 96:30(e7615)

Received: 14 February 2017 / Received in final form: 26 June 2017 / Accepted: 5 July 2017

<http://dx.doi.org/10.1097/MD.0000000000007615>



**Figure 1.** Smooth-surfaced exophytic masses with visible blood vessels on both torus tubarius were noted on endoscopy. (A) Right side, (B) left side. Note the blood clot in the right torus tubarius.

The patient was diagnosed as having localized nasopharyngeal amyloidosis. He underwent a myringotomy on the right side and was treated with prednisolone (0.3 mg/kg/day) and cefpodoxime (3 mg/kg/day) for 2 weeks and the symptoms subsided. The patient reported no further complaints at 1-year follow-up and the lesion from nasopharyngeal amyloidosis was still present.

The Ethical committee approval was acquired from the institutional ethical review board of Chonbuk National University Hospital, Korea (IRB number: 2016-01-018).

### 3. Discussion

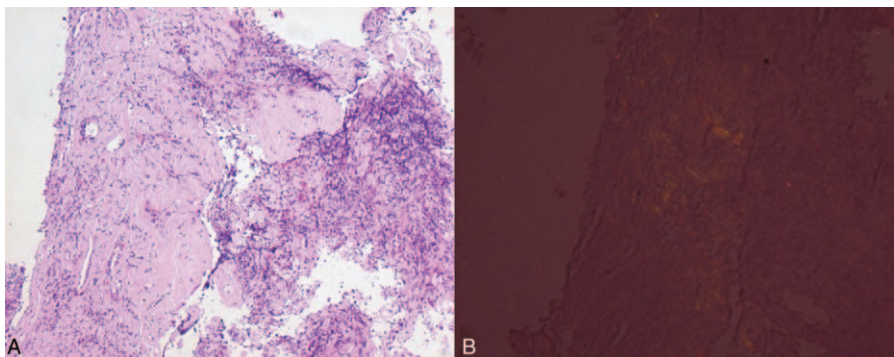
Localized amyloidosis is extremely rare, frequently involves the head and neck region without systemic manifestations, and has an excellent prognosis. The larynx is the most affected area (61%), followed by the oropharynx, trachea, orbit, and nasopharynx.<sup>[4]</sup> Nasopharyngeal amyloidosis has previously been described in the literature in 13 different patients, all of whom had localized amyloidosis.<sup>[5]</sup> Although it is usually asymptomatic, nasopharyngeal amyloidosis may cause epistaxis, aural fullness, middle ear effusion, and conductive hearing loss as in this case. Our patient had a representative endoscopic image of hematoma due to vessel wall invasion. This indicates the

importance of being alert to the major symptoms of nasopharyngeal amyloidosis; otherwise, it may be missed.

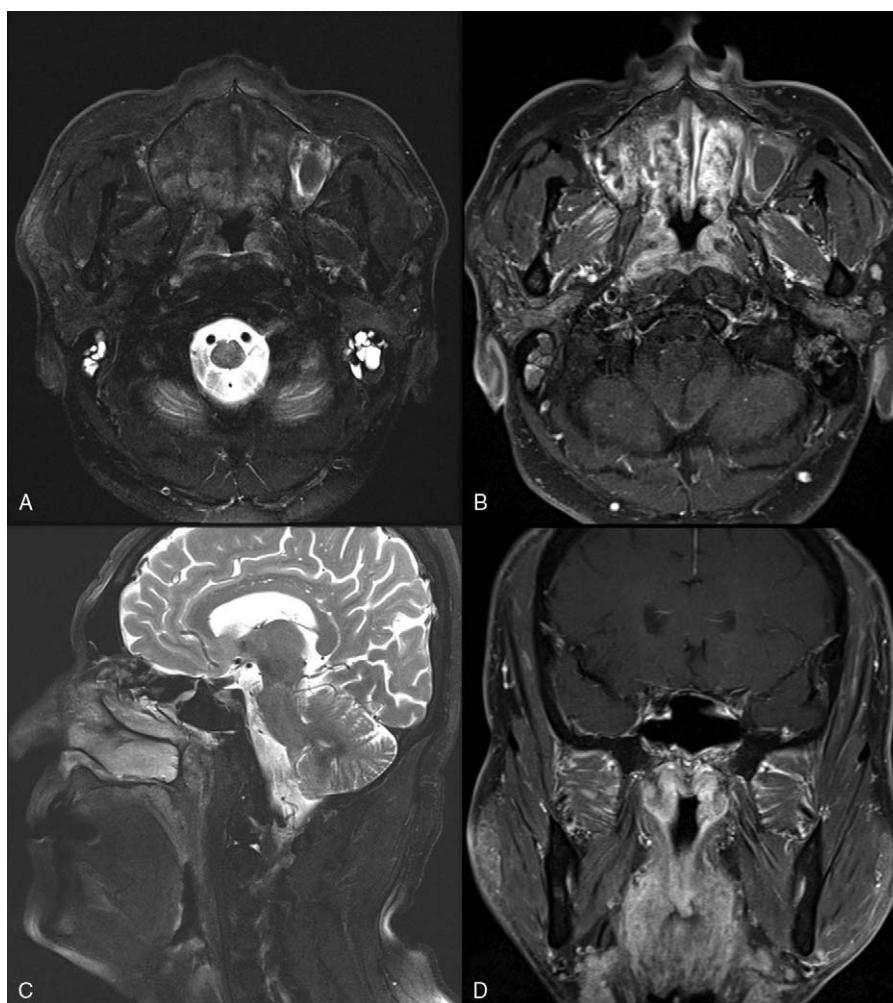
The differential diagnosis of nasopharyngeal amyloidosis includes nasopharyngeal carcinoma and lymphoma. The phenotypic examination is usually nonspecific; however, several authors have reported the appearance of nasopharyngeal amyloidosis. The endoscopic appearance of nasopharyngeal amyloidosis is of a heterogeneously reddish, smooth-surfaced exophytic tumor in the nasopharynx.<sup>[6]</sup> In our case, a smooth-surfaced exophytic mass with visible blood vessels on the torus tubarius was characteristically noted. A blood clot was also noted in the right torus tubarius, which was the cause of nasal bleeding.

The “gold standard” for the diagnosis of amyloidosis is a tissue biopsy. Histology of the biopsied specimen using hematoxylin and eosin staining shows amyloid as an extracellular, amorphous, acellular eosinophilic deposit, sparing the overlying epithelium. Congo red staining shows characteristic apple-green birefringence and dichroism under a polarized light microscope.<sup>[2]</sup> Staining with methyl violet or crystal violet reveals metachromatic pink-violet staining.<sup>[2]</sup> A negative result for abdominal fat and rectal biopsy is necessary for diagnosis of the localized form, not systemic amyloidosis.

There is no universally effective medical treatment for nasopharyngeal amyloidosis but surgery can be an option.<sup>[7]</sup>



**Figure 2.** (A) Hematoxylin and eosin staining showed deposits of amyloid under epithelial layers. (B) Amyloid demonstrating apple-green birefringence with polarized light after Congo red staining.



**Figure 3.** (A) Axial T2-weighted magnetic resonance imaging shows heterogeneous enhancement of the lesion in the nasopharynx. (B) Axial gadolinium-enhanced T1-weighted magnetic resonance imaging shows hyperintense, submucosal soft-tissue mass in the nasopharynx. (C) Sagittal T2-weighted magnetic resonance imaging shows heterogeneous enhancement of the lesion in the nasopharynx. (D) Coronal gadolinium-enhanced T1-weighted magnetic resonance imaging shows hyperintense, submucosal soft-tissue mass in the nasopharynx.

The surgical excision of nasopharyngeal amyloidosis is usually conservative, not radical, because relapse is common. Complete removal of nasopharyngeal amyloidosis can impair normal physiological functions. There have been no reports showing progression of localized form to systemic amyloidosis. In addition, a survival benefit from surgical excision of nasopharyngeal amyloidosis has not been demonstrated. For these reasons, careful observation with regular follow-up by nasopharyngoscopy and radiologic study is a reasonable therapeutic option, as in our case.<sup>[6]</sup>

#### 4. Conclusion

Although it is rare, nasopharyngeal amyloidosis should be considered in the differential diagnosis of epistaxis, nasal obstruction, and otitis media with effusion, which are the main symptoms of nasopharyngeal carcinoma. In the absence of

systemic disease, localized nasopharyngeal amyloidosis may be treated conservatively.

#### References

- [1] Kennedy TL, Patel NM. Surgical management of localized amyloidosis. *Laryngoscope* 2000;110:918–23.
- [2] Thompson LD, Derringer GA, Wenig BM. Amyloidosis of the larynx: a clinicopathologic study of 11 cases. *Mod Pathol* 2000;13:528–35.
- [3] Lachmann HJ, Goodman HJ, Gilbertson JA, et al. Natural history and outcome in systemic AA amyloidosis. *N Engl J Med* 2007;356:2361–71.
- [4] Glenner GG. Amyloid deposits and amyloidosis: the beta-fibrilloses. *N Engl J Med* 1980;302:1283–92. 1333–43.
- [5] Panda NK, Saravanan K, Purushotaman GP, et al. Localized amyloidosis masquerading as nasopharyngeal tumor: a review. *Am J Otolaryngol* 2007;28:208–11.
- [6] Chen YS, Li WY, Ho CY. Localized nasopharyngeal amyloidosis. *J Chin Med Assoc* 2010;73:549–52.
- [7] Sánchez Legaza E, Cervera Oliver C, Guerrero Cauqui R. Amyloidosis of the nasopharynx. *Acta Otorrinolaringol Esp* 2013;64:377–8.