

“Collateral Damage:” Horner’s Syndrome Following Excision of a Cervical Vagal Schwannoma

Abstract

Horner’s syndrome is characterized by triad of blepharoptosis, miosis, and anhidrosis on the lateral part of the face. Incidence of iatrogenic Horner syndrome resulting from neck surgeries has been reported between 10% to 18.5%. Iatrogenic Horner syndrome resulting from excision of cervical vagal nerve schwannoma is uncommon, and has rarely been mentioned in literature. We report a rare case of iatrogenic preganglionic Horner’s syndrome resulting from excision of a cervical vagal schwannoma. An 18 years old female presented with the complaints of sudden drooping of right upper lid associated with reduced sweating on right side of face for the past 3 months. There was history of excision of a right cervical vagal schwannoma. Ocular examination revealed mild ptosis, miosis with anisocoria more in scotopic illumination. Photographs of the patient prior to surgery showed no evidence of ptosis. Preoperative Magnetic resonance imaging revealed a mass suggesting a vagal nerve schwannoma. A diagnosis of iatrogenic preganglionic Horner’s syndrome was made and the patient was kept under follow up. Horner’s syndrome is an uncommon sequelae of cervical vagal schwannoma excision that results from injury of the cervical sympathetic chain intraoperatively and hence should be discussed with the patient during pre-operative counseling.

Keywords: Horner’s syndrome, ptosis, vagal schwannoma

Introduction

Horner’s syndrome or oculosympathetic paresis was first described by Johann Friedrich Horner in 1869.^[1] The syndrome is characterized by classical triad of blepharoptosis, miosis, and anhidrosis on the lateral part of the face. The syndrome results from disruption of the sympathetic innervation of the eye and ocular adnexa at different levels and thus is classified into central, preganglionic, and postganglionic syndrome.^[2]

Most common causes of preganglionic Horner’s syndrome are trauma and tumors.^[2] Cluster migraine^[3] and carotid artery dissection^[4] are the common causes for postganglionic Horner’s syndrome.

The incidence of iatrogenic Horner’s syndrome resulting from neck surgeries has been reported between 10% and 18.5%.^[5] Cervical surgeries that can result in iatrogenic Horner’s syndrome include thyroidectomy, coronary bypass surgery, carotid endarterectomy, spine surgery, and cervical or thoracoscopic sympathectomy.

This is an open access journal, and articles are distributed under the terms of the Creative Commons Attribution-NonCommercial-ShareAlike 4.0 License, which allows others to remix, tweak, and build upon the work non-commercially, as long as appropriate credit is given and the new creations are licensed under the identical terms.

For reprints contact: reprints@medknow.com

Iatrogenic Horner’s syndrome resulting from excision of cervical vagal nerve schwannoma is uncommon and has rarely been mentioned in literature.^[6] We report a rare case of iatrogenic preganglionic Horner’s syndrome resulting from excision of a cervical vagal schwannoma.

Case Report

An 18-year-old female presented with the complaints of sudden drooping of the right upper lid associated with reduced sweating on the right side of face for the past 3 months. There was history of undergoing surgery for excision of a right cervical vagal schwannoma within 3 months. General systemic examination was within normal limits. Best-corrected visual acuity was 20/20 in both eyes (OU). Ocular examination revealed mild ptosis in the right eye [Figure 1]. Marginal reflex distance 1 was 3 mm in the right eye and 4 mm in the left eye. Levator palpebrae superioris action was 15 mm in both eyes. Pupillary examination revealed miosis in the right eye with anisocoria more in scotopic illumination [Figure 2a and b]. There was no relative afferent pupillary

How to cite this article: Kumar KV, Alam MS. “Collateral damage:” Horner’s syndrome following excision of a cervical vagal schwannoma. *Int J App Basic Med Res* 2018;8:190-2.

**KV Praveen Kumar,
Md Shahid Alam¹**

*Department of Ophthalmology,
Narayana Medical College,
Nellore, Andhra Pradesh,
¹Department of Orbit and
Oculoplasty, Sankara Netralaya,
Chennai, Tamil Nadu, India*

Received: 26 November, 2016.
Accepted: 26 March, 2018

Address for correspondence:
Dr. KV Praveen Kumar,
Department of Ophthalmology,
Narayana Medical College,
Nellore, Andhra Pradesh, India.
E-mail: smilefriend84@
yahoo.com

Access this article online

Website:
www.ijabmr.org

DOI:
10.4103/ijabmr.IJABMR_439_16

Quick Response Code:



defect. Extraocular movements were full in all directions of gaze. Rest of the anterior segment examination in both eyes was unremarkable. Fundus examination in both eyes was normal. Cranial nerve examination was within normal limits. Photographs of the patient before surgery showed no evidence of ptosis. The presence of these clinical features suggested a preganglionic Horner's syndrome. Preoperative magnetic resonance imaging revealed a mass in the posterior aspect of the carotid sheath which displaced the carotid bulb, proximal internal carotid artery, and external carotid artery on the right side suggesting a vagal nerve schwannoma. However, anatomic localization of the vagus nerve could not be done on the available MRI images [Figure 3a and b]. Histopathological report available with the patient was suggestive of vagal schwannoma predominantly of Antony A type. A diagnosis of iatrogenic preganglionic Horner's syndrome was made, and the patient was lost to follow-up.

Discussion

Horner's syndrome results from the disruption of sympathetic supply to the eye. The sympathetic system supplying the eye originates in the hypothalamus and in its course travels through the neck in the form of cervical sympathetic trunk.^[7] The superior cervical sympathetic ganglia of the cervical sympathetic chain divides into two branches, with one branch supplying the dilator pupillae and Muller muscle of the eye and the other supplying the facial muscles.^[7] A disruption anywhere in this course can result in Horner's syndrome and has been classified as central, preganglionic, and postganglionic Horner's syndrome.

Cervical portion of vagus nerve lies in the carotid sheath between internal carotid artery and internal jugular vein. The cervical sympathetic chain lies medial to internal jugular vein.^[8] The cervical portion of vagus nerve does not lie in proximity to cervical sympathetic chain, so much so to cause an iatrogenic damage to the sympathetic chain, unless the tumor is quite big, which might be the case with our patient.

The onset of Horner's syndrome after cervical surgeries is rare.^[9] The most common injury to sympathetic chain during such surgeries is direct trauma, and the common sites involved are prevertebral fascia, paratracheal area, posteromedial area to the carotid sheath, and lung apex.^[9] A thorough review of literature showed isolated case reports of postoperative Horner's syndrome following excision of cervical schwannoma and paraganglionoma.^[10,11] Tomita *et al.* in their study of 9 patients of cervical sympathetic chain schwannomas reported postoperative Horner's syndrome in all the cases.^[12] Other rare complications resulting from injury to sympathetic chain during cervical surgeries include first-bite syndrome and Pourfour du Petit syndrome.

The common postoperative complications following excision of a vagal nerve schwannoma are injury to the nerve, hoarseness of voice, and vocal cord palsy.

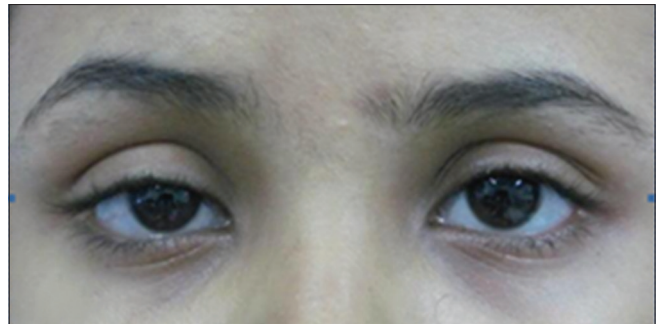

Figure 1: Clinical photograph showing mild ptosis in the right eye

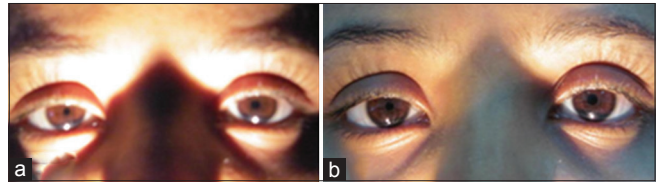


Figure 2: (a and b) Miosis in the right eye with anisocoria more in scotopic illumination

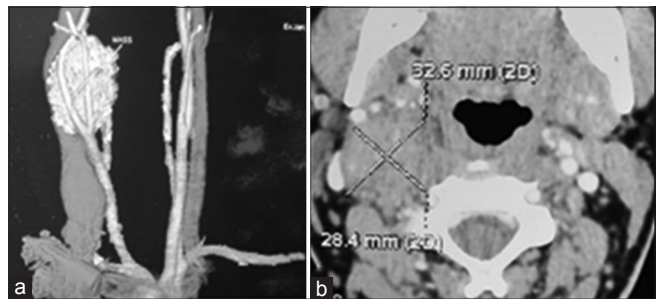


Figure 3: (a and b) Magnetic resonance imaging showing a mass in the posterior aspect of the carotid sheath displacing the carotid bulb, proximal internal carotid artery, and external carotid artery on the right side

In an extensive review on surgery for cervical vagal schwannomas by Cavallaro *et al.*, 25% of patients had no postoperative complications and 22.6% had postoperative hoarseness of voice. Horner's syndrome was reported as a rare complication.^[6]

Horner's syndrome following excision of a vagal schwannoma can occur due to direct injury to cervical sympathetic chain during excision or indirect injury due to traction on the sympathetic chain. Indirect injuries generally recover spontaneously over time, and Horner's syndrome also resolves. Direct transaction of sympathetic trunk is unlikely to recover.^[9]

We presume that injury to the carotid sheath during the excision for vagal schwannoma must have resulted in injury to the sympathetic chain leading to the development of postoperative Horner's syndrome in this patient. An abnormal anatomical relationship is another possibility which can cause such iatrogenic damage.

The postoperative neurological complications developing following excision of vagal schwannomas are usually

transient and in majority of the cases do not require specific management. Ptosis can be treated surgically if it does not improve spontaneously. Anisocoria usually does not produce symptoms in these patients. Surgical correction of ptosis can be done through slight advancement of the levator aponeurosis or resection of the conjunctiva and Müller's muscle.

We conclude that Horner's syndrome is an uncommon sequel of cervical vagal schwannoma excision that results from injury of the cervical sympathetic chain intraoperatively and hence should be discussed with the patient during preoperative counseling. A thorough knowledge of cervical sympathetic chain is essential to prevent the occurrence of this complication.

Declaration of patient consent

The authors certify that they have obtained all appropriate patient consent forms. In the form the patient(s) has/have given his/her/their consent for his/her/their images and other clinical information to be reported in the journal. The patients understand that their names and initials will not be published and due efforts will be made to conceal their identity, but anonymity cannot be guaranteed.

Financial support and sponsorship

Nil.

Conflicts of interest

There are no conflicts of interest.

References

1. Horner JF. Über eine form von ptosis. *Klin Monatsbl Augenheilk* 1869;7:193-8.
2. Maloney WF, Younge BR, Moyer NJ. Evaluation of the causes and accuracy of pharmacologic localization in Horner's syndrome. *Am J Ophthalmol* 1980;90:394-402.
3. Dodick DW, Saper J. Cluster and chronic daily headache. *Neurology* 2003;60:S31.
4. Flaherty PM, Flynn JM. Horner syndrome due to carotid dissection. *J Emerg Med* 2011;41:43-6.
5. Patel S, Ilsen PF. Acquired Horner's syndrome: Clinical review. *Optometry* 2003;74:245-56.
6. Cavallaro G, Pattaro G, Iorio O, Avallone M, Silecchia G. A literature review on surgery for cervical vagal schwannomas. *World J Surg Oncol* 2015;13:130.
7. Kardon R. Anatomy and physiology of the autonomic nervous system. In: Miller NR, Newman NJ, Bioussé V, Kerrison JB, editors. *Walsh and Hoyt Clinical Neuro-Ophthalmology*. 6th ed. Baltimore: Williams & Wilkins; 2005. p. 649.
8. Williams MA, McAvoy C, Sharkey JA. Horner's syndrome following attempted internal jugular venous cannulation. *Eye (Lond)* 2004;18:104-6.
9. González-Aguado R, Morales-Angulo C, Obeso-Agüera S, Longarela-Herrero Y, García-Zornoza R, Acle Cervera L, *et al.* Horner's syndrome after neck surgery. *Acta Otorrinolaringol Esp* 2012;63:299-302.
10. Clements DM, Hedges AR, Tudor GR. Horner's syndrome following excision of a vagal paraganglionoma. *Int J Clin Pract* 2002;56:626-7.
11. Bocciolini C, Dall'olio D, Cavazza S, Laudadio P. Schwannoma of cervical sympathetic chain: Assessment and management. *Acta Otorhinolaryngol Ital* 2005;25:191-4.
12. Tomita T, Ozawa H, Sakamoto K, Ogawa K, Kameyama K, Fujii M, *et al.* Diagnosis and management of cervical sympathetic chain schwannoma: A review of 9 cases. *Acta Otolaryngol* 2009;129:324-9.