

Available online at [www.sciencedirect.com](http://www.sciencedirect.com)

ScienceDirect

journal homepage: [www.elsevier.com/locate/radcr](http://www.elsevier.com/locate/radcr)

## Case Report

# Scalpel sign: Dorsal thoracic arachnoid web, thoracic arachnoid cyst and ventral cord herniation <sup>☆</sup>

Christopher Shane Buntting, MBBS<sup>a,\*</sup>, Yeji Ham, MD<sup>b</sup>, Ken X Teng, MD<sup>b</sup>, James Dimou, FRACS<sup>b</sup>, Andrew J Gauden, FRACS<sup>b</sup>, Girish Nair, FRACS<sup>b</sup>

<sup>a</sup>The Alfred Hospital, 55 Commercial Road, Melbourne, 3004, Victoria, Australia

<sup>b</sup>Royal Melbourne Hospital, 300 Grattan Street, Parkville, 3050, Victoria, Australia

## ARTICLE INFO

## Article history:

Received 13 March 2022

Revised 26 June 2022

Accepted 29 June 2022

## Keywords:

Scalpel sign

Cord compression

Ventral cord herniation

Arachnoid web

Arachnoid cyst

## ABSTRACT

The “Scalpel sign” is a radiological sign which can be identified on magnetic resonance imaging and indicates dorsal compression of the spinal cord [1]. Prior descriptions of a “Scalpel sign” have been reported in the literature and the awareness and identification of this pathognomonic sign may aid in the rapid diagnosis and treatment of patients with dorsal arachnoid web, dorsal arachnoid cyst or ventral cord herniation. We describe 3 cases which highlight these rare conditions for which this sign is pathognomonic and summarize the pertinent literature related to these disorders [1,2].

© 2022 The Authors. Published by Elsevier Inc. on behalf of University of Washington.

This is an open access article under the CC BY-NC-ND license (<http://creativecommons.org/licenses/by-nc-nd/4.0/>)

## Introduction

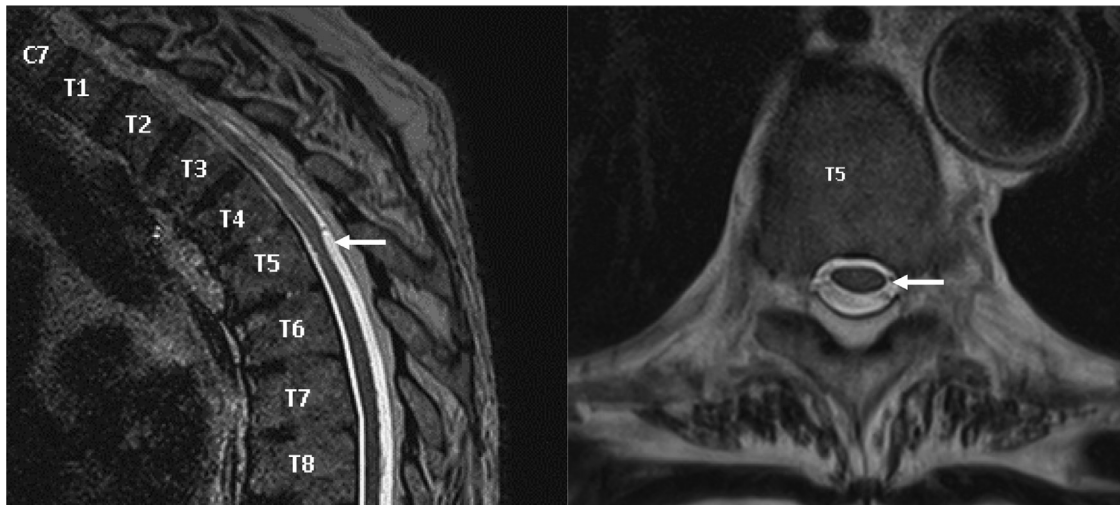
The “Scalpel sign” was first termed by Reardon et al, to describe the pathognomonic finding on imaging for several intradural extramedullary spinal pathologies in the absence of other obvious lesions such as tumor, hemorrhage or infection [1]. The “Scalpel” describes the anterior displacement of the thoracic cord creating a larger dorsal CSF space, ultimately creating the appearance of the sagittal profile of

a surgical scalpel. Dorsal thoracic arachnoid web, idiopathic ventral cord herniation and intradural spinal arachnoid cyst are conditions which can demonstrate these finding on MRI imaging [1–5]. The awareness and identification of these conditions early can spare patients prolonged suffering and help doctors refer their patients for treatment. This paper presents 3 cases which illustrate the pathologies associated with the scalpel sign and discuss the pertinent details related to these conditions for the clinician to quickly refer to as needed.

<sup>☆</sup> Competing Interests: All authors declare no conflict of interest.

\* Corresponding author.

E-mail address: [c.buntting@alfred.org.au](mailto:c.buntting@alfred.org.au) (C.S. Buntting).



**Fig. 1** – MRI-T2 weighted imaging with a sagittal view of the thoracic spine (Left), and an axial view at the level of the T5 vertebrae (Right). On the sagittal image behind the vertebral body of T5, note the indentation of the spinal cord displacing the spinal cord ventrally as indicated by the arrow. Note on the axial image on the right, the relative flattening of the spinal cord as indicated by the arrow. This was found at the time of surgery to be a dorsal thoracic arachnoid web.

## Case 1: Dorsal thoracic arachnoid web

### Case presentation

#### History and examination

The patient was an 80-year-old right-handed gentleman who was referred to our service with symptoms of progressive right lower limb weakness over a period of 2 years. He described an insidious onset of lower limb weakness that was not associated with trauma or symptoms to suggest an infective or systemic cause of his symptoms. The patient was previously independent in all activities but in recent months he had adopted a single point stick to aid with walking. The patient had a history of chronic back pain, benign paroxysmal positional vertigo, hypertension, and paroxysmal tachycardia. He had also undergone bilateral total hip arthroplasty's for osteoarthritis several years before.

On examination, the patient was observed to be dragging his right lower limb when walking. There was no evidence of fasciculation or muscular atrophy. His right lower limb was found to have increased tone and his power was 4/5 throughout all movements of his right lower limb. He had brisk reflexes in his right lower limb and altered sensation. Examination of his left leg was normal.

#### Investigations

The patient was initially seen by a Neurologist and underwent a battery of tests including an MRI of his whole neuroaxis. A MRI of the thoracic spine revealed a subtle indentation of the dorsal aspect of the spinal cord at the vertebral level of T5. He subsequently underwent a further MRI with high resolution T2 sequences which again demonstrated more obvious indentation of the dorsal spinal cord in the shape of a surgical Scalpel (Fig. 1).

#### Surgical intervention

The patient underwent a T4 to T6 thoracic laminectomy. After opening the dura, the surgical team observed a focal region of abnormal multilayered arachnoid strands arranged in a web-like pattern causing compression of the thoracic cord. Sharp dissection was conducted to incise the arachnoid web and decompress the spinal cord. Based on these findings an intraoperative diagnosis of dorsal thoracic arachnoid web was made.

#### Outcome and follow up

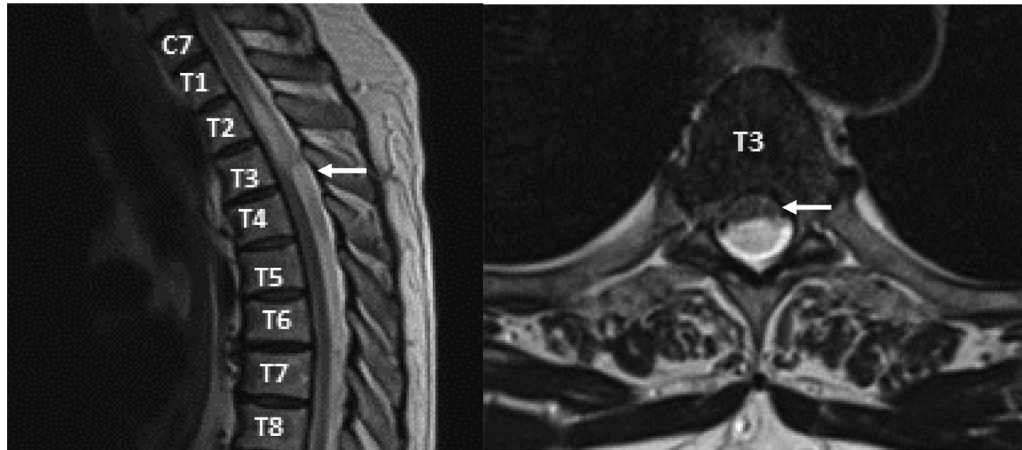At 6 weeks following his surgical intervention, the patient reported that he had symptomatically improved. On examination there was significant improvement of his gait and subjective sensory disturbance. The patient remained stable at four years of follow-up. An MRI conducted postoperatively demonstrated resolution of the "Scalpel" sign appearance of the thoracic spinal cord.

#### Discussion

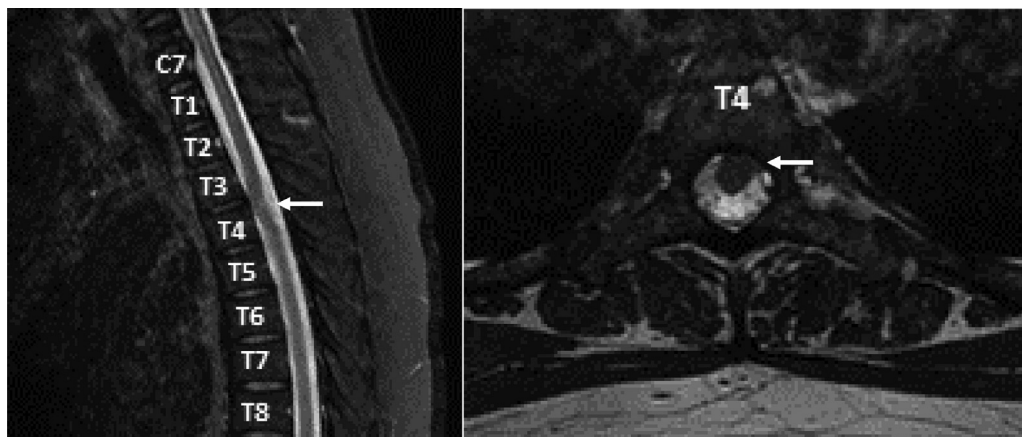
Dorsal thoracic arachnoid web is a disease entity of unknown etiology and incidence which can cause slow progressive weakness and myelopathy as well as sensory symptoms including pain and numbness. There is evidence, however, that the lesion may be completely asymptomatic and can be found incidentally on imaging of the spinal cord [6].

Other imaging findings which may be identifiable include the presence of transverse bands of arachnoid tissue extending to the dorsal surface of the spinal cord on high resolution T2 imaging. Although ventral displacement is visible on imaging, the arachnoid web itself is often not visible on MRI or CT myelogram imaging [1–5].

The arachnoid web itself is a thin intradural membrane over the dorsal aspect of the thoracic cord often causing compression and anterior displacement of the spinal cord. The



**Fig. 2** – MRI-T2 weighted imaging with a sagittal view of the thoracic spine (Left), and an axial view at the level between the T3 and T4 vertebrae (Right). On the sagittal image on the left, note the sharp indentation of the spinal cord ventrally (indicated by the arrow) with an associated syrinx superior to this. On the axial image on the right, note the significant ventral displacement and flattening of the spinal cord as indicated by the arrow. This is a clearer example of the “Scalpel Sign”. This patient was found at surgery to have a dorsal thoracic arachnoid cyst.



**Fig. 3** – MRI-T2 weighted imaging with a sagittal view of the thoracic spine (Left), and an axial view at the level between the T3 and T4 vertebrae (Right). On the sagittal image on the left note the ventral displacement of the spinal cord and the lack of CSF space between the spinal cord and vertebrae as indicated by the arrow. On the axial image on the right, note the herniation of the spinal cord and the lack of CSF (T2 hyperintense signal) between the cord and the T4 vertebral body as indicated by the arrow. This patient was found at the time of surgery to have a ventral cord herniation.

arachnoid web can also alter CSF flow dynamics by blocking flow through the central canal and can ultimately result in syringomyelia. Histological examination of surgically resected samples demonstrates meningeal tissue, connective tissue with some areas of calcification without any evidence of neoplastic cells [7–9].

The etiology of the dorsal thoracic arachnoid web is unclear, and several hypotheses have been developed to explain the pathogenesis of the disorder. One theory hypothesizes that arachnoid webs are precursors of developing arachnoid cysts or are the remnants of a ruptured arachnoid cyst [4,5,10,11]. Other theories include an etiology of congenital, post-traumatic, post infectious and iatrogenic nature. How-

ever, to date there is no known cause of this lesion nor why they are found in the thoracic region [4,5,10,11].

### Conclusion

Currently, there are no guidelines regarding the appropriate management of dorsal thoracic arachnoid web. In minimal or asymptomatic presentations there are reports of successful conservative management with regular clinical review with neurophysiological and imaging studies. In patients with weakness, progressive symptoms or symptoms that have failed conservative therapy, surgical intervention can be offered. In patients with dorsal thoracic arachnoid web an open

laminectomy and sharp dissection of the arachnoid web can relieve the compressive effect of this lesion on the thoracic spinal cord and improve symptoms in most patients [4].

---

## Case 2: Thoracic spinal arachnoid cyst

### Case presentation

#### History and examination

The patient was a 64-year-old male patient who was referred to our service from a peripheral hospital with symptoms of progressive thoracic region back pain and allodynia in his left hand. The symptoms had progressed over a period of 2 years and significantly limited patient's ability to perform the activities of daily living due to pain. The patient had a past medical history of chronic obstructive pulmonary disease as well as cataracts. He was a smoker and consumed alcohol occasionally. He was right handed and had previously worked as a carpenter.

On examination the patient was found to have normal tone, power and reflexes in his upper limbs and lower limbs. However, in the region of the T2/T3 dermatome he reported altered sensation to light touch. The patient also reported significant amounts of pain during the sensory component of the examination.

#### Investigations

The patient underwent MRI imaging of the whole neuro-axis which revealed an extensive syrinx from the region adjacent to vertebral bodies C2 to T4. At the vertebral body level of T3/4 there appeared to be a sharp indentation of the spinal cord from a dorsal position resembling a surgical scalpel. A differential diagnosis of spinal arachnoid cyst and arachnoid web causing compression were considered and the patient proceeded to surgical intervention.

#### Surgical intervention

The patient underwent a T3 to T5 laminectomy. Under microscopic guidance, a linear durotomy was performed and the capsule was firstly fenestrated and then dissected away from the thoracic spinal cord. Histopathology was also sent. On the basis of the intraoperative findings a diagnosis of an arachnoid cyst was obtained.

#### Outcome and follow up

Postoperatively the patient reported almost complete resolution of the symptoms of pain in his arms. His thoracic back pain had also improved significantly and the patient was discharged on the fifth day of admission. Histopathology revealed fibrous tissue and a cyst lining composed of bland flattened to cuboidal cells. The cells themselves had a meningotheial appearance. This overall was in keeping with an arachnoid cyst.

#### Discussion

Spinal arachnoid cysts are collections of CSF within an arachnoid membrane wall which can be ventral or dorsal to the spinal cord. In addition to their position relative to the

spinal cord, they can be extradural or intradural in location. The scalpel sign is associated with intradural thoracic spinal arachnoid cysts. Intradural thoracic spinal arachnoid cysts can be asymptomatic but may also present with features of myelopathy or a sensory disturbance. This condition when symptomatic typically presents in patients in their fifth decade of life and have a preponderance to be found in the thoracic region [12,13].

The pathogenesis of the disorder is still unknown although several theories suggesting both acquired and idiopathic causes have been suggested [12]. The cysts may be associated with inflammatory and infectious conditions, neural tube defects, trauma, and kyphotic deformities. Regardless there is a consensus regardless of event initiation that an anomaly in an arachnoid membrane occurs leading to the development of these cysts which have variable degree of communication with the surrounding CSF [12,13].

Imaging may reveal the 'Scalpel sign' or a subtle cystic structure containing fluid of different density compared to the surrounding cerebrospinal fluid. In contrast to thoracic arachnoid webs, spinal arachnoid cysts may be ventrally placed and can cause compression of the cord over a larger area rather than the more focal compression often found in dorsal thoracic web. However, it is difficult to differentiate between dorsal thoracic arachnoid web and dorsal spinal arachnoid cyst on imaging alone and the disease entity may only be revealed if surgery is required [1–5,12,13].

#### Conclusion

In symptomatic patients with dorsal spinal arachnoid cysts surgical intervention involving laminectomy and fenestration of these cysts or resection of the cyst wall may be offered. As mentioned, the nature of the compressive lesion may not be discovered until the time of surgery and treatment may have to be tailored to findings intraoperatively. Intradural cysts may recur and several strategies to reduce this risk including adjunctive shunting and expansile duraplasty may be utilized to help prevent this. The majority of patients achieve an excellent outcome although some patients may see no change in their symptoms [12,13].

---

## Case 3: Idiopathic ventral cord herniation

### Case presentation

#### History and examination

The patient was a 48-year-old female who presented to the Emergency Department reporting symptoms of back pain and difficulty walking. The symptoms had begun 2 months prior to her presentation had steadily progressed prompting her presentation. Examination revealed right-sided lower limb weakness in all movements; and reduced vibration sense and proprioception in the same limb. Her left lower limb examined completely normally. She had a partial right Brown-Sequard syndrome. The rest of her neurological examination was normal.

### Investigations

An MRI of her thoracic spine revealed anterior displacement of the thoracic spinal cord at the vertebral level of T3/T4. This appeared to protrude through the dura and was more left sided; and the herniated segment appeared to directly contact the T3/4 interspace and the T4 vertebral body. There was no associated syrinx or obvious cord edema.

### Surgical intervention

The patient was administered general anesthetic and a T3-T4 laminectomy was performed and a midline durotomy was conducted to expose the spinal cord. Arachnoid dissection and dissection of the denticulate ligaments were performed bilaterally to allow for very careful manipulation of the spinal cord. This allowed for visualization of the anterior dural defect which was craniocaudal in orientation. The herniated cord was released and decompressed through careful expansion of the dural defect and dissection of the arachnoid attachments. A Durepair patch was laid over the ventral dural defect and sutured, and this repair was supported with a fibrin sealant. The dorsal durotomy was closed with continuous sutures. A Valsalva maneuver was performed intraoperatively – using the mechanical ventilation settings to increase airway pressure for a brief period – to ensure no cerebrospinal fluid leak was present and this was successful. Based on the imaging and intraoperative findings, a diagnosis of ventral cord herniation was confirmed.

### Outcome and follow up

In the subsequent days of her inpatient stay her lower limb weakness improved and she was discharged after a 3-week period of rehabilitation. Unfortunately this initial improvement subsequently plateaued at her 4-month postoperative follow-up with MRI demonstrating anterior tethering of the cord at the site of the dural repair. Further operative management was thought to more likely result in harm rather than benefit and was not pursued after a discussion with the patient.

---

## Discussion

Idiopathic ventral cord herniation is a rare condition whereby the spinal cord herniates – usually antero-laterally – through a dural defect. The disorder can present at any age but most commonly between the fourth and fifth decade of life. Patients may be asymptomatic, but commonly patients present with insidious symptoms of myelopathy and a Brown-Sequard syndrome [2,14].

The pathogenesis of the disorder is thought to be related to congenital, traumatic, or inflammatory processes causing a defect in the dura. In their study, Bartel's et al performed a biopsy on a patient with idiopathic ventral cord herniation and found that the herniated tissue was not that of a functioning spinal cord [15–17]. Instead, glio-neuronal tissue proliferation was demonstrated indicating a developmental cause whereby a local collection of neural crest cells develop into non-functioning neural cells adjacent to the mesenchymal

cells of the meninges contributing to the appearance of a herniation or defect. Regardless of the cause of the dural defect it is thought that ongoing cerebrospinal fluid pressure changes force the cord through the defect over time ultimately resulting in symptoms in some patients [15–17].

On MRI or CT myelogram imaging the Scalpel sign may be observed. There are several differences which can help differentiate between ventral cord herniation and dorsal thoracic arachnoid web or dorsal spinal arachnoid cyst. As indicated by the pathogenesis, in Idiopathic ventral cord herniation there is no evidence of space between the dura and the spinal cord. Furthermore, in ventral cord herniation there is often evidence of distortion of the spinal cord at the site of herniation through the dura; and the herniated tissue may be abutting the adjacent vertebral column or even appear to herniate into it. This is in contrast to dorsal thoracic arachnoid cyst or web's where there is often evidence of space between the dura and spinal cord [15–17].

Surgical intervention for idiopathic ventral cord herniation aims to decrease the herniation, restore anatomy and prevent recurrence of the herniation through the defect. This most often involves a posterior approach with a laminectomy to expose normal cord above and below the defect. Ultrasound may be used to identify the site of the herniation prior to durotomy. The dentate ligament is then released either ipsilateral or bilaterally to allow for manipulation of the cord and approach of the dural defect and herniation. Direct release of the herniation is then performed, and closure of the dura conducted with a synthetic or autologous dural patch [15–18].

---

## Conclusion

There are no guidelines for the management of ventral cord herniation but in patient's where the disorder is identified and the patient is suffering from progressive or debilitating neurological findings, surgical intervention can be recommended [15–18]. However, surveillance and nonoperative management may be reasonable in patients with minimal or no symptoms; and in some cases it may appear that the herniation may disappear on future MRI imaging [19].

---

## Summary of learning points

The scalpel sign is a pathognomonic feature of dorsal thoracic arachnoid web but may be present in dorsal spinal arachnoid cyst and ventral cord herniation. It is important for radiologists and clinicians to recognize this sign early and formulate the associated diagnosis to avoid delays to definitive surgical management when indicated.

Dorsal thoracic arachnoid web is an intradural extramedullary lesion caused by strands of arachnoid tissue compressing the dorsal aspect of the thoracic spinal cord. The etiology of the condition is unclear and treatment involves laminectomy and incision of the arachnoid web.

Intradural spinal arachnoid cysts are CSF-filled arachnoid sacs with variable communication with the surrounding CSF

space. Their treatment involves laminectomy and resection or fenestration of the cyst.

Ventral cord herniation is a rare condition characterized by a dural defect and herniation of the spinal cord through this defect. Treatment involves release of the herniation and closure of the dural defect via a laminectomy; although monitoring patients may also be considered.

## Patient consent

The patients involved in the study have signed informed consent and have authorized the use of aspects of their cases and imaging for research and educational purposes. Consent was obtained from all patients involved in this study and a record of this consent is kept with the authors and where possible has been documented in the electronic records of the patient's concerned. All patients have been de-identified in the paper presented.

## REFERENCES

- [1] Reardon MA, Raghavan P, Carpenter-Bailey K, Mukherjee S, Smith JS, Matsumoto JA, et al. Dorsal thoracic arachnoid web and the “scalpel sign”: a distinct clinical-radiologic entity. *Am J Neuroradiol* 2013;34:1104–10.
- [2] Schultz R Jr, Steven A, Wessell A, Fischbein N, Sansur CA, Gandhi D, et al. Differentiation of idiopathic spinal cord herniation from dorsal arachnoid webs on MRI and CT myelography. *J Neurosurg Spine* 2017;26:754–9.
- [3] Ruschel LG, Agnoletto GJ, Aurich LA, Vosgerau RP. Dorsal arachnoid web and scalpel sign: a diagnostic imaging entity. *Turkish Neurosurg* 2018;28(4):689–90.
- [4] Nisson PL, Hussain I, Hartl R, Kim S, Baaj AA. Arachnoid web of the spine: a systematic literature review. *J Neurosurg Spine* 2019;31:175–84.
- [5] Ben Ali H, Hamilton P, Zygmunt S, Yakoub KM. Spinal arachnoid web—a review article. *J Spine Surg* 2018;4:446–50.
- [6] Lee JY, Lee JW, Lee GY, Kang HS. Focal anterior displacement of the thoracic spinal cord without evidence of spinal cord herniation or an intradural mass. *Korean J Radiol* 2014;15:733–8.
- [7] Brodbelt AR, Stoodley MA. Syringomyelia and the arachnoid web. *Acta Neurochir (Wien)* 2003;145:707–11.
- [8] Sridharan A, Heilman CB. Transverse dorsal arachnoid web and syringomyelia: case report. *Neurosurgery* 2009;65:E216–17.
- [9] Sayal PP, Zafar A, Carroll TA. Syringomyelia secondary to “occult” dorsal arachnoid webs: report of two cases with review of literature. *J Craniocerv Junct Spine* 2016;7:101–4.
- [10] Paramore CG. Dorsal arachnoid web with spinal cord compression: variant of an arachnoid cyst? Report of two cases. *J Neurosurg Spine* 2000;93:287–90.
- [11] Enis DK, Jones JJ, Maartens N. Unusual case of progressive myelopathy. *J Clin Neurosci* 2018;49:89–90.
- [12] French H, Somasundaram A, Biggs M, Parkinson J, Allan R, Ball J, et al. Idiopathic intradural dorsal thoracic arachnoid cysts: a case series and review of the literature. *J Clin Neurosci* 2017;40:147–52.
- [13] Wang MY, Levi ADO, Green BA. Intradural spinal arachnoid cysts in adults. *Surg Neurol Int* 2003;60:49–56.
- [14] Sharma P, Elbanan M, Kochar P. Understanding idiopathic spinal cord herniation – a comprehensive review of imaging and literature. *J Clin Imaging Sci* 2019;9:22.
- [15] Bartels RHMA, Kusters B, Brunner H, Hosman AJF, Alfen NV, Grotenhuis JA. Pathogenesis of idiopathic ventral herniation of spinal cord. *Neuropathol Analysis* 2018;114:31–3.
- [16] Summers JC, Balasubramani YV, Chan PCH, Rosenfeld JV. Idiopathic spinal cord herniation: clinical review and report of three cases. *Asian J Neurosurg* 2013;8(2):97–105.
- [17] Ghali MGZ, Srinivasan VM, Rao VY, Omeis I. Idiopathic thoracic spinal cord herniation. *J Clin Neurosci* 2018;51:1–5.
- [18] Payer M, Zumsteg D, Tribolet ND, Wetzel S. Surgical management of thoracic idiopathic spinal cord herniation. Technical case report and review. *Acta Neurochir (Wien)* 2016;158:1579–82.
- [19] Samuel N, Goldstein CL, Santaguida C, Fehlings MG. Spontaneous resolution of idiopathic thoracic spinal cord herniation: case report. *J Neurosurg Spine* 2015;23(3):306–8.