

Efficacy of directly observed treatment short-course intermittent regimen in spinal tuberculosis

Rejith Valsalan, Rajesh Purushothaman, Raveendran MK, Balaji Zacharia, Sibin Surendran

ABSTRACT

Background: Most important cause of treatment failure and emergence of drug resistance in the treatment of tuberculosis is noncompliance. Compliance can be improved by direct observation of drug intake, intermittent therapy, and short-course treatment. The efficacy of Directly Observed Treatment Short Course (DOTS) strategy advocated by World Health Organization (WHO) in spinal tuberculosis is not yet proven. We conducted a prospective clinical study on a consecutive series of patients with spinal tuberculosis treated by Category I Revised National Tuberculosis Control Programme (RNTCP) regimen based on DOTS strategy of WHO from 2004 to 2007 to evaluate the efficacy.

Materials and Methods: Forty-nine consecutive patients of spinal tuberculosis were treated with short-course intermittent chemotherapy under Category I RNTCP/DOTS strategy. Patients were followed up for a minimum period of 2 years. Surgery was done if the patient presented with significant neurologic deficit or when the drug treatment failed. Outcome was assessed by clinical, radiologic, and laboratory criteria, and graded into excellent, good, fair, and poor based on various parameters.

Results: 63.4% ($n=26$) of the patients had excellent results. 14.6% ($n=6$) of the patients had good and fair results. Three patients (7.3%) had poor results 48.7% ($n=20$) of the patients had but only one of them was severe enough to warrant change of drug.

Conclusions: Efficacy of DOTS was comparable with other standard regimens. There was a significant reduction in adverse side effects when compared with daily regimens. Study showed that the outcome was better in those treated early.

Key words: Directly observed treatment, short-course chemotherapy, tuberculosis spine

INTRODUCTION

The management of spinal tuberculosis has evolved through various eras of management, from drugs alone, radical surgery combined with drugs, to the current era of drug treatment in majority of patients with surgery limited to those with specific indications.¹ Surgery is indicated in presence of complications such as failure of treatment, significant or worsening neurological deficit, kyphosis, and abscess.^{2,3} Modern antituberculous drugs have accelerated the rate and quality of recovery and have minimized the incidence of mortality, complications, and relapse.^{4,5} Depending on the combination and number

of drugs, duration of treatment, and frequency of drug administration, there are a number of treatment regimens available.⁶⁻⁹

Despite the availability of effective drugs, the outcome of treatment was unpredictable and had little epidemiological impact on the incidence of tuberculosis, mainly due to noncompliance with treatment.¹⁰ Noncompliance resulted in the treatment failure, emergence of drug resistance, and spread of disease. At present, World Health Organization recommends Directly Observed Treatment Short Course (DOTS regimen) for all cases of both pulmonary and extrapulmonary tuberculosis.¹¹ The DOTS strategy is based on intermittent drug intake and short-course therapy, and it also includes tenets such as political commitment, good management practices, and the direct observation of doses to ensure compliance. To date, DOTS remains the keystone of global efforts at tuberculosis control.^{12,13} However, there are no published data on the effectiveness of DOTS regimen in spinal tuberculosis.

This study assesses the effectiveness of DOTS regimen in spinal tuberculosis, the frequency and type of side effects, and the effect of the regimen in the various stages of the disease.

Department of Orthopaedics, Medical College, Calicut, Kerala, India

Address for correspondence: Dr. Rejith Valsalan,
Sree Valsam P.O. Chalad, Kannur - 670 014, Kerala, India.
E-mail: drrejith@gmail.com

Access this article online	
Quick Response Code:	Website: www.ijoonline.com
	DOI: 10.4103/0019-5413.93673

MATERIALS AND METHODS

Forty nine consecutive cases of spinal tuberculosis were treated with DOTS regimen from June 2004 to January 2007. A case of spinal tuberculosis was diagnosed in the presence of the following criteria:

The clinical features like persistent localized back pain, constitutional symptoms such as loss of weight, loss of appetite and evening rise of temperature, physical signs like localized tenderness, reduced range of movement, cold abscess, spinal deformity, and laboratory findings like raised erythrocyte sedimentation rate (ESR) and raised C reactive protein.

The X-ray features include regional osteopenia, fussy disc margins reduction/obliteration of the disc space, loss of anterior vertebral body height and kyphotic deformity with paravertebral shadow [Figure 1]. CT was undertaken when a CT-guided biopsy was taken.

Positive bacteriological findings by either culture or positive real-time polymerase chain reaction (RTPCR) for *Mycobacterium tuberculosis* in the aspirated sample from the lesion.

Patients above the age of 15 years with histopathological evidence of spinal TB or strong clinoradiological evidence of tuberculosis with no gross muscle weakness (MRC grade 3 or more) or severe kyphosis with a minimum followup of 2 years was included in the study. Patients who ceased treatment before 6 months or those in whom surgical decompressions were done or human immunodeficiency virus (HIV) positive were excluded.

Patients who were suspected to have spinal tuberculosis were investigated by blood investigations, X-rays, Magnetic Resonance Imaging, percutaneous CT-guided needle biopsy for culture, histopathology, and RTPCR for *M. tuberculosis* as required. X-ray and Magnetic Resonance Imaging findings were noted. All patients were screened for HIV and were found

to be negative. Every effort was made to get tissue diagnosis. Of the 49 patients, CT-guided tissue sample was taken for biopsy, culture and RT-PCR in 40 patients, 32 patients had histopathological or bacteriological confirmation, and eight had inconclusive evidence such as scanty aspirate or blood only. All patients were given DOTS therapy after liver function tests (LFT) and an ophthalmological evaluation. All the drugs were given free of cost and drug quality was assured by the concerned health bodies under Revised National Tuberculosis Control Programme (RNTCP) of Government of India. Patients were treated as inpatients during the initial 2 to 3 days of treatment, in order to watch for any adverse drug reaction. Once the patient was tolerating the treatment well, patients were discharged and sent to the nearest DOTS provider. Patients who were ambulatory at the time of diagnosis were kept ambulatory during treatment with spinal brace, with restriction of heavy and load-bearing activities. All patients with spinal tuberculosis were treated by Category I DOTS regimen used for seriously ill extrapulmonary disease. This consisted of four drugs (INH, Rifampicin, Ethambutol, and Pyrazinamide) administered under direct observation by a trained personnel, three times a week for two months, followed by two drugs (INH and Rifampicin), thrice weekly for seven months or until regression of symptoms along with laboratory and radiological signs of resolution, whichever was later.¹⁴ Laboratory signs of healing include return of ESR to normal and correction of lymphocytosis. Radiological signs of healing includes, return to normal bone density and sclerosis and reduction in paravertebral soft tissue shadow in X-ray, and regression of pathological soft tissue swelling on magnetic resonance imaging.¹⁵ Compliance was ensured using frequent field visits, random checking, quality assessment protocols, and modern management principles by RNTCP personnel.

Patients were asked to come for followup to our department every month for two months and then once in two months till the treatment is completed. During each followup

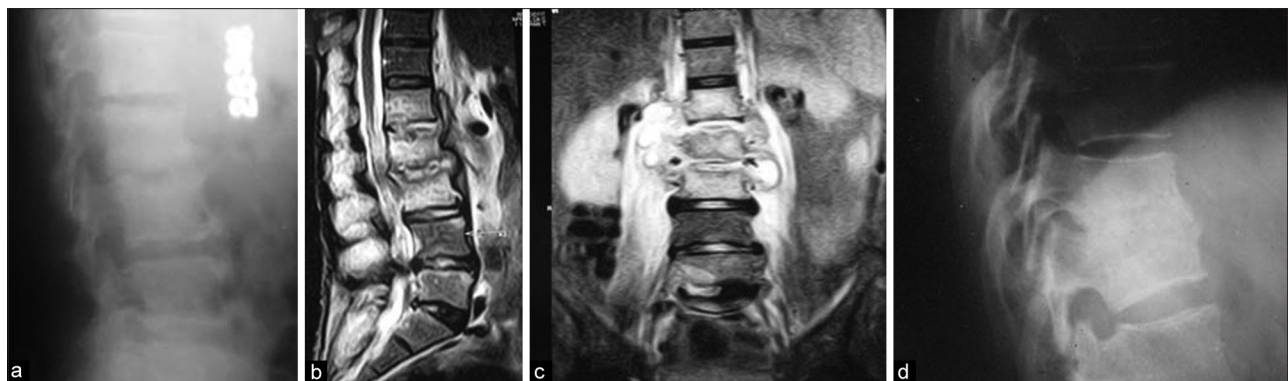


Figure 1: (a) X-ray lumbar spine lateral view at presentation showing narrowing of L3/4 disc space with end plate erosion. (b and c) T2W MRI mid sagittal and coronal views showing hyperintense/contrast enhancement suggestive of edema/inflammation involving bodies of L1, L2, L3 with end plate irregularities and disc space narrowing at L2-L3. There is hyper intense/contrast enhanced para vertebral abscess/soft tissue component extending from L1 to L3 level. The para spinal muscles are edematous (d) the same patient after 9 months of DOTS showing healing with bony fusion

visit, physical and neurologic examination findings were recorded, complete blood counts with ESR and LFT were monitored and followup X-rays were taken. Ophthalmology consultation was done at the beginning of treatment and on first followup to rule out optic neuropathy due to Ethambutol. If there was no positive response in clinical, radiological, and laboratory parameters after 12-16 weeks of treatment or if there is worsening during this period, then patients were suspected to be clinically resistant to first-line antituberculous drugs or having compressive lesion and were subjected to anterior decompression and instrumentation along with AFB culture and sensitivity of the specimen. If found to be resistant to primary-line drugs, additional drugs were started, as per DOTS protocol, consisting of Streptomycin + Isonicotinyl Hydrazine + Rifampicin + Ethambutol + Pyrazinamide + Moxifloxacin + cycloserine, pending culture and sensitivity results.¹⁶ Second line drugs for drug-resistant tuberculosis include Kanamycin, Ciprofloxacin, Sparfloxacin, Ethionamide, etc.¹⁷ However, none of the patients in this study was found to have drug resistance.

In case of drug intolerance like persistent allergic rash, rising increase in liver enzyme levels drug therapy was altered as per the advice of the pulmonologist, this was done by stopping all the drugs for 2 to 3 days, then introducing one drug at a time over the next 10 to 15 days while keeping the patient admitted and monitoring the patient clinically and by LFT. If the neurological deficit progressed, the patients were subjected for a surgical decompression. On completion of 9 months of anti tuberculous therapy (ATT), if the patient is relieved of pain and other symptoms, ESR was back to normal, and imaging studies showed signs of healing, then treatment was stopped. Patients were followed up once in every three months after successful completion of ATT. Final outcome was graded so that there was a minimum of 2-year followup. So, there was at least 12- to 15-month gap after completion of ATT when outcome was assessed.

However, if the patient is having persistent pain, elevated ESR, progression of neurological deficit, increase in size of the abscess, or progression of kyphosis, the treatment was continued and surgical intervention by anterior decompression and instrumentation was done.

Outcome measures

In patients with neurological deficits, neurological grading based on the MRC grading was assessed in detail. A radiological staging of the disease was done based on the Table 1.⁵

The radiological assessment was done by four independent observers (two radiologists and two orthopedic surgeons) in order to avoid bias.

While grading the final outcome, the following criteria were taken into consideration:¹⁵

1. Clinical evidence of healing evaluated by relief of symptoms, marked reduction in pain, increase in physical endurance,¹⁸ and decreased ESR.
2. Radiological signs of healing by means of X-ray, i.e., cessation of bone destruction, appearance of the normal trabecular pattern, correction of osteopenia, bone block or bony ankylosis, and regression in the size of the abscess were assessed [Figure 2].¹⁴
3. Completion of DOTS therapy without fail for at least 9 months.
4. Frequency and nature of adverse drug reactions.
5. Severe progression of kyphosis (>30 degree from beginning the treatment) at affected level at the end of treatment/severe side effects that forced to discontinue treatment.
6. Failure of treatment by nine months, like patient having persistent pain, elevated ESR, progression of neurological deficit, increase in size of the abscess, or progression of kyphosis, necessitating continuation beyond 9 months/addition of drugs.

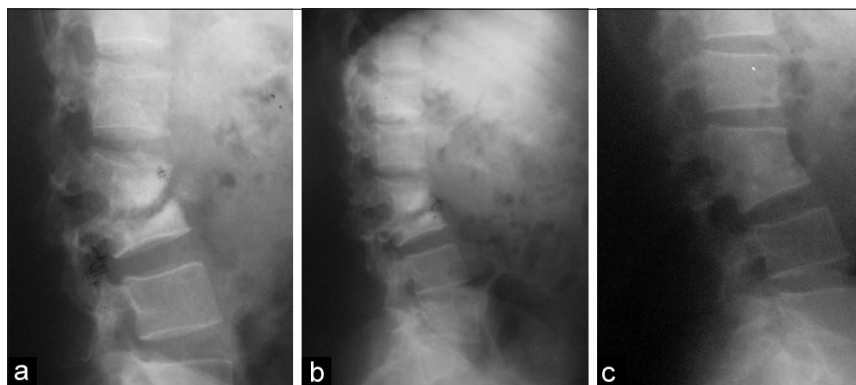


Figure 2: Sequential series of X-rays in a 50 year old female with thoracolumbar TB (a) at presentation, (b) at 4 months and at 10 months, (c) showing the destruction of the joint space and erosion of the endplates initially followed by bony fusion and bone block formation by around 9 months of DOTS. This patient had an atypical sclerotic appearance, however the diagnosis was confirmed by a CT guided biopsy

Table 1: Staging of TB spine

Stage	Clinicoradiologic features
I. Predestructive	Straightening of curvatures, spasm of paravertebral muscles, magnetic resonance imagingmagnetic resonance imaging shows marrow edema
II. Early destructive	Diminished disc space + Paradiscal erosion ('Knuckle' < 10°) magnetic resonance imaging shows marrow edema and break of osseous margins, computerised tomography scan shows marginal erosions or cavitations
III. Mild angular kyphosis	2-3 vertebrae involved (Kyphosis: 10°-30°)
VI. Moderate angular kyphosis	>3 vertebrae involved (Kyphosis: 30°-60°)
V. Severe kyphosis	>3 vertebrae involved (Kyphosis: >60°)

In stage III, IV, V diagnosis is clear on conventional X-rays. computerised tomography scan and magnetic resonance imaging would show advanced changes; however, these are unnecessary except for difficult sites

7. Failure of nonoperative treatment and/or progression of neurological deficit requiring surgical intervention.

On this basis, results were classified into the following four groups:¹⁴

Excellent result: Complete resolution of disease with DOTS regimen for 9 months, with no residual disability or deformity and absent or minor adverse drug reactions.

Good result: Complete resolution of disease with DOTS regimen for 9 months with no residual disability or deformity and with the occurrence of medically manageable side effects of drug therapy, such as gastrointestinal intolerance, drug-induced jaundice, etc.

Fair result: Complete resolution of disease, but with a post-treatment kyphosis deformity of 30 degrees or more at the affected level or the patients had to be shifted to second line drugs, or patients who are having mild residual pain which is however not limiting their physical activity.

Poor result: Cases that did not respond to conservative treatment, primary or secondary line, had a deteriorating neurological deficit and had to be operated.

RESULTS

Forty nine consecutive patients with spinal tuberculosis were treated by DOTS. Of them, 41 patients satisfied the inclusion criteria and were included in the study. Eight were excluded due to, lost of followup ($n=3$), expired ($n=2$) and discontinuation of ATT ($n=3$) by patients, one during the treatment due to myocardial infarction unrelated to the treatment and the other one after successful completion of the treatment due to unrelated cause. There were 22 males and 19 females with an average age of 41.1 years (range 15 to 72 years). Most of the patients (22%, $n=9$) belonged to the 21 to 30 years age group. 87.8% ($n=36$)

of the patients presented with localized backache. Motor weakness was seen in 29.3% ($n=12$) of the cases. The mean duration of the symptoms was 3.2 months (SD = 5.29) with a maximum of 2 years and a minimum of 2 weeks. The average ESR at the beginning of the treatment was 91.1 (SD = 18.07) with a maximum ESR of 120 and a minimum of 44. The fall in ESR was not so marked in the initial 1 month but it fell steeply in the next few months and stabilized by around 4 to 6 months.

The thoracic spine was involved in 29.3% ($n=12$), thoracolumbar junction in 24.4% ($n=10$), the lumbar and sacral vertebrae involved in 46.3% ($n=19$). Eight patients (19.5%) showed magnetic resonance imaging changes suggestive of predestructive lesion. However, the majority 43.9% ($n=18$) were in the early destructive phase. Twelve patients (29.3%) showed mild angular kyphosis with 2 to 3 vertebral involvement. Three patients (7.3%) had moderate angular kyphosis with >3 vertebral involvement. None had severe kyphosis. The angle of kyphosis ranged from 12° to 34°. The mean angle of progression of kyphosis at the site was less than 8° at the site of kyphosis. Only one patient had progression to greater than 40°; however, there was no neurological deficit. Five patients were found to have psoas abscess. Four of the abscesses regressed at 4th month without any intervention. One patient had the abscess drained in the third month. However, continued short-course chemotherapy was successful in this patient.

48.7% ($n=20$) of the patients had adverse drug reactions like nausea, skin rashes, and abdominal discomfort but only one of them was severe enough to warrant change of drug. 12.2% ($n=5$) of the patients had gastric disturbances like vomiting and abdominal discomfort, which was relieved by antacids and H₂ antagonists. Another 12.2% ($n=5$) had marginally elevated liver enzymes, of which only one patient was symptomatic (2.5%). 7.3% ($n=3$) had arthralgias. Another 7.3% ($n=3$) of patients had generalized itching which gradually subsided. One patient developed severe hypersensitivity to pyrazinamide and had to be substituted with second line drugs as per the pulmonologist's advice.

63.4% ($n=26$) of the patients had excellent results. 14.6% ($n=6$) of the patients had good results. Another 14.6% ($n=6$) had fair results. Three patients had poor results forming 7.3% of the study group. Of the three with poor results, two patients had no improvement even after further 2 months of intermittent short-course chemotherapy and had to undergo surgical decompression after which they improved with the continuation of DOTS regimen. The third patient was a 58-year-old male with T11/12 spinal

tuberculosis with grade III power in lower limbs, whose neural deficit improved on non operative treatment; however, he did not have complete symptomatic relief at 9 months. Continuation of DOTS for another 3 months leads to clinical improvement. The results depending on the stage of disease are given in Table 2. There was no significant difference between the outcomes depending on the different level of involvement. The clinical outcome was irrespective of the number of vertebral involvement or the level of involvement. After creating a 2 × 2 table with predestructive and early destructive groups as early presenters and the rest as late presenters, and also combining excellent and good as favorable outcome and fair and poor as unfavorable response, a Fishers 2-tailed exact test was done [Table 3].

The two-tailed *P* value equals 0.0031. The association between the groups and outcome is considered to be vary statistically significant. Patients diagnosed in the predestructive stage had excellent results in 87.5% of the cases, whereas in early destructive phase, it decreased to about 72.2%, in mild angular kyphosis to 50%, and none in the moderate angular kyphosis. None of our cases had severe angular kyphosis. The *P* value equals 0.0031, which implies that there is a significant association between stage of the disease at the time of the treatment and the outcome.

DISCUSSION

The effectiveness of DOTS regimen in pulmonary and nonskeletal forms of extrapulmonary tuberculosis is well established.¹⁹ But its role in spinal tuberculosis is not yet established.

Antituberculous chemotherapy is very effective in a compliant patient. The failure of treatment and emergence of drug resistance is due to non compliance which can only be overcome by establishing a human bond between the patient and the provider through DOT. In the developing world, evidence from uncontrolled studies shows that the introduction of DOTS has increased completion of therapy and cure rates from 25–50% (with unsupervised treatment) to 80–90%, with relapse rates of less than 5%.^{20,21} The daily regimen has shown 7% of hepatotoxicity and about 46% of severe arthralgias,²² the incidence of these side effects with DOTS intermittent short-course chemotherapy in this study was hepatotoxicity in less than 2.5% and arthralgia in 7.3% only, and intermittent therapy is as effective as daily therapy.²³⁻²⁵

In vitro studies have shown that drugs given thrice a week were as effective as those given daily.²⁴ These experiments

Table 2: Outcome of DOTS in various stages of spinal tuberculosis

	Excellent (%)	Good (%)	Fair (%)	Poor (%)
Predestructive (n=8)	87.5 (7)	12.5 (1)	-	-
Early destructive (n=18)	72.2 (13)	16.6 (3)	11.1 (2)	-
Mild angular kyphosis (n=12)	50 (6)	16.6 (2)	16.6 (2)	16.6 (2)
Moderate angular kyphosis (n=3)	-	-	66.6 (2)	33.3 (1)

Table 3: 2 × 2 tables for outcome depending on stage of the disease

	Favorable response	Non-favorable response
Early diagnosis	24	2
Late diagnosis	8	7

demonstrate that when a culture of *M. tuberculosis* is exposed to a single dose of antituberculosis drugs, there is a delay of several days (24-48 hrs)—the so-called “lag period”—before renewed growth of the bacteria occurs. All antituberculosis drugs, with the exception of Thioacetazone, exhibit this lag phenomenon and are therefore suitable for intermittent administration. Studies at Tuberculosis Research Centre (TRC), Chennai, India, have shown that twice-weekly regimen was as effective as the daily-unsupervised regimen.^{26,27} This forms the rationale of the usage of the thrice weekly regimens recommended in the RNTCP. Hence, intermittent regimen has the advantage of being less toxic, less costly²⁸ requiring fewer visits by patients, and is logistically more feasible.

Despite all the above mentioned advantages of DOTS regimen, many orthopedic surgeons continue to give daily regimens. This is basically due to the fact that the efficacy of short-course intermittent therapy like DOTS regimen is not scientifically proven.

Recommendations for surgery in cases with neurological deficit remains ill defined. Nussbaum *et al.* stated that “No patient with neurological deficit recovered or stabilized with non-operative management.”²⁹ Moon, on the other hand, recommended that only advanced neurological deficit, such as paraplegia, is a surgical indication in this disease.³ In this study, surgical indications were based on the study conducted by Nene and Bhojraj,¹⁴ where presentations with paraplegia, gross motor weakness (MRC Grade 2 or less), or neurologic deterioration while on treatment were absolute indications for surgical intervention. In our series, 12 patients presented with varying motor deficits, and 10 of these recovered completely with medical treatment alone, without the need for surgical decompression. When the outcome was compared with the short-course regimen given in that study, there was no significant difference in the outcome suggesting the comparable efficacy of the

intermittent regimen *vs* daily regimen.¹⁴ It is evident from the above data that earlier the initiation of the treatment, the better is the result. If the treatment is started during the predestructive or early destructive stages, the results are excellent or good; however, in the later stages of kyphosis with involvement of more vertebrae, the results start becoming fair or poor. The destroyed tissues can never attain the pre-disease level once they are destroyed; this explains the better results in those patients treated in the early stages of the disease. This is in accordance with the study conducted at TRC in 1997 by Rajeshwari *et al.* which showed the significance of early detection of cases in obtaining better results.²³

Limitation of the study is that sample size is small, most of the cases were in the early stages of tuberculosis and only a small number of cases had moderate disease hence it is unclear whether DOTS is useful in advanced stages of disease. Another limitation is that patients with significant neurologic deficit or deformity were excluded from the study.

CONCLUSION

DOTS strategy is as effective as short-course daily regimen in early stages of disease. Clinical outcome of treatment depends on the amount of destruction at the commencement of chemotherapy, with excellent results in the predestructive and early destructive phases of disease.

REFERENCES

1. Tuli SM. Tuberculosis of the spine: A historical review. *Clin Orthop Relat Res* 2007;460:29-38.
2. Bhojraj S, Nene A. Lumbar and lumbosacral tuberculous spondylodiscitis in adults. Redefining the indications for surgery. *J Bone Joint Surg Br* 2002;84:530-4.
3. Moon MS. Tuberculosis of the spine. Controversies and a new challenge. *Spine (Phila Pa 1976)* 1997;22:1791-7.
4. Tuli SM. Results of treatment of spinal tuberculosis by "middle-path" regime. *J Bone Joint Surg Br* 1975;57:13-23.
5. Konstam PG, Blesovsky A. The ambulant treatment of spinal tuberculosis. *Br J Surg* 1962;50:26-38.
6. Moon MS, Kim I, Woo YK, Park YO. Conservative treatment of tuberculosis of the thoracic and lumbar spine in adults and children. *Int Orthop* 1987;11:315-22.
7. Moon MS, Moon YW, Moon JL, Kim SS, Sun DH. Conservative treatment of tuberculosis of the lumbar and lumbosacral spine. *Clin Orthop Relat Res* 2002;398:40-49.
8. Upadhyay SS, Saji MJ, Sell P, Sell B, Yau AC. Longitudinal changes in spinal deformity after anterior spinal surgery for tuberculosis of the spine in adults. A comparative analysis between radical and debridement surgery. *Spine* 1994;19:542-9.
9. Parthasarathy R, Sriram K, Santha T, Prabhakar R, Somasundaram PR, Sivasubramanian S. Short-course chemotherapy for tuberculosis of the spine. A comparison between ambulant treatment and radical surgery—ten-year report. *J Bone Joint Surg Br* 1999;81:464-71.
10. Styblo K. Overview and epidemiological assessment of the current global tuberculosis situation: With an emphasis on tuberculosis control in developing countries. *Bull Int Union Tuberc Lung Dis* 1988;63:39-44.
11. Report on the tuberculosis epidemic. In *Stop TB at the source* Geneva: World Health Organization; 1995.
12. Cox HS, Morrow M, Deutschmann PW. Long term efficacy of DOTS regimens for tuberculosis: Systematic review. *BMJ* 2008;336:484-7.
13. WHO: The stop TB strategy, Building on and enhancing DOTS to meet the TB-related millennium development goals Geneva; World Health Organization; 2006.
14. Nene A, Bhojraj S. Results of nonsurgical treatment of thoracic spinal tuberculosis in adults. *Spine J* 2005;5:79-84.
15. D I Boxer CP, A L Hine, M McNicol. Radiological features during and following treatment of spinal tuberculosis. *Br J Radiol* 1992;65:476-9.
16. Goble M, Iseman MD, Madsen LA, Waite D, Ackerson L, Horsburgh CR Jr. Treatment of 171 patients with pulmonary tuberculosis resistant to isoniazid and rifampin. *N Engl J Med* 1993;328:527-32.
17. Wang Z, Ge Z, Jin W, Qiao Y, Ding H, Zhao H, *et al.* Treatment of spinal tuberculosis with ultrashort-course chemotherapy in conjunction with partial excision of pathologic vertebrae. *Spine J* 2007;7:671-81.
18. Five-year assessments of controlled trials of ambulatory treatment, debridement and anterior spinal fusion in the management of tuberculosis of the spine. Studies in Bulawayo (Rhodesia) and in Hong Kong. Sixth report of the Medical Research Council Working Party on Tuberculosis of the Spine. *J Bone Joint Surg Br* 1978;60-B:163-77.
19. Davies PD. The role of DOTS in tuberculosis treatment and control. *Am J Respir Med* 2003;2:203-9.
20. Wilkinson D. High-compliance tuberculosis treatment programme in a rural community. *Lancet* 1994;343:647-8.
21. Murray CJ, DeJonghe E, Chum HJ, Nyangulu DS, Salomao A, Styblo K. Cost effectiveness of chemotherapy for pulmonary tuberculosis in three sub-Saharan African countries. *Lancet* 1991;338:1305-8.
22. Fox W, Ellard GA, Mitchison DA. Studies on the treatment of tuberculosis undertaken by the British Medical Research Council tuberculosis units, 1946-1986, with relevant subsequent publications. *Int J Tuberc Lung Dis* 1999;3:S231-79.
23. Rajeswari R, Balasubramanian R, Venkatesan P, Sivasubramanian S, Soundarapandian S, Shanmugasundaram TK, *et al.* Short-course chemotherapy in the treatment of Pott's paraplegia: Report on five year follow-up. *Int J Tuberc Lung Dis* 1997;1:152-8.
24. Canetti G, Grumbach F, Grosset J. Long-term, two-stage chemotherapy of advanced experimental murine tuberculosis with intermittent regimes during the second stage. *Tubercle* 1963;44:236-40.
25. Balasubramanian R, Ramachandran R. Management of non-pulmonary forms of tuberculosis: Review of TRC studies over two decades. *Indian J Pediatr* 2000;67:S34-40.
26. Lotte A, Hatton F, Perdrizet S, Rouillon A. A concurrent comparison of intermittent (Twice-Weekly) isoniazid plus streptomycin and daily isoniazid plus pas in the domiciliary treatment of pulmonary tuberculosis; Tuberculosis chemotherapy centre, Madras. *Bull World Health Organ* 1964;31:247-71.
27. Balasubramanian R. Fully intermittent six-month treatment

regimen for pulmonary tuberculosis in south India. *Indian J Tuberc* 1991;38:51-3.

28. Wandwalo E, Robberstad B, Morkve O. Cost and cost-effectiveness of community based and health facility based directly observed treatment of tuberculosis in Dar es Salaam, Tanzania. *Cost Eff Resour Alloc* 2005;3:6.
29. Nussbaum ES, Rockswold GL, Bergman TA, Erickson DL, Seljeskog EL. Spinal tuberculosis: A diagnostic and management

challenge. *J Neurosurg* 1995;83:243-7.

How to cite this article: Valsalan R, Purushothaman R, Raveendran MK, Zacharia B, Surendran S. Efficacy of directly observed treatment short-course intermittent regimen in spinal tuberculosis. *Indian J Orthop* 2012;46:138-44.

Source of Support: Nil, **Conflict of Interest:** None.

Author Help: Online submission of the manuscripts

Articles can be submitted online from <http://www.journalonweb.com>. For online submission, the articles should be prepared in two files (first page file and article file). Images should be submitted separately.

1) **First Page File:**

Prepare the title page, covering letter, acknowledgement etc. using a word processor program. All information related to your identity should be included here. Use text/rtf/doc/pdf files. Do not zip the files.

2) **Article File:**

The main text of the article, beginning with the Abstract to References (including tables) should be in this file. Do not include any information (such as acknowledgement, your names in page headers etc.) in this file. Use text/rtf/doc/pdf files. Do not zip the files. Limit the file size to 1 MB. Do not incorporate images in the file. If file size is large, graphs can be submitted separately as images, without their being incorporated in the article file. This will reduce the size of the file.

3) **Images:**

Submit good quality color images. Each image should be less than 4096 kb (4 MB) in size. The size of the image can be reduced by decreasing the actual height and width of the images (keep up to about 6 inches and up to about 1800 x 1200 pixels). JPEG is the most suitable file format. The image quality should be good enough to judge the scientific value of the image. For the purpose of printing, always retain a good quality, high resolution image. This high resolution image should be sent to the editorial office at the time of sending a revised article.

4) **Legends:**

Legends for the figures/images should be included at the end of the article file.