



Functional Endoscopic Sinus Surgery and Recurrence of Post-COVID Mucormycosis

B. M. Rudagi¹ · Jay Goyal¹ · Chinmayee Palande¹ · Prachi Patil¹

Received: 20 April 2022 / Accepted: 4 October 2022
© The Association of Oral and Maxillofacial Surgeons of India 2022

Abstract

Purpose To evaluate the value and limitation of functional endoscopic sinus surgery alone for the management of post-COVID mucormycosis and need for adjunctive invasive procedure.

Materials and Methods This is a clinical observational study that included a total of 17 patients who underwent FESS for post-COVID mucormycosis from April 2021 to May 2021. These patients reported to our institute with no improvement in their symptoms post-FESS from June 2021 to July 2021. Aggressive Surgical debridement of the involved sinuses, removal of surrounding necrotic bone and orbital exenteration (wherever necessary) was done in these patients. A regular follow-up till six months was done for every patient. Sixteen out of 17 patients did not report with any fresh complaint or recurrence.

Results The study included male and female in ratio of 12:5, with a mean age of 62.5 ± 7.7 years (range: 50–75 years). These patients underwent functional endoscopic sinus surgery, one to two months before reporting to our institute. Post-FESS, there was no improvement in the symptoms. All these patients were given systemic antifungal treatment post-operatively. The specimen was sent for histopathological as well as microbiological examination. All the FESS operated patients required a secondary more aggressive surgical intervention.

Conclusion Post-COVID mucormycosis is an aggressive fungal infection, for which FESS proves inadequate. It

requires an aggressive surgical debridement of the necrotic bone along with the debridement of the sinuses.

Keywords Post-COVID mucormycosis · Functional endoscopic sinus surgery (FESS) · Maxillectomy · Ethmoidectomy · Orbital exenteration

Introduction

Corona viruses are a family of viruses that can cause illnesses such as common cold, severe acute respiratory syndrome (SARS) and Middle East respiratory syndrome (MERS). In 2019, a new virus causing severe acute respiratory syndrome was identified which came to be known as severe acute respiratory syndrome 2, most commonly known as Corona Virus Disease-19 (COVID-19).

Corona Virus Disease (COVID-19) with viral pneumonia has been a worrisome health condition globally in the 2019–20 pandemic, with associated severe morbidity, high cost of care and unfavourable clinical outcome. Although COVID-19 primarily affects the lungs, different disease complications, such as myocardial injury, arrhythmia, thromboembolic events, and immune dysregulation, were reported.

With the escalation of COVID-19 severity and with its mutations, in the second wave of the COVID-19 pandemic, we witnessed the rise of post-COVID mucormycosis in India, which soon became an epidemic. As an institute, we have been witnessing and treating 2–3 cases of mucormycosis annually. The graph reached its peak in the 2020 pandemic, treating 6–7 cases daily.

Mycotic infection of the paranasal sinuses was first described in 1893 by Mackenzie. With the rising fungal

✉ Chinmayee Palande
drchinmayeepalande@gmail.com

¹ Department of Oral and Maxillofacial Surgery, J.M. F's A.C.P.M Dental College and Hospital, Dhule, Maharashtra, India

infection over the decades, mucormycosis ranks third after candidiasis and aspergillosis.

It is a cascade of multiple reasons during COVID such as low immunity, cytokine storm causing extreme inflammatory reaction and micro-thromboembolism, heavy dosage of steroids, increased blood sugar levels, poor oral and upper airway hygiene. This leads to opportunistic fungal infection and its rapid spread. Various fungi like *Rhizopus* species, *Mucor* species, *Rhizomucor* species, *Syncephalastrum* species, *Cunninghamella bertholletiae*, *Apophysomyces* species, and *Lichtheimia* (formerly *Absidia*) species commonly cause Mucormycosis.

Mucormycosis being a fulminant fungal infection associated with high morbidity and mortality rates. This is most common in people with uncontrolled diabetes and in people who have had a kidney transplant. These fungi develop rapidly and release large numbers of spores into the air. *Rhizopus* is an angio-invasive fungi, which hampers the blood supply and eventually causing necrosis of the tissue.

The disease usually starts in the nose and sinuses after inhalation of fungal spores. It proliferates and spreads to the paranasal sinuses (sino-nasal mucormycosis) and then to the orbit by direct extension or through haematogenous route (sino-orbital mucormycosis). It can also spread to the lung, gastro-intestine, skin, heart, spleen, and brain (sino-orbital–cerebral mucormycosis) which being the last stage of the spread. Post-COVID mucormycosis was an emergent situation, with a need to intervene immediately to stop the further spread of the disease.

Functional endoscopic sinus surgery is a minimally invasive technique used to restore sinus ventilation and normal function. It uses nasal endoscopes to enlarge the nasal drainage pathways of the paranasal sinuses to improve sinus ventilation and allow access of topical medications [1, 2] This procedure is generally used to treat inflammatory and infectious sinus diseases, including chronic rhinosinusitis that do not respond to drugs [3, 4] nasal polyps [4, 5] some cancers [6], and decompression of eye sockets/optic nerve in Graves ophthalmopathy. With advancements in the field, FESS became popular; however, mucormycosis being an aggressive fungal infection, there was inadequate debridement and a need for revision surgery. FESS remains inefficient for treating this aggressive fungal infection. Post-COVID mucormycosis should not be managed conservatively, as it may lead to residual infective tissue in the sinuses and further recurrence of the disease. Hence, open approach remains gold standard for mucormycosis.

In this article, we are evaluating the value and limitation of endoscopic sinus surgery alone for the management of post-COVID mucormycosis and need for adjunctive invasive procedure.

Material and Methods

This is a clinical observational study conducted at the A.C.P.M Dental College, Dhule. The Institutional Research Ethics Committee has approved with ref no. 1016/JMF's ACPMDC/IEC.

A total of 17 patients underwent FESS for mucormycosis from April 2021 to May 2021. Informed consent was obtained from all individual participants included in the study. The study included twelve men and five women, with a mean age of 62.5 ± 7.7 years (range: 50–75 years). Out of the seventeen patients, 13 patients were known case of diabetes mellitus with a duration of 15 years \pm 3 years (range: 5–25 years). These patients reported to our institute from June 2021 to July 2021 with chief complaint of consistent headache and nasal discharge, tenderness over malar region, tooth mobility, multiple draining sinuses, circumorbital oedema, ptosis and chemosis. Previous CT findings show sino-nasal inflammatory findings involving maxillary, ethmoid, frontal and sphenoid sinuses with bony erosions s/o invasive fungal aetiology. KOH stain was done prior to FESS s/o fungal elements in the nasal discharge. However, they had an asymptomatic period of 10 days \pm 2 days (Table 1).

In this study, we included patients who had undergone FESS, who had positive CT findings post-FESS for residual fungal tissue, patients with a histopathological diagnosis with a KOH stain positive for fungal elements, with a positive history of COVID-19 with viral pneumonia, willing to undergo second surgery and to give a valid informed consent to be included in the study and patients with an HRCT score below 10. Patients with active pneumonia and a HRCT score above 10, patients with Renal failure, patients with extensive cerebral mucor involvement, patients below 50 years of age, patients not giving consent for post-surgical inj. Amphotericin therapy and patients not giving a valid consent to be included without histopathological confirmation of any fungal elements were excluded from the study.

On clinical and radiological examination, we found out that there was recurrence/residual of the fungal infection with CT findings (Fig. 3) showing mucosal thickening in paranasal sinuses associated with erosion of orbital walls, maxillary sinus, ethmoidal sinus, sphenoidal sinus, frontal sinus, and cribriform plate in various degrees. The table given below illustrates the 17 cases which were included in the study with their various clinical features, asymptomatic period post-FESS, extent of the infection and the treatment given.

When patients reported to our institute, a comprehensive work-up was done which included detailed history, neurological examination, ocular examination, previous FESS operated details, previous radiographic examination, biopsy/fungal culture reports to assess the extent and severity of the recurrence of the disease. Initial

Table 1 Table showing details of the 17 cases; their clinical features and treatment

| Sr No | Age/Gender | Clinical features | FESS conducted | Asymptomatic period | Orbit/CNS involvement | Paranasal sinuses involved | Treatment given |
|-------|------------|---|----------------|---------------------|-----------------------|---|---|
| 1 | 65/F | Consistent headache, nasal discharge, frontal swelling, infra-orbital tenderness, circumorbital oedema | 58 days ago | - | Frontal bone eroded | Maxillary, ethmoid, frontal, and sphenoid | Maxillectomy + Sinus curettage + Systemic Antifungal |
| 2 | 70/M | Consistent headache, pus discharge, mobile teeth, hypoesthesia over the right infra-orbital region | 53 days ago | 7 days | - | Maxillary and ethmoid | Alveolectomy + Sinus curettage + Systemic Antifungal |
| 3 | 47/M | Infra-orbital tenderness, headache, mobile teeth, pus discharge | 49 days ago | - | - | Maxillary and ethmoid | Partial maxillectomy + Sinus curettage + Systemic Antifungal |
| 4 | 62/M | Infra-orbital tenderness, headache, nasal discharge, | 47 days ago | 10 days | - | Maxillary and ethmoid | Alveolectomy + Sinus curettage + Systemic Antifungal |
| 5 | 56/M | Mobile Teeth, pus discharge | 45 days ago | 14 days | - | Maxillary and ethmoid | Alveolectomy + Sinus curettage + Systemic Antifungal |
| 6 | 54/M | Infra-orbital tenderness, headache | 45 days ago | 18 days | - | Maxillary and ethmoid | Sinus curettage + Systemic Antifungal |
| 7 | 59/M | Infra-orbital tenderness | 43 days ago | 30 days | - | Maxillary | Sinus Curettage + Systemic Antifungal |
| 8 | 67/F | Infra-orbital tenderness, headache, Mobile teeth, pus discharge | 41 days ago | 12 days | Frontal bone eroded | Maxillary, ethmoid, frontal | Alveolectomy + Sinus curettage + Systemic Antifungal |
| 9 | 61/M | Infra-orbital tenderness on the right side of face, circumorbital oedema, chemosis, ptosis of the right eye | 40 days ago | 5 days | Orbital Apex syndrome | Maxillary, Ethmoid, frontal and sphenoid | Maxillectomy + orbit exenteration + Sinus curettage + Systemic Antifungal |
| 10 | 60/M | Infra-orbital tenderness, headache, Mobile teeth | 40 days ago | 20 days | - | Maxillary, ethmoid | Alveolectomy + Sinus curettage + Systemic Antifungal |
| 11 | 57/F | Infra-orbital tenderness, headache, Mobile teeth, pus discharge, hypoesthesia over the left side of face, ptosis (no loss of vision) of the left eye | 40 days ago | - | Orbital Apex syndrome | Maxillary, Ethmoid and frontal | Partial maxillectomy + Sinus curettage + Systemic Antifungal |
| 12 | 55/M | Infra-orbital tenderness, headache, Mobile teeth, chemosis of the left eye + circumorbital oedema | 39 days ago | 3 days | Orbital Apex syndrome | Maxillary, Ethmoid, frontal and sphenoid | Maxillectomy + orbit exenteration + Sinus curettage + Systemic Antifungal |
| 13 | 69/M | Consistent headache, Mobile teeth, pus discharge | 37 days ago | 14 days | - | Maxillary and ethmoid | Alveolectomy + Sinus curettage + Systemic Antifungal |
| 14 | 59/F | Consistent headache, hypoesthesia over the right side of face, chemosis + circumorbital oedema over the right side of the face, and loss of vision with right eye | 35 days ago | - | Orbital Apex syndrome | Maxillary, Ethmoid, frontal and sphenoid | Maxillectomy + orbit exenteration + Sinus curettage + Systemic Antifungal |

Table 1 (continued)

| Sr No | Age/Gender | Clinical features | FESS conducted | Asymptomatic period | Orbit/CNS involvement | Paranasal sinuses involved | Treatment given |
|-------|------------|--|----------------|---------------------|-----------------------|-----------------------------|--|
| 15 | 72/M | Consistent headache, Mobile Teeth, nasal discharge | 33 days ago | 15 days | – | Maxillary and ethmoid | Alveolectomy + Sinus curettage + Systemic Antifungal |
| 16 | 58/M | Consistent Headache, mobile teeth | 32 days ago | 12 days | – | Maxillary, ethmoid, frontal | Alveolectomy + Sinus curettage + Systemic Antifungal |
| 17 | 63/F | Mobile teeth | 29 days ago | 14 days | – | Maxillary, ethmoid | Alveolectomy + Sinus curettage + Systemic Antifungal |

investigations included complete blood count, HbA1c, random blood sugar, blood sugar-fasting and post-prandial, serum ferritin, D-DIMER, HRCT-Thorax, repeat CT-PNS or CT-PNS + orbit or MRI-PNS + Orbit was advised whichever appropriate; to assess the extent and severity of the recurred disease. Patients were immediately started on Inj. Amphotericin B Liposomal 3.5–5.5 mg/kg/day, calculated according to the extent, and spread of the disease; known diabetic patients and those with raised blood sugar levels were put on insulin therapy. Maximum duration of the therapy was 2–3 week post-operatively irrespective of the pre-operative dosage. Renal functions were monitored periodically during the antifungal therapy and diabetes was controlled with insulin therapy. Aggressive surgical debridement of the involved sinuses, surrounding bone and orbital exenteration was done in all patients (Wherever necessary) and the specimen was sent for histopathological as well as microbiological examination.

One patient reported late approximately 5-month post-FESS and the CT findings showed involvement of the roof and floor of the orbit, basisphenoid, bilateral cribriform plate. This patient had cerebral spread with a poor prognosis, post-operatively.

A regular follow-up of patients was done for six months, and 16 out of 17 patients did not report with any fresh complaint or recurrence.

Result

The study included twelve men and five women, with a mean age of 62.5 ± 7.7 years (range: 50–75 years). These patients underwent functional endoscopic sinus surgery, one to two months before reporting to our institute. Post-FESS, there was no improvement in the symptoms, due to which these patients reported to our institute for definitive management. Out of the seventeen patients, eleven patients with involvement of maxillary, ethmoid and frontal sinuses; nine patients underwent Alveolectomy sinus curettage, and two patients underwent partial maxillectomy followed by sinus curettage. Four patients with involvement of maxillary, ethmoid, sphenoid, and frontal sinuses underwent maxillectomy, ethmoidectomy, sphenoidotomy and sinus curettage. Two patients with minimal involvement of maxillary and ethmoid sinuses underwent sinus curettage. Out of these seventeen patients, four patients presented with orbital apex syndrome of which three patients underwent orbital exenteration (Table 1). All these patients were given systemic antifungal treatment post-operatively. The specimen was sent for histopathological as well as microbiological examination (Fig. 1 and 2).

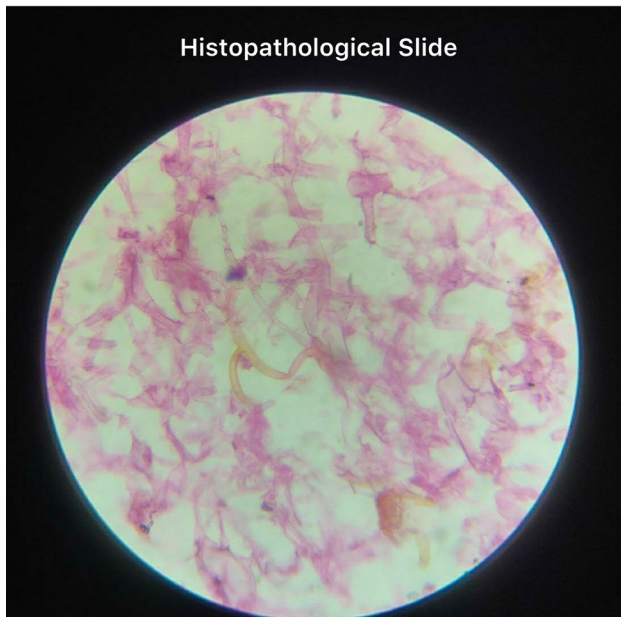


Fig. 1 Histopathological specimen

Discussion

Invasive fungal infections caused by the members of Mucorales (mucormycosis) are relatively rare but have increased in the last years. Compared to other fungal pathogens, such as *Aspergillus fumigatus* or *Candida albicans*, only little is known so far on fungal properties leading to successful infection and host immune response to the various representatives of the Mucorales. Mucormycosis is angio-invasive; therefore, it spreads rapidly involving the surrounding bone and the tissues along with the sinuses. These aggressive and highly destructive infections occur predominantly in immunocompromised hosts, especially in patients with haematological malignancies or those receiving haematopoietic stem cell transplantation. Diabetic patients with ketoacidosis and patients with transfusional/ dyserythropoietic iron overload are unique risk groups.

The year 2021 saw the rise of post-COVID mucormycosis predisposing to various factors such as decreased immunity, high blood sugar levels, aggressive use of corticosteroids, oxygen therapy and more. The fungal infection initiates in the nasal or oral cavity after a person inhales the spores. It spreads cephalo into the maxillary sinuses further spreading to the ethmoid, frontal, and sphenoid sinuses. Moreover, the infection through the lacrimal ducts causes orbital cellulitis further aggravating into orbital apex syndrome. Fungal hyphae produce ‘rhizoferrin’, which binds to serum iron. The rhizoferrin-iron complex is important for fungal growth [7, 8]. Hyperglycaemia also stimulates the fungal growth, and there is a reduction in chemotaxis and phagocytic efficiency that permits these innocuous organisms to proliferate

[9]. Hence, patients with diabetic ketoacidosis are more susceptible to mucormycosis as they have elevated levels of serum iron [7, 8]. It presents as a necrotic black skin ulceration on the face or neck or as a sinus infection [9]. Due to the aggressive course of the disease, it spreads to the cavernous sinus and to the brain parenchyma through the involvement of the cribriform plates, orbital vessels, or the orbital apex. It is the most fatal infection known to humans because of its rapid dissemination by the blood vessels [10]. Emergent curettage of the sinuses with the removal of the infected bone and tissues is the only treatment.

Functional endoscopic sinus surgery is a minimally invasive procedure that facilitates sinus curettage with nominal bone removal, facilitating passage for dependent drainage. The aim of endoscopic sinus surgery (ESS) in these patients would be to remove necrotic tissue and restore sinus drainage. Endoscopic sinus surgery opens the middle meatus, unplugs any oedematous infundibular mucosa, and enlarges the stenosed ostium, therefore unobstructing the OS and the maxillary sinus. It allows decompression and passive motion of secretions and allows culture of infected mucosa. It aerates the sinus and provides access to remove infected foci [11]. Benefits of using endoscopic sinus surgery include improved visibility, minimal invasiveness, and less operative morbidity especially in some of these patients that can be acutely ill [12].

Surgery is a very important part of the treatment of these patients, largely because of difficulty of medically clearing the disease in necrotic tissue. The principle of surgical treatment is to debride the area until one encounters normal bleeding tissue. The infected mucor tissue bleeds very little because of the vaso-occlusive effect of the fungus and patients may need repetitive debridement [13]. Surgical option mainly depends upon the extension of the mucormycosis which may vary from debridement with Caldwell-Luc, medial maxillectomy, ethmoidectomies, sphenoidotomies, and even radical maxillectomy with orbital exenteration in very severe cases [12].

Caldwell-Luc procedure is performed to completely remove the infected sinus lining, taking care to avoid injury to the natural ostium. The Caldwell-Luc operation uses an external approach for surgical treatment of the severely diseased maxillary sinus. It is an alternative to middle meatal antrostomy done via endonasal endoscopic surgery and was the primary approach used for accessing the maxillary sinus before the advent of endoscopic sinus surgery. [14]

Out of the seventeen patients, 13 patients were known case of diabetes mellitus with a duration of 15 years \pm 3 years (range:5–25 years); these diabetic patients and those with raised blood sugar levels were put on insulin therapy. Diagnosis of mucormycosis was made while the COVID-19 treatment was ongoing or 2–3 weeks post-treatment. The common presenting symptom and

Post FESS CT PNS showing recurrence

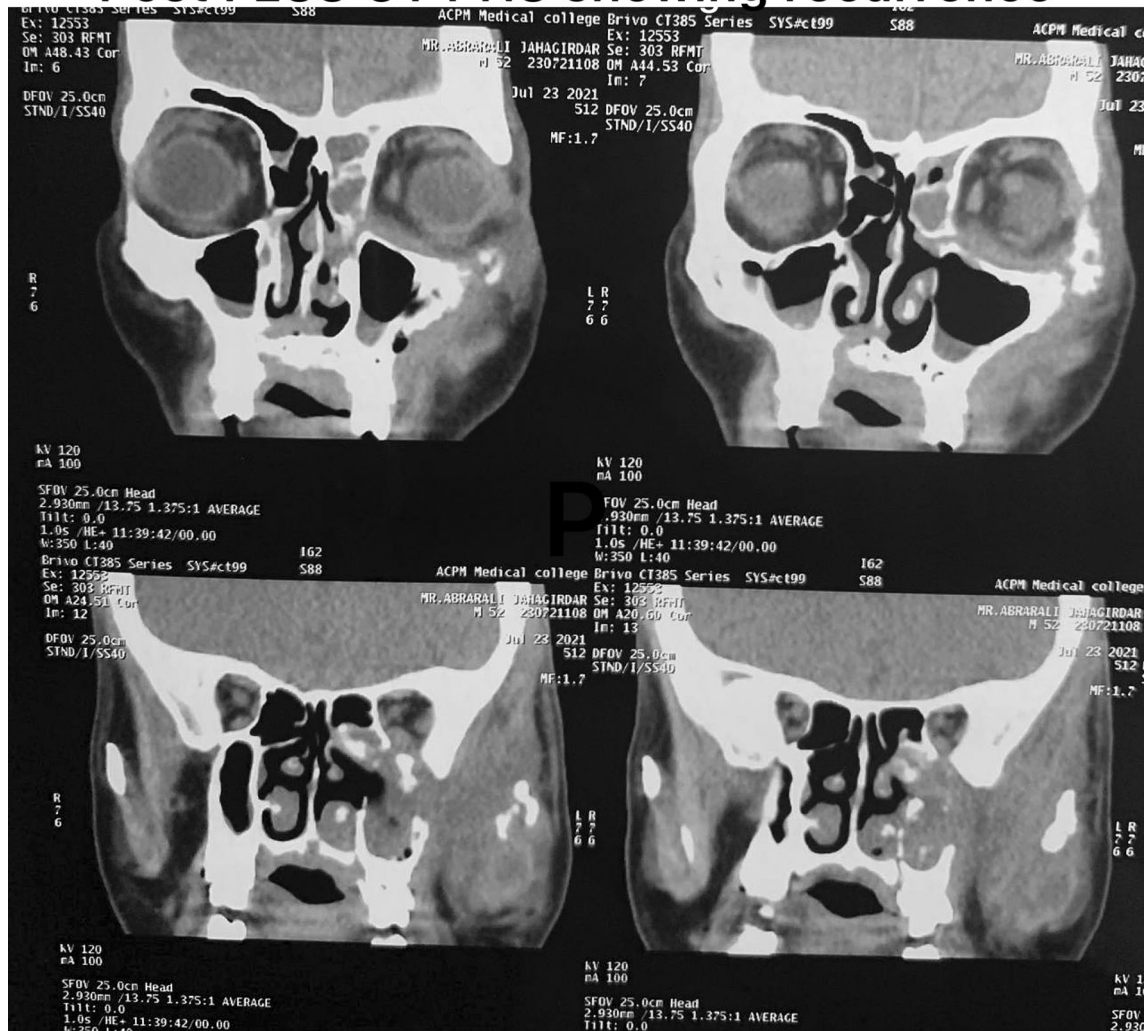


Fig. 2 Post-FESS CT-PNS showing recurrence

signs were infra-orbital tenderness (50%), mobile teeth (60%), Pus discharge (40%), severe headache (80%), nasal discharge (16%) and hyposthesia (20%), chemosis. Frontal sinus perforation was seen in one patient. Fungal culture was positive for *Rhizopus* (88%) and *mucor* (12%) species. These patients had an asymptomatic period of 10 days \pm 2 days (Table no.1). Previous CT/MRI scan of these patients showed mucosal thickening involving bilateral maxillary sinus, ethmoid with hypertrophied nasal turbinates and erosion of the bone, while one patient showed mucosal thickening of frontal sinus with erosion of the frontal bone. These patients underwent functional endoscopic sinus surgery, one to two months before reporting to our institute. FESS was planned on the basis of the sinus involvement and the procedure being minimally invasive; however, the extensive bony erosion does not facilitate the criteria for ESS.

As FESS facilitates dependent drainage and mucor thickening cannot be facilitated dependently. The only report found in the literature was a report from Taiwan. This involved 9 patients (since 1985), treated with endoscopic sinus surgery. Six had ESS alone and 3 required additional procedures because of the spread of disease. All patients received amphotericin B, and 8 out of 9 survived [15]. FESS will need adjunctive procedures with it if there is extension of the mucor beyond the medial wall of the maxillary sinus or hard palate extension.

The evaluation of pre-operative and post-operative CT-scans after FESS (Fig. 3) revealed residual infected tissue in the sinuses which was inadequately curetted. This led to rapid and continual spread of the fungal elements in the non-infected sinuses. ESS facilitates gravity dependant drainage of the sinuses. FESS proves inadequate if there is extensive bone necrosis along with the sinus lining.

Pre-operative evaluation is critical in mucormycosis for deciding the treatment plan. Mucor invades the bone and surrounding vasculature which makes necrotic bone removal along with sinus lining imperative.

Caldwell-Luc procedure or open surgical procedure facilitates adequate removal of the necrotic bone by providing clear visibility. A greater reduction in inflammatory parameters in the sinus mucosa is obtained with Caldwell-Luc operation than with FESS [16].

The hallmarks of successful treatment are control of underlying disease, systemic antifungal therapy, and aggressive surgical therapy [17].

Conclusion

Mucormycosis being a fulminating angio-invasive fungal infection of the sino-nasal tract that often extends to the orbit, brain, palate, and skin. FESS is a minimally invasive procedure which does not facilitate complete removal of the necrotic and infected bone and tissues leading to rapid and aggressive spread of the fungal infection. Mucormycosis requires an aggressive surgical debridement adjunct to antifungal therapy for a long-standing prognosis.

Author Contributions All authors contributed to the study conception and design. Material preparation, data collection and analysis were performed by Dr. B. M. Rudagi, Dr. Jay Goyal, Dr. Chinmayee Palande and Dr. Prachi Patil. The first draft of the manuscript was written by Dr. Chinmayee Palande and all authors commented on previous versions of the manuscript. All authors read and approved the final manuscript.

Funding The authors did not receive support from any organization for the submitted work.

Declarations

Conflict of interest All authors certify that they have no affiliations with or involvement in any organization or entity with any financial interest or non-financial interest in the subject matter or materials discussed in this manuscript.

Ethical Standard This is a clinical observational study conducted at the A.C.P.M Dental College, Dhule. The Institutional Research Ethics Committee has approved with ref no. 1016/JMF's ACPMDC/IEC dated 17/04/2021 and the study was performed in accordance with the ethical standards as laid down in the 1964 Declaration of Helsinki and its later amendments or comparable ethical standards.

Informed consent Informed consent was obtained from all individual participants included in the study.

References

- Slack R, Bates G (1998) Functional endoscopic sinus surgery. *Am Fam Physician* 58:707–718
- Da Jiang.(2018) Functional Endoscopic Sinus Surgery. In: ENT Clinical Services. UNC Otolaryngology/Head and Neck Surgery <https://www.med.unc.edu/ent/patient-care/clinical-services/functional-endoscopic-sinus-surgery>. Accessed 1 Dec 2021.
- Sukato DC, Abramowitz JM, Boruk M, Goldstein NA, Rosenfeld RM (2018) Endoscopic sinus surgery improves sleep quality in chronic rhinosinusitis: a systematic review and meta-analysis. *Otolaryngol Head Neck Surg.* <https://doi.org/10.1177/0194599817737977>
- Patel A. (2016.) Functional Endoscopic Sinus Surgery: Overview, Preparation, Technique. In: *Drugs and Diseases*. Medscape. <https://www.scribd.com/document/354193418/Functional-Endoscopic-Sinus-Surgery-Overview-Preparation-Technique>. Accessed 1 2021.
- Cazzavillan A, Castelnuovo P, Berlucchi M, Baiardini I, Franzetti A, Nicolai P, Gallo S, Passalacqua G (2012) Management of chronic rhinosinusitis. *Pediatr Allergy Immunol.* <https://doi.org/10.1111/j.1399-3038.2012.01322.x>
- Meccariello G, Deganello A, Choussy O, Gallo O, Vitali D, De Raucourt D, Georgalas C (2016) Endoscopic nasal versus open approach for the management of sinonasal adenocarcinoma: A pooled-analysis of 1826 patients. *Head Neck.* <https://doi.org/10.1002/hed.24182>
- Mathebula SD (2008) Mucormycosis. *S Afr Optom.* <https://doi.org/10.4102/aveh.v67i1.179>
- Dokmetas HS, Canbay E, Yilmaz S, Elaldi N, Topalkara A, Oztoprak I, Yildiz E (2002) Diabetic ketoacidosis and rhino-orbital mucormycosis. *Diabetes Res Clin Pract.* [https://doi.org/10.1016/S0168-8227\(02\)00021-9](https://doi.org/10.1016/S0168-8227(02)00021-9)
- Anehosur V, Agrawal SM, Joshi VK, Anand J, Krishnamuthy K, Kumar N (2019) Incidence and treatment protocol for maxillofacial fungal osteomyelitis: a 12-year study. *J Oral Maxillofac Surg.* <https://doi.org/10.1016/j.joms.2019.06.187>
- Hilal AA, Taj-Aldeen SJ, Mirghani AH (2004) Rhino-orbital mucormycosis secondary to *Rhizopus oryzae*: A case report and literature review. *ENT Journal* 83(8):556–562
- Stammberger H, Zinreich SJ, Kopp W, Kennedy DW, Johns ME, Rosenbaum AE (1987) Surgical treatment of chronic recurrent sinusitis—the Caldwell-Luc versus a functional endoscopic technique. *HNO* 35:93–105
- Al-Omran MK, Mirza H (2007) Rhinomaxillary mucormycosis: the role of endoscopic sinus surgery in the management. *Saudi J Otorhinolaryngol Head Neck Surg* 9:63–65
- Raj P, Vella EJ, Path FRC, Bicker ton RC (1998) Successful treatment of rhino cerebral mucormycosis by a combination of aggressive surgical debridement and the use of systemic liposome amphotericin B and local therapy with nebulized amphotericin: A case report. *J Laryngol Otol.* <https://doi.org/10.1017/S002221510140484>
- Datta RK, Viswanatha B, Shree Harsha M (2016) Caldwell luc surgery: revisited, indian. *J Otolaryngol Head Neck Surg.* <https://doi.org/10.1007/s12070-015-0883-y>
- Jiang RS, Hsu CY (1999) Endoscopic sinus surgery for rhinocerebral mucormycosis. *Am J Rhinol* 13(2):105–110
- Forsgren K, Fukami M, Penttila M, Kumlien J, Stierna P (1995) Endoscopic and Caldwell-Luc approaches in chronic maxillary sinusitis: a comparative histopathologic study on preoperative and postoperative mucosal morphology. *Ann Otol Rhinol Laryngol* 104(5):350–357
- Peterson KL, Wang M, Canalis RF, Abemayor E (1997) Rhinocerebral mucormycosis: Evolution of the disease and treatment

options. Laryngoscope. <https://doi.org/10.1097/00005537-199707000-00004>

Publisher's Note Springer Nature remains neutral with regard to jurisdictional claims in published maps and institutional affiliations.

Springer Nature or its licensor holds exclusive rights to this article under a publishing agreement with the author(s) or other rightsholder(s); author self-archiving of the accepted manuscript version of this article is solely governed by the terms of such publishing agreement and applicable law.