

This article is licensed under the Creative Commons Attribution-NonCommercial 4.0 International License (CC BY-NC) (<http://www.karger.com/Services/OpenAccessLicense>). Usage and distribution for commercial purposes requires written permission.

Case Report

# Implantation of the Black Artisan Iris-Claw Intraocular Lens: A Case Series

Nazli Demirkaya<sup>a</sup> Keamela Vasanthanathan<sup>a</sup> Ivanka van der Meulen<sup>a, b</sup>  
Ruth Lapid-Gortzak<sup>a, b</sup>

<sup>a</sup>Department of Ophthalmology, Amsterdam UMC, location Meibergdreef, University of Amsterdam, Amsterdam, The Netherlands; <sup>b</sup>Retina Total Eye Care, Driebergen, The Netherlands

## Keywords

Black Artisan intraocular lens · Pupil-occluding intraocular lens · Lens implantation · Binocular visual dysfunction · Intractable diplopia

## Abstract

In this case series, we report the use of the black Artisan iris-claw intraocular lens (IOL) (Ophtec, The Netherlands) in 6 patients with various visually debilitating symptoms requesting occlusion of one eye. Between 2016 and 2019, 6 (5 female, 1 male) patients underwent implantation of the custom-made black Artisan iris-claw IOL after other management strategies had failed to relieve their symptoms. The black Artisan IOL is an opaque anterior chamber IOL that is fixated to the iris by enclavation. Data were obtained from the electronic patient records (Epic, Verona, WI, USA). All implantation surgeries were uneventful. In terms of outcomes, 4 patients (67%) were satisfied with the result. In 2 patients (33%), the dysphotopic symptoms were not resolved, and these patients opted for either an enucleation or an evisceration. In conclusion, a black Artisan IOL is a valuable and – if needed – reversible option in the management of patients suffering from monocular debilitating visual symptoms leading to disturbances of binocular vision. The clinical presentation leading to the implantation of a pupil-occluding IOL varies and patient satisfaction following implantation is variable. Careful preoperative evalua-

tion of patient factors and expectations, and stepped-care management is recommended to minimize treatment failure. Pupil-occluding lens implantation is often the last step in the treatment of intractable visual complaints in eyes with complex ophthalmologic history, before evisceration or enucleation.

© 2020 The Author(s)  
Published by S. Karger AG, Basel

## Introduction

Several therapeutic options are available for patients with intractable diplopia or other debilitating neuro-ophthalmic symptoms, requesting occlusion of one eye. Noninvasive options are patches (worn on the face or on glasses), occlusive contact lenses, or filters placed on glasses. However, a patch is cosmetically unappealing and some patients may still be symptomatic despite patching, or become intolerant for contact lenses, and may be considered for implantation of an opaque intraocular lens (IOL). In recent years, several case series/reports have been published on the use of opaque occlusive IOLs, placed in the posterior (sulcus or bag fixated; Morcher GmbH, Germany; Ophtec 0.0D black Ani II “no hole” IOL, The Netherlands; Dr Schmidt Intraokularlinsen GmbH, Germany), or anterior (iris-fixated black Artisan IOL; Ophtec, The Netherlands) chamber, in both pseudophakic and phakic patients [1–11].

Here, we describe our experience with the black Artisan iris-claw IOL in six patients with various symptoms requiring intraocular occlusion, after failure of other management strategies. To our knowledge, this is the largest case series describing implantation of this particular IOL.

## Case Presentation

In this single-center retrospective case series, 6 patients (5 female, 1 male) underwent implantation of the black Artisan iris-claw IOL (Ophtec, The Netherlands) for disturbances of binocular vision at the Amsterdam UMC during 2016–2019.

The Artisan black iris-claw 201 IOL is a custom-made non-foldable polycarbonate non-near-infrared light-transmitting IOL with an optic diameter of 5.4 mm and is fixated to the mid-peripheral iris, in the same manner as the other types of Artisan lenses are enclavated to the iris (Fig. 1).

Preoperatively, topical pilocarpine 2% was applied to achieve adequate miosis. Four patients were operated under general anesthesia. The surgical procedure in short: two side port incisions (1 mm) were made, viscoelastics (Provisc, Alcon, USA) was injected into the anterior chamber, followed by the creation of a corneoscleral 5.4 mm main incision. The IOL was inserted and fixated by enclavation to the mid-peripheral iris in the prepupillary plane. A surgical peripheral iridectomy was made. After irrigation/aspiration of the viscoelastics, the main incision was closed with interrupted 10.0 nylon sutures.

In the postoperative course, a topical steroid and antibiotic preparation (Tobradex, Tobramycine 0.3% and dexamethasone 0.1%, Alcon, USA) and Nepafenac 0.3% (Alcon, USA) were used for 4 weeks. Mean follow-up period was 5 months (range 1–14 months).

Data were obtained from the electronic patient records (Epic).

### *Case 1*

A 55-year-old female with primary open angle glaucoma and a history of strabismus and multiple glaucoma surgeries (Ex-Press implant ODS, Baerveldt implant OS) described bothersome black spots and flashes of light in her worse left eye, which influenced her binocular vision as well. When she closed her left eye, these symptoms disappeared. An occlusive (iris print) contact lens did not suppress the dysphotopsia completely; in addition, the patient experienced difficulty inserting and removing the contact lens. Next, a black Artisan iris-claw IOL was implanted, although during preoperative anterior segment examination iris-diaphany was noticed nasally, and during informed consent the possibility of persisting symptoms after implantation was mentioned. Three months postoperatively, the patient requested a permanent solution for persisting debilitating light sensations and the left eye was eventually eviscerated. Following this procedure, our patient was symptom-free.

### *Case 2*

A 48-year-old female with an amblyopic right eye (unilateral high myopia of –17 dpt with visual acuity 1/60 after scleral buckle procedure) and a history of severe Graves' orbitopathy (consecutive bilateral orbital decompression and twice strabismus surgery of the right eye) had a recurrence of disturbing binocular diplopia after being symptom-free for 3 years. She was intolerant of an occlusive contact lens, due to dry eye symptoms, and a black Artisan iris-claw IOL was inserted in the right eye. Postoperatively, the diplopia had disappeared, but the patient was still symptomatic from persistent peripheral light entering the eye and also suffered from intractable pain.

Four months after implantation, the patient requested enucleation of the eye, after which she was relieved from her symptoms.

### *Case 3*

A 52-year-old female with a history of orbital cellulitis and abscess and several orbital surgeries complained of persisting binocular diplopia (due to restrictive ocular motility) and pain behind the left globe (for which she was referred to a pain clinic). Trial of a black contact lens alleviated her symptoms, but proved difficult for her to use. A black Artisan iris-claw IOL was implanted in the left eye; afterwards, the diplopia disappeared and only at night some side illumination was noticed by the patient, which did not bother her. At follow-up, mild uveitis and cellular precipitates were observed on the surface of the IOL, which were treated with topical fluormetholone and resolved.

### *Case 4*

A 74-year-old male with metamorphopsia and poor vision in his left eye – after repeat vitrectomy for recurrent rhegmatogenous macular-off retinal detachment – occluded this eye with a black “pirate” patch, but requested a more permanent occlusion with a better cosmetic appearance. The patient was very satisfied after implantation of the black Artisan iris-claw IOL.

### *Case 5*

A 83-year-old female developed disabling dysphotopsia (describing it as scattering of light and seeing a “hanging bubble”) in her right eye after five vitrectomies (pucker peeling,

recurrent retinal detachment, oil in and out procedures). She tried an occlusive contact lens for 2 years, but her symptoms were not reduced sufficiently and she had difficulty handling the contact lenses as well. The dysphotopsia was eliminated after implantation of the black Artisan iris-claw IOL. Six weeks postoperatively (2 weeks after tapering off the Tobradex eye drops) a rebound uveitis was observed and treated successfully with dexamethasone drops. Fourteen months postoperatively, our patient is still satisfied with this IOL.

### Case 6

A 51-year-old female with persisting binocular diplopia (despite multiple strabismus surgeries) was referred to our clinic for a second opinion, having already tried prisms, atropine eye drops (to treat a possible accommodating spasm), monovision, sclera lenses, and occluding contact lenses. Due to severe ocular surface syndrome, the use of contact lenses became increasingly non-tolerable for her and after careful consideration, a black Artisan iris-claw IOL was implanted in the right eye. The diplopia was eliminated, although some side illumination was reported, which partly resolved with the use of topical pilocarpine (2%; once daily). Three months postoperatively, our patient still experienced some degree of side illumination, which was acceptable for her, and she was discharged from our clinic.

### Discussion

Several opaque pupil-occluding IOLs are available for patients with invalidating symptoms such as visual confusion, metamorphopsia, intractable diplopia, or dysphotopsia, who are in need of intraocular occlusion of one eye [9]. We believe we present the largest case series of 6 patients implanted with the Artisan black iris-claw 201 IOL, a polycarbonate non-near-infrared light-transmitting IOL, that can be enclavated pre- or retropupillary, as opposed to black IOLs that are placed in the bag/sulcus or fixated to the sclera. Preoperative scotopic pupillometry is not needed as complete pupillary occlusion can be achieved with the use of pre- or intraoperative miotics prior to enclavation [12].

Although implantation of this IOL can be easily reverted, it is advisable to consider non-invasive options first, considering the risk of possible surgery-related complications [13]. Four of our patients (Cases 1, 3, 5, 6) tried occlusive contact lenses before, but found it difficult to use and/or did not achieve adequate relief. This is in line with previous reports describing short-term relief with occlusive contact lenses [2]. One patient (Case 4) had used an occlusive eye patch, which eliminated his metamorphopsia, but was cosmetically unacceptable to the patient.

A possible advantage of the occlusive Artisan IOL over polymethyl methacrylate IOLs like the black Morcher posterior chamber IOL is its ability to block all wavelengths of light [8, 12], including infrared light, thus providing total light occlusion and potentially increased postoperative patient satisfaction. However, patients needing a regular posterior segment evaluation to follow up on diabetic retinopathy, risk of retinal detachment, naevi, or other pathologies, can only be examined by ultrasound, due to the inability to monitor the posterior segment with light imaging modalities, like optical coherence tomography [12].

In our series, four of five patients (Cases 1, 2, 4, 5) had a preoperative visual acuity of hand movements or less and occlusive IOL implantation was the next step in the management of

their disabling symptoms before considering removal of the globe. Postoperatively, five of six patients (Cases 1, 3, 4, 5, 6) had residual light perception, despite an accurate IOL position (with the exception of Case 3, who had a slightly inferiorly decentered IOL, which was not disturbing). Cases 1 and 2 eventually underwent an evisceration and enucleation, respectively. Of note, during preoperative consultation, iris transillumination was observed nasally in Case 1 and she was informed about the possibility of treatment failure after IOL implantation. In addition to persisting light perception, severe ocular pain was an important reason to remove the eye of Case 2. In contrast, Cases 3, 5, and 6 perceived but were not negatively affected by the side illumination.

Our results compare with a recent case series described by Gong et al. [10] of 5 (of 6) patients being implanted with a custom-made Ophtec 0,0 dpt black polycarbonate Ani II (no hole; 9 mm optic diameter) IOL into the capsular bag. This IOL has the same near-infrared-blocking properties as the black Artisan iris-claw IOL used in our series and provides total light occlusion; regardless, 4 patients had variable light perception postoperatively [10].

The mechanisms underlying residual light perception despite the use of a near-infrared-blocking IOL are unclear; transscleral light transmission, iris transillumination, para-optical light leakage, and problematic neuroadaptation may all be of influence on the postoperative outcome.

Limitations of this case series are its retrospective nature, the small number of patients, and short follow-up period. Mild postoperative uveitis was observed in two patients and treated successfully with topical corticosteroids. Compared to in-the-bag IOLs, an iris-fixated IOL has a slightly increased risk of causing corneal edema due to endothelial cell loss, pigment dispersion syndrome, glaucoma (and cataract formation in phakic patients) [13]. Although retropupillary IOL fixation is aesthetically more pleasing than an anterior approach, and has a smaller risk of causing corneal decompensation, we chose to enclavate prepupillary, since the cases we described were complex eyes, after multiple surgical interventions.

In conclusion, this case series addresses a heterogeneous group of six patients with complicated ocular histories (Table 1) who were implanted with the black Artisan iris-claw IOL (Ophtec, The Netherlands) for varying debilitating symptoms requiring permanent occlusion of one eye. Patient satisfaction following implantation was variable. A thorough preoperative evaluation of patient factors (including signs of iris or scleral transillumination) and expectations, and stepped-care management is recommended to minimize treatment failure. A pupil-occluding IOL is often the last step in management before removal of the eye.

## Statement of Ethics

All subjects have consented to the submission and publication of the case reports, images included.

## Conflict of Interest Statement

Ruth Lapid-Gortzak: Alcon: consulting, speaker bureau member, research funding; Eye Med: consulting; Eye Yon: consulting, research funding; Hanita lenses: consulting, speaker

bureau member; Sanoculis: consulting; Santen: consulting; Thea Pharma: consulting, speaker bureau member; VSY Biotechnology: speaker bureau member. The other authors have no financial disclosures to make.

## Funding Sources

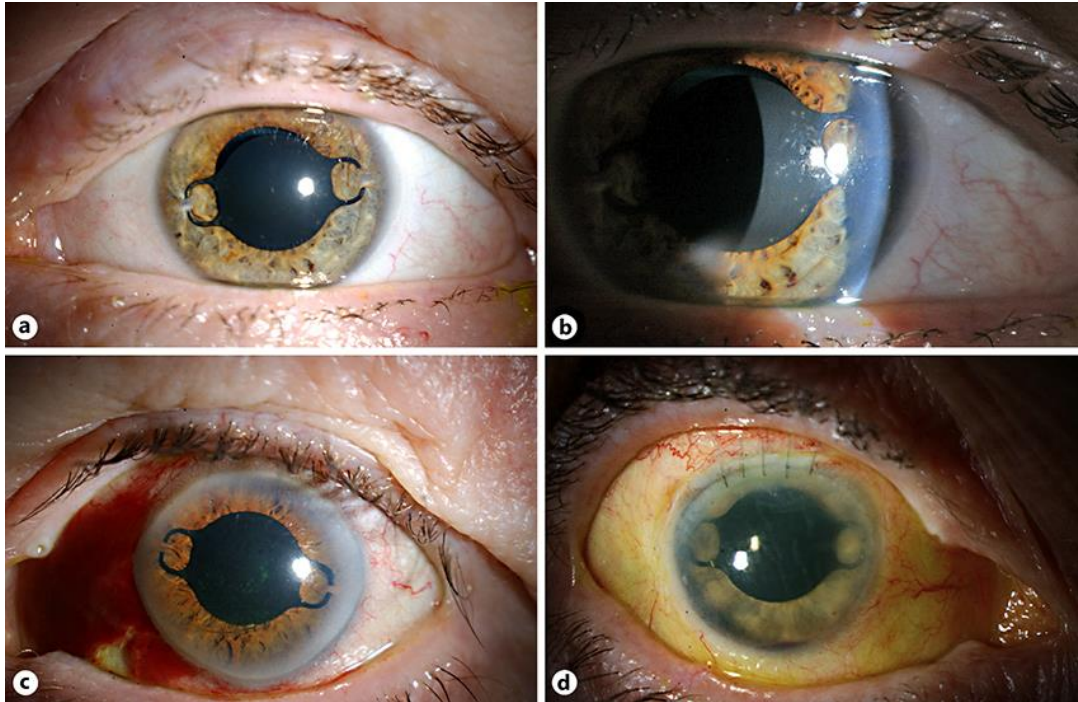
No funding or grant support was received.

## Author Contributions

Nazli Demirkaya, MD, PhD: conception of the paper, design of the paper, data analysis and interpretation, literature search, manuscript drafting. Keamela Vasanthanathan, MD: co-writing of the manuscript, literature search. Ivanka van der Meulen, MD, PhD: patient management, data collection, manuscript editing and revision. Ruth Lapid-Gortzak, MD, PhD: patient management, data collection, manuscript editing and revision as well as final approval. All authors state that they approve the paper. All authors attest that they meet the current ICMJE criteria for authorship.

## References

- 1 Wong SC, Islam N, Ficker L. Black occlusive IOLs. *Ophthalmology*. 2007 Dec;114(12):2365–2365.e2.
- 2 Hadid OH, Wride NK, Griffiths PG, Strong NP, Clarke MP. Opaque intraocular lens for intractable diplopia: experience and patients' expectations and satisfaction. *Br J Ophthalmol*. 2008 Jul;92(7):912–5.
- 3 Kwok T, Watts P. Opaque intraocular lens for intractable diplopia-UK survey. *Strabismus*. 2009 Oct-Dec;17(4):167–70.
- 4 Yusuf IH, Peirson SN, Patel CK. Occlusive IOLs for intractable diplopia demonstrate a novel near-infrared window of transmission for SLO/OCT imaging and clinical assessment. *Invest Ophthalmol Vis Sci*. 2011 Jun;52(6):3737–43.
- 5 Lee RM, Dubois VD, Mavrikakis I, Okera S, Ainsworth G, Vickers S, et al. Opaque intraocular lens implantation: a case series and lessons learnt. *Clin Ophthalmol*. 2012;6:545–9.
- 6 Yusuf IH, Arun KS, Rosen P, Patel CK. Black-on-black secondary occlusive IOL implantation to alleviate enigmatic light perception through a black IOL. *J Cataract Refract Surg*. 2013 Sep;39(9):1439–41.
- 7 Yusuf IH, Peirson SN, Patel CK. Black intraocular lenses: near infra-red light transmission may risk treatment failure. *Br J Ophthalmol*. 2013 Oct;97(10):1353–4.
- 8 Shonibare O, Lochhead J. 'Double occlusion': black Artisan iris claw intraocular lens insertion following failed occlusion treatment for intractable diplopia. *Eye (Lond)*. 2014 Jun;28(6):768–9.
- 9 Yusuf IH, Fung TH, Patel CK. Primary black intraocular lens selection. *Eye (Lond)*. 2014 Nov;28(11):1380–2.
- 10 Gong JW, O'Colmain U, MacEwen CJ. Opaque intraocular lens implantation. *Eye (Lond)*. 2015 Jul;29(7):978–80.
- 11 Yusuf IH, Fung TH, Patel CK. Response to 'Opaque intraocular lens implantation'. *Eye (Lond)*. 2015 Jul;29(7):980–1.
- 12 Yusuf IH, Peirson SN, Patel CK. Inability to perform posterior segment monitoring by scanning laser ophthalmoscopy or optical coherence tomography with some occlusive intraocular lenses in clinical use. *J Cataract Refract Surg*. 2012 Mar;38(3):513–8.
- 13 Hassaballa MA, Macky TA. Phakic intraocular lenses outcomes and complications: artisan vs Visian ICL. *Eye (Lond)*. 2011 Oct;25(10):1365–70.



**Fig. 1.** **a, b** Case 3, 4 months postoperatively. The IOL is slightly decentered and does not cover the pupil superiorly, as shown in **a**. Cellular precipitates on the IOL surface are visible in **b**. **c** Case 4, 1 month postoperatively. **d** Case 5, 10 days postoperatively.

**Table 1.** Patient characteristics

Case	Sex/ age, years	Symptoms	Relevant ophthalmic history	Previous treatment(s)	Preoperative lens status	Operated eye	Visual acuity		Follow- up after surgery, months	Postoperative course
							pre-op	post-op		
1	F/55	Dysphotopsia (negative and positive)	Multiple glaucoma surgeries	Occlusive contact lens	Pseudophakic	L	5/300	LP temporal	3	Evisceration
2	F/48	Intractable diplopia	Amblyopia; unilateral high myopia, Graves orbitopathy; retinal detachment surgery	Strabismus surgery	Phakic	R	1/60	LP	4	Enucleation
3	F/52	Intractable diplopia	Orbital cellulitis (abscess drainage and medial wall decompression); restrictive ocular motility	Occlusive contact lens	Phakic	L	0.6	LP superior at night	5	Elimination of diplopia; mild postoperative uveitis; discharged
4	M/74	Metamorphopsia	Recurrent retinal detachment (twice vitrectomy); secondary glaucoma	Occlusive eye patch	Pseudophakic	L	1/300	NLP	1	Very satisfied; discharged
5	F/83	Dysphotopsia	Retinal detachment surgery R eye (multiple times)	Occlusive contact lens	Pseudophakic	R	LP	LP	14	Satisfied, acceptable light perception; mild postoperative uveitis
6	F/51	Intractable diplopia	Strabismus surgeries, severe ocular surface syndrome	Prisms; atropine; monovision; sclera lens; occlusive contact lens	Phakic	R	1.0	LP	3	Elimination of diplopia, acceptable light perception; discharged

F, female; M, male; R, right; L, left; LP, light perception; NLP, non-light perception.