

A case of recurrent varicose veins due to the multiple fistulas from superficial femoral artery

SAGE Open Medical Case Reports
Volume 8: 1–4
© The Author(s) 2020
Article reuse guidelines:
sagepub.com/journals-permissions
DOI: 10.1177/2050313X20926423
journals.sagepub.com/home/sco



Satoshi Watanabe^{id}, Takafumi Tsuji, Shinya Fujita, Soji Nishio and Eisho Kyo

Abstract

Recurrent varicose veins are considered to be caused by the recurrence of reflux but rarely may be secondary to other pathologies. A 39-year-old man complained of right lower leg skin pigmentation, pain and fatigue for several years. Duplex ultrasound revealed that the great saphenous vein diameter at the saphenofemoral junction level was 7.7 cm, and at the knee medial level was 14.4 cm. The reflux time at the proximal great saphenous vein level was 1.85 s. Endovenous laser ablation for dilated and refluxed great saphenous vein was performed. However, 1 year later, the symptoms recurred. Duplex ultrasound suspected abnormal arterial flow from the right superficial femoral artery to the recanalized segment of previously ablated great saphenous vein and anterior accessory saphenous vein. One month later, despite the successful re-endovenous laser ablation, the symptoms recurred. Computed tomography angiography showed three fistulous vessels from superficial femoral artery to anterior accessory saphenous vein. Combined treatments with endovenous laser ablation and coil embolization was performed. Ultimately, the fistulas were obliterated and the patient remained free of symptoms. Varicose veins due to the fistulas from superficial femoral artery are rare and difficult to diagnose but can be entirely treated with the percutaneous approach.

Keywords

Varicose veins, arteriovenous fistula, EVLA, coil embolization

Date received: 27 August 2019; accepted: 20 April 2020

Introduction

Lower limb varicose veins are common and early clinical sign of chronic venous disease (CVD) and one of the common diseases in vascular surgery. Varicose veins have been reported to affect 30% of the adult population.¹ In advanced stages, varicose veins may lead to ulcers and thrombosis, posing a serious threat to health and quality of life.² Varicose veins, edema, skin pigmentation, and ulcers are the major clinical signs of CVD. Primarily, varicose veins are considered to be caused by valvular dysfunction but rarely may be secondary to other pathologies.³ This case revealed the unusual secondary causes of varicose veins.

Case report

A 39-year-old man, a sports gym manager, complained of right lower leg skin pigmentation, pain and fatigue for several years. Duplex ultrasound showed dilatation and reflux of both right great saphenous vein (GSV) and small saphenous vein (SSV). The GSV diameter at the saphenofemoral junction

(SFJ) level was 7.7 mm, and at the knee medial level was 14.4 mm. The reflux time at the proximal GSV level was 1.85 s. The Clinical-Etiology-Anatomy-Pathophysiology classification was C4a and venous clinical severity score was 12. Endovenous laser ablation (EVLA) (using a 1470 nm diode laser (LEONALD1470; Biolitec, Bonn, Germany) with a radial 2ring fibre ELVeS™ Radial 2ring™ fibre; Biolitec)) was performed for GSV from 2 cm distal to the SFJ to below knee level under 250 mL of tumescent local anaesthesia (0.9% saline 500 mL, 2% lidocaine 30 mL, 0.1% adrenaline 1 mL, and 7% sodium bicarbonate 20 mL) with ultrasound guidance. Ablation length was 49.5 cm with linear endovenous energy density of 70 J/cm. Similarly, EVLA was performed for SSV from 2 cm distal to the saphenopopliteal junction (SPJ) to

Department of Cardiology, Kusatsu Heart Center, Kusatsu, Japan

Corresponding Author:

Satoshi Watanabe, Department of Cardiology, Kusatsu Heart Center, Komaizawa-cho 407-1, Kusatsu 525-0014, Shiga, Japan.

Email: watanabe@kusatsu-heartcenter.co.jp

Twitter handle: @YoruSuichuPools



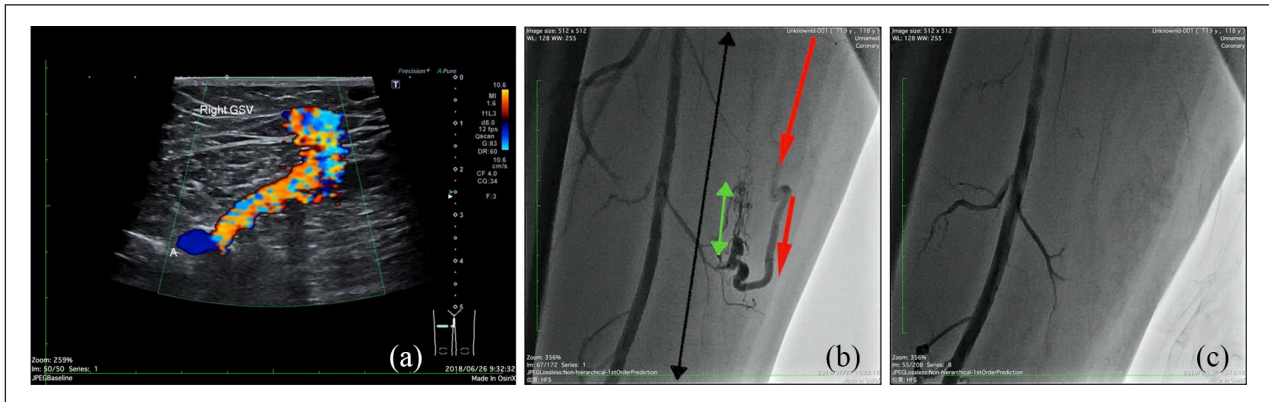


Figure 1. Abnormal arterial flow to the recanalized segment of previously ablated great saphenous vein (GSV) from the right superficial femoral artery (SFA) (a). Under the guidance of arteriography, endovenous laser ablation (EVLA) for two anterior accessory saphenous veins (AASV) was performed (red arrows). Black arrow indicates where ablation of the great saphenous vein (GSV) was previously performed. Green arrow indicates the recanalized segment of previously ablated GSV (b). A final angiogram showed reduced abnormal flow and no inflow to AASVs from SFA (c).

below knee level. On the next day, there were no complications, including endovenous heat-induced thrombosis.

One year later, the patient presented to our outpatient clinic because of recurrent symptoms. Duplex ultrasound suspected abnormal arterial flow from the right superficial femoral artery (SFA) to the recanalized segment of previously ablated GSV and anterior accessory saphenous vein (AASV) (Figure 1(a)). EVLA was performed for two segments of the AASV using arteriographic guidance (Figure 1(b)). A final angiogram showed reduced abnormal flow and no inflow to AASVs from SFA (Figure 1(c)). One month later, despite the successful closure of AASVs, Duplex ultrasound suggested multiple fistulous flows from SFA to post-EVLA-AASVs. Computed tomography angiography confirmed the same findings (Figure 2). We tried to treat using a percutaneous approach. First, EVLA for the recanalized AASV was performed. Then, a total of 10 coils (2 Figure 8-18 Fibered Platinum Coils 2 mm x 5 mm + 1 VortX™ Diamond-18 Fibered Platinum Coils 3 mm x 3.3 mm + 1 Straight-18 Fibered Platinum Coils 5 mm for the proximal fistula, 2 Figure 8-18 2 mm x 5 mm for the middle fistula, and 1 Figure 8-18 2 mm x 5 mm + 2 VortX™ Diamond-18 3 mm x 3.3 mm + 1 Straight-18 5 mm for the distal fistula, Boston Scientific, Marlborough, MA) were implanted to the visible three fistulas (Figure 3(a)). Final arteriography from SFA showed no abnormal fistulous flow to the veins (Figure 3(b)) and the patient was still free of symptoms.

Discussion

Primary venous disease commonly results in superficial venous incompetence, particularly located at the connecting points between deep and superficial veins, SFJ, SPJ, or perforating veins. Incompetence (or reflux) of the superficial venous system may result in venous hypertension and the

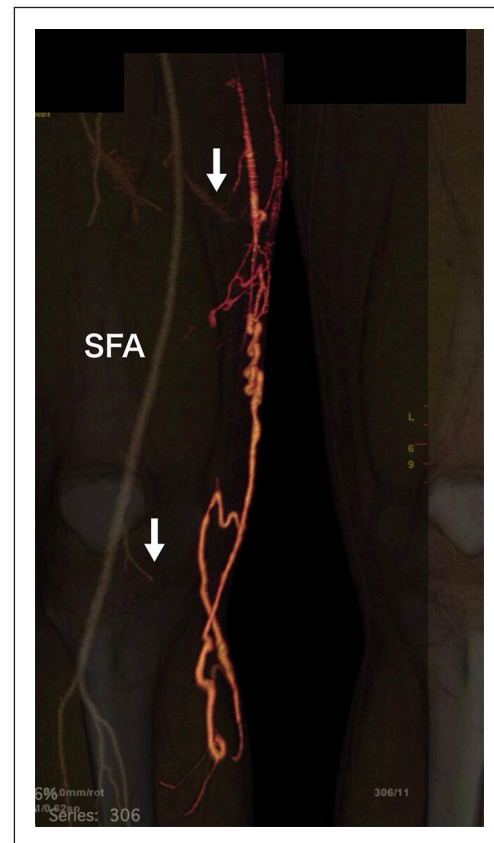


Figure 2. Computed tomography angiography shows the location of superficial recurrent varicose veins, the superficial femoral artery (SFA) and the arteriovenous connection. White arrow indicates two of the detective fistulous connections from SFA to anterior accessory saphenous vein (AASV).

development of signs and symptoms of CVD. However, secondary varicose veins usually occur as a result of previous deep venous thrombosis, although trauma and intra-abdominal

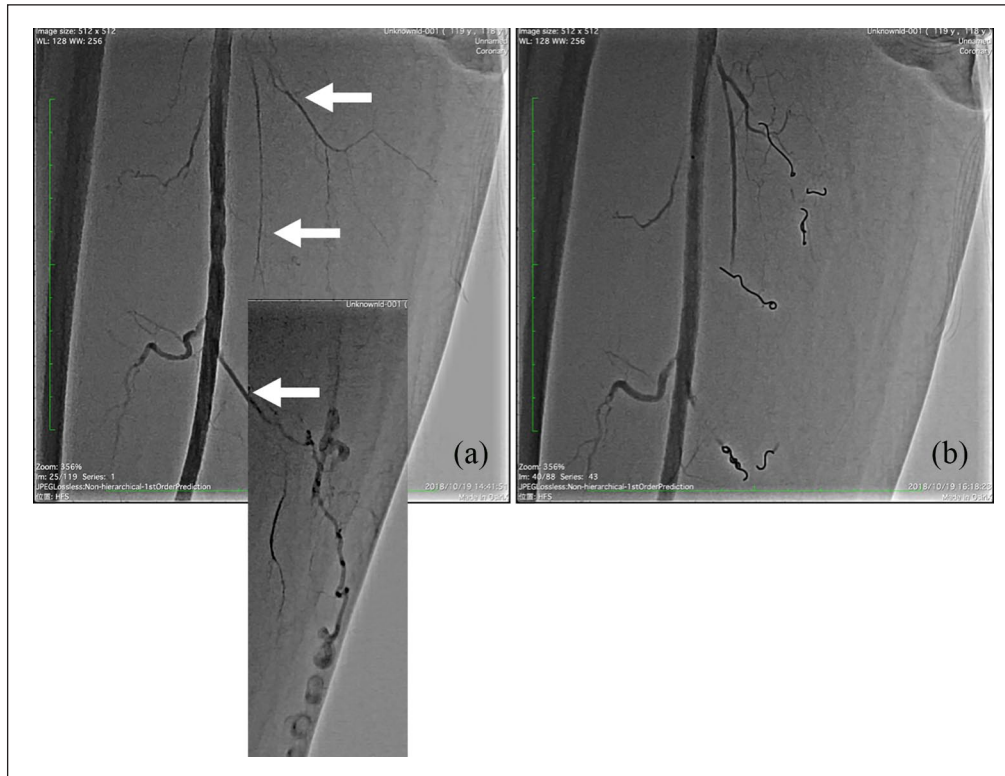


Figure 3. A total of 10 coils were implanted to the visible three fistulas (a). Final arteriography from superficial femoral artery (SFA) showed no abnormal fistulous flow to the veins (b).

masses may also result in impaired venous drainage and the development of CVD.³

Nevertheless, secondary varicose veins due to the development of arteriovenous fistulas are extremely rare. Initially, we considered an iatrogenic cause related to the original EVLA. In the present case, arteriography showed at least three fistulous flows from SFA. If the entry needle or laser fibre had inadvertently injured the artery, there could be shunting to the vein. However, it would be very unlikely that there would be three fistulas if this had been the mechanism. The high laser-tip temperature could cause vein wall perforation with concomitant arterial injury to an adjacent vessel. This risk is presumably greater if tumescent anaesthesia fails to separate the vein from an arterial branch even when laser energy is within the recommended range. It is also conceivable that needle puncture of the vein and a small artery may occur during administration of tumescent anaesthesia. In the present case, we carefully administered a total of 250 mL of tumescent local anaesthesia into the saphenous compartment under the ultrasound guidance. Then, we treated 49.5 cm length of GSV with linear endovenous energy density (LEED) of 70 J/cm. Therefore, it is unlikely to consider that our procedure caused these fistulas. A case of a false aneurysm arising from a branch of the inferior epigastric artery after EVLA was previously reported⁴; however, this aneurysmal formation did not connect to the vein. The most probable explanation for the development of the false aneurysm is direct trauma to the artery by the needle used to inject

the tumescent anaesthesia. In this case, the fistulas were completely vessel-like shape without aneurysmal formation. Theivacumar and Gough⁵ experienced arteriovenous fistulas following EVLA caused by concomitant venous and arterial wall thermal injury or needle trauma during administration of tumescent anaesthesia.

Although the underlying pathologic mechanism and subsequent development of these secondary varicose veins due to arteriovenous fistulas were not entirely known, the clinical appearance and symptoms are similar to those of primary varicose veins. To the best of our knowledge, this is the first report of recurrent varicose vein arteriographically detected arteriovenous fistulas after EVLA. Re-EVLA of the vein was not sufficient to maintain the occlusion against the arterial pressure. Therefore, to obtain complete recovery, coil embolization was considered to be reasonable in this case. Despite the useful results of combined coil embolization and foam sclerotherapy for varicose veins,⁶ in the present case, embolization of the feeding vessels was considered to be crucial and reasonable.

Conclusion

Secondary varicose veins due to the fistulas from SFA are rare and difficult to diagnose but can be entirely treated with the combined bilateral percutaneous approach from arteries and veins.

Learning objectives

Recurrent varicose veins within a short period after interventional treatment may imply an unusual secondary cause including arteriovenous fistulas. It should be considered such a complication with the widespread clinical use of EVLA.

Declaration of conflicting interests

The author(s) declared no potential conflicts of interest with respect to the research, authorship, and/or publication of this article.

Ethical approval

Our institution does not require ethical approval for reporting individual cases or case series.

Funding

The author(s) received no financial support for the research, authorship, and/or publication of this article.

Informed consent

Written informed consent was obtained from the patient for their anonymized information to be published in this article.

ORCID iD

Satoshi Watanabe  <https://orcid.org/0000-0003-3917-0894>

References

1. Eberhardt RT and Raffetto JD. Chronic venous insufficiency. *Circulation* 2014; 130: 333–346.
2. Wittens C, Davies AH, Bækgaard N, et al. Editor's choice – management of chronic venous disease: clinical practice guidelines of the European Society for Vascular Surgery (ESVS). *Eur J Vasc Endovasc Surg* 2015; 49: 678–737.
3. Bhatti AM, Siddique K, Bashir RA, et al. Unusual causes of secondary varicose veins. *J Ayub Med Coll Abbottabad* 2013; 25(3–4): 81–85.
4. Ostler AE, Holdstock JM, Harrison CC, et al. Arterial false aneurysm in the groin following endovenous laser ablation. *Phlebology* 2015; 30(3): 220–222.
5. Theivacumar NS and Gough MJ. Arterio-venous fistula following endovenous laser ablation for varicose veins. *Eur J Vasc Endovasc Surg* 2009; 38(2): 234–236.
6. Kayssi A, Oreopoulos G, Tan KT, et al. Combined coil embolization and foam sclerotherapy for the management of varicose veins. *Ann Vasc Surg* 2017; 38: 293–297.