

Papillary thyroid carcinoma with tracheal invasion

A case report

Jiateng Zhang, MD*, Chao Fu, Kefei Cui, Xiao Ma

Abstract

Rationale: Compared with most malignant tumors, papillary thyroid carcinoma (PTC) is usually associated with favorable survival and low recurrence rate. The prognostic factors of PTC include age, sex, tumor size, enlarged lymph nodes, and extrathyroidal extension. Among the extrathyroidal extension, upper aerodigestive tract (ADT) invasion by PTC is a marker of more aggressive tumor behavior, defining a subpopulation of patients at a greater risk of recurrence and death.

Patient concerns: A 61-year-old woman had a cervical mass that was slowly growing for three years. Additionally, she had haemoptysis of 1-year duration. During the month prior to her visit, she had difficulty breathing.

Diagnosis: Neck ultrasonography (US) and thyroid computed tomography (CT) images both showed a well-defined calcified mass on the left lobe of the thyroid gland. Additionally, the thyroid CT revealed that part of the mass protruded into the lumen which resulted in the thickening on the left side of the trachea. Accordingly, her diagnoses were as follows: firstly, a solid mass on the left lobe of the thyroid gland with tracheal compression; and finally, the space-occupying airway lesion.

Interventions: She underwent a bronchoscopic examination, which revealed a mass blocking most of the upper endoluminal trachea. Thus, the mass was resected at the upper tracheal segment, followed by electrocautery and argon plasma coagulation treatment. She was then transferred to the Thyroid Surgery Department. Thyroid surgeons took the surgical type of bilateral subtotal thyroidectomy + exploration of bilateral recurrent laryngeal nerve + dissection of the lymph node in neck central area + circumferential sleeve resection + end-to-end anastomosis + tracheotomy in the patient.

Outcomes: After surgery, she recovered well without any local recurrence or distant metastasis.

Lessons: When patients with PTC have haemoptysis, hoarseness, dyspnea, or any other symptoms, and the imaging examinations reveal a space-occupying lesion in the thyroid and airway, clinicians should focus on PTC with tracheal invasion, a bronchoscopic examination must be immediately performed because the subsequent surgical management depends on the degree of tracheal invasion.

Abbreviations: ADT = aerodigestive tract, CT = computed tomography, MRI = magnetic resonance imaging, PET-CT = positron emission tomography-computed tomography, PTC = papillary thyroid carcinoma, US = ultrasonography.

Keywords: papillary thyroid carcinoma, thyroid tumor, tracheal invasion

Editor: N/A.

Given that our study wasn't a clinical experimental research, and it didn't involve the human biological experiment. Thus the study didn't need the approval of the ethics committee. Informed consent has been obtained from the patient, which has been contained in this study.

The authors declare that there is no conflicts of interest.

Department of Ultrasound, The First Affiliated Hospital of Zhengzhou University, Zhengzhou 450052, China.

* Correspondence: Jiateng Zhang, Department of Ultrasound, The First Affiliated Hospital of Zhengzhou University, 1 East Jianshe Road, Erqi District, Zhengzhou, Henan, China (e-mail: 2822572517@qq.com).

Copyright © 2019 the Author(s). Published by Wolters Kluwer Health, Inc. This is an open access article distributed under the terms of the Creative Commons Attribution-Non Commercial-No Derivatives License 4.0 (CCBY-NC-ND), where it is permissible to download and share the work provided it is properly cited. The work cannot be changed in any way or used commercially without permission from the journal.

How to cite this article: Zhang J, Fu C, Cui K, Ma X. Papillary thyroid carcinoma with tracheal invasion. *Medicine* 2019;98:38(e17033).

Received: 29 November 2018 / Received in final form: 13 July 2019 / Accepted: 12 August 2019

<http://dx.doi.org/10.1097/MD.00000000000017033>

1. Introduction

PTC is a common endocrine malignant tumor around the world. On account of the scarce regional infiltration, PTC is generally regarded as a curable disease. Thus, most patients have favorable postoperative survival. The mortality rate of PTC is estimated to be between 11% and 17%.^[1] However, in some cases of PTC with regional infiltration, the postoperative outcomes could be considerable morbidity and mortality. The most common metastatic sites of thyroid carcinoma are the lung, bone, mediastinal lymph nodes, pelvic area, brain, and liver. Thyroid cancer rarely invades the trachea, but if it does, airway bleeding and obstruction can lead to death.^[2] Here, we report a case of PTC with tracheal invasion in a 61-year-old woman.

2. Case report

A 61-year-old woman incidentally noticed a mass in her neck 3 years ago. Soon after, she began to present haemoptysis for a year. Further, her physical condition extraordinarily worsened over the course of the month prior to her visit and she had

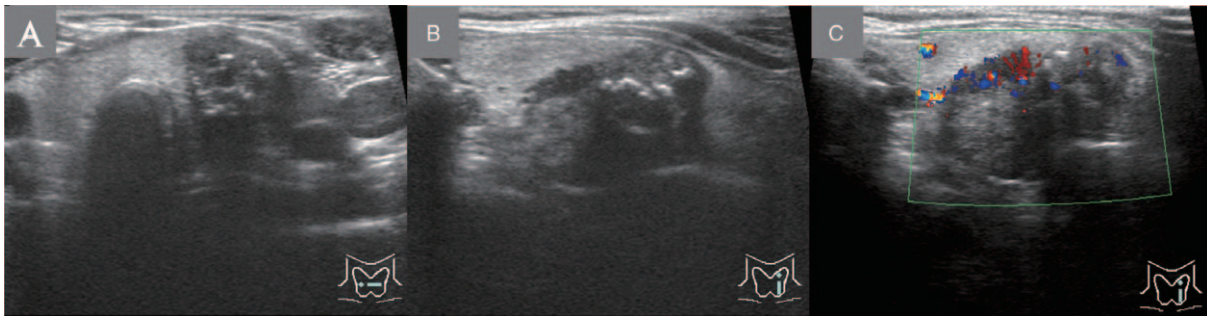


Figure 1. Neck ultrasonogram. (A) The cross-section showed that part of the trachea was surrounded by a solid mass; (B) the longitudinal section showed a solid mass with calcifications on the middle and lower part of the left lobe of the thyroid gland; (C) the longitudinal section showed that the mass had a second-degree blood supply.

difficulty in breathing. Meanwhile, the mass continued to slowly grow before she sought medical care.

When she visited our hospital, we found a solid mass of roughly two centimeters in diameter with unclear boundary on the left lobe of the thyroid gland. And she felt no pain as we palpated the mass. The mass could easily move upward and downward when she swallowed. No enlarged cervical lymph node was noted. According to the ultrasonogram, the left lobe of the thyroid gland was enlarged, and a hypoechoic solid mass with irregular shape could be detected in the middle and lower part of the left lobe of the thyroid gland. The mass appeared to be partially wrapped around the trachea, and its size was $2.8 \times 1.8 \times 1.9$ cm (vertical diameter \times transverse diameter \times anteroposterior diameter). Not only was the internal echo inhomogeneous but the inner part of the mass showed a cluster distribution of dot-like calcifications, which were accompanied with acoustic shadows. Additionally, the mass had a second-degree blood supply. Thus, the US indicated that there was a solid mass with calcifications on the left lobe of the thyroid gland (Thyroid Imaging Reporting and Data System [TI-RADS] category 5) (Figure 1).

The thyroid CT image showed a well-defined calcified mass on the left lobe of the thyroid gland, and the mass partially protruded into the lumen, resulting in the thickening on the left side of the trachea. The mass also had obvious enhancement (Figure 2). The fiberoptic bronchoscopy showed a mass blocking most of the upper endoluminal trachea (Figure 3). Pathologic features showed a papillary infiltrating growth of the lamina

propria of the cricotracheal mucosa, which revealed PTC infiltrating the trachea. Accordingly, the Shin's staging of tracheal invasion was stage IV (Figure 4).

The cervical mass partially wrapped around the trachea resulted in severe tracheostenosis. As this could potentially cause asphyxia at any moment, the thyroid surgeons suggested her to transfer to the Respiratory Medicine Department to receive the appropriate therapy. The respiratory physicians recommended her undergo positron emission tomography-computed tomography (PET-CT) and tracheal reconstruction.

PET-CT revealed a soft-tissue mass with intense radioactivity on the left lobe of the thyroid gland. The maximum values of CT and standardized uptake were 497 U and 26.9, respectively. The size of the mass was $2.5 \times 2.5 \times 3.0$ cm (vertical diameter \times transverse diameter \times anteroposterior diameter). Hyperdense calcified shadows could be detected in the mass, and part of the mass protruded into the endoluminal trachea, hence the trachea was compressed to the right side and appeared to be obviously stenotic (Figure 5).

Therefore, according to the above imaging findings, respiratory physicians considered that it was necessary for her to receive a bronchoscopic treatment. Tumor resection was performed by bronchoscopy on the upper tracheal segment to alleviate the tracheal obstruction. And the resected tissue was subjected to histopathological examination. Then she was transferred to the Thyroid Surgery Department, and thyroid surgeons took the

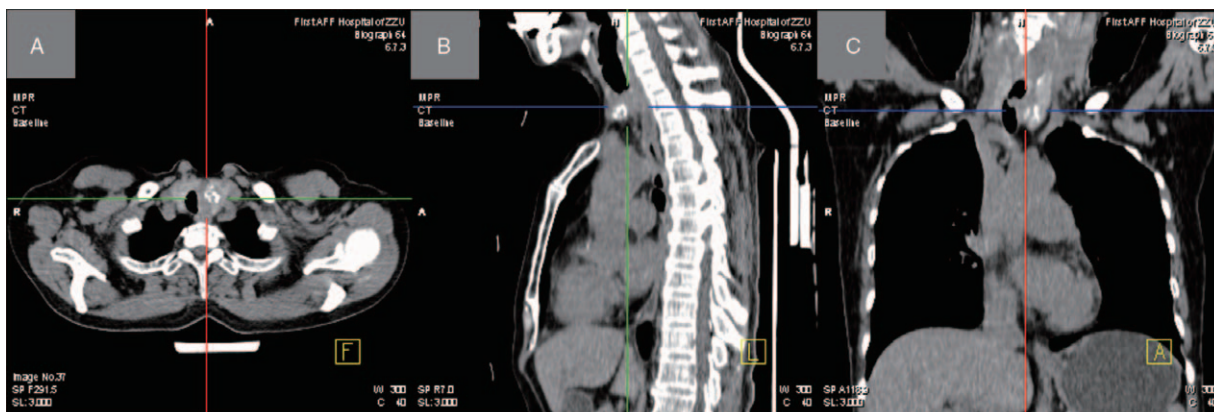


Figure 2. Thyroid computed tomography scan. (A) The axial image showed a well-defined calcified mass on the left lobe of the thyroid gland; (B) the sagittal image showed that the mass blocked most of the upper endoluminal trachea; (C) the coronal image showed a thickened area on the left side of the trachea and part of the mass protruding into the lumen.

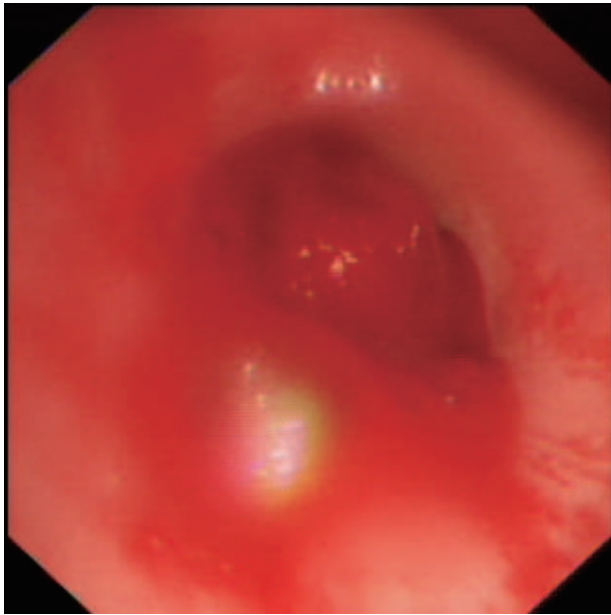


Figure 3. Bronchoscopy appearance. A neoplasm blocked most of the upper endoluminal trachea.

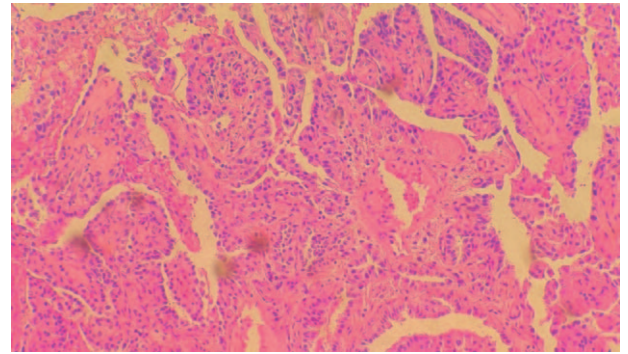


Figure 4. Microscopic appearance. Pathological features revealed a papillary infiltrating growth of the lamina propria of the cricotracheal mucosa. H&E= high-power field.

surgical type of bilateral subtotal thyroidectomy + exploration of bilateral recurrent laryngeal nerve + dissection of the lymph node in neck central area + circumferential sleeve resection + end-to-end anastomosis + tracheotomy in the patient. The operation went smoothly, but she presented with fluid exudation in the cervical incision because of wound infection postoperatively, and the situation improved after changing the wound dressing. After the surgery, she presented secondary hypocalcaemia; therefore calcium was given intravenously during the perioperative period. After she was discharged, surgeons advised her to take calcium, vitamin D and levothyroxine tablets, and receive ¹³¹I treatment postoperatively. So far, we have followed up her postoperative recovery for approximately one and a half years, and she recovered well without any local recurrence or distant metastasis during this period.

3. Discussion

PTC is well known for its favorable prognosis and survival. Although the upper ADT is close to the thyroid gland, the incidence of invasion by PTC is extremely low. Whereas morbidity and mortality will rise when the upper ADT is invaded.^[3] The International Union Against Cancer classifies the upper ADT invasion as the T4a category.^[4]

The extrathyroidal extension is the extension of the primary thyroid tumor outside the thyroid capsule, in which the tumor invades the adjacent structures including striated muscles, trachea, larynx, jugular vein, carotid artery, esophagus, and recurrent laryngeal nerve. Extrathyroidal extension is universally considered a conspicuously adverse prognostic factor, and its incidence in PTCs is about 5%–34%.^[5] The TNM classification is the most widely-used staging system for extrathyroidal extension worldwide (Table 1).

Failure to control the extrathyroidal extension in thyroid tumors can cause a series of complications and eventual death. In particular, tumors with tracheal invasion can lead to airway obstruction which is the direct cause of most deaths in the case of thyroid tumors. Preoperative clinical manifestations of tracheal invasion include haemoptysis, hoarseness, presence of the cervical mass, and shortness of breath.^[7] The worst condition

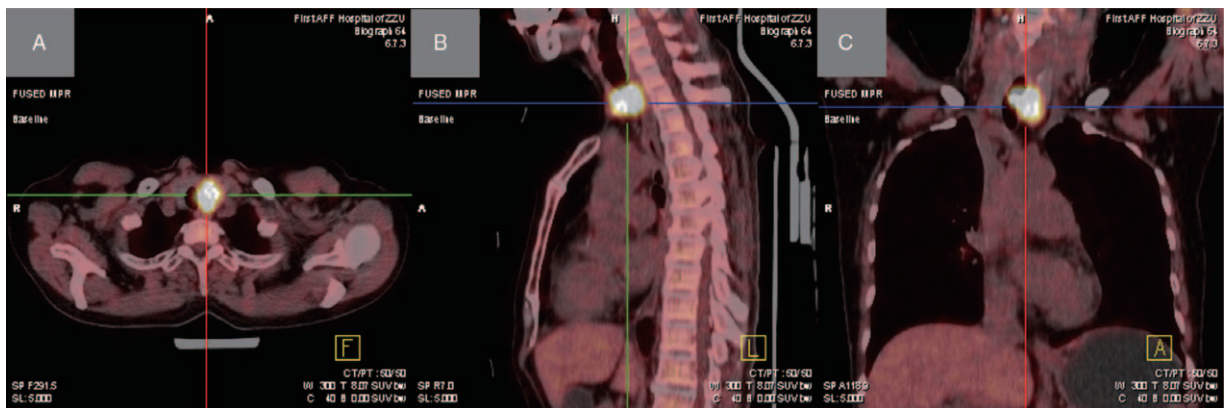


Figure 5. Positron emission tomography–computed tomography scan. (A) The axial image showed a soft-tissue mass with intense radioactivity on the left lobe of the thyroid gland; (B) the sagittal image showed an intensely radioactive soft-tissue mass blocking most of the upper endoluminal trachea; (C) the coronal image showed that the trachea was compressed to the right side, and part of the mass protruded into the lumen, which can result in the stenosis observed in that area of the trachea.

Table 1**TNM classification system for well-differentiated thyroid cancer category description.**

Tx	Primary tumor cannot be assessed
T0	No evidence of primary tumor
T1	Tumor 2 cm or less in greatest dimension limited to the thyroid
T2	Tumor more than 2 cm but not more than 4 cm in greatest dimension limited to the thyroid
T3	Tumor more than 4 cm in greatest dimension limited to the thyroid or any tumor with minimal extrathyroidal extension (e.g., extension to sternothyroid muscle or perithyroid soft tissues)
T4a	Tumor of any size extending beyond the thyroid capsule to invade subcutaneous soft tissues, larynx, trachea, esophagus, or recurrent laryngeal nerve
T4b	Tumor invades prevertebral fascia or tumor invades prevertebral fascia or encases carotid artery or mediastinal vessels
Nx	Regional lymph nodes can't be assessed
N0	No regional lymph nodes metastasis
N1a	Metastasis to level VI (pretracheal, paratracheal, and prelaryngeal/Delphian lymph nodes)
N1b	Metastasis to unilateral, bilateral, or contralateral cervical or superior mediastinal lymph nodes
Mx	Distant metastasis cannot be assessed
M0	No distant metastasis
M1	Distant metastasis

Reorganized of the sixth edition of the American Joint Committee on Cancer/International Union Against Cancer (AJCC/UICC) TNM classification system of primary thyroid tumor.^[6]

of PTC with tracheal invasion is when the tumor has extended to the endoluminal trachea, with an incidence of 0.5%–1.5%.^[8]

McCaffrey^[11] assumed that the primary thyroid tumor could directly invade the trachea, but this usually occurred as a result of extension from a metastatically involved paratracheal lymph node. However, Shin et al^[9] thought that the direct invasion of PTC is also a significant invasion pathway. They proposed that the penetration of PTC into the trachea was either due to the proximity of the thyroid capsule and the peritracheal fascia or the presence of potential lines of weakness in the tracheal wall where the vessels penetrate perpendicular to the lumen, allowing pathways of invasion by mechanical shearing forces. Once the thyroid tumor transgressed the glandular capsule, it could proceed to invade the trachea, esophagus, and larynx. The upper ADT invasion was described as a gradual process that started off with the outer layer, moving deeper, and finally entering the intraluminal mucosa.^[10] Shin et al^[9] described a staging of tracheal invasion based on the pathologic features, which were defined by the degree of the cricoid cartilage and intraluminal tracheal invasion (Table 2).

Shimamoto et al^[11] revealed that there is no prognostic difference between the invasion of esophagus and trachea, but the aggressiveness of tracheal infiltration seems to be closely related to the degree of esophageal infiltration, and the invasion of larynx indicates that the disease has evolved into an advanced stage. Kim et al^[10] showed that the simultaneous involvement of the trachea and esophagus were associated with higher local recurrence, and laryngeal involvement was related to the lower disease-specific survival.

Imaging examinations, including US, CT, and magnetic resonance imaging (MRI), are commonly performed in thyroid tumors with tracheal invasion. US have the unique advantage over the other imaging examinations as it allows the simultaneous evaluation of thyroid tumor invasion and cervical lymph nodes

metastasis. Park et al^[12] proved that the US performed well in showing the extension of primary thyroid tumors and diagnosing the preoperative staging of thyroid tumors with lymph nodes metastasis. The American Thyroid Association's Management Guidelines declared that clinicians should take the preoperative neck US for patients with differentiated thyroid carcinoma.^[13]

Yamamura et al^[14] have summarized different types of tracheal resections of 24 patients with differentiated thyroid carcinoma infiltration and retrospectively reviewed the preoperative US features with postoperative histologic findings. They concluded that the US features were consistent with the pathologic findings, and the total accuracy of US was 83.3%. Thus, the US should be the first choice to establish the diagnosis of thyroid tumors with tracheal invasion even at an early stage.

MRI is also a good choice for examining thyroid tumors with tracheal invasion. The high accuracy of MRI is attributed to its superior soft-tissue contrasting characteristic. Features of tracheal infiltration on MRI images include the endoluminal mass and soft-tissue signals in tracheal cartilage. In one study,^[15] when thyroid tumors invaded the trachea, esophagus, and carotid artery, the prediction accuracy of MRI was 88%, 94%, and 91%, respectively. Moreover, MRI can diagnose thyroid tumors invading the adjacent structures simply by measuring tumor circumferences on images.^[16]

CT is another imaging examination for assessing thyroid tumors with tracheal invasion. Seo et al^[17] demonstrated that CT had better accuracy (83.2%–98.8%) and specificity (89.8%–99.4%) for diagnosing thyroid tumors invading adjacent structures. However, the sensitivity of CT was lower than that of US and MRI, which ranged from 28.6% to 78.2%.

The bronchoscopic examination is generally performed in patients suspected of having thyroid tumors with tracheal invasion. The extent of invasion is further assessed by histopathologic analysis on the resected tissue. Bronchoscopy is quite valuable to measure the extent of laryngotracheal invasion and allow the direct observation of the changes in the bronchial mucosa. Randolph et al^[18] advocated that the preoperative bronchoscopy should be examined for patients with invasive thyroid tumors or vocal cord paralysis.

Surgical managements of tracheal invasion consist of the shave excision of the affected tissue and full-thickness tracheal resection. Shave excision is only suitable for the cases of superficial invasion of the cricoid cartilage and in which thyroid

Table 2**Shin's staging of tracheal invasion.**

Stage 0	When there is no ETE
Stage I	For extra thyroidal disease abutting the airway
Stage II	When invasion of the cartilage rings is present
Stage III	When disease invades the submucosa of the trachea
Stage IV	When disease involves the mucosa of the trachea

ETE = extrathyroidal extension.

tumors have not extended to the cricotracheal lumen.^[19] Once the intraluminal trachea is invaded, patients will require the full-thickness tracheal resection by means of a window resection or sleeve resection.^[20] For patients with involvement of less than four tracheal rings and endotracheal involvement of less than 50% of the tracheal rings, the window resection of trachea can be adopted. In cases of involvement of small areas of the trachea, the section with the removed tracheal wall can be pulled up and closed. After window resection, the defect can be repaired with sternocleidomastoid myoperiosteal, pectoralis major myocutaneous, or anterior cervical flap and artificial stent.^[21] Circumferential sleeve resection is adopted for the cases with significant cricotracheal infiltration, for patients with thyroid carcinoma invading more than 50% of the tracheal rings, tracheal involvement of 4–6 cartilage rings and Shin's stage IV, while window resection is not suitable in these cases. At this time, circumferential sleeve resection+end-to-end anastomosis should be considered. This method can ensure adequate resection range and does not require low-level preventive tracheotomy, which is only considered in special conditions such as bilateral vocal cord paralysis, anastomotic dehiscence or dyspnoea.^[22]

Therefore, surgery is the first treatment for thyroid tumors infiltrating the trachea. Postoperative complications include the following: secondary wound infection, which can be treated with local debridement and dressing changes; formation of mouth-floor fistula, which can be treated with debridement and pressure dressing; secondary hypocalcaemia, which can be treated by intravenous administration of calcium during the perioperative period, followed by long-term oral administration of calcium tablets and vitamin D; if tracheotomy is performed, extubating may fail due to the small anterior-posterior diameter of the trachea at the upper edge of the tracheotomy. Whether ¹³¹I treatment should be performed after surgery and the specific indications for ¹³¹I treatment remain controversial. The main question is whether low-risk patients benefit from such treatment. Most scholars still recommend that patients with laryngotracheal invasion by differentiated advanced T4 thyroid cancer receive ¹³¹I treatment after surgery if it is tolerable to them. This could be due to the fact that postoperative ¹³¹I treatment can reduce the risk of recurrence and improve the survival rate.^[23,24]

4. Conclusion

Overall, the postoperative survival rate of patients with PTC is generally excellent. If patients have the clinical manifestations of tracheal invasion, they should immediately undergo imaging examinations such as US, CT, or MRI. The bronchoscopic treatment must be performed in patients if the imaging examinations reveal the presence of a PTC with tracheal invasion. The subsequent surgical approach depends on the degree of tracheal invasion. Considering that the extent of invasion will dictate the following steps for surgical management as well as prognosis, it is critical to diagnose the PTC with tracheal invasion as early as possible.

Author contributions

Formal analysis: Chao Fu.

Resources: Kefei Cui.

Supervision: Xiao Ma.

Writing – original draft: Jiateng Zhang.

Writing – review & editing: Jiateng Zhang.

References

- [1] McCaffrey TV, Lipton RJ. Thyroid carcinoma invading the upper aerodigestive system. *Laryngoscope* 1990;100:824–30.
- [2] Cody HS3rd, Shah JP. Locally invasive, well-differentiated thyroid cancer. 22 years' experience at Memorial Sloan-Kettering Cancer Center. *Am J Surg* 1981;142:480–3.
- [3] Djalilian M, Beahrs OH, Devine KD, et al. Intraluminal involvement of the larynx and trachea by thyroid cancer. *Am J Surg* 1974;128:500–4.
- [4] Sobin LH, Wittekind Ch<Eds>. TNM Classification of Malignant Tumours. New York: Wiley-Liss, Inc; 2002.
- [5] Ortiz S, Rodriguez JM, Soria T, et al. Extrathyroid spread in papillary carcinoma of the thyroid: clinicopathological and prognostic study. *Otolaryngol Head Neck Surg* 2001;124:261–5.
- [6] Greene FL, Page DL, Fleming ID, et al. *AJCC Cancer Staging Manual-Thyroid*, 77–87. New York, NY: Springer; 2002.
- [7] Gaißert HA, Honings J, Grillo HC, et al. Segmental laryngotracheal and tracheal resection for invasive thyroid carcinoma. *Ann Thorac Surg* 2007;83:1952–9.
- [8] Melliere DJ, Ben Yahia NE, Becquemin JP, et al. Thyroid carcinoma with tracheal or esophageal involvement: limited or maximal surgery? *Surgery* 1993;113:166–72.
- [9] Shin DH, Mark EJ, Suen HC, et al. Pathologic staging of papillary carcinoma of the thyroid with airway invasion based on the anatomic manner of extension to the trachea: a clinicopathologic study based on 22 patients who underwent thyroidectomy and airway resection. *Hum Pathol* 1993;24:866–70.
- [10] Kim H, Jung HJ, Lee SY, et al. Prognostic factors of locally invasive well-differentiated thyroid carcinoma involving the trachea. *Eur Arch Otorhinolaryngol* 2016;273:1919–26.
- [11] Shimamoto K, Satake H, Sawaki A, et al. Preoperative staging of thyroid papillary carcinoma with ultrasonography. *Eur J Radiol* 1998;29:4–10.
- [12] Park JS, Son KR, Na DG, et al. Performance of preoperative sonographic staging of papillary thyroid carcinoma based on the sixth edition of the AJCC/UICC TNM classification system. *Am J Roentgenol* 2009;192:66–72.
- [13] Cooper DS, Doherty GM, Haugen BR, et al. Management guidelines for patients with thyroid nodules and differentiated thyroid cancer. *Thyroid* 2006;16:109–42.
- [14] Yamamura N, Fukushima S, Nakao K, et al. Relation between ultrasonographic and histologic findings of tracheal invasion by differentiated thyroid cancer. *World J Surg* 2002;26:1071–3.
- [15] Takashima S, Matsushita T, Takayama F, et al. Prognostic significance of magnetic resonance findings in advanced papillary thyroid cancer. *Thyroid* 2001;11:1153–9.
- [16] Takashima S, Takayama F, Wang Q, et al. Differentiated thyroid carcinomas. Prediction of tumor invasion with MR imaging. *Acta Radiol* 2000;41:377–83.
- [17] Seo YL, Yoon DY, Lim KJ, et al. Locally advanced thyroid cancer: can CT help in prediction of extrathyroidal invasion to adjacent structures? *Am J Roentgenol* 2010;195:W240–4.
- [18] Randolph GW, Kamani D. The importance of preoperative laryngoscopy in patients undergoing thyroidectomy: voice, vocal cord function, and the preoperative detection of invasive thyroid malignancy. *Surgery* 2006;139:357–62.
- [19] Moritani S. Surgical management of cricotracheal invasion by papillary thyroid carcinoma. *Ann Surg Oncol* 2015;22:4002–7.
- [20] Ebihara M, Kishimoto S, Hayashi R, et al. Window resection of the trachea and secondary reconstruction for invasion by differentiated thyroid carcinoma. *Auris Nasus Larynx* 2011;38:271–5.
- [21] Kebebew E, Clark OH. Locally advanced differentiated thyroid cancer. *Surg Oncol* 2003;12:91–9.
- [22] Shimizu J, Arano Y, Yachi T, et al. A 90-year-old woman with trachea-invading thyroid cancer requiring four-ring resection of cervical trachea because of airway stenosis. *Ann Thorac Cardiovasc Surg* 2007;13:341–4.
- [23] Mayson SE, Yoo DC, Gopalakrishnan G. The evolving use of radioiodine therapy in differentiated thyroid cancer. *Oncology* 2015;88:247–56.
- [24] Yang Z, Flores J, Katz S, et al. Comparison of survival outcomes following postsurgical radioactive iodine versus external beam radiation in stage IV differentiated thyroid carcinoma. *Thyroid* 2017;27:944–52.