



# NODULAR LYMPHOCYTE-PREDOMINANT HODGKIN LYMPHOMA: A RARE LYMPHOMA WITH ISOLATED HEPATIC PRESENTATION

Bruno David Freitas, Andreia Salgado Machado, Margarida Lagarto, Inês Araújo, Candida Fonseca

Serviço de Medicina Interna, Hospital de São Francisco Xavier, Centro Hospitalar de Lisboa Ocidental, Lisboa, Portugal

**Corresponding author:** Bruno David Freitas    **e-mail:** brunodavidfreitas@gmail.com

Received: 04/09/2023    Accepted: 11/09/2023    Published: 28/09/2023

**Conflicts of Interests:** The Authors declare that there are no competing interests.

**Patient Consent:** The authors obtained written informed consent from the patient.

This article is licensed under a [Commons Attribution Non-Commercial 4.0 License](#)

**How to cite this article:** Freitas B, Salgado Machado A, Lagarto M, Araújo I, Fonseca C. Nodular lymphocyte-predominant Hodgkin lymphoma: a rare lymphoma with isolated hepatic presentation. *EJCRIM* 2023;10:doi:10.12890/2023\_004061.

## ABSTRACT

Primary hepatic lymphoma (PHL) is extremely rare, accounting for less than 1% of all lymphomas, and is limited to the liver without extrahepatic involvement. A 30-year-old male was admitted in the Emergency Department complaining of weakness, fever, night sweats, significant weight loss, discrete ring alopecia, hepatomegaly, right axillary adenopathy and oedema of both legs. Laboratory evaluation showed normocytic normochromic anaemia, thrombocytosis, hyperbilirubinemia, cholestasis and increased international normalised ratio (INR). A computed tomography (CT) scan found an enlarged liver with a heterogeneous structure and moderate ascites. After admission in our ward further investigation revealed increased sedimentation velocity, ferritin and serum lactate dehydrogenase. A hepatic biopsy was performed which confirmed the diagnosis as a nodular lymphocyte-predominant Hodgkin lymphoma (NLPHL). The patient was transferred to a haematological ward and underwent chemotherapy with six cycles of R-CHOP. He is in complete remission after a year and half since the beginning of treatment. NLPHL, a very rare lymphoma, is more common in men between the third and fifth decades of life. Usually, the symptoms are very unspecific; a few patients have B symptoms at admission. This kind of presentation is also common in infectious, metabolic and autoimmune diseases, which were excluded in this case. Due to technical issues the final diagnosis was only possible due to the liver biopsy. Treatment with standard Hodgkin lymphoma protocols leads to complete remission in more than 95% of patients with NLPHL.

## KEYWORDS

Fever, cytocholelasis, primary hepatic lymphoma, nodular lymphocyte-predominant HL

## LEARNING POINTS

- Differential diagnosis of fever, especially in young patients, is very complex and complete investigation takes time, which can delay the diagnosis of malignancies such as primary hepatic lymphoma (PHL).
- PHL is very rare, and overlapping symptoms with other liver diseases can make the diagnosis very challenging.
- When the suspicion of PHL is very high, only the hepatic biopsy can lead to the correct diagnosis because the disease has no extrahepatic involvement.



## INTRODUCTION

Infiltrative liver disorders form a group of diseases of rare presentation that includes amyloidosis, granulomas, sarcoidosis and lymphomas.

The primary hepatic lymphoma (PHL) is defined as lymphoma limited to the liver without extrahepatic involvement<sup>[1]</sup>. The PHL is a rare disease accounting for less than 1% of all lymphomas.

PHL often presents with non-specific symptoms such as abdominal pain, weight loss, fatigue and hepatomegaly. Due to its rarity and overlapping symptoms with other liver diseases, PHL can be challenging to diagnose<sup>[2]</sup>. Imaging studies, including ultrasound, computed tomography (CT) scanning and magnetic resonance imaging (MRI), are commonly used to identify liver lesions and evaluate their characteristics. A definitive diagnosis is made through liver biopsy.

The aim of this report is to increase awareness of primary hepatic lymphoma due to its rarity and non-specific presentation, leading to a complex differential diagnosis.

## CASE DESCRIPTION

A 30-year-old male, melanodermic, previously healthy and without tobacco or drug use or epidemiological risk factors – namely, foreign travel or contact with wild animals – presented to the emergency department. He complained of weakness in the two weeks before, night sweats and a 10 kg weight loss over six months. On admission he was febrile, pale and had discrete ring alopecia, palpable hepatomegaly, single right axillary adenopathy and distal oedema of both legs. On laboratory evaluation, the blood count showed normocytic, normochromic anaemia, increased red blood cells distribution width, poikilocytosis, the presence of target cells and minor thrombocytosis; the biochemistry revealed a hepatic cytocholestatics with hyperbilirubinemia, a spontaneous increase of INR to 1.5 and mild proteinuria. All other blood parameters were within the reference ranges (Table 1). The study was completed with imagiological examinations such as chest radiography and abdominopelvic CT scan (Fig. 1), which showed an enlarged liver with a heterogeneous structure and no nodules, parietal gallbladder oedema, a normal size spleen with well-defined hypervascular area and moderate ascites. The patient was therefore admitted to the Internal Medicine ward for further investigation.

Infectious causes were excluded by negative urine and blood cultures (aerobic, anaerobic and mycobacteria), immunological studies (for HIV, HTLV, hepatitis A, B, C and E virus, EBV, CMV, enterovirus, parvovirus B19, HSV, HH6–8, *Treponema pallidum*, brucellosis, *Leptospira spp.*, *Rickettsia conorii*, *Schistosoma spp.*, *Leishmania spp.*, *Plasmodium spp.*, Interferon- $\gamma$  release assays (IGRA)) and transthoracic echocardiogram.

Metabolic diseases were excluded based on normal levels of ceruloplasmin and alpha1-antitrypsin, and no mutations in the haemochromatosis gene were found.

Laboratory parameter	Patient	Normal range
Haemoglobin (g/l)	104	130-170
Mean corpuscular volume (fl)	89.6	80-96.1
Mean corpuscular haemoglobin (pg)	30.0	27.3-33.7
Red blood cells distribution width (%)	21.6	<15.6
Leukocytes ( $\times 10^9/l$ )	3.8	4.0-10.0
Absolute neutrophil count ( $\times 10^9/l$ )	2.43	
Absolute lymphocyte count ( $\times 10^9/l$ )	1.03	
Platelets ( $\times 10^9/l$ )	128	
Prothrombin time (s)	16.7	<14
Activated partial prothrombin time (s)	25.9	23-38
Fibrinogen - Claus (g/l)	1.29	1.5-4.0
Factor V (% activity)	110	62-139
C-reactive protein (mg/dl)	0.30	<0.1
Procalcitonin (ng/ml)	0.27	<0.1
Urea (mg/dl)	33	13-43
Creatinine (mg/dl)	0.75	0.7-1.2
Sodium (mEq/l)	139	136-145
Potassium (mEq/l)	4.96	3.5-5.1
Calcium (mg/dl)	8.7	8.4-10.2
Total bilirubin (mg/dl)	1.57	<1.40
Conjugated bilirubin (mg/dl)	0.56	<0.3
Aspartate transaminase (IU/l)	319	<40
Alanine transaminase (IU/l)	253	<41
GamaGT (U/l)	400	10-71
Alkaline phosphatase (IU/l)	399	40-130
Total proteins (g/dl)	5.2	6.4-8.3
Albumin (g/dl)	3.0	3.5-5.2
Leukocyturia	negative	
Proteinuria	+ (0.25-0.8g/l)	
Haematological study		
Haemoglobin (g/l)	100	130-170
Reticulocytes (%)	2.2	0.5-2
Mean corpuscular volume (fl)	91.0	80-96.1
Mean corpuscular haemoglobin (pg)	30.6	27.3-33.7
Red blood cells distribution width (%)	21.6	<15.6
Serum iron ( $\mu\text{g/dl}$ )	84	33-193
Ferritin (ng/ml)	>10,000	30-340
Total iron binding capacity ( $\mu\text{g/dl}$ )	190	250-425
Transferrin saturation (%)	44	20-45
Folate (mmol/l)	5.23	10-42
Cyanocobalamin (pmol/l)	644	141-489
HbA2 (%)	3.7	<3.5
Platelets ( $\times 10^9/l$ )	124	150-400
Prothrombin time (s)	15.9	<14
Activated partial prothrombin time (s)	27.3	23-38
b2-microglobulin (mg/dl)	4.79	1.09-2.53
Haptoglobin (mg/dl)	30	30-200
Coombs test	Negative	
Cryoglobulin	Negative	
Blood proteins electrophoresis	No monoclonal peak	
IgA (mg/dl)	327	50-400
IgM (mg/dl)	135	50-300
IgG (mg/dl)	1040	600-1500
Free light chains K (mg/l)	27.6	6.7-22.4
Free light chains L (mg/l)	32.4	8.3-27.0
Immunophenotyping of peripheral blood		
- Neutrophils	72.1%	
- Lymphocytes	15.1%	
- T cells (CD3+)	12.5%	
- NK (CD3- CD56+/-)	2.4%	
- B cells (CD19+); kappa/lambda	0.20%; 1	
- Comment	No abnormal lymphocyte population	
Thalassemia	No mutations present	

Table 1. Laboratory evaluation

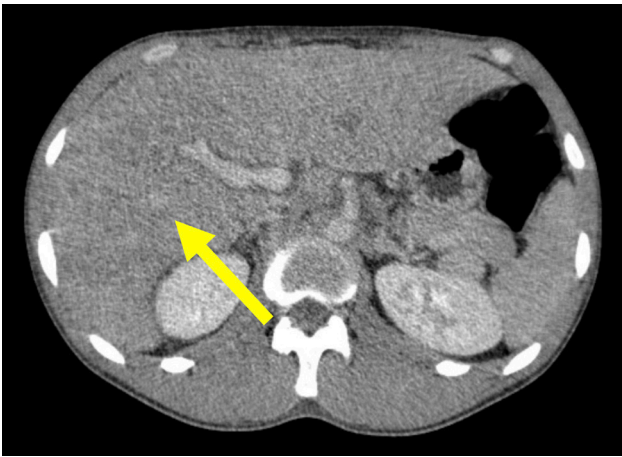


Figure 1. Complementary evaluation

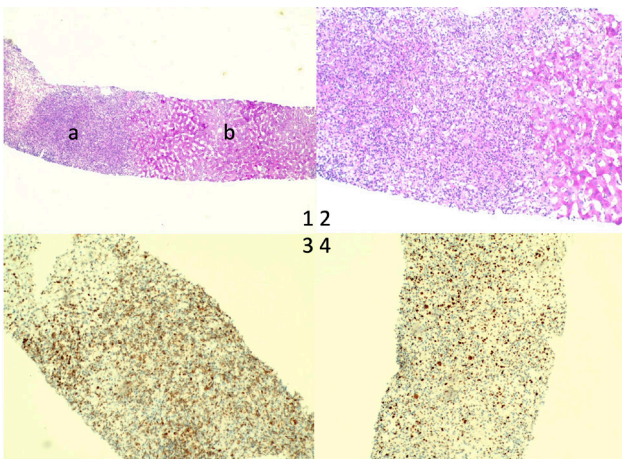


Figure 2. Liver biopsy (HE stain) x40: a - lymphoma; b - normal liver. 2 - liver biopsy (HE stain) x100. 3 - liver biopsy (BLC-2 stain). 4 liver biopsy (BLC-6 stain)

Autoimmune panel		
C3 (mg/dl)	111	90-180
C4 (mg/dl)	46.5	10-40
Rheumatoid factor (IU/ml)	<9.19	<15
Anti-cyclic citrullinated peptide antibodies (u/ml)	<0.1	<5
Antinuclear antibodies	negative	negative
Anti-dsDNA antibodies	negative	negative
Anti Ro/La/Sm/U1-RNP/Scl-70/Jo-1	negative	negative
Anti-hepatic antigens antibodies (LKM-1, LC-1, SLA/LP, AMA-M2, AMA-M2-3E, Sp 100, PML, gp210)	negative	negative
	16.7	<14
Anti-Ro52 antibody	positive	negative
Anti-neutrophil cytoplasmic antibody (c-ANCA, p-ANCA)	negative	negative
Ganglion immunophenotyping		
Neutrophils	1.8%	
Lymphocytes	96.5%	
- T cells (CD3+)	75.5%	
NK (CD3- CD56+/-)	0.9%	
B cells (CD19+); kappa/lambda	20.1%; 1.14	
Comment	No abnormal lymphocyte population. No metastatic cells were found	
Liver biopsy		
CD20+, PAX5+ (weak), BCL6+, BCL2+ (weak), CD3-, CD5-, CD30-, CD10-, CD23-, EBER-, EMA	Nodular lymphocyte-predominant Hodgkin lymphoma	

Table 2. Complementary evaluation

The haematologic study showed 2.2% reticulocytosis, folate deficiency, normal erythrocyte mean corpuscular haemoglobin and volume, increased red cell distribution width, borderline increase of HbA2 (3.7%), markedly elevated ferritin, increased beta-2-microglobulin, decreased haptoglobin, negative Coombs test, undetected cryoglobulin, normal proteinogram, immunoglobulins within normal range and unremarkable peripheral blood immunophenotyping. Based on these results, the authors considered it necessary to exclude thalassemia and autoimmune disease. Both screening tests yielded negative results (Table 2). After excluding other adenopathies by body CT scan, the right axillary adenopathy was removed (Table 2), and the patient underwent a medullary study with a myelogram and bone biopsy, both with no abnormal findings.

Due to increasing hepatic dysfunction and no other leads for the diagnosis, the patient underwent a hepatic biopsy (Fig. 2), which revealed nodular lymphocyte-predominant Hodgkin lymphoma (Table 2). After the diagnosis, the patient was transferred to the haematological ward and underwent chemotherapy with R-CHOP (six cycles in 5 months); after 1.5 years he was in complete remission.

## DISCUSSION

This case relates to a 30-year-old male admitted for the study of fever, night sweats and weight loss over the course of six months. The diagnosis was only possible through liver biopsy.

PHL is more frequent in men and the presentation varies from incidental discovery to fulminant hepatic failure. Symptoms are usually non-specific, and include right upper quadrant pain, fatigue, weight loss, fever, anorexia and nausea<sup>[2]</sup>.

The pathogenesis of PHL is unknown but chronic antigen stimulation appears to play a role. Some risk factors are known, such as HCV, HBV, HIV and EBV. PHL has also been associated with solid organ transplant<sup>[4]</sup>. None of these conditions were present in our patient.

The majority of PHL consists of B-cell NHL (63–66%)<sup>[4]</sup>. Hepatic involvement by classic Hodgkin lymphoma (CHL) is uncommon. CHL is generally a lymph-node based disease and hepatic involvement usually occurs in late and advanced stages of the disease. Primary manifestation in the liver is extremely rare.

The World Health Organization classifies CHL into four types (nodular sclerosing, mixed cellularity, lymphocyte rich and lymphocyte depleted) that are characterised by their microscopic appearance (the presence of Reed-Sternberg (RS) cells) and cell surface marker expression. There is another non-classical type of HL, the nodular lymphocyte-predominant Hodgkin lymphoma (NLPHL), which corresponds to 5% of all cases, and in which RS cells can be absent.

NLPHL is a rare lymphoma with an incidence of 0.2/100,000/y<sup>[5]</sup> peaking between the third and fifth decade of life and with male predominance<sup>[3]</sup>. The NLPHL is

characterised by distinct pathological and clinical features. The cell surface marker expression for the disease-defining lymphocyte-predominant cells consistently express CD20 but lack CD30. Clinically about 9% of NLPHL patients have B symptoms (fever, night sweats and unintentional weight loss) at presentation. In the case presented, all B symptoms were present at admission.

Fever and hepatic dysfunction, as in our patient, can occur in a multitude of conditions including infections, and autoimmune and metabolic diseases, so the differential diagnosis is quite extensive.

Infection was excluded based on microbiological and immunological tests. Because of the hepatic heterogeneity present in the CT scan, there was a need to exclude metabolic diseases such as Wilson disease, alpha-1 antitrypsin deficiency and haemochromatosis.

The haematological disorder was studied because it was the leading marker for diagnosis. The only positive findings during hospitalisation were normocytic normochromic anaemia with increased RDW and HbA2, and the presence of target cells that led to the study of haemoglobinopathies. Anaemia and hyperbilirubinemia implied the need to exclude haemolytic anaemia, and suspicion of proliferative haematological disease led to the medullary study.

As all previously mentioned studies were unable to give the diagnosis, there was the need to proceed with liver biopsy. The final diagnosis was only possible owing to the liver biopsy.

This case was challenging due to the difficulty in obtaining a histological diagnosis.

Treatment of NLPHL patients using standard HL protocols leads to complete remission in more than 95% of patients.

## CONCLUSION

PHL is a rare disease and even more rare when it is due to NLPHL. The clinical features are non-specific, and histology is mandatory for diagnosis. This clinical case was marked by the challenges faced due to the lack of results to corroborate the suspicion of proliferative haematological disease, leading to a complex battery of medical test to exclude other potential causes of fever in a gravely ill patient.

---

## REFERENCES

1. Lei KI. Primary non-Hodgkin's lymphoma of the liver. *Leuk Lymphoma* 1998;29:293–299.
2. Resende V, Oliveira TS, Gomes RT, Laboissière RS, Tavares-Junior WC, de Melo Couto OF. Primary hepatic lymphoma: a case report. *Int J Surg Case Rep* 2013;4:1165–1168.
3. American Cancer Society. Key Statistics for Hodgkin Lymphoma. [Online] Jan 12, 2022. [Cited: 10 March 2022.] <https://www.cancer.org/cancer/hodgkin-lymphoma/about/key-statistics.html>
4. Steller EJA, van Leeuwen MS, van Hillegersberg R, Schipper MEI, Rinkes IHMB, Molenaar, IQ. Primary lymphoma of the liver – a complex diagnosis. *World J Radiol* 2012; 4:53–57.
5. Eichenauer DA, Engert A. Nodular lymphocyte-predominant Hodgkin lymphoma: a unique disease deserving unique management. *Hematology Am Soc Hematol Educ Program* 2017;2017:324–328.