



# Chondrosarcomas in children and adolescents

Ajay Puri

- Chondrosarcomas in children and adolescents are uncommon and constitute < 5% of all chondrosarcomas. There are very few studies discussing extremity chondrosarcomas in young patients.
- The pelvis is the most common site, followed by the proximal femur.
- As cartilaginous tumours can be quite challenging to diagnose, it is best for these lesions to be discussed in a multidisciplinary meeting which includes a radiologist and a pathologist specializing in bone tumours.
- Treatment principles are similar to those in adults, with adequate surgical excision respecting oncologic principles being the mainstay of treatment. Select extremity Grade I chondrosarcomas may be managed with extended intralesional curettage without increasing the risk for local recurrence or metastatic disease, but case selection is critical and should be based on clinical, imaging and histological characteristics.
- Chondrosarcomas are resistant to chemotherapy and relatively radioresistant. For mesenchymal chondrosarcomas, there may be a role for chemotherapy, though data on this is limited.
- Prognosis and rate of recurrence correlate directly to the adequacy of the surgical resection.
- Chondrosarcomas in younger patients behave in a similar fashion to those in adults, and outcomes in the young are no different from those in adults.

**Keywords:** bone tumour; limb salvage; secondary chondrosarcoma

Cite this article: *EFORT Open Rev* 2020;5:90-95.

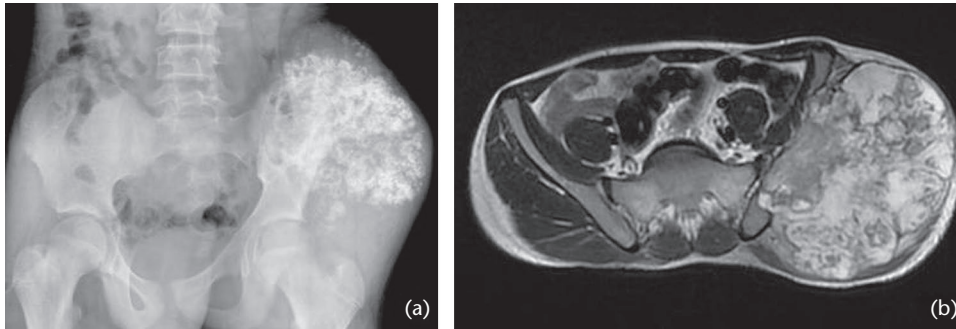
DOI: 10.1302/2058-5241.5.190052

Chondrosarcoma, a tumour of cartilage producing cells, comprises a heterogeneous group of malignant cartilaginous tumours. It is the most common sarcoma of bone in patients above the age of 20 years and predominantly affects individuals in the fourth to the sixth decades of life.<sup>1,2</sup>

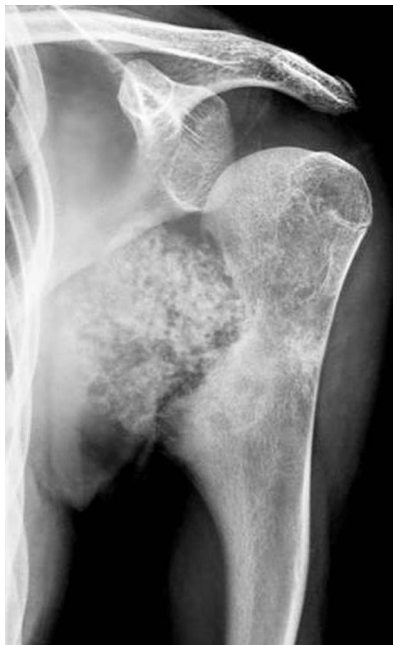## Incidence

Chondrosarcomas are very uncommon in children and adolescents and there are very few studies that specifically discuss extremity chondrosarcomas in young patients.<sup>3-7</sup> A nationwide, population-based study in Finland of patients < 18 years of age diagnosed with a bone sarcoma during the period 1991–2005 demonstrated an overall incidence of 3.6 per million for osteosarcoma, 1.2 for Ewing's sarcoma and only 0.3 for chondrosarcoma.<sup>8</sup> The Bone and Soft Tissue Tumour (BSTT) registry, a nationwide Japanese database, identified 521 young patients (< 15 years) diagnosed with bone sarcoma from 2006 to 2013. Only eight (1.5%) had chondrosarcoma.<sup>9</sup> Only 11 cases (4% of all chondrosarcomas) were 21 years old or younger during an 11-year period at a high-volume tertiary referral sarcoma care unit in India.<sup>7</sup> Similarly in a combination of the data from Dahlin and Campanacci (763 patients in their combined series) only 32 (4%) were less than 20 years old.<sup>10</sup> In Lee et al's series of 227 patients from Massachusetts General Hospital over a 22 year period, only 15 (7%) were less than 20 years old.<sup>11</sup> Apirin et al reported that only 12 patients with a diagnosis of chondrosarcoma were treated at the Children's Hospital Medical Center in Boston during the period from 1957 to 1980<sup>6</sup> while Gambarotti et al reported only 17 chondrosarcomas (excluding mesenchymal chondrosarcoma) in patients younger than 18 years between 1981 and 2014 at the Rizzoli Institute.<sup>3</sup>

A malignant cartilage tumour that arises de novo centrally in a previously normal bone is known as a primary chondrosarcoma. It is also called a central or conventional chondrosarcoma. Tumours that arise from previously benign cartilaginous lesions are called secondary chondrosarcomas. The precursor lesion for secondary chondrosarcomas may either be an osteochondroma or an enchondroma. A secondary chondrosarcoma that develops on the surface of a bone as a result of malignant transformation within the cartilage cap of a pre-existing osteochondroma is also called a peripheral chondrosarcoma (Fig. 1 & Fig. 2). The risk of chondrosarcoma arising in a solitary osteochondroma has been reported to be less



**Fig. 1** (a) X-ray of secondary chondrosarcoma developing in a prior osteochondroma of the pelvis. (b) MRI showing an axial T2 image of secondary chondrosarcoma of the pelvis.



**Fig. 2** X-ray of secondary chondrosarcoma developing in a prior osteochondroma of the proximal humerus.

than 1%. However, in multiple osteochondromatosis the risk increases to 5%, though they usually present after skeletal maturity. In 2012, Mosier et al published the only reported case in the literature of a chondrosarcoma possibly arising secondary to an enchondroma in a paediatric patient.<sup>12</sup> Subsequently in 2016, the series of 17 patients of paediatric chondrosarcomas by Gambarotti et al included a case developing in a metacarpal in a patient with Maffucci's syndrome.<sup>3</sup> Patients with Ollier disease and Maffucci's syndrome may have up to a 40% risk of developing chondrosarcoma.<sup>13</sup>

Most adult series have 75–85% cases of primary chondrosarcomas.<sup>14,15</sup> Except for the series by Puri et al, most other series of chondrosarcomas in the young demonstrated a similar distribution. In Puri et al's series of 11

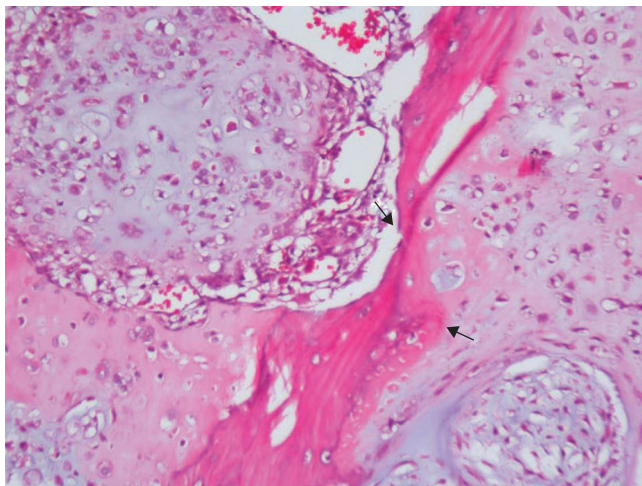
chondrosarcomas in younger patients, six (55%) were secondary chondrosarcomas (compared to 22% secondary chondrosarcomas in their entire cohort of 249 chondrosarcoma patients during that same period).<sup>7</sup> This was unusual as such a skewed representation has not been reported in other series of chondrosarcomas in the young. Huvos et al reported 28% secondary chondrosarcomas, Young et al had 26% chondrosarcomas secondary to pre-existing benign solitary or multiple cartilaginous lesions, while Gambarotti et al's series had 29%.<sup>3–5</sup>

The pelvis, followed by the proximal femur, is the most common site of skeletal involvement in chondrosarcomas irrespective of the age group. The series of chondrosarcomas in the young by Huvos et al, Puri et al and Apirin et al too reported that the pelvic bones were the most common location.<sup>4,6,7</sup> In Gambarotti et al's series of young chondrosarcomas, seven of 17 cases occurred in the femur.<sup>3</sup>

## Pathology

Chondrosarcomas are malignant cartilaginous matrix producing tumours. A chondrosarcoma may have overlapping features with a chondroblastic osteosarcoma (a much more common tumour in younger individuals). There can be heterotopic bone formation/ossification or endochondral ossification in certain chondrosarcomas and conspicuous chondroid differentiation in some osteosarcomas. Careful assessment of the type of matrix produced by the tumour cells, whether chondroid or osteoid can help differentiate a chondrosarcoma from an osteosarcoma.

Grading of a chondrosarcoma is based on cellularity, nuclear size, degree of nuclear staining (hyperchromasia) and presence of mitotic figures.<sup>16</sup> A diagnosis of a Grade II or a Grade III chondrosarcoma can usually be made on the basis of cytologic or histologic features alone. Differentiating an enchondroma from a well differentiated/Grade I chondrosarcoma can be difficult. Features such as bone permeation (cortex and/or medulla), open/vesicular



**Fig. 3** Chondrosarcoma – a cellular chondroid tumour with atypical cells, frequent binucleation and demonstrating bone entrapment/permeation (arrows).

chromatin of cell nuclei and a mucoid matrix are features that favour a chondrosarcoma (Fig. 3). The criteria for diagnosis of a chondrosarcoma in small bones include cortical or soft tissue destruction or presence of mitotic figures.

The 2013 World Health Organization (WHO) Classification of Tumors of Soft Tissue and Bone now separates chondrosarcoma into two International Classification of Diseases codes. This is reflective of the different prognosis of chondrosarcoma based on grade, with Grade I distinguished from Grade II and Grade III chondrosarcoma.<sup>17</sup> It has also introduced the synonym ‘atypical cartilaginous tumour’ for ‘Grade I chondrosarcoma’, classifying it as an intermediate type of tumour, not a malignancy. This may be a better reflection of its clinical behaviour which demonstrates a locally aggressive nature with little risk of metastasis.<sup>17</sup>

Clinical behaviour, anatomical location and radiologic findings must be taken into consideration in conjunction with the histologic criteria to differentiate an enchondroma from a low-grade chondrosarcoma. The presence of focal pain is often used to crudely distinguish a chondrosarcoma, but it may be difficult to localize pain in the paediatric population. In a study based on initial clinical and imaging information that did not directly involve any pathologists or radiologists and was restricted to orthopaedic oncologists for diagnosis and grading of cartilaginous neoplasms, inter and intra-observer agreements were only fair to good.<sup>18</sup> As cartilaginous tumours can be quite challenging to diagnose, it is best for these lesions to be discussed in a multidisciplinary meeting which includes a radiologist and a pathologist specializing in bone tumours.

Mesenchymal chondrosarcoma, an aggressive histological subtype with a tendency for late local and disseminated

recurrence, generally comprise 2–10% of all chondrosarcomas. Dabska and Huvos reported a series of 19 cases of mesenchymal chondrosarcoma in the young. These represented 26% of chondrosarcoma patients under the age of 21 years in their series.<sup>19</sup> Twelve of these lesions occurred between the ages of 16 and 21 years and all but one of the tumours arose in the skeleton, with nearly half of them involving the lower extremities.<sup>19</sup> However, in a series of 12 patients with mesenchymal chondrosarcoma in children and young adults from St. Jude Children’s Research Hospital, seven patients presented with disease arising in the head and neck region and three involved the chest wall.<sup>20</sup> Not a single one was in the extremity or pelvis.

### Staging

Prior to commencing treatment all patients must be evaluated for appropriate staging. Similar to other primary bone sarcomas, investigations include plain radiographs and magnetic resonance imaging (MRI) of the involved region, computed tomography (CT) scan of the chest and a bone scan. Considering the extreme rarity of isolated skeletal metastasis in chondrosarcoma, recent studies have questioned the need for a bone scan in all chondrosarcomas.<sup>21,22</sup> While Douis et al suggested that there was no role for routine whole body bone scintigraphy in the initial surgical staging of chondrosarcoma, Gulia et al suggested that only symptomatic patients or those with pulmonary metastasis warranted any additional staging investigations

The role of positron emission tomography (PET)-CTscan is being increasingly investigated to help differentiate the grade of chondroid lesions. Reports suggest that the standardized uptake value (SUV) max can correlate with the histologic grade. A very low SUVmax supports a diagnosis of a benign tumour, while an elevated SUVmax is suggestive of a higher grade chondrosarcoma.<sup>23</sup> A PET-CT may also help detect malignant change in a previously benign chondroid neoplasm by showing higher metabolic activity in the area of sarcomatous transformation.<sup>24</sup>

### Treatment

Considering the paucity of data regarding chondrosarcomas in younger individuals, treatment principles remain similar to those followed in adults. Chondrosarcomas are resistant to chemotherapy and relatively radioresistant.<sup>15</sup> Thus, surgical excision is the only reliable treatment for these tumours. A wide resection observing oncologic principles is recommended for Grade II and Grade III chondrosarcomas. Similarly for Grade I chondrosarcomas with aggressive radiological findings, a wide resection with adequate margins is traditionally considered

preferable for best local control. However, recently there have been reports suggesting that there may be a role for safely treating extremity Grade I chondrosarcoma with extended intralesional curettage without increasing the risk of local recurrence or metastatic disease.<sup>25</sup> Case selection is critical and should be based on clinical, imaging and histological characteristics. The advantage of intralesional curettage is that the functional results are superior to cases treated with resection. Cartilage lesions in the pelvis and sacrum can frequently recur after intralesional excision even if the histologic appearance is benign or suggests a low-grade neoplasm. Therefore, wide excisions are recommended for nearly all cartilaginous lesions of the pelvis and sacrum.

Children, because of the dynamic nature of growing bones, pose a unique reconstruction challenge after resection. Though there are no reports focusing exclusively on reconstruction after resection in chondrosarcomas among the young, the principles remain similar to those for other skeletal tumours in the young. The issue of ultimate limb-length discrepancy at skeletal maturity, especially in the lower limb, can be difficult to address. Though the newer generation non-invasive expandable prostheses are now being increasingly used, they are not without their share of complications.<sup>26</sup> As mentioned earlier, the pelvis and the proximal femur are the most common sites involved in chondrosarcoma. Pelvic periacetabular resections in children are best managed with pseudarthrosis, though an ili-ofemoral arthrodesis and reimplantation of sterilized tumour bone have also been described.<sup>27–29</sup> Van Kampen et al reviewed 40 children who had a proximal femoral replacement for malignant disease.<sup>28</sup> They recommended that at the time of initial surgery it is best to cause as little damage to the acetabulum as possible, but most children would need revision surgery as they got older. A hip rotationplasty, in which placement of the cartilaginous condyle of the tibia into the acetabulum permits development of a new femoral head, can also be an alternative after resection for lesions of the proximal femur in the extremely young.<sup>30</sup> Biological means of reconstruction using autografts, allografts and re-implantation of sterilized tumour bone offer an attractive alternative option in certain scenarios.<sup>31</sup>

Both prognosis and rate of recurrence correlate directly to the adequacy of the surgical resection in lesions requiring wide resection.<sup>32,33</sup> For mesenchymal chondrosarcoma, there may be a role for chemotherapy, though data on this is limited.<sup>2,34</sup> The role of radiotherapy is limited and experience with radiotherapy in chondrosarcoma is mostly restricted to older patients. Though it is not the first choice for local control in cartilage lesions, the development of newer techniques of delivery has resulted in an increasing role for radiation therapy in unresectable lesions or after incomplete resection, especially in the skull

base and the spine.<sup>35</sup> Radiotherapy may also be useful for palliation.

## Outcomes

Huvos et al indicated that survival was worse in paediatric than in adult chondrosarcomas.<sup>4</sup> This could be because more than a fourth of their patients had mesenchymal chondrosarcoma, a histologic subtype with a poorer prognosis. Other series in younger patients do not concur with this finding.<sup>7</sup> Young et al and Gambarotti et al did not support the view that chondrosarcomas are more aggressive in children than in adults.<sup>3,5</sup> Data from the Japanese BSTT registry also showed similar cancer survival rates for children and adults with chondrosarcoma.<sup>9</sup> Puri et al mentioned that though survival appeared better in their paediatric chondrosarcomas as compared to most series of chondrosarcomas in adults, this needs to be interpreted with caution in view of the small numbers.<sup>31</sup> The only mortality in their series was in a case of mesenchymal chondrosarcoma. A review of 247 paediatric chondrosarcoma patients by Wu et al, collated from the National Cancer Institute's Surveillance, Epidemiology and End Results databases (SEER, 1973 to 2014), found that paediatric patients have significantly better survival rates than adult patients.<sup>36</sup> This observation also needs to be interpreted with caution as the SEER database has inherent drawbacks. It does not contain detailed information on patient comorbidities and a central pathology review is not available. More than 40% of the paediatric chondrosarcomas in this series were reported in sites other than the limbs or pelvis and < 55% were localized, which is unusual.

## Screening in patients with benign cartilage lesions

The literature suggests that there is an increased risk of malignant transformation for osteochondromas occurring in the axial skeleton, for lesions in the proximal aspect of the extremities, for recurrent tumours and in patients with multiple osteochondromatosis. Pain and/or increase in size of the lesion after skeletal maturity are the most common clinical signs of malignant transformation. The risk of malignant transformation of a solitary osteochondroma is generally lower than in patients with multiple osteochondromatosis. Regular self-examination is recommended and can usually easily be accomplished in the more peripherally located lesions. In certain doubtful cases supplementary X-ray imaging may be necessary, while in deep-seated areas which are more difficult to access manually an examination using MRI is helpful. Though debatable, an annual whole-body MRI after skeletal maturity in multiple osteochondromatosis patients may be beneficial

in detecting malignant transformation earlier.<sup>37,38</sup> In patients with Ollier disease and Maffucci syndrome a careful radiological examination should be carried out when any complaints of pain and/or swelling appear or increase. As these patients are known to have a higher risk for other associated soft tissue malignancies such as pancreatic and hepatic adenocarcinoma, mesenchymal ovarian tumours and brain tumours; appropriate cross sectional imaging is recommended when patients have symptoms.<sup>13,39</sup> Patients with endochondral lesions in the pelvis, femur, humerus or scapula may benefit from an annual clinical examination and whole-body MRI because of the higher risk of malignant transformation at these sites and the risk of undergoing ‘painless’ transformation into chondrosarcoma.<sup>40</sup>

## Conclusion

Chondrosarcomas in children and adolescents are uncommon and constitute < 5% of all chondrosarcomas. Treatment principles are similar to those in adults, with adequate surgical excision respecting oncologic principles being the mainstay of treatment. The extreme rarity of chondrosarcomas in younger patients precludes the possibility of any significant statistical analyses based on a single institution series, but overall it appears that chondrosarcomas in younger patients behave in a similar fashion to those in adults and outcomes in the young are no different from those in adults.

### AUTHOR INFORMATION

Department of Surgery, Tata Memorial Hospital, HBNI, Mumbai.

Correspondence should be sent to: Ajay Puri, Department of Surgery, Room No. 45, Tata Memorial Hospital, HBNI, Mumbai.  
Email: docpuri@gmail.com

### ACKNOWLEDGEMENTS

Prof. Puri would like to thank Prof. Bharat Rekhi (Professor of Pathology, Tata Memorial Hospital) for editing the pathology write up and contributing the pathology photomicrographs.

### FUNDING STATEMENT

Although none of the authors has received or will receive benefits for personal or professional use from a commercial party related directly or indirectly to the subject of this article, benefits have been or will be received but will be directed solely to a research fund, foundation, educational institution, or other non-profit organization with which one or more of the authors are associated.

### ICMJE CONFLICT OF INTEREST STATEMENT

AP reports that their institution has received consulting fees or honorarium from Smith and Nephew for inputs on developing a tumour prosthesis, both related to and outside the submitted work.

### LICENCE

© 2020 The author(s)

This article is distributed under the terms of the Creative Commons Attribution-Non Commercial 4.0 International (CC BY-NC 4.0) licence (<https://creativecommons.org/licenses/by-nc/4.0/>) which permits non-commercial use, reproduction and distribution of the work without further permission provided the original work is attributed.

### REFERENCES

1. Fiorenza F, Abudu A, Grimer RJ, et al. Risk factors for survival and local control in chondrosarcoma of bone. *J Bone Joint Surg Br* 2002;84:93–99.
2. Gerrand C, Athanasou N, Brennan B, et al; British Sarcoma Group. UK guidelines for the management of bone sarcomas. *Clin Sarcoma Res* 2016;6:7.
3. Gambarotti M, Righi A, Picci P, et al. Paediatric chondrosarcomas: a retrospective review of 17 cases. *Histopathology* 2016;68:1073–1078.
4. Huvos AG, Marcove RC. Chondrosarcoma in the young: a clinicopathologic analysis of 79 patients younger than 21 years of age. *Am J Surg Pathol* 1987;11:930–942.
5. Young CL, Sim FH, Unni KK, McLeod RA. Chondrosarcoma of bone in children. *Cancer* 1990;66:1641–1648.
6. Aprin H, Riseborough EJ, Hall JE. Chondrosarcoma in children and adolescents. *Clin Orthop Relat Res* 1982;166:226–232.
7. Puri A, Gulia A, Kurisunkal VJ, Sukumar V, Rekhi B. Chondrosarcomas in adolescents: are they different? *J Pediatr Orthop B* 2019. doi:10.1097/BPB.0000000000000641 [Epub ahead of print].
8. Serlo J, Tarkkanen M, Sampo M, Vettenranta K, Riikonen P, Helenius I. Incidence, treatment and survival of paediatric patients with bone sarcomas in Finland from 1991 to 2005. *Acta Paediatr* 2015;104:738–745.
9. Fukushima T, Ogura K, Akiyama T, Takeshita K, Kawai A. Descriptive epidemiology and outcomes of bone sarcomas in adolescent and young adult patients in Japan. *BMC Musculoskelet Disord* 2018;19:297.
10. Springfield DS, Gebhardt MC, McGuire MH. Chondrosarcoma: a review. *Instr Course Lect* 1996;45:417–424.
11. Lee FY, Mankin HJ, Fondren G, et al. Chondrosarcoma of bone: an assessment of outcome. *J Bone Joint Surg Am* 1999;81:326–338.
12. Mosier SM, Patel T, Strenge K, Mosier AD. Chondrosarcoma in childhood: the radiologic and clinical conundrum. *J Radiol Case Rep* 2012;6:32–42.
13. Verdegaal SH, Bovee JV, Pansuriya TC, et al. Incidence, predictive factors, and prognosis of chondrosarcoma in patients with Ollier disease and Maffucci syndrome: an international multicenter study of 161 patients. *Oncologist* 2011;16:1771–1779.
14. Bjornsson J, McLeod RA, Unni KK, Ilstrup DM, Pritchard DJ. Primary chondrosarcoma of long bones and limb girdles. *Cancer* 1998;83:2105–2119.
15. Gelderblom H, Hogendoorn PC, Dijkstra SD, et al. The clinical approach towards chondrosarcoma. *Oncologist* 2008;13:320–329.
16. Flanagan AM, Lindsay D. A diagnostic approach to bone tumours. *Pathology* 2017;49:675–687.
17. Fletcher CD, Hogendoorn P, Mertens F, Bridge J. *WHO classification of tumours of soft tissue and bone*. Fourth ed. Lyon, France: IARC Press, 2013.
18. Zamora T, Urrutia J, Schweitzer D, Amenabar PP, Botello E. Do orthopaedic oncologists agree on the diagnosis and treatment of cartilage tumors of the appendicular skeleton? *Clin Orthop Relat Res* 2017;475:2176–2186.

19. **Dabska M, Huvos AG.** Mesenchymal chondrosarcoma in the young. *Virchows Arch A Pathol Anat Histopathol* 1983;399:89–104.
20. **Bishop MW, Somerville JM, Bahrami A, et al.** Mesenchymal chondrosarcoma in children and young adults: a single institution retrospective review. *Sarcoma* 2015;2015:608279.
21. **Gulia A, Puri A, Byregowda S.** Staging investigations in chondrosarcoma: is evaluation for skeletal metastases justified? Analysis from an epidemiological study at a tertiary cancer care center and review of literature. *South Asian J Cancer* 2016;5:3–4.
22. **Douis H, James SL, Grimer RJ, Davies MA.** Is bone scintigraphy necessary in the initial surgical staging of chondrosarcoma of bone? *Skeletal Radiol* 2012;41:429–436.
23. **Subhawong TK, Winn A, Shemesh SS, Pretell-Mazzini J.** F-18 FDG PET differentiation of benign from malignant chondroid neoplasms: a systematic review of the literature. *Skeletal Radiol* 2017;46:1233–1239.
24. **Purandare NC, Puranik A, Shah S, Agrawal A, Puri A, Gulia A, Nayak P, Rekhi B, Rangarajan V.** Can 18F-FDG PET/CT diagnose malignant change in benign chondroid tumors? *Nucl Med Commun* 2019;40:645–651.
25. **Kim W, Han I, Kim EJ, Kang S, Kim HS.** Outcomes of curettage and anhydrous alcohol adjuvant for low-grade chondrosarcoma of long bone. *Surg Oncol* 2015;24:89–94.
26. **Tsagozis P, Parry M, Grimer R.** High complication rate after extendible endoprosthetic replacement of the proximal tibia: a retrospective study of 42 consecutive children. *Acta Orthop* 2018;89:678–682.
27. **Puri A, Gulia A, Pruthi M.** Results of surgical resection in pediatric pelvic tumors. *J Pediatr Orthop B* 2013;22:24–29.
28. **van Kampen M, Grimer RJ, Carter SR, Tillman RM, Abudu A.** Replacement of the hip in children with a tumor in the proximal part of the femur. *J Bone Joint Surg Am* 2008;90:785–795.
29. **Fujiwara T, Lex JR, Stevenson JD, et al.** Surgical treatment for pelvic Ewing sarcoma: what is a safe and functional acetabular reconstruction when combined with modern multidisciplinary treatments? *J Surg Oncol* 2019;120:985–993.
30. **Winkelmann WW.** Type-B-IIIa hip rotationplasty: an alternative operation for the treatment of malignant tumors of the femur in early childhood. *J Bone Joint Surg Am* 2000;82:814–828.
31. **Puri A, Gulia A.** Paediatric diaphyseal malignant tumors: options for reconstruction after intercalary resection. *J Pediatr Orthop B* 2011;20:309–317.
32. **Stevenson JD, Laitinen MK, Parry MC, Sumathi V, Grimer RJ, Jeys LM.** The role of surgical margins in chondrosarcoma. *Eur J Surg Oncol* 2018;44:1412–1418.
33. **Evans HL, Ayala AG, Romsdahl MM.** Prognostic factors in chondrosarcoma of bone: a clinicopathologic analysis with emphasis on histologic grading. *Cancer* 1977;40:818–831.
34. **Nooij MA, Whelan J, Bramwell VH, et al; European Osteosarcoma Intergroup.** Doxorubicin and cisplatin chemotherapy in high-grade spindle cell sarcomas of the bone, other than osteosarcoma or malignant fibrous histiocytoma: a European Osteosarcoma Intergroup study. *Eur J Cancer* 2005;41:225–230.
35. **Palm RF, Oliver DE, Yang GQ, Abuodeh Y, Naghavi AO, Johnstone PAS.** The role of dose escalation and proton therapy in perioperative or definitive treatment of chondrosarcoma and chordoma: an analysis of the National Cancer Data Base. *Cancer* 2019;125:642–651.
36. **Wu AM, Li G, Zheng JW, et al.** Chondrosarcoma in a paediatric population: a study of 247 cases. *J Child Orthop* 2019;13:89–99.
37. **Herget GW, Kontny U, Saueressig U, et al.** Osteochondroma and multiple osteochondromas: recommendations on the diagnostics and follow-up with special consideration to the occurrence of secondary chondrosarcoma. *Radiologe* 2013;53:1125–1136.
38. **Sonne-Holm E, Wong C, Sonne-Holm S.** Multiple cartilaginous exostoses and development of chondrosarcomas: a systematic review. *Dan Med J* 2014; 61:A4895.
39. **Schwartz HS, Zimmerman NB, Simon MA, Wroble RR, Millar EA, Bonfiglio M.** The malignant potential of enchondromatosis. *J Bone Joint Surg Am* 1987;69:269–274.
40. **Herget GW, Strohm P, Rottenburger C, et al.** Insights into enchondroma, enchondromatosis and the risk of secondary chondrosarcoma: review of the literature with an emphasis on the clinical behaviour, radiology, malignant transformation and the follow up. *Neoplasma* 2014;61:365–378.