

Alternative Treatment Options in Patients with Colorectal Cancer Who Encounter Fluoropyrimidine-Induced Cardiotoxicity

This article was published in the following Dove Press journal:
OncoTargets and Therapy

Muhammad Wasif Saif 

NorthwellHealth Cancer Institute,
Donald and Barbara Zucker School of
Medicine at Hofstra, Feinstein Institute
for Medical Research, Lake Success,
New York, NY, USA

Abstract: 5-Fluorouracil (5-FU) remains to be the backbone of chemotherapy regimens approved for treatment of colorectal cancer and other gastrointestinal cancers and breast cancer. The incidence of cardiotoxicity associated with 5-FU ranges from 1.5–18%. Previous studies also concluded that rechallenging a patient with previous 5-FU cardiotoxicity with either lower dose or another mode of administration could result in repeat of cardiac complication in up to 45% of patients. Nearly 13% of patients died upon re-exposure to 5-FU. Clinical manifestations of cardiac complications of fluoropyrimidines including angina, myocardial infarction, arrhythmias, hypotension, Tako-Tsubo syndrome, heart failure, cardiogenic shock, pericarditis, and even sudden death have been reported. Cardiotoxicity is unpredictable and no alternative chemotherapeutics have been defined so far. The author describes here treatment options for patients with metastatic colorectal cancer who have encountered fluoropyrimidine-induced cardiotoxicity, including switching to a different fluoropyrimidine, switching to a different schedule of intravenous 5-FU, or switching to a non-fluoropyrimidine-containing chemotherapy regimen if one exists. Switching to a non-fluoropyrimidine-containing chemotherapy regimen is usually the most feasible choice for patients with metastatic disease as data on adjuvant setting is usually a fluoropyrimidine or its combination with oxaliplatin at present.

Keywords: 5-FU, cardiotoxicity, fluoropyrimidines, 5-fluorouracil, DPD, dihydropyrimidine dehydrogenase, FBAL, fluoro-beta-alanine, TAS-102, uridine triacetate, S-1, capecitabine, UFT

Introduction

Fluoropyrimidines remain to be the backbone of regimens to treat many common solid tumors, including head and neck (H&N), breast, pancreas, stomach, anus, skin, small bowel, and especially colorectal cancer.¹ As we continue to use these agents commonly, recognition of its related uncommon or under-recognized toxicities such as cardiac toxicity has also improved. Cardiotoxicity associated with either 5-FU or capecitabine is of utmost significance for many reasons. 5-FU is usually given orally or intravenously as a bolus or by continuous intravenous infusion and as a topical application. Intravenous 5-FU is administered to nearly 275,000 cancer patients per year and capecitabine is taken by an additional 30,000 patients per year in the US. Moreover, 5-FU is usually administered for a series of cycles up to 6 months in adjuvant setting and till progression in advanced stages. Additionally, 5-FU administration continues in the second-line after progression in combination with other agents,

Correspondence: Muhammad Wasif Saif
NorthwellHealth Cancer Institute,
Donald and Barbara Zucker School of
Medicine at Hofstra, Feinstein Institute
for Medical Research, Lake Success,
New York, NY 11042, USA
Tel +1 516-321-2238
Fax +1 516-321-2272
Email wsaif@northwell.edu

eg FOLFOX to FOLFIRI. These statistics further underline the importance of recognizing and managing the cardiac toxicity associated with 5-FU and its analogs.

Clinical manifestations of cardiac complications of fluoropyrimidines may include angina, myocardial infarction, arrhythmias, hypotension, Tako-Tsubo syndrome, heart failure, cardiogenic shock, pericarditis, and even sudden death,^{2,4} as summarized in Table 1.

The underlying pathophysiological mechanisms to explain 5-FU-induced cardiotoxicity remain undefined, but its association with mode and schedule of administration and genuine reproducibility have been well-recognized.^{2,3} It is proposed to be multifactorial, and many mechanisms proposed include coronary spasm, direct myocardial ischemia due to endothelial damage, changes in platelet aggregability, abnormalities of coagulation proteins, an autoimmune reaction, result of pharmacogenetics related to 5-FU, such as dihydropyrimidine dehydrogenase (DPD) enzyme abnormality, direct effect of the catabolite, especially fluoro-beta-analine (FBAL) on the myocardium, or cardiotoxic impurities in 5-FU formulation^{2,5} (Table 2 and Figure 1).

Several studies have also attempted to identify factors that might alter the incidence or severity of 5-FU-induced cardiac toxicity, including age, prior history of coronary artery disease, presence of comorbidities (smoking, hypertension, diabetes), and concomitant administration of other chemotherapeutic agents or radiation therapy.^{2-4,7} However, the majority of the cases reported previously had no such risk factors identified except few proposing an increased risk with concomitant administration of certain chemotherapeutics, such as 5-FU when used with cisplatin, or prior chest radiation, or combination of capecitabine with oxaliplatin and bevacizumab.²⁻⁸ We presented a met-analysis in 2001 which revealed that cardiac toxicity

was associated with the longer duration of 5-FU administration and later we found similar toxicities associated with capecitabine, that mimics medium duration of the infusion. No relationship to dose was found.^{2,4} Reports include both chemo-naïve patients as well as those rechallenged after developing cardiac toxicity to 5-FU.⁹

Previous studies have alarmed that rechallenging a patient with previous 5-FU cardiotoxicity with either a lower dose or another mode of administration could result in repeat of cardiac complication in up to 45% of patients.^{2,7-9} Additionally, approximately 13% of patients died upon being re-exposed to 5-FU.² Investigators have also evaluated the use of anti-anginal drugs with 5-FU and capecitabine. Two older studies looked at nitroglycerine and nifedipine and diltiazem. In one study, seven out of 300 patients manifested cardiac toxicity after administration of 5-FU with prophylactic nitroglycerin which failed to prevent EKG changes suggestive of myocardial ischemia during repeat infusion.¹⁰ A similar lack of protective efficacy was seen with either nifedipine 60 mg/day, or diltiazem 80 mg/day administered with simultaneous intravenous nitroglycerin at therapeutic doses.¹¹ Eskilsson and Albertsson treated 58 patients receiving fluorouracil infusions with verapamil 120 mg three times a day. They found evidence of ischemia in 12% of patients, compared with 13% in a previously studied comparable group not receiving prophylaxis.¹² They concluded that calcium-channel blockade does not protect against cardiotoxicity. These data underline the fact that a rechallenge with 5-FU is not without risk and should be reserved only for those patients in whom there is no reasonable alternative therapy while observing aggressive prophylaxis and close monitoring.

The previous experience in investigating the cardiac toxicities of fluoropyrimidines, contribution to the clinical trials associated with development of S-1, TAS-102, and research in 5-FU pharmacogenetics of our group maintains my interest in managing 5-FU associated cardiotoxicity.⁸⁻¹⁰ The treatment options for patients who have encountered fluoropyrimidine-induced cardiotoxicity in patients with CRC can be broadly divided into three groups:

1. Switch to a different fluoropyrimidine,
2. Switch to a different schedule of intravenous 5-FU, or
3. Switch to a non-fluoropyrimidine-containing chemotherapy regimen if one exists.

Switching to a non-fluoropyrimidine-containing chemotherapy regimen is usually the most feasible choice

Table 1 The Most Frequent Cardiac Complications Related to 5-FU Administration²

Cardiac Manifestations of 5-FU/Capecitabine Toxicities	
Cardiac Event	%
Angina	45%
Myocardial infarction	22%
Arrhythmias (notably atrial fibrillation, VT, and VF)	23%
Acute pulmonary edema	5%
Cardiac arrest	1.4%
Pericarditis	1.4%
Congestive heart failure	2%

Table 2 Potential Mechanisms Underlying 5-FU Cardiotoxicity^{2,5}

Mechanism	Results
Autoimmune	<ul style="list-style-type: none"> A delayed immune reaction has been proposed to explain 5-FU cardiotoxicity. These investigators also reported a beneficial effect of steroids, further supporting the above possible explanation.
Direct myocardial damage	<ul style="list-style-type: none"> Edema of myocardial fibers and loss of striations were found within 12 hours of exposure to 5-FU in a rat model. Injected radiolabeled ¹⁴C-labeled-5-FU into a mouse model showed localization within the myocardium which was retained for 96 hours (longer than most organ systems). In another preclinical study, repeated infusions of 5-FU induced left ventricular hypertrophy, foci of myocardial necrosis, thickening of intramyocardial arterioles, and disseminated apoptosis in myocardial cells of the epicardium, as well as endothelial cells of the distal coronary arteries.
Impurities in 5-FU formulation	<ul style="list-style-type: none"> Commercial vials of 5-FU over time develop 5-FU degradation products, ie, fluoroacetaldehyde (FACET) and fluoromalon-aldehydic acid (FmalD) which are cardiotoxic in animal models. Also, 5-FU gets metabolized into two compounds, alpha-fluoro-beta-hydroxypropionic acid (FHPA) and fluoroacetate, which are again cardiotoxic.
Interference with TCA cycle	<ul style="list-style-type: none"> Analysis of TCA cycle intermediates in animal studies revealed an accumulation of citrate within the myocardium, possibly resulting from an inhibition of aconitase by fluorocitrate, as a cause of depletion of the high-energy phosphates. 5-FU depletes high-energy phosphate compounds in the myocardium resulting in metabolic dysfunction.
Vasospasm	<ul style="list-style-type: none"> Administration of 5-FU caused vasospasm of the aortic rings of rabbits which was dose dependent. 5-FU may have a direct endothelial-independent vasoconstriction secondary to activation of PKC, probably via activation of PKC receptors. An elevated level of endothelin-1 (ET-1), a potent natural vasoconstrictor, was found in two patients with cardiac toxicity from 5-FU.
Hypercoagulability	<p>Increase in fibrinopeptide A (FPA) levels and decrease in Protein C activity as compared to Protein C antigen levels was observed in a study during the continuous infusion of 5-FU, which returned to the baseline at the end of 5 days of CIV.</p>

(Continued)

Table 2 (Continued).

Mechanism	Results
Increased iron content	<ul style="list-style-type: none"> Increased iron content might be associated with increased oxygen consumption. Animal studies showed iron was 20% higher compared to time zero when measured by a Flame Atomic absorption spectrophotometer, hence supporting the cardiac ischemia related to 5-FU.
Cytotoxic effect	The inhibition of mature cytoplasmic rRNA production may be an important common mechanism of RNA-directed cytotoxicity for all the fluoropyrimidines
Effect on erythrocytes	<ul style="list-style-type: none"> Exposure of the erythrocytes to 5-FU irreversibly affects their energetic metabolism as well as their functioning. Using ³¹P NMR spectroscopy, a rapid increase in O₂ consumption in 5-FU treated erythrocytes was observed which led to severe changes in the metabolism of phosphate compounds in erythrocytes. Erythrocytes produced more 2,3-BPG in order to maintain the metabolism of oxygen within the physiological range, which led to deoxygenation of oxy-Hb. This made oxygen transport and/or delivery more difficult, resulting in ischemic damage.

for patients with metastatic disease because data on adjuvant setting supports only the use usually of a fluoropyrimidine monotherapy, such as 5-FU or capecitabine or its combination with oxaliplatin at present. [Table 3](#) summarizes other agents, including novel fluoropyrimidines and non-fluoropyrimidines, as alternative treatment options with cancer.

Switch to a Different Fluoropyrimidines

[Table 3](#) summarizes the novel and other analogs of different fluoropyrimidines which may be considered as an alternative treatment for colorectal cancer patients who encountered cardiotoxicity to 5-FU or capecitabine. The composition, data on cardiac toxicity, potential mechanism of action responsible for lower incidence of cardiac toxicities, any comparison to 5-FU/capecitabine if available, and availability are summarized below.

Switch to a Different Schedule of Intravenous 5-FU

Previous data indicated that the incidence of 5-FU related cardiotoxicity is lower with a bolus schedule than with

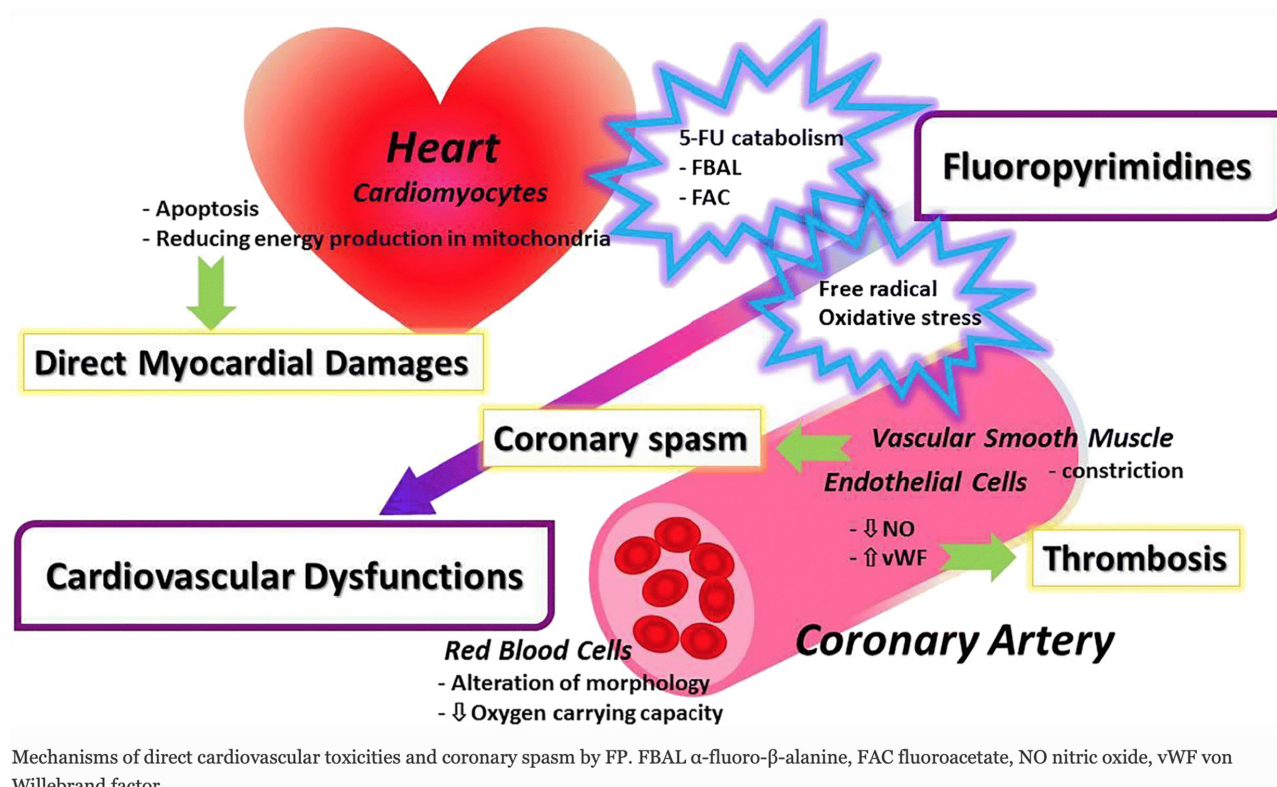


Figure 1 Mechanisms of cardiac toxicities associated with 5-FU/capecitabine Adapted from Shiga, T, Hiraide, M Cardiotoxicities of 5-Fluorouracil and Other Fluoropyrimidines. *Curr. Treat. Options in Oncol.* 2020;21(27). This article is licensed under a Creative Commons Attribution 4.0 International License, <http://creativecommons.org/licenses/by/4.0/>.⁶

a continuous infusion schedule or oral capecitabine. Based on these observations, we further investigated the feasibility and safety that bolus 5-FU can be an alternative for patients who have developed cardiotoxicity while receiving 5-FU or capecitabine. To date, we have treated up to 13 patients safely with bolus 5-FU. Table 4 summarizes the published cases of successful rechallenge with bolus 5-FU in patients who developed cardiotoxicity with infusional or oral fluoropyrimidine.^{24,25}

Interestingly, capecitabine was rechallenged in few of these patients in our experience but sadly all of them developed similar symptoms, leading to cessation of the drug. It is of utmost importance to understand that the experience with this strategy is limited to only a few cases and that bolus 5-FU has also been associated with cardiac toxicity as well. We believe that 5-FU is rapidly cleared from the blood stream following bolus 5-FU (half-life of 15–20 minutes) and probably a direct effect of drug on cardiac systems is unlikely, as seen in these cases.^{24,25} However, at present we do not endorse use of bolus 5-FU unless done in a vigorous environment in consultation with the cardiology team and discontinue 5-FU

immediately if a cardiac event occurs. It is also important to remember that a delayed onset cardiotoxicity has also been reported in the literature and demands a close follow-up.

Switch to a Non-Fluoropyrimidine Containing Chemotherapy Regimen

Switching to a non-fluoropyrimidine-containing chemotherapy regimen is the most viable option for patients with mCRC. Table 5 summarizes the data on these regimens.

Summary

To sum up, 5-FU cardiotoxicity is an infrequent, but a real phenomenon. It is probable that 5-FU cardiotoxicity may be much more common and clinically significant than previously reported as awareness has risen due to continued use, many 5-FU based regimens, longer duration on therapy, and availability of novel agents.^{2,42,43} Although the history of pre-existing coronary artery disease may increase the risk of cardiac toxicity associated with 5-FU/capecitabine, the published data does not seem to

Table 3 Switch to a Different Fluoropyrimidine

Drug	Composition	Cardiac Safety	Mechanism of Potential Decreased Cardiac Toxicity	Comparison or Challenge After 5-FU and Capecitabine	Availability
TAS-102 (Lonsurf)	TAS-102 consists of nucleoside analog (trifluridine) and a thymidine phosphorylase inhibitor (tipiracil). ¹³	We performed a meta-analysis of 869 publications including 1877 patients. Compared with placebo, TAS-102 did not increase the risk of myocardial infarction (OR=1.97; 95% CI=0.22–17.89), hypertension (OR=0.73; 95% CI=0.37–1.44), palpitations (OR=1.51; 95% CI=0.30–7.56), cardio-pulmonary arrest (OR=0.83; 95% CI=0.11–6.32), or syncope (OR=1.50; 95% CI=0.06–37.14). ¹⁴	1. TAS 102 has a different oncological target (tri-fluorothymidine monophosphate [TF-TMP] and tri-fluorothymidine triphosphate [TF-TTP]) vs 5-FU or capecitabine (FdUMP fluorodeoxyuridine monophosphate [FdUMP] and fluorodeoxyuridine triphosphate [FdUTP]). 2. Possibly higher tumoral incorporation of FTD into DNA than its incorporation into normal tissues DNA, thereby, decreasing cardiac damage. 3. Finally, TAS 102 is not catabolized by DPD, hence cardiotoxic catabolites of 5-FU, such as FBAL, F-citrate are significantly lower quantitatively resulting in less cardiotoxicity.	In the registration Phase III study that led to its FDA approval, only one patient treated with TAS-102 was reported to have an episode of cardiac ischemia among 800 treated patients who have been exposed to 5-FU previously. ¹⁵	Approved only for refractory colon and gastric cancer at present in the US.
S-1	S-1 contains tegafur (FF) and two types of enzyme inhibitor, gimeracil/ 5-chloro-2,4-dihydropyridine (CDHP) a potent inhibitor of DPD and potassium oxonate (Oxo) which inhibits phosphorylation of intestinal 5-FU in a molar ratio of 1:0.4:1. ¹⁶	In the published Phase II or III studies of S-1, no grade III or IV cardiovascular events were reported. ¹⁶	1. S-1 is an oral DPD inhibitory fluoropyrimidine (DIF) based on a biochemical modulation of 5-FU. Gimeracil is a highly active reversible DPD inhibitor, 180-fold more active than uracil (the DPD inhibitor in UFT). Because of the significant DPD inhibition by gimeracil, levels of cardiotoxic catabolites of 5-FU levels are significantly lower than after capecitabine or I.V. 5-FU administration, and hence less cardiotoxicity can be expected. ¹⁷	Experience with S-1 in CRC patients with previous 5-FU- or capecitabine-induced cardiotoxicity is limited to anecdotal reports. ¹⁸	S-1 is approved in Japan, China, Taiwan, Korea, Singapore, and European countries but not available in the US.
UFT	Combination of ftorafur with uracil, which UFT. Uracil competitively inhibits the enzyme DPD, leading to higher intratumoral concentrations of 5-FU. ¹⁹	In animal experiments, adding uracil to tegafur reduced cardiotoxicity as compared with tegafur alone. ¹⁵ Cardiotoxicity, such as angina pectoris, arrhythmia, congestive heart failure, myocardial infarction, and cardiac arrest have been reported in only 1% with UFT than with 5-FU or capecitabine. ¹⁹	Uracil is a natural substrate for DPD, and competes with 5-FU for this enzyme, reducing the degradation of 5-FU to its toxic metabolites FBAL and F-citrate.	The experience with this strategy is limited to isolated case reports. However, report of death of one patient following rechallenge with UFT who had prior cardiotoxicity associated with I.V. 5-FU (De Gramont's schedule) has been published. ²⁰	UFT has been in widespread use in many areas worldwide, including Japan, Asia, South America, and Spain for over 20 years. UFT is not available in the US.

(Continued)

Table 3 (Continued).

Drug	Composition	Cardiac Safety	Mechanism of Potential Decreased Cardiac Toxicity	Comparison or Challenge After 5-FU and Capecitabine	Availability
Raltitrexed	Raltitrexed is chemically similar to folic acid and is in the class of chemotherapy drugs called folate antimetabolites, which inhibit one or more of three enzymes that use folate and derivatives as substrates: DHFR, GARFT and thymidylate synthase. Raltitrexed is fully active after polyglutamylation, which allows cellular retention of the drug. By inhibiting Thymidylate synthase (TS), thus formation of precursor pyrimidine nucleotides, raltitrexed prevents the formation of DNA and RNA, which are required for the growth and survival of both normal cells and cancer cells. ²¹	Raltitrexed alone as well as in combination with oxaliplatin or irinotecan provides a safe option in terms of cardiac toxicity for such patients based on previous studies. ²²	The metabolism of raltitrexed is independent of DPD. Other than its intracellular polyglutamation, raltitrexed is not metabolized and is excreted largely unchanged in the urine.	Ransom et al have published a successful rechallenge with raltitrexed in 42 patients with mCRC who had to stop 5-FU or capecitabine due to cardiotoxicity. No patient suffered any subsequent cardiac problems. ²³	Overall, raltitrexed is considered inferior to 5-FU because of higher treatment-related mortality and is therefore not widely available. Currently, available in Canada, Europe, Singapore, and Middle East only.

Table 4 Summary of Few Cases Rechallenged with Bolus 5-FU

Pt. No	Age, Years	Sex	Regimen	Re-Challenge with Bolus 5-FU	Outcome
1	35	M	FOLFOX	FLOX	Tolerated without cardiac symptoms and signs
2	34	M	5-FU CIV with concurrent XRT	Bolus 5-FU with LCV on Mon/Wed/Fri per week	Tolerated without cardiac symptoms and signs
3	54	M	FOLFOX	FLOX	Tolerated without cardiac symptoms and signs
4	39	M	5-FU CIV with concurrent XRT	Bolus 5-FU with LCV on Mon/Wed/Fri per week	Tolerated without cardiac symptoms and signs
5	56	M	5-FU CIV with concurrent XRT	Bolus 5-FU with LCV on Mon/Wed/Fri per week	Tolerated without cardiac symptoms and signs
6	61	M	ECF	Weekly bolus 5-FU and LCV	Tolerated without cardiac symptoms and signs

Abbreviations: FOLFOX: oxaliplatin, 5-FU and leucovorin; ECF: Epirubicin, cisplatin and 5-FU, NA: not available; LCV: leucovorin, CIV: continuous infusion of 5-FU, XRT: radiotherapy

Table 5 Non-Fluoropyrimidine Containing Chemotherapy Regimen

Agent	Line of Therapy	Any Potential Cardiac Toxicity
Irinotecan as a single agent	Second-line irinotecan alone for advanced CRC ²⁶	Not reported.
Irinotecan in combination with Cetuximab	Cetuximab plus irinotecan with irinotecan alone after fluoropyrimidine and oxaliplatin failure in mCRC patients with KRAS wild type. ²⁷	Not reported.
Irinotecan in combination with aflibercept (zaltrap)	Velour study showed superiority of FOLFIRI plus aflibercept compared to FOLFIRI in patients who have failed oxaliplatin-based regimen with or without bevacizumab. ²⁸	Like other anti-VEGF agents are known to cause arterial thromboembolism.
Oxaliplatin as a single agent	Oxaliplatin as monotherapy was initially approved in the second-line setting in Europe. ²⁹ However, later studies showed inferiority of oxaliplatin over its combination with 5-FU. Monotherapy use of oxaliplatin is generally not recommended, especially in the US, based on ECOG E3200 study.	No known cardiotoxicity.
Combining irinotecan with oxaliplatin (IROX)	IROX regimen has documented activity in phase III studies in first and second-line treatment of metastatic CRC. ³⁰ But it is important to remember that the efficacy of IROX was significantly inferior to FOLFOX in first-line treatment. In second-line treatment after 5-FU failure, IROX was found to be superior to irinotecan monotherapy. ³¹	Not reported.
Cetuximab or panitumumab monotherapy	Cetuximab and panitumumab are active as a single agent in chemorefractory mCRC patients with K-RAS wild type tumors. ^{32,33}	Not reported.
Regorafenib	Regorafenib has been approved to treat mCRC that has progressed after all standard therapies (fluoropyrimidine-, oxaliplatin-, and irinotecan-based chemotherapy, an anti-VEGF therapy, and, if KRAS wild type, an anti-EGFR therapy). ³⁴	Like other anti-VEGF agents are known to cause arterial thromboembolism.
TAS-102	TAS-102 has been approved to treat mCRC that has progressed after all standard therapies (fluoropyrimidine-, oxaliplatin-, and irinotecan-based chemotherapy, an anti-VEGF therapy, and, if KRAS wild type, an anti-EGFR therapy). ¹⁵	In the registration RECURSE phase III study that led to its FDA approval, only one patient treated with TAS-102 was reported to have an episode of cardiac ischemia among 800 treated patients who have been exposed to 5-FU previously.
Immunotherapy (for MSI-high)	In May 2017, the FDA granted approval for using pembrolizumab, a programmed cell death protein 1 (PD-1) antibody, in patients with microsatellite unstable mCRC. ³⁵	Cases of cardiotoxicity, such as myocarditis, Tako-Tsubo cardiomyopathy, cardiac arrest, myocardial infarction, have been reported, that usually occur immediately after the infusion or during the first year of therapy.
Mitomycin (MMC)	Data does not support use of single agent based on a multicenter, multinational analysis of mitomycin C in refractory metastatic colorectal cancer. ³⁶ MIXE regimen (mitomycin plus capecitabine) has shown activity as salvage therapy but cannot be recommended due to capecitabine's cardiotoxicity previously discussed. ³⁷	MMC has been implicated as a possible cardiotoxic agent (CHF).
Mitomycin (MMC) + Oxaliplatin (MOX)	One possible alternative regimen is MOX (mitomycin with oxaliplatin) which has shown some activity in salvage setting of mCRC. ³⁸ We recently published the first case series that reports the safety and feasibility of s-MOX in patients with mCRC who developed cardiac toxicity to 5-FU or capecitabine. ^{4,8,9,39}	Overall, the s-MOX regimen was well tolerated. The most common toxicities included < grade 2 peripheral neuropathy, nausea, vomiting, thrombocytopenia, and anemia. ³⁸

(Continued)

Table 5 (Continued).

Agent	Line of Therapy	Any Potential Cardiac Toxicity
Mitomycin (MMC) + Irinotecan (MIRI)	MIRI regimen (mitomycin with irinotecan) has also shown some activity in salvage setting of mCRC. ^{39,40} We have developed a modified regimen (s-MIRI – unpublished) administering mitomycin 7mg/m ² on day 1 and irinotecan 150 mg/m ² on day 1 and day 15 every 28 days (unpublished) which was found to be safer without any recurrent cardiac toxicities in five patients who had previously encountered cardiotoxicity to 5-FU and/or capecitabine (unpublished).	s-MIRI did not result in recurrent cardiac toxicities in five patients who had previously encountered cardiotoxicity to 5-FU and/or capecitabine (unpublished).
TAS-102	TAS-102 shares similarities with fluoropyrimidines, but its mechanism of action is distinct. In some investigators' opinion, switching to TAS-102 should be considered as switching to a non-fluoropyrimidine. ^{13,14}	There is ample data suggesting that TAS-102 is the first "cardio-gentle" fluoropyrimidine in the colorectal cancer landscape. ⁴¹
Combination of other oral fluoropyrimidines (S-1 and UFT) with irinotecan (TEGAFIRI), oxaliplatin (TEGAFOX, UFOX) are also viable options outside the US.		

underline the predictive value of the presence of cardiac risk factors for the development of 5-FU-induced cardiac side-effects. Therefore, caution must be taken in treating these patients and if any signs or symptoms suggest cardiotoxicity, the drug should be suspended and a thorough work-up must be performed with multidisciplinary approach.

Despite a known benefit of nitrates and calcium channel blockers in ischemic heart disease, the effectiveness of this prophylactic therapy in patients receiving 5-FU/capecitabine has not been consistent.^{10–12} Few other reports indicated that beta-blockers should be avoided as they can be spasmogenic. Use of prophylactic use of anti-anginal agents has not been consistent. Cianci et al⁴⁴ reported their experience with three cases of 5-FU-associated cardiotoxicity who received prophylactic transepidermal nitroglycerin. In this case series, they reported that the patients did not develop ischemic symptoms, such as angina. Kinhult et al⁴⁵ showed that dalteparin, an antithrombotic, can protect against thrombogenic effects of 5-FU, secondary to its direct toxic effect on the vascular endothelium.

We recommend assessment of traditional cardiovascular risk factors and optimal management of cardiovascular disease, as a part of routine care for all patients before, during, and after receiving 5-FU/capecitabine (Table 6). However, in any patient who develops symptoms suggestive of ischemia, such as angina and/or electrocardiographic evidence of myocardial ischemia during the administration of 5-FU and capecitabine, termination of chemotherapy and administration of nitrates or calcium channel blockers should be considered

under close observation. Cardiology consultation must be carried out and risk stratification should be performed. It is important to keep in mind that rechallenging these patients with similar agents can result in reoccurrence of cardiac toxicity. In addition to ischemic toxicity, arrhythmias also

Table 6 Suggested Recommendations

Pre-treatment
History: Cardiac disease, risk factors, cardiotoxic medications Family History Exam: Cardiac, weight Tests: Baseline EKG
During treatment
Monitor for cardiovascular symptoms Weight and Fluid balance Electrolyte monitoring (especially when used in combination with cisplatin) Be careful when administering 5-FU with other cardiotoxic drugs, including anti-VEGF agents Immediately stop infusion or capecitabine if cardiovascular symptom develops (including hypotension) Treat with conventional therapy for such cardiac event Complete cardiac work-up
Re-challenge
Only perform in selected patients if clinically important and no alternate therapy available Close monitoring Consider continuous electrocardiographic monitoring Consult a cardiologist Otherwise consider alternative treatment options

occur in these patients. Therefore, ECG monitoring is recommended if there is any suspicion leading to cardiotoxicity of these agents.⁴⁶ In addition to non-invasive diagnostic tests, coronary angiography should be considered in patients who develop ischemia during or following 5-FU/capecitabine. Cardiac toxicity with newer oral 5-FU agents seem to be of less frequency, especially TAS-102, which is more widely available compared to older agents, such as S-01 or S-1 or UFT. In the adjuvant setting, only UFT and raltitrexid as a single agent have documented activity in randomized phase III trials, and experience with combination regimens is scarce. As mentioned earlier, re-challenge with 5-FU/capecitabine after an episode of cardiac toxicity to these agents can pose a higher risk of complications, including sudden cardiac death.² Therefore, one must consider immediate termination of these chemotherapeutic drugs and modification of the treatment regimen.

It is worth-mentioning here that in 2015, uridine triacetate, an oral active prodrug of uridine, which is a naturally occurring nucleoside and competes with the 5-FU metabolite for incorporation into RNA of normal tissue, was approved by the Food and Drug Administration (FDA) as an antidote to 5-FU (or capecitabine).⁴⁷ In a study, 137 of 142 overdose patients who were treated with uridine triacetate had a rapid reversal of severe acute cardiotoxicity.⁴⁷ The indications included use of uridine triacetate in patients with overdose or for those who exhibit early-onset, severe, or life-threatening toxicity affecting the cardiac or central nervous system, and/or early onset, unusually severe adverse reactions (eg, gastrointestinal toxicity and/or neutropenia). It is worth mentioning here that overdose of 5-FU/capecitabine is not the most responsible for its cardiotoxicity. In fact, the majority is regarding to normal chemotherapy regimens and not overdose. At present, the use of this antidote to prevent or treat cardiac toxicity of 5-FU has not been studied and warrants future studies to clarify its role in the treatment of fluoropyrimidine associated cardiotoxicity.

Funding

Partly funded by R01 CA085381.

Disclosure

The author reports no conflicts of interest for this work.

References

1. Myers CE. The pharmacology of the fluoropyrimidines. *Pharmacol Rev*. 1981;33:1–15.

- Saif MW, Shah MM, Shah AR. Fluoropyrimidine-associated cardiotoxicity: revisited. *Expert Opin Drug Saf*. 2009;8(2):191–202. doi:10.1517/14740330902733961
- Anand AJ. Fluorouracil cardiotoxicity. *Ann Pharmacother*. 1994;28(3):374–378. doi:10.1177/106002809402800314
- Saif MW, Tomita M, Ledbetter L, Diasio RB. Capecitabine-related cardiotoxicity: recognition and management. *J Support Oncol*. 2008;6(1):41–48.
- Norwood RA, Lokich JJ, Moore C. The syndrome of 5-fluorouracil cardiotoxicity: an elusive cardiopathy. *Cancer*. 1993;72:2287–2288.
- Shiga T, Hiraide M. Cardiotoxicities of 5-Fluorouracil and other fluoropyrimidines. *Curr Treat Options in Oncol*. 2020;21(27). doi:10.1007/s11864-020-0719-1
- Jensen SA, Sorensen JB. Risk factors and prevention of cardiotoxicity induced by 5-fluorouracil or capecitabine. *Cancer Chemother Pharmacol*. 2006;58:487–493. doi:10.1007/s00280-005-0178-1
- Kwakman JJ, Simkens LH, Mol L, Kok WE, Koopman M, Punt CJ. Incidence of capecitabine-related cardiotoxicity in different treatment schedules of metastatic colorectal cancer: A retrospective analysis of the CAIRO studies of the Dutch colorectal cancer group. *Eur J Cancer*. 2017;76:93–99. doi:10.1016/j.ejca.2017.02.009
- Van Cutsem E, Hoff PM, Blum JL, et al. Incidence of cardiotoxicity with the oral fluoropyrimidine capecitabine is typical of that reported with 5-fluorouracil. *Ann Oncol*. 2002;13:484–485. doi:10.1093/annonc/mdf108
- Akpek G, Hartshorn KL. Failure of oral nitrate and calcium channel blocker therapy to prevent 5-fluorouracil-related myocardial ischemia: a case report. *Cancer Chemother Pharmacol*. 1999;43(2):157–161. doi:10.1007/s002800050877
- Olekowicz L, Bruckner HW. Prophylaxis of 5-fluorouracil-induced coronary vasospasm with calcium channel blockers. *Am J Med*. 1988;85:750–751. doi:10.1016/S0002-9343(88)80268-7
- Eskilsson J, Albertsson M. Failure of preventing 5-fluorouracil cardiotoxicity by prophylactic treatment with verapamil. *Acta Oncol*. 1990;29(8):1001–1003. doi:10.3109/02841869009091790
- Chen J, Han M, Saif MW. TAS-102 an Emerging Oral Fluoropyrimidine. *Anticancer Res*. 2016;36(1):21–26.
- Lopez CA, Azimi-Nekoo E, Chung SY, Newman J, Shen J, Saif MW. Meta-analysis and systematic review of the cardiotoxicity of TAS-102. *JCO*. 2020;38:e16053e16053. doi:10.1200/JCO.2020.38.15_suppl.e16053
- Mayer RJ, Van Cutsem E, Falcone A, et al. Randomized trial of TAS-102 for refractory metastatic colorectal cancer. *N Engl J Med*. 2015;372(20):1909–1919. doi:10.1056/NEJMoa1414325
- Saif MW, Syrigos KN, Katirtzoglou NA. S-1: a promising new oral fluoropyrimidine derivative. *Expert Opin Investig Drugs*. 2009;18(3):335–348. doi:10.1517/13543780902729412
- Saif MW, Rosen LS, Saito K, Zergebel C, Ravage-Mass L, Mendelson DS. A Phase I study evaluating the effect of CDHP as a component of S-1 on the pharmacokinetics of 5-fluorouracil. *Anticancer Res*. 2011;31(2):625–632.
- Franck C, Malfertheiner P, Venerito M. Safe administration of S-1 after 5-fluorouracil-induced cardiotoxicity in a patient with colorectal cancer. *BMJ Case Rep*. 2017;2017:bcr2016219162. doi:10.1136/bcr-2016-219162
- Yamamoto J, Haruno A, Yoshimura Y, et al. Effect of coadministration of uracil on the toxicity of tegafur. *J Pharm Sci*. 1984;73:212–214. doi:10.1002/jps.2600730217
- Kikuchi K, Majima S, Murakami M. Clinical survey on cardiotoxicity of tegafur (FT-207) compilation of a nationwide survey. *Gan to Kagaku Ryoho*. 1982;9(8):1482–1488.
- Köhne CH, Thuss-Patience P, Friedrich M, et al. Raltitrexid (Tomudex): an alternative drug for patients with colorectal cancer and 5-fluorouracil associated cardiotoxicity. *Br J Cancer*. 1998;77(6):973–977. doi:10.1038/bjc.1998.160

22. Van Cutsem E, Cunningham D, Maroun J, Cervantes A, Glimelius B. Raltitrexed: current clinical status and future directions. *Ann Oncol.* 2002;13(4):513-522. doi:10.1093/annonc/mdf054
23. Ransom D, Wilson K, Fournier M, et al. Final results of australasian gastrointestinal trials group ARCTIC study: an audit of raltitrexed for patients with cardiac toxicity induced by fluoropyrimidines. *Ann Oncol.* 2014;25:117-121. doi:10.1093/annonc/mdt479
24. Saif MW, Garcon MC, Rodriguez G, Rodriguez T. Bolus 5-fluorouracil as an alternative in patients with cardiotoxicity associated with infusion 5-fluorouracil and capecitabine: a case series. *In vivo.* 2013;27(4):531-534.
25. Shaib W, Lee V, Saif MW. Bolus 5-fluorouracil as an alternative modality to infusion 5-fluorouracil in a patient with rectal cancer and capecitabine-induced cardiotoxicity. *Vivo.* 2009;23(5):821-826.
26. Fuchs CS, Moore MR, Harker G, et al. Phase III comparison of two irinotecan dosing regimens in second-line therapy of metastatic colorectal cancer. *J Clin Oncol.* 2003;21:807-814. doi:10.1200/JCO.2003.08.058
27. Cunningham D, Humblet Y, Siena S, et al. Cetuximab monotherapy and cetuximab plus irinotecan in irinotecan-refractory metastatic colorectal cancer. *N Engl J Med.* 2004;351:337-345. doi:10.1056/NEJMoa033025
28. Van Cutsem E, Joulain F, Hoff PM, et al. Aflibercept plus FOLFIRI vs. Placebo plus FOLFIRI in second-line metastatic colorectal cancer: a post hoc analysis of survival from the phase III Velour study subsequent to exclusion of patients who had recurrence during or within 6 months of completing adjuvant oxaliplatin-based therapy. *Target Oncol.* 2016;11(3):383-400.
29. Becouarn Y, Rougier P. Clinical efficacy of oxaliplatin monotherapy: phase II trials in advanced colorectal cancer. *Semin Oncol.* 1998;25(2 Suppl 5):23-31.
30. Grivicich I, Mans DR, Peters GJ, Schwartzmann G. Irinotecan and oxaliplatin: an overview of the novel chemotherapeutic options for the treatment of advanced colorectal cancer. *Braz J Med Biol Res.* 2001;34(9):1087-1103. doi:10.1590/S0100-879X2001000900001
31. Haller DG, Rothenberg ML, Wong AO, et al. Oxaliplatin plus irinotecan compared with irinotecan alone as second-line treatment after single-agent fluoropyrimidine therapy for metastatic colorectal carcinoma. *J Clin Oncol.* 2008;26(28):4544-4550. doi:10.1200/JCO.2008.17.1249
32. Jonker DJ, O'Callaghan CJ, Karapetis CS, et al. Cetuximab for the treatment of colorectal cancer. *N Engl J Med.* 2007;357:2040-2048. doi:10.1056/NEJMoa071834
33. Van Cutsem E, Peeters M, Siena S, et al. Open-label phase III trial of panitumumab plus best supportive care compared with best supportive care alone in patients with chemotherapy-refractory metastatic colorectal cancer. *J Clin Oncol.* 2007;25:1658-1664. doi:10.1200/JCO.2006.08.1620
34. Grothey A, Van Cutsem E, Sobrero A, et al. Regorafenib monotherapy for previously treated metastatic colorectal cancer (CORRECT): an international, multicenter, randomized, placebo-controlled, Phase 3 trial. *Lancet.* 2013;381(9863):303-312. doi:10.1016/S0140-6736(12)61900-X
35. Le DT, Kim TW, Van Cutsem E, et al. Phase II open-label study of pembrolizumab in treatment-refractory, microsatellite instability-high/mismatch repair-deficient metastatic colorectal cancer: KEYNOTE-164. *J Clin Oncol.* 2020;38(1):11-19. doi:10.1200/JCO.19.02107
36. Ferrarotto R, Machado K, Mak MP, et al. A multicenter, multinational analysis of mitomycin C in refractory metastatic colorectal cancer. *Eur J Cancer.* 2012;48:820-826. doi:10.1016/j.ejca.2012.01.008
37. Saif MW, Kaley K, Brennan M, Garcon MC, Rodriguez G. Mitomycin-C and capecitabine (MIXE) as salvage treatment in patients with refractory metastatic colorectal cancer: a retrospective study. *Anticancer Res.* 2013;33(6):2743-2746.
38. Ehrlich MI, Kaley K, Smith M, Saif WM. Safety and efficacy of s-MOX regimen in patients with colorectal cancer who developed cardiotoxicity following fluoropyrimidine administration: a case series. *Arch Med Case Rep.* 2020;2(1):23-29.
39. Scheithauer W, Kornek GV, Brugger S, et al. Randomized phase II study of irinotecan plus mitomycin C vs. oxaliplatin plus mitomycin C in patients with advanced fluoropyrimidine/leucovorin-pretreated colorectal cancer. *Cancer Invest.* 2002;20(1):60-68. doi:10.1081/CNV-120000367
40. Comella P, Biglietto M, Casaretti R, et al. Irinotecan and mitomycin C in 5-fluorouracil-refractory colorectal cancer patients. A phase I/II study of the Southern Italy cooperative oncology group. *Oncology.* 2001;60(2):127-133. doi:10.1159/000055309
41. Petrelli F, Barni S, Bertocchi P, Zaniboni A. TAS-102, the first "cardio-gentle" fluoropyrimidine in the colorectal cancer landscape? *BMC Cancer.* 2016;16:386. doi:10.1186/s12885-016-2409-8
42. Stewart T, Pavlakis N, Ward M, et al. Cardiotoxicity with 5-fluorouracil and capecitabine: more than just vasospastic angina. *Intern Med J.* 2010;40:303-307. doi:10.1111/j.1445-5994.2009.02144.x
43. Saif MW, Smith M, Maloney A. The first case of severe takotsubo cardiomyopathy associated with 5-fluorouracil in a patient with abnormalities of both dihydropyrimidine Dehydrogenase (DPYD) and Thymidylate Synthase (TYMS) genes. *Cureus.* 2016;8(9):e783.
44. Cianci G, Morelli MF, Cannita K, et al. Prophylactic options in patients with 5-fluorouracil-associated cardiotoxicity. *Br J Cancer.* 2003;88(10):1507-1509. doi:10.1038/sj.bjc.6600967
45. Kihnult S, Albertsson M, Eskilsson JCM, et al. Antithrombotic treatment in protection against thrombotic effects of 5-fluorouracil on vascular endothelium: a scanning microscopy evaluation. *Scanning.* 2001;23:1-8. doi:10.1002/sca.4950230101
46. Rezkalla S, Kloner RA, Ensley J, et al. Continuous ambulatory ECG monitoring during fluorouracil therapy: a prospective study. *J Clin Oncol.* 1989;7:509-514. doi:10.1200/JCO.1989.7.4.509
47. Ma WW, Saif MW, El-Rayes BF, et al. Emergency use of uridine triacetate for the prevention and treatment of life-threatening 5-fluorouracil and capecitabine toxicity. *Cancer.* 2017;123:345. doi:10.1002/encr.30321

OncoTargets and Therapy

Publish your work in this journal

OncoTargets and Therapy is an international, peer-reviewed, open access journal focusing on the pathological basis of all cancers, potential targets for therapy and treatment protocols employed to improve the management of cancer patients. The journal also focuses on the impact of management programs and new therapeutic

agents and protocols on patient perspectives such as quality of life, adherence and satisfaction. The manuscript management system is completely online and includes a very quick and fair peer-review system, which is all easy to use. Visit <http://www.dovepress.com/testimonials.php> to read real quotes from published authors.

Submit your manuscript here: <https://www.dovepress.com/oncotargets-and-therapy-journal>