



Since January 2020 Elsevier has created a COVID-19 resource centre with free information in English and Mandarin on the novel coronavirus COVID-19. The COVID-19 resource centre is hosted on Elsevier Connect, the company's public news and information website.

Elsevier hereby grants permission to make all its COVID-19-related research that is available on the COVID-19 resource centre - including this research content - immediately available in PubMed Central and other publicly funded repositories, such as the WHO COVID database with rights for unrestricted research re-use and analyses in any form or by any means with acknowledgement of the original source. These permissions are granted for free by Elsevier for as long as the COVID-19 resource centre remains active.



Contents lists available at ScienceDirect

Journal of Clinical and Translational Endocrinology: Case Reports

journal homepage: www.elsevier.com/locate/jctecasereports.com

Pituitary apoplexy after COVID-19 vaccination: A case report

Nur Aisyah Zainordin^{a,*}, Sharifah Faradila Wan Muhammad Hatta^a, Nazimah Ab Mumin^b, Fatimah Zaherah Mohd Shah^a, Rohana Abdul Ghani^a

^a Internal Medicine Discipline, Faculty of Medicine, University Technology MARA, Jalan Hospital, 47000, Sungai Buloh, Selangor, Malaysia

^b Radiology Department, Faculty of Medicine, University Technology MARA, Jalan Hospital, 47000, Sungai Buloh, Selangor, Malaysia

ARTICLE INFO

Keywords:

Pituitary apoplexy
Covid-19 vaccination
Pituitary hypophysitis

ABSTRACT

Background: Pituitary apoplexy is a rare endocrine emergency, which commonly presents with headache and is occasionally associated with visual disturbances. Prompt diagnosis and treatment can be both life and vision saving. In the emergence of novel coronavirus and global pandemic, rapid development of new vaccines have shown to reduce morbidity and mortality associated with Covid-19. Recognition of rare potential adverse effects of these vaccines including pituitary apoplexy are yet to be reported. A causal link between pituitary apoplexy and COVID-19 vaccination has not been established.

Case presentation: We report a case of a 24-year-old woman who presented with progressively worsening headache soon after completing her COVID-19 vaccination. Imaging showed pituitary apoplexy with an underlying pituitary mass. In view of the age and the typical presentation of severe headache, pituitary hypophysitis was considered, despite the absence of the almost pathognomonic feature of a thickened pituitary stalk in the initial imaging. In the context that the headache had started shortly after the administration of the second dose of COVID-19 vaccine, this potentially could have been the trigger for the occurrence of pituitary apoplexy.

Conclusion: Although the pathophysiology is not entirely clear and no direct link could be ascertained, our patient may have developed an exaggerated immunological response after the vaccine, with a possible pituitary hypophysitis leading to a pituitary apoplexy.

1. Background

As of June 2022, the World Health Organization (WHO) estimated over 544 million confirmed coronavirus disease 2019 (COVID-19) cases and 12 billion vaccinations had been administered [1]. With a total mortality approaching 6.4 million, the coronavirus pandemic has impacted health, economical and social aspects of every country in the world. Since the outbreak of COVID-19, ongoing efforts have been made to discover effective vaccines against the disease. In most countries, both mRNA and DNA vaccines have been administered, and their side effects have also been extensively reported.

The Pfizer–BioNTech (BNT162b2) COVID-19 vaccine, the AstraZeneca (ChAdOx1 nCov-19), which uses recombinant adenovirus vector derived from chimpanzees, and the Sinovac COVID-19 vaccination (Sinovac Biotech, China) are three vaccines that have been approved to be administered in Malaysia. Out of the three vaccines, AstraZeneca was the least vaccine administered, ie approximately to 8.2% of the

vaccinated population [2,3].

There had been issues surrounding the prothrombotic sequelae of the AstraZeneca vaccine, with numerous cases of venous sinus thrombosis being reported in previously fit and well recipients. However, to date, occurrences of pituitary apoplexy following COVID-19 vaccination had only been reported twice [4]. Here, we present the case of a previously healthy 24-year-old female who developed pituitary apoplexy following the second dose of an AstraZeneca COVID-19 vaccine. This case demonstrates the need for heightened clinical awareness towards potential complications of COVID-19 and its vaccines, even in the setting of other known or presumed differential diagnoses. This could avoid anchoring bias and expedite appropriate care.

2. Case Presentation

A 24-year-old female with no known medical illness, presented with sudden onset of severe frontal headache that she described as the “worst

* Corresponding author. Endocrine Unit, Internal Medicine Discipline, Faculty of Medicine, University Technology MARA, Jalan Hospital, 47000, Sungai Buloh, Selangor, Malaysia.

E-mail address: aisyahzack@gmail.com (N.A. Zainordin).

<https://doi.org/10.1016/j.jecr.2022.100123>

Received 1 March 2022; Received in revised form 27 June 2022; Accepted 24 July 2022

Available online 4 August 2022

2214-6245/© 2022 The Authors. Published by Elsevier Inc. This is an open access article under the CC BY-NC-ND license (<http://creativecommons.org/licenses/by-nc-nd/4.0/>).

headache ever". The headache had started about a week prior to her presentation, which was one day after receiving her second AstraZeneca vaccine dose and had gradually worsened. Upon further history, she has had long standing history of similar nature of headache, which was mild to moderate generalized throbbing headache mainly on the left temporal area since the age of 15. However, the headaches were generally responsive to simple analgesia, which did not require further hospital treatment. Hence, her headache was never been investigated before. She denied other symptoms including blurring of vision, eye pain and diplopia. There was no recent history of galactorrhea and her menstrual cycles had been regular 28-30-day cycles. She noted gradual weight increment of 3–4 kg within the past 6 months, which was likely due to lack of physical activity during the nationwide restricted movement disorders. Otherwise, there were no other features to suggest any obvious underlying endocrine disorders.

On admission, her blood pressure was 120/80 mmHg, with no evidence of postural hypotension. She was overweight with a body mass index (BMI) of 29kg/m². Confrontational visual field assessment was normal with no evidence of bitemporal hemianopia. Neurological examination was grossly normal. There were no features to suggest acromegaly or Cushing syndrome. Formal eye assessments subsequently showed normal fundus and visual fields bilaterally.

Blood tests revealed polycythemia (haemoglobin 16.1g/dL) and leukocytosis ($17 \times 10^9/L$), with normal platelet, coagulation profile, renal profile, liver enzymes, and C-reactive protein. Screening for COVID-19 with nasopharyngeal polymerase chain reaction (PCR) test at admission was negative.

Initial non-contrast-enhanced computed tomography (CT) of the brain showed a sellar region mass, likely arising from the pituitary gland (Fig. 1). A magnetic resonance imaging (MRI) of the pituitary was subsequently performed, which showed a heterogenous enhancement of the pituitary gland, (more within the periphery), extending to the

suprasellar region, measuring approximately 1.1cm × 1.6 × 1.9cm (AP x W x CC) (Fig. 2). It was hypointense centrally with high signal in the periphery on T1W images, heterogenous, hyperintense signal on T2W images with areas of low signal within, and some low signal/blooming artefacts on the T2 Gradient echo sequences (GRE) images. The pituitary stalk was unable to be delineated. There was mass effect to the optic chiasm and compression of the cavernous portion of the left internal carotid artery (ICA) (Fig. 3). These features were suggestive of pituitary apoplexy with mass effect to the optic chiasm and cavernous portion of the left ICA.

Further pituitary hormonal tests were conducted and the results are presented in Table 1. The results showed normal anterior pituitary hormone levels, with the exception of insulin-like growth factor-1 (IGF-1) at a level of 417 ng/ml. Overnight dexamethasone test was performed and showed suppressed cortisol level of 48.4 nmol/L. Growth hormone (GH) suppression test resulted in suppressed GH level of <0.1ng/ml in the presence of hyperglycemia.

In view of the high IGF-1 with normal GH, as well as an obvious sellar lesion, the diagnosis of GH-secreting pituitary macroadenoma or acromegaly was entertained. However, as the average age for the diagnosis of acromegaly has been previously reported to be within the range of 40–50 years old [5], the diagnosis seemed unlikely for this patient. Pituitary hypophysitis was, therefore, considered because of the more likely age group and the typical presentation of severe headache, despite the absence of the almost pathognomonic feature of a thickened pituitary stalk in the initial imaging. In the context that the headache had started shortly after the administration of the second dose of COVID-19 vaccine, this potentially could have been the trigger for the occurrence of pituitary apoplexy.

During her initial presentation, she was given high doses of analgesia and her symptoms abated but did not resolve. She was discharged with a referral for a Neurosurgical consult and planned for a repeat pituitary

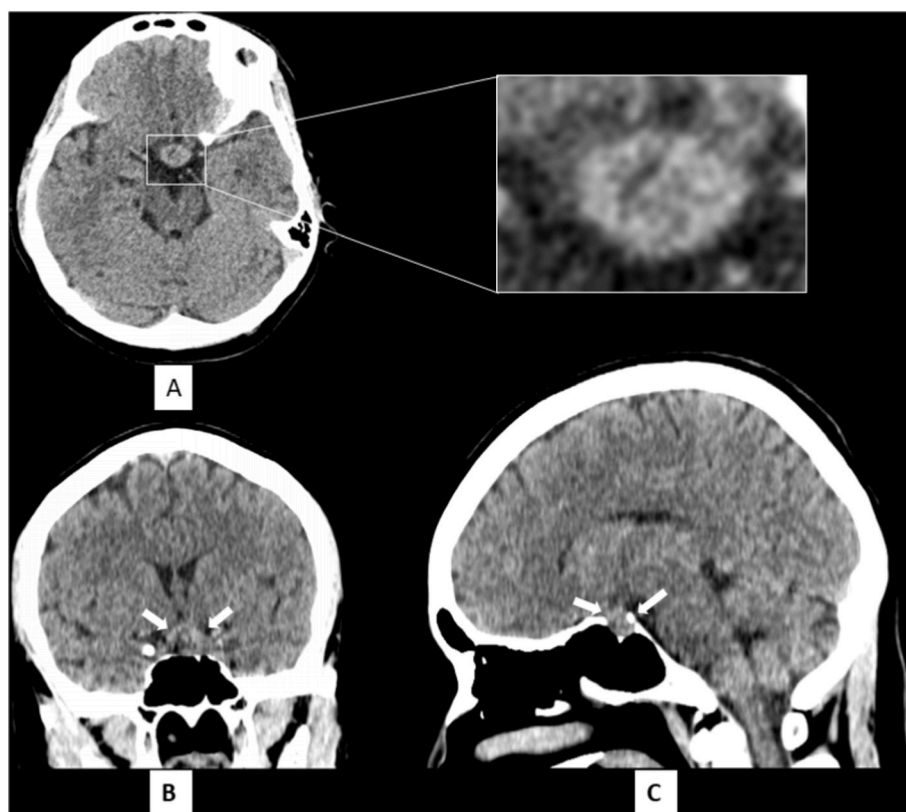


Fig. 1. Non contrast-enhanced CT Brain in axial view (A) with accompanying magnified image of the high density sellar lesion with hypodensity within. The coronal reconstructed view (B) and sagittal reconstructed view (C) demonstrates the lesion (white arrows) to occupy the whole of cavernous sinus with pressure remodelling of the floor or sella turcica. The images suggested a sellar mass and differential diagnosis at this point of time includes pituitary adenoma.

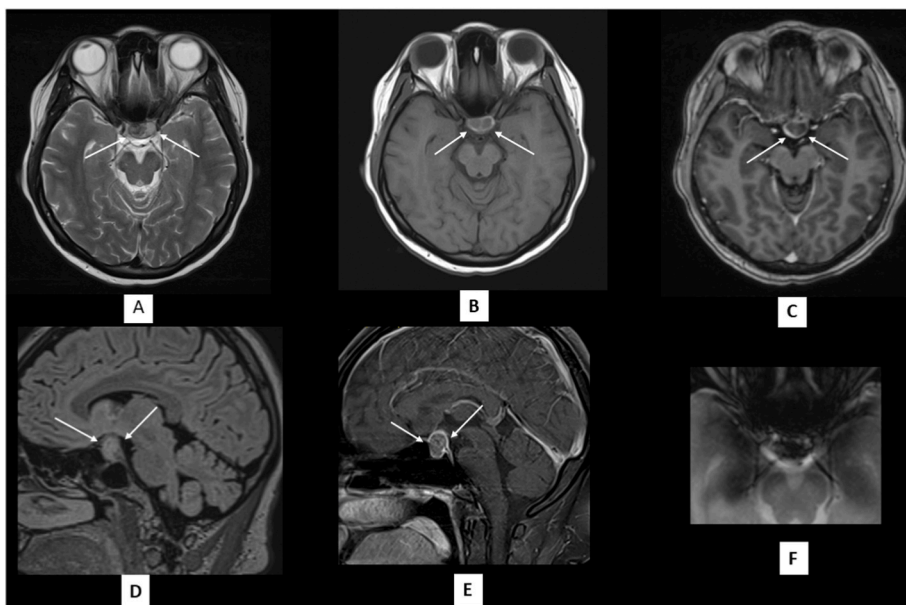


Fig. 2. Contrast-enhanced MRI brain. Axial T2 sequence (A) showing an isointense lesion with central heterogeneous low signal intensity areas within (white arrows). On Axial T1 pre-contrast (B) and T1-post contrast (C), sagittal T1 pre-contrast (D) and post-contrast (E), the lesion showed rim-enhancement (white arrows). Areas of T2 low signal are iso-intense on T1 pre-contrast. Magnified image of the lesion in axial GRE (F) showing blooming artefact within the lesion. This constellation of findings are suggestive of bleeding within a pre-existing pituitary adenoma.

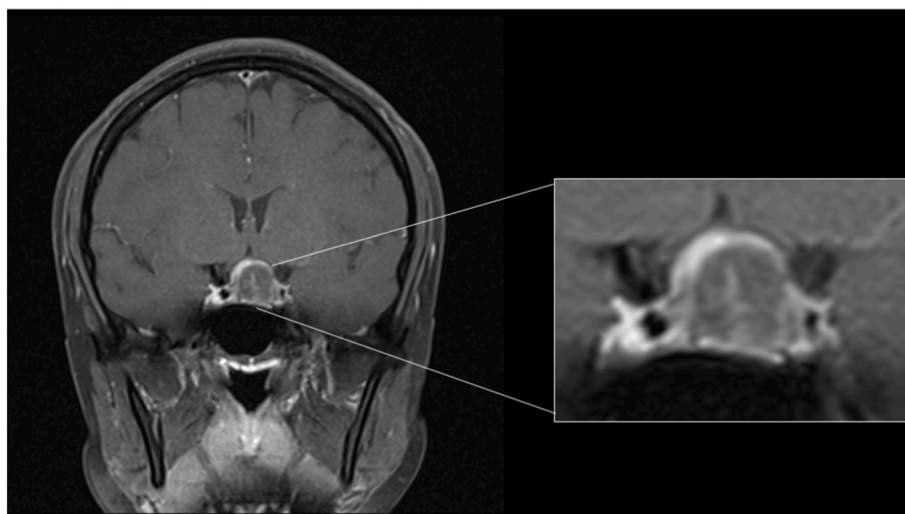


Fig. 3. Coronal T1 post-contrast with magnification of the lesion demonstrating that there is rim-enhancement with low signal intensity within the lesion.

Table 1
Pituitary hormonal workup after finding of CT brain.

INVESTIGATIONS	RESULTS	NORMAL RANGE
FSH (IU/L)	7.3	Follicular: 2.4–12.6
LH (IU/L)	12.9	Follicular: 3.5–12.6
Estradiol (pmol/L)	427.9	Follicular: 98.1–571
Am cortisol (nmol/L)	505	101–535.7
Prolactin (mIU/L)	119.5	<550
TSH (mIU/L)	1.09	0.27–4.2
FT4 (pmol/L)	19.3	12–22
IGF-1 (ng/ml)	417	98.7–289

MRI. Unfortunately, she returned with a persistently severe headache four days later. During this subsequent admission, her blood pressure was noted to be relatively low at 115/75 mmHg despite being in severe pain. The diagnosis of hypocortisolism secondary to pituitary apoplexy was considered and intravenous hydrocortisone 50mg QID was commenced, which led to improvements in her symptoms. She was discharged after 3 days with reducing doses of oral hydrocortisone.

The patient underwent a follow up pituitary MRI, which showed a significant 50% reduction in the size of the pituitary mass (Fig. 4).

However, the severe headache persisted, which required a third hospital admission a week later. After further considerations, the diagnosis of pituitary hypophysitis seemed plausible and thus hydrocortisone was changed to 0.5mg/kg dexamethasone. Three weeks later the headache had greatly improved and she generally felt much better. A repeat pituitary MRI brain will be evaluated on planned outpatient follow-up.

3. Discussion

Pituitary apoplexy is a clinical syndrome caused by an abrupt hemorrhaging and/or infarction of the pituitary gland, generally in the presence of a pituitary adenoma [6]. It can occur either spontaneously or due to a stressful trigger. It is uncommon with a prevalence of about 6.2 cases per 100,000 inhabitants [7]. Headache is the most prominent symptom of acute apoplexy and is present in more than 80% of patients [8]. Most common pituitary adenomas which developed pituitary

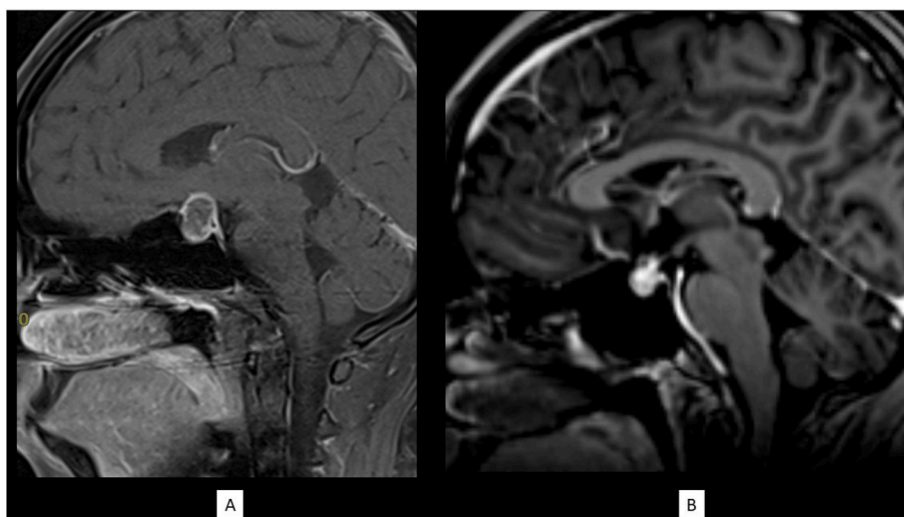


Fig. 4. Sagittal T1 post-contrast at presentation (a) in comparison with the reassessment MRI performed one month later (b). There is approximately 50% reduction in the pituitary mass lesion size.

apoplexy are non-functioning macroadenomas, prolactinomas and growth hormone secreting tumours [6]. Although over 50% of apoplexy had unknown or undiscovered precipitating events, risk factors include pregnancy, post-partum state, trauma, hypertension, and coagulopathy [6], none of which was present in our patient. In view of the close proximity between the onset of symptoms and the COVID-19 vaccine, we could only postulate that there was an association between the two. There has been an increasing number of reported thrombocytopenia, bleeding, and arterial and venous thromboses cases occurring within days to weeks after the administration of the Oxford-AstraZeneca COVID-19 vaccine [9]. Such conditions could possibly trigger pituitary apoplexy. However, we note that this was not the case for our patient whose platelet and coagulation profiles were normal.

The Oxford/AstraZeneca ChAdOx1-S/nCoV-19 [recombinant] vaccine is composed of a single recombinant chimpanzee adenovirus (ChAdOx1) vector. The vaccine expresses the S glycoprotein/spike protein of SARS-CoV-2 gene, which instructs the host cells to produce the protein of the S-antigen, allowing the body to generate an immune response and retain that information in memory immune cells [10]. Therefore, another reported hypothesis is an inflammatory response or antibody reaction leading to vascular dysfunction and predisposition towards cerebrovascular events [11]. The extensive vascular structure of the pituitary gland, and the underlying fragility of the vascular network renders it particularly vulnerable to such consequences. Furthermore, pituitary tumours are likely to outgrow their blood supply or experience compression by the expanding tumor mass, both of which could lead to ischemia due to reduced blood supply to the gland [6]. These mechanisms provide explanations on why patients with underlying pituitary adenomas are at risk for pituitary apoplexy, infarction and necrosis. Thus, we opine that this patient could have an underlying pituitary hypophysitis that could have developed an immunological reaction, triggered by the COVID-19 vaccination, resulting in an apoplexy. Covid-19 vaccination has been reported to cause pituitary hypophysitis after Moderna Covid-19 vaccine that occurs few days of vaccination [12].

Nonetheless, our patient suffered from headache since she was 15 years. It is possible that she has other undetected inherited abnormality which was not known to us since biopsy was not done. Pituitary hypophysitis perhaps could be a likely diagnosis for this patient, in view of right age group and her symptoms resolving with high dose steroids.

To date, this report would be the third reporting pituitary apoplexy after COVID-19 vaccination [3,13]. There had been a case report of pituitary apoplexy, which occurred in a 44-year-old man, who presented

with sudden onset of blurring of vision and change in mental status 3 days following the second dose of COVID-19 vaccine, in which type of vaccine was not mentioned in the report [3]. His MRI showed a suprasellar mass with optic chiasm. Unlike our patient, he underwent an endoscopic transsphenoidal resection of the pituitary tumor in view of the compression of the optic chiasm. The pathology report showed focal hemorrhage and necrosis of pituitary adenoma cells. In our patient, although a Neurosurgical consult was initially considered, a conservative approach was subsequently agreed with the patient, in view of the improvements in her symptoms and the reduction in tumor size after the initiation of high doses of corticosteroids. Full comparison is shown in Table 2.

We concur with Rajasekaran et al., that the diagnosis of pituitary apoplexy should be considered in patients presenting with acute severe headache with or without neuro-ophthalmic signs in the absence of other more common causes [14]. We considered the diagnosis of hypocortisolism in view of background diagnosis of pituitary apoplexy, severity of symptoms and relative low blood pressure in response to stress. Prompt treatment was given with corticosteroids without dynamic testing and repeat cortisol in view of severity of symptoms. Nonetheless, therapeutic strategies for pituitary apoplexy are extremely controversial. In the past, pituitary apoplexy was almost universally

Table 2

Comparison between three existing case reports.

	Zainordin et al.	Jaggi et al. [3]	Piñar-Gutiérrez A et al. [13]
Age	24 year old female	44 year old male	37 year old female
Underlying medical conditions	Possible pituitary hypophysitis	Hypogonadism Suprasellar mass with optic chiasm	Unknown
Symptoms onset time after vaccination	1 day	3 days	5 days
Type of vaccination	Astra-Zeneca	Not mentioned	Astra Zeneca
Outcome	Symptoms improved after treatment of high dose steroid	Transsphenoidal resection of the pituitary tumor. Requires maintenance dose steroids and levothyroxine post operatively	Symptoms resolved spontaneously without treatment

considered a neurosurgical emergency, but reports of spontaneous clinical recovery and/or tumor disappearance have led some specialists to adopt a conservative approach in selected cases [6]. Emergency management of pituitary apoplexy is centered around resuscitation and support. In patients who present with hypotension early corticosteroids should be considered and promptly administered to maintain hemodynamic stability [6]. Early surgery is considered necessary in patients with reduced or deteriorating consciousness, or in cases of severe visual loss due to optic chiasm compression [14].

4. Conclusions

This report highlights a case of a pituitary apoplexy occurring in a young woman, possibly as a rare complication of the COVID-19 vaccine that she had received. Although it was not accompanied by the seemingly recognized features of thrombocytopenia, we believe that the apoplexy could have occurred due to vascular dysfunction secondary to the overwhelming immunological response. We acknowledge the importance of the COVID-19 vaccines as part of the global management strategy against this devastating pandemic and we strongly advocate their administrations as recommended by the relevant bodies. Research to further our understanding of potential complications of COVID-19 vaccination is important. Despite the rarity of this endocrine emergency, there should be a low threshold for the suspicion and subsequent diagnosis of pituitary tumours and the risk for pituitary apoplexy secondary to COVID-19 vaccination.

5. Availability of data and materials

Data sharing is not applicable to this article as no datasets were generated or analyzed during the current study.

Funding

The author(s) received no financial support for the research, authorship and/or publication of this article.

Contributions

NAZ reported the case and wrote the initial manuscript. SF, FZ and NM cared for the patient and aided in manuscript revisions. RAG made substantial contributions to drafts and revisions of the manuscript. All authors read and approved the final manuscript.

Ethical approval

Our institution does not require ethical approval for reporting individual cases or case series.

Informed consent

Written informed consent was obtained from the patient for their anonymized information to be published in this article.

Consent

I, ALYSSA NADIA IMRAN, give my consent for the Material about me/the patient to appear in a BMJ publication.

I confirm that I have seen the photo, image, text or other material about me, have read the article to be submitted and am legally entitled to give this consent.

Declaration of competing interest

The authors declare that they have no known competing financial interests or personal relationships that could have appeared to influence the work reported in this paper.

Acknowledgments

We thank our patient and all individuals who contributed to the management of this case.

Abbreviations:

COVID-19	Coronavirus disease 2019
mRNA	Messenger RNA
GH	Growth Hormone
IGF-1	Insulin-like growth factor 1
MRI	Magnetic resonance imaging

References

- [1] World Health Organization. WHO coronavirus (COVID-19) dashboard. 10.10.21, Available at: <https://covid19.who.int/>.
- [2] Malaysia Ministry of Health. COVIDNOW dashboard. 10.10.21, Available at: <https://covidnow.moh.gov.my/vaccinations/>.
- [3] Jaggi S, Jabbour S. Abstract #1001394: a rare endocrine complication of the COVID-19 vaccine. *Endocr Pract* 2021;27(6):S116–7.
- [4] COVID-19 AstraZeneca vaccine analysis. 10.10.21, Available at: https://assets.publishing.service.gov.uk/government/uploads/system/uploads/attachment_data/file/1023929/COVID-19_AstraZeneca_Vaccine_Analysis_Print_DLP_29.09.2021_final.pdf.
- [5] Vilar L, et al. Acromegaly: clinical features at diagnosis. *Pituitary* 2017;20(1):22–32.
- [6] Briet C, et al. Pituitary apoplexy. *Endocr Rev* 2015;36(6):622–45.
- [7] Fernandez A, Karavitaki N, Wass JA. Prevalence of pituitary adenomas: a community-based, cross-sectional study in Banbury (Oxfordshire, UK). *Clin Endocrinol* 2010;72(3):377–82.
- [8] Bujawansa S, et al. Presentation, management and outcomes in acute pituitary apoplexy: a large single-centre experience from the United Kingdom. *Clin Endocrinol* 2014;80(3):419–24.
- [9] Pottgård A, et al. Arterial events, venous thromboembolism, thrombocytopenia, and bleeding after vaccination with Oxford-AstraZeneca ChAdOx1-S in Denmark and Norway: population based cohort study. *BMJ* 2021;373:n1114.
- [10] Heinz FX, Stiasny K. Distinguishing features of current COVID-19 vaccines: knowns and unknowns of antigen presentation and modes of action. *npj Vaccines* 2021;6(1):104.
- [11] Biousse V, Newman NJ, Oyesiku NM. Precipitating factors in pituitary apoplexy. *J Neurol Neurosurg Psychiatr* 2001;71(4):542–5.
- [12] Murvelashvili N, Tessnow A. A case of hypophysitis following immunization with the mRNA-1273 SARS-CoV-2 vaccine. *J Invest Med High Impact Case Rep* 2021;9:23247096211043386.
- [13] Piñar-Gutiérrez A, Remón-Ruiz P, Soto-Moreno A. Case report: pituitary apoplexy after COVID-19 vaccination. *Medicina clinica*; 2021.
- [14] Rajasekaran S, et al. UK guidelines for the management of pituitary apoplexy. *Clin Endocrinol* 2011;74(1):9–20.