

Rheumatoid Arthritis and Cardiac Compression Caused by a Large Fibrotic Intrapericardial Mass and Effusion: A Case Report

Authors' Contribution:
Study Design A
Data Collection B
Statistical Analysis C
Data Interpretation D
Manuscript Preparation E
Literature Search F
Funds Collection G

AF 1 **Kazue Okajima**
E 2 **Therese Posas-Mendoza**
A 3 **Diane D. Tran**
AF 3 **Robert A. Hong**

1 Department of Cardiology, University of Hawaii, John A. Burns School of Medicine, Honolulu, HI, U.S.A.
2 Department of Internal Medicine, University of Hawaii, John A. Burns School of Medicine, Honolulu, HI, U.S.A.
3 Department of Cardiology, Queens Medical Center, Honolulu, HI, U.S.A.

Corresponding Author: Kazue Okajima, e-mail: kokajima@hawaii.edu
Conflict of interest: None declared

Patient: Female, 58
Final Diagnosis: Pericardial effusion and mass
Symptoms: Fatigue • lower extremity edema • shortness of breath
Medication: —
Clinical Procedure: Pericardiocentesis
Specialty: Rheumatology

Objective: Unknown etiology





Background: Pericarditis is common in rheumatoid arthritis, mostly occurring as an extra-articular manifestation of the disease. We describe a patient with stable rheumatoid arthritis who presented with a large pericardial effusion and a compressive fibrotic pericardial mass. The patient had recently started treatment with a tumor necrosis factor-alpha (TNF- α) antagonist.

Case Report: The patient was a 58-year-old woman with rheumatoid arthritis who presented with right ventricular compression caused by a pericardial fibrotic mass and a large pericardial effusion. The patient did not have active arthritis at the time of presentation. She had been started on treatment with a tumor necrosis factor-alpha (TNF- α) antagonist 4 months prior to this presentation. She was successfully treated with surgical pericardiectomy and resection of the pericardial mass. Pathologic analysis of the pericardial mass demonstrated fibrosis and no evidence of active inflammation, rheumatoid arthritis, opportunistic infection, or malignancy.

Conclusions: We describe a patient with stable rheumatoid arthritis who developed subacute right heart compression syndrome secondary to pericardial effusion and fibrous pericardial mass. The exact cause of pericarditis and the pericardial mass remain uncertain. There is a need for increased awareness of the association between use of TNF- α antagonists and the possible development of an intrapericardial fibrotic mass and effusion.

MeSH Keywords: Antirheumatic Agents • Pericardial Effusion • Pericardiectomy • Tumor Necrosis Factor-alpha

Full-text PDF: <https://www.amjcaserep.com/abstract/index/idArt/916491>

 1009   3  11



Background

Rheumatoid arthritis is a chronic inflammatory disease which usually affects the synovial membrane, but may have extra-articular manifestations, including cardiac involvement. The most common cardiac manifestations of rheumatoid arthritis are pericarditis, pericardial effusions, myocarditis, coronary vasculitis, diastolic dysfunction, and valvular heart disease [1].

We describe the case of a 58-year-old woman with rheumatoid arthritis who developed subacute right ventricular compression secondary to a pericardial effusion and a fibrotic mass. The patient's joint disease and rheumatic markers were stable at the time of presentation. Analysis of the pericardial fluid and mass did not reveal evidence of active inflammation, rheumatoid arthritis, opportunistic infection, or malignancy. We propose that there may be a causative relationship between the use of tumor necrosis factor-alpha (TNF- α) antagonists and the development of pericardial fluid and mass. We have reviewed the literature addressing this possibility.

Case Report

The patient was a 58-year-old woman with a history of hypertension and rheumatoid arthritis, who presented to our hospital with a 2-month history of increasing fatigue, lower-extremity edema, and shortness of breath. Her rheumatoid arthritis was diagnosed 5 years prior to her hospitalization. She was initially treated with methotrexate, and converted to leflunomide (a cell cycle inhibitor) 3 years prior to presentation. Because of recurrent arthritis, anti-TNF- α therapy with golimumab was added 4 months prior to this presentation. The patient's treatment for rheumatoid arthritis at the time of admission included hydroxychloroquine, prednisone, leflunomide, and golimumab. There was evidence of active arthritis. Physical examination demonstrated elevation of jugular vein pressure and marked pitting edema of the lower extremities. Diagnostic data demonstrated leukocytosis with a white blood cell count of 15 K/ μ l (normal range: 3.80–10.80), a creatinine of 1.7 mg/dl (normal: 0.6–1.4), a total bilirubin 4.8 mg/dl (normal: 0–1.2), troponin 0.11 ng/ml (normal: <0.05), and a NT pro BNP 5070 pg/ml (normal: <125). An erythrocyte sedimentation rate obtained prior to admission was 27 mm/h (normal: <30), and CCP IgG was negative. An electrocardiogram was remarkable for an ectopic atrial tachycardia. A transthoracic echocardiogram was obtained and revealed a 2.5-cm circumferential pericardial effusion with right ventricular diastolic collapse and a possible mass compressing the right ventricle (Figure 1). A CT scan demonstrated a nodular liver consistent with cirrhosis. The patient underwent pericardiocentesis, with the removal of 320 cc of hemorrhagic fluid. Analysis of the fluid did not reveal evidence of malignancy or infection, including mycobacterium and fungi. A repeat transthoracic echocardiogram

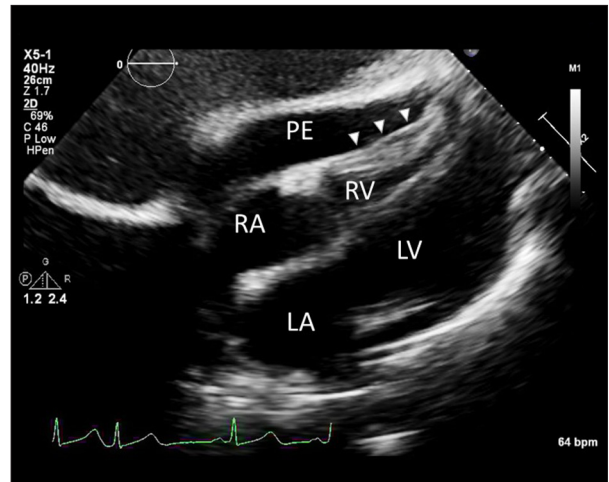


Figure 1. Echocardiogram. Subcostal view demonstrating large pericardial effusion and a mass (arrow) compressing the right ventricle. PE – pericardial effusion; RA – right atrium; RV – right ventricle; LV – left ventricle; LA – left atrium.

documented resolution of the effusion, but findings consistent with a constrictive process and thickened pericardium. A cardiac MRI with gadolinium contrast revealed a 3.5-cm soft tissue mass within the pericardial sac overlying and compressing the right ventricle (Figure 2). The patient underwent surgical exploration and removal of the pericardial mass. After the median sternotomy, both left and right cardiac chambers were found to be surrounded by thick (6–8 mm), fibrotic, partially calcified pericardium. The pericardium was resected laterally to within about 2 cm of the course of the phrenic nerve. The pericardial mass was a friable organized collection of fibrous material with tanned cauliflower-like appearance over the anterior part of the heart near the atrioventricular groove. Pathologic evaluation of the pericardial mass revealed a 7.2×6×1-cm mass with acellular fibrinous debris and cholesterol clefts but no evidence of inflammation, malignancy, infection, or granuloma nodules (Figure 3). The pericardium appeared fibrotic with evidence of chronic inflammation. TNF- α therapy was discontinued on discharge. Serial echocardiograms performed up to 26 months after surgery demonstrated no re-accumulation of pericardial effusion or recurrence of a pericardial mass.

Discussion

Pericardial involvement in patients with stable rheumatic arthritis is uncommon, and fibrotic pericardial masses are even more rarely described. The pericardial mass and effusion were probably not caused by active rheumatoid arthritis, opportunistic infection, or malignancy, and analysis of the pericardial effusions and resected intrapericardial mass were not suggestive of any of these conditions.

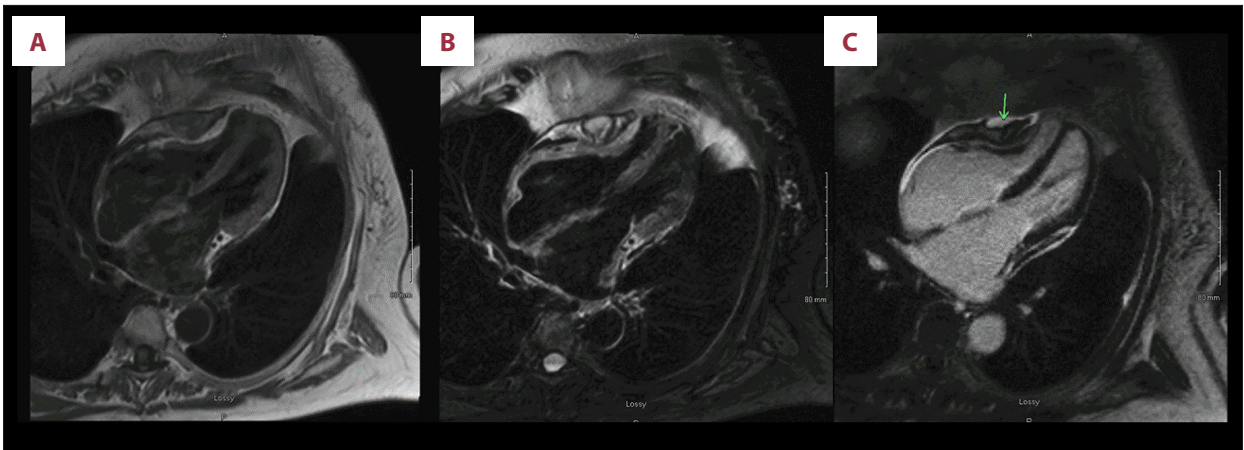


Figure 2. Cardiac magnetic resonance imaging. (A) T-1 weighted, demonstrates isointense soft mass measuring in the pericardial sac compressing right ventricle. (B) T-2 weighted demonstrated the mass with T2 hyper intensity. (C) Late gadolinium enhancement demonstrates intense enhancement in the pericardium and part of the soft tissue mass.

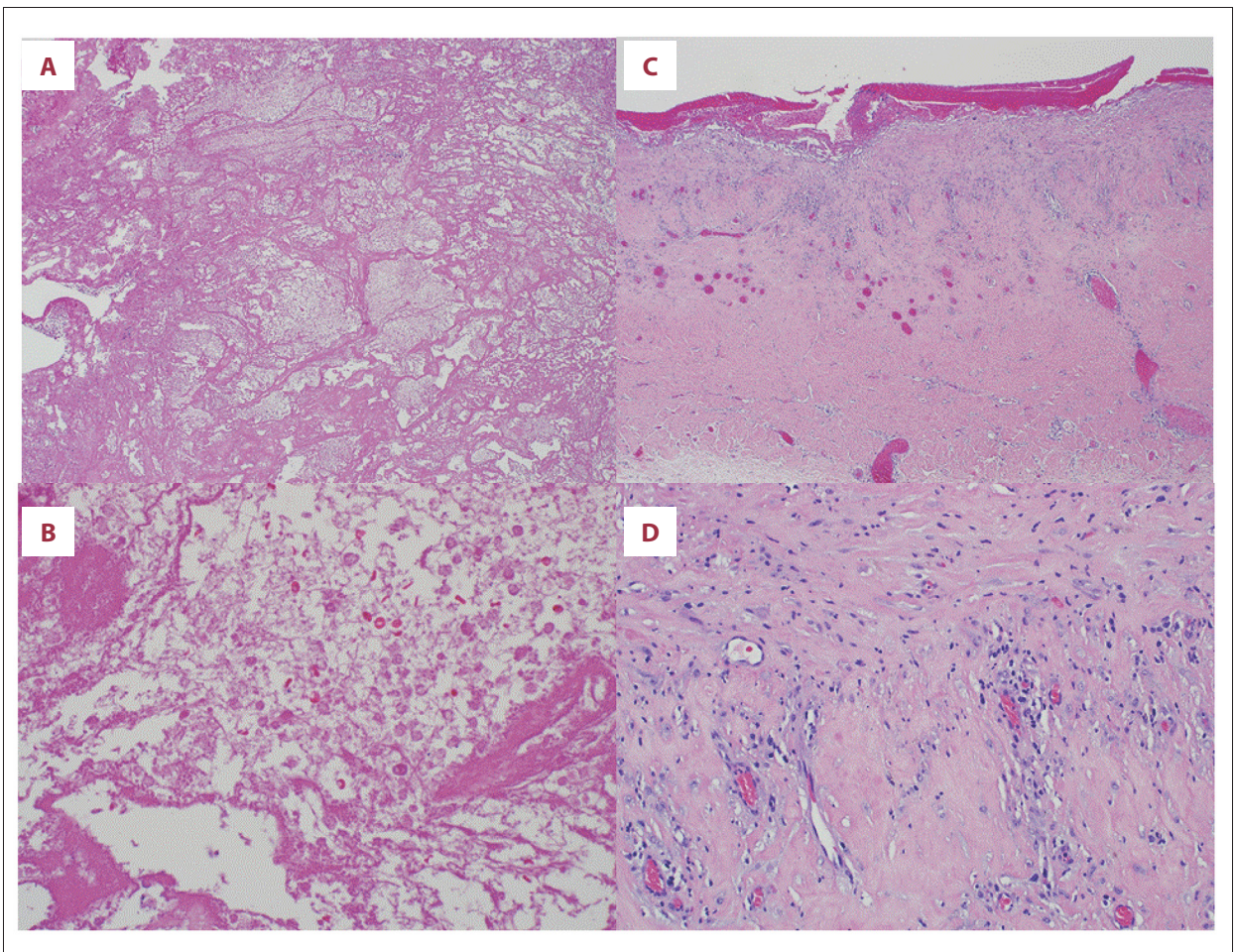


Figure 3. Histology (hematoxylin-eosin stain). (A) Intrapericardial mass, acellular fibrous material with entrapped red blood cell (magnification $\times 4$). (B) Intrapericardial mass (magnification $\times 40$). (C) Pericardium. Thickened, fibrotic pericardium with chronic inflammation and granulation tissue (magnification $\times 4$). (D) Pericardium (magnification $\times 40$).

In a 2013 review of the literature describing cardiac abnormalities in patients with rheumatoid arthritis, none were found to have had fibrotic pericardial mass development [2]. In our review of the recent literature, 3 patients with rheumatoid arthritis were documented have intrapericardial fibrous masses [3–5]. In most reports, it was proposed that inflammation and extra-articular rheumatoid disease caused the pericardial fibrosis. Of 3 cases with pericardial fibrosis, active arthritis was noted in 1 case. Interestingly, 1 patient had been treated with leflunomide, and 2 other reports did not specify the treatment regimen.

Pericardial effusions have been reported as a possible adverse effect of TNF- α inhibitor use [6–9]. Soh et al. reported 2 cases of pericardial effusions in patients on TNF- α therapy, both with surgical drainage. Ozkan et al. reported a case with dramatic improvement of pericardial effusion with discontinuation of adalimumab therapy. Edward et al. described 7 patients who developed pericardial effusion on anti-TNF- α therapy. An autoimmune reaction to TNF- α inhibitor, paradoxical flares of systemic rheumatoid arthritis secondary to anti-TNF therapy, drug-induced lupus, and cutaneous/systemic vasculitis have all been proposed as possible explanations for the development of the pericardial effusions in these patients. To the best of our knowledge, there has been no report of pericardial effusion with TNF- α therapy with golimumab, but similar effects might be expected from golimumab.

References:

1. Voskuyl AE: The heart and cardiovascular manifestations in rheumatoid arthritis. *Rheumatology (Oxford)*, 2006; 45(Suppl. 4): iv4–7
2. Corrao S, Messina S, Pistone G et al: Heart involvement in rheumatoid arthritis: Systematic review and meta-analysis. *Int J Cardiol*, 2013; 167(5): 2031–38
3. Al-Ani M, Weber M, Winchester D, Kosboth M: Pericardial mass in a patient with rheumatoid arthritis. *BMJ Case Rep*, 2015; 2015: pii: bcr2015209861
4. Bhat P, Chandrasekaran B, Barnes E: Cardiac compression from a rheumatoid pericardial mass. *Heart*, 2006; 92(9): 1337
5. Rodriguez Monserrate CP, del Rio JR, Lopez Lopez Y et al: Rheumatoid pericardial mass producing right ventricle inflow tract restriction: a case report. *Bol Asoc Med PR*, 2012; 104(4): 47–49
6. Soh MC, Hart HH, Corkill M: Pericardial effusions with tamponade and visceral constriction in patients with rheumatoid arthritis on tumour necrosis factor (TNF)-inhibitor therapy. *Int J Rheum Dis*, 2009; 12(1): 74–77
7. Ozkan H, Cetinkaya AS, Yildiz T, Bozat T: A rare side effect due to TNF- α blocking agent: Acute pleuropericarditis with adalimumab. *Case Rep Rheumatol*, 2013; 2013: 985914
8. Edwards MH, Leak AM: Pericardial effusions on anti-TNF therapy for rheumatoid arthritis – a drug side effect or uncontrolled systemic disease? *Rheumatology (Oxford)*, 2009; 48(3): 316–17
9. Lather HD, Kahlenberg JM: Hemorrhagic pericardial effusion with tamponade: a rare adverse effect of infliximab – case report and literature review. *Case Rep Rheumatol*, 2016; 2016: 2576496
10. Distler JH, Schett G, Gay S, Distler O: The controversial role of tumor necrosis factor alpha in fibrotic diseases. *Arthritis Rheum*, 2008; 58(8): 2228–35
11. Yoshikawa GT, Dias GA, Fujihara S et al: Formation of multiple pulmonary nodules during treatment with leflunomide. *J Bras Pneumol*, 2015; 41(3): 281–84

Studies performed in murine fibroblasts have suggested that TNF- α antagonists can contribute to myofibroblast proliferation [10]. Interestingly, leflunomide has been associated with interstitial lung disease and pulmonary nodule formation [11]. Although the possibility that leflunomide caused intrapericardial mass cannot be excluded, our patient was most recently started on golimumab 4 months prior to this presentation, while on chronic leflunomide therapy. Accordingly, we feel that tumor necrosis factor-alpha (TNF- α) antagonist may potentially cause fibrotic changes in the pericardium and pericardial masses.

Conclusions

We describe an uncommon case of a patient with stable rheumatoid arthritis who developed subacute right ventricular compression caused by a large pericardial effusion and a fibrotic pericardial mass. While the exact cause of pericardial effusion and fibrotic lesions remains uncertain, we feel that there may be a causative association between the use of tumor necrosis factor-alpha (TNF- α) antagonists and the development of pericardial effusion and fibrotic pericardial masses.