

Case Series

Open surgery for aneurysms of the splenic artery at the hilum of the spleen: Report of three cases

Giulio Illuminati*, Giulia Pizzardi, Rocco Pasqua

The Department of Surgical Sciences, University of Rome "La Sapienza", Rome, Italy

ARTICLE INFO

Article history:

Received 23 April 2018

Received in revised form 8 May 2018

Accepted 13 May 2018

Available online 18 May 2018

Keywords:

Splenic artery

Aneurysm

Surgical treatment

Case report

ABSTRACT

INTRODUCTION: Aneurysms of the splenic artery (SAA) located at the hilum of the spleen are not well fit for endovascular or laparoscopic treatment. Open surgery may still be the best option of treatment.

PRESENTATION OF CASES: We report the cases of 3 female patients of a mean age of 59 years (range, 45–68 years) with a hilar (n = 2) or parahilar (n = 1) SAA undergoing successful open surgical resection, through a short left subcostal access. Recovery was uneventful and mean, postoperative length of stay was 4 days (range, 3–5 days).

DISCUSSION: Results of this report support surgical resection and splenectomy for the treatment of SAA located at the hilum of the spleen. For this particular location endovascular treatment may not be advised, as coil embolization can be followed by a massive splenic infarction precipitating the need for splenectomy, due to the exclusion of backflow from the left gastroepiploic artery through the short gastric vessels. As well, endovascular exclusion through insertion of an endograft may not be feasible due to the absence of a distal landing zone, as stent grafting requires a normal caliber artery of sufficient length on each side of the aneurysm.

CONCLUSION: Surgical excision and splenectomy, through a short subcostal incision, remains a viable option of treatment for hilar SAA.

© 2018 Published by Elsevier Ltd on behalf of IJS Publishing Group Ltd. This is an open access article under the CC BY-NC-ND license (<http://creativecommons.org/licenses/by-nc-nd/4.0/>).

1. Introduction

Indications for treatment of splenic artery aneurysms (SAA) have remained fairly stable in the time, including ruptured aneurysms, pseudoaneurysms or septic aneurysms, asymptomatic aneurysms in women of childbearing age and asymptomatic aneurysms of diameter > 2 cm [1]. Methods of treatment, on the other hand have evolved, including now, beside open surgery, endovascular and laparoscopic treatment [1–6]. In particular, endovascular treatment is becoming more and more popular, thus progressively reducing indications for open repair. However, attempting transcatheter embolization for aneurysms located at the hilum of the spleen exposes to the complication of massive splenic infarction, thus requiring splenectomy any way. We report 3 cases of aneurysm of the splenic hilum, durably treated at an academic hospital by “en bloc” resection together with the spleen, through a short left subcostal incision, followed by a short and uneventful postoperative course. This study is reported in line with the PROCESS guidelines [7].

2. Presentation of cases

2.1. Case # 1

A 63-year-old woman underwent an abdominal ultrasound study for a non-specific, vague, diffuse abdominal pain seldom associated with nausea after eating meals. The study revealed a 2.0-cm diameter aneurysm of the distal splenic artery. A CT-scan of the head, chest and abdomen excluded any evident aortic, pulmonary and abdominal disease, aorto-iliac and visceral arteries' disease, but confirmed an aneurysm of the splenic artery, located at the hilum with partial lining thrombus and of a major diameter of 2.0 cm (Fig. 1). The patient signed informed consent and underwent resection of the aneurysm and splenectomy through a left subcostal access, performed by the senior author (GI). Postoperative course was uneventful and she was discharged home on postoperative day 3.

2.2. Case # 2

A 68-year-old woman was addressed after a failing attempt at trans-femoral catheterization and embolization of a 3.1 cm diameter, para-hilar aneurysm of the splenic artery (Fig. 2). The pre-procedural CT-scan of the head, chest and neck was negative

* Corresponding author at: Via Vincenzo Bel lini 14, 00198, Rome, Italy.
E-mail address: giulio.illuminati@uniroma1.it (G. Illuminati).

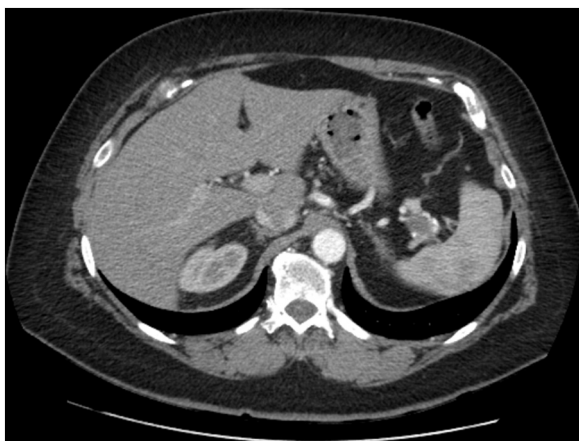

Fig. 1. CT-scan of the abdomen showing a 2.0 cm diameter aneurysm of the splenic artery at the hilum of the spleen.

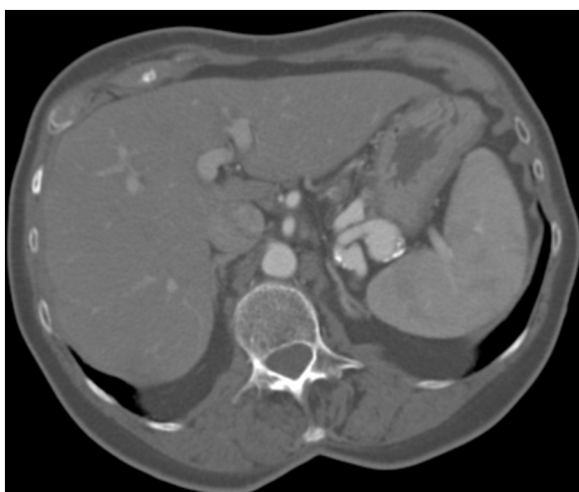

Fig. 2. CT-scan of the abdomen showing a 3.1 cm diameter, para-hilar aneurysm of the splenic artery, surgically resected after a failing attempt at trans-catheter coil embolization.

for other associated diseases. After discussing the possibility of an iterative endovascular attempt via the humeral artery, the final decision was to perform surgical resection of the aneurysm and the patient gave her informed consent. Resection of the aneurysm and splenectomy were performed by the senior author (GI) through a left subcostal access and were followed by a regular, 5-days long postoperative course (Fig. 3).

2.3. Case # 3

A 45-year-old woman was admitted for the treatment of a 1.8 cm hilar, splenic aneurysm detected at an abdominal ultrasound obtained for an aspecific urinary bladder discomfort. After eliminating other associated diseases at a head, chest and abdomen CT-scan, indication for treating the aneurysm was retained, since, despite the diameter smaller than 2 cm and her age, the patient was still fertile and potentially childbearing. Given the hilar location of the aneurysm, informed consent was obtained for surgical treatment, which was performed by the senior author (GI) and consisted of aneurysmectomy and splenectomy through the same, standard subcostal incision. The patient was discharged home on postoperative day 4, after an uneventful recovery.

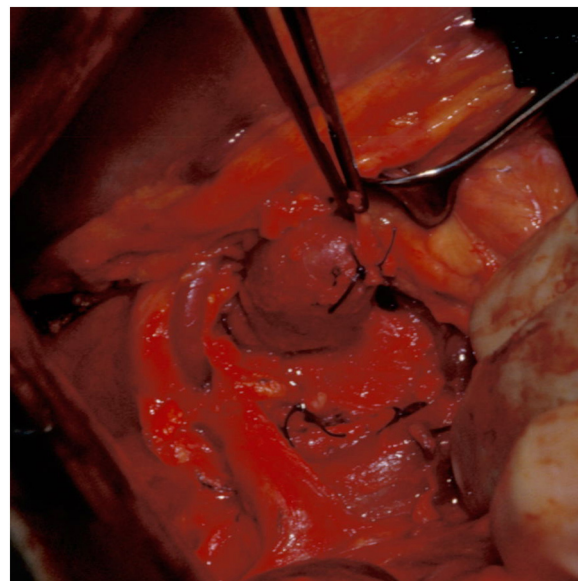


Fig. 3. Intraoperative view of case # 2. A para-hilar aneurysm is being resected "en bloc" with the spleen after proximal ligation of the splenic artery.

3. Discussion

The results of this study support the hypothesis that surgical resection and splenectomy for aneurysms of the splenic artery located at the hilum of the spleen remains a viable option of treatment. For this particular location endovascular treatment may not be advised, as coil embolization can be followed by a massive splenic infarction precipitating the need for splenectomy, due to the exclusion of backflow from the left gastroepiploic artery through the short gastric vessels. As well, endovascular exclusion through insertion of an endograft is not feasible due to the absence of a distal landing zone, as stent grafting requires a normal caliber artery of sufficient length on each side of the aneurysm [8,9]. Laparoscopy could be an alternative to open surgery and successful laparoscopic resection of large, expanding SAA has already been performed and reported [2]. However, the retrogastric and intrapancreatic setting of SAA may be technically demanding and require long operating times [4,6]. On the other hand, for aneurysms of the middle and proximal splenic artery endovascular embolization or exclusion via an endograft allows good results and is becoming more and more the standard treatment of this condition [1,9–13]. Nonetheless, seldom embolization may fail in durably treating aneurysms. Sac enlargement due to persistent filling of the aneurysm after coil embolization occurs in about 4.5% of the patients [1] and rebleeding after embolization of a ruptured aneurysm may also occur [14]. Embolization may be followed, occasionally by splenic infarcts, pain, fever, pancreatitis and recanalization [8,10,13]. For ruptured aneurysms surgery remains always a solid option [15].

Rarely aneurysms may arise from a splenic artery with an aberrant origin from the superior mesenteric artery [8,10,11,16–19]. In this setting also coil embolization has been successfully applied [3,11]. However, dislodgement or misplacement of coils in the superior mesenteric artery, with consequent bowel ischemia may occur, especially when aneurysmal neck is very short [8], and recanalization or incomplete thrombosis of the aneurysm due to the high flow in the superior mesenteric artery is possible [10]. In one of the present cases surgical resection was actually indicated after a failing attempt to embolize a para-hilar SAA. In all the cases, finally, open surgery required a very short postoperative stay and allowed durable treatment of hilar SAA.

This study has the limitation of any case report or short series, consisting of the limited number of effectives. Nonetheless, data were objectively presented and are supported by the existing literature on the specific matter.

4. Conclusion

Until laparoscopic resection can overall be safely accomplished within acceptably short operating times, surgical excision and splenectomy through a short subcostal incision remains a viable option of treatment for hilar SAA.

Conflict of interests

None of the authors has any conflict of interest to disclose.

Funding

No funding supported this study.

Ethical approval

Given the retrospective nature of the study based on case reports no institutional ethical approval was required.

Consent

Written informed consent was obtained from the patients for publication of these cases and accompanying images. A copy of the written consent is available for review by the Editor-in-Chief of this journal on request.

Author contribution

GI: critical review and writing of the paper; GP: data gathering and review of the paper; RP: data gathering and review of the paper.

Registration of research studies

UIN: 4010.

Guarantor

Giulio Illuminati.

References

- [1] G. Fang, B. Chen, W. Fu, D. Guo, X. Xu, J. Jiang, J. Luo, Z. Dong, Strategies for endovascular treatment of complicated splenic artery aneurysms, *J. Vasc. Surg.* 18 (March (9)) (2018) S0741–S5214, 30171–X. [Epub ahead of print].
- [2] A.K. Meinke, N.R. Floch, M.P. Dicorato, Laparoscopic options in the treatment of splenic artery aneurysms, *Surg. Endosc.* 16 (2002) 1107.
- [3] S.L. Dong, X. Chen, Z.X. Tu, et al., Aneurysm of the anomalous splenic artery arising from superior mesenteric artery treated by coil embolization: a report of two cases and literature review, *Ann. Vasc. Surg.* 48 (251) (2018).
- [4] N.C. Batagini, H. El-Arousy, D.G. Clair, L. Kirksey, Open versus endovascular treatment of visceral artery aneurysms and pseudoaneurysms, *Ann. Vasc. Surg.* 35 (2016) 1–8.
- [5] W. Hogendoorn, A. Lavida, M.G. Hunink, et al., Open repair, endovascular repair, and conservative management of true splenic artery aneurysms, *J. Vasc. Surg.* 60 (2014) 1667–1676.
- [6] W. Hogendoorn, A. Lavida, M.G. Hunink, et al., Cost-effectiveness of endovascular repair, open repair, and conservative management of splenic artery aneurysms, *J. Vasc. Surg.* 61 (2015) 1432–1440.
- [7] R.A. Agha, A.J. Fowler, S. Rajmohan, I. Barai, D.P. Orgill, PROCESS Group, Preferred reporting of case series in surgery; the PROCESS guidelines, *Int. J. Surg.* 36 (2016) 319–323.
- [8] G. Illuminati, G. LaMuraglia, G. Nigri, F. Vietri, Surgical repair of an aberrant splenic artery aneurysm: report of a case, *Ann. Vasc. Surg.* 21 (2007) 216–218.
- [9] R.A. Larson, J. Solomon, J.P. Carpenter, Stent graft repair of visceral artery aneurysms, *J. Vasc. Surg.* 36 (2002) 1260–1263.
- [10] T.M. Mastracci, M. Cadeddu, R.F. Colopinto, C. Cinà, A minimally invasive approach to the treatment of aberrant splenic artery aneurysms: a report of two cases, *J. Vasc. Surg.* 41 (2005) 1053–1057.
- [11] M. Sato, I. Anno, M. Yamaguchi, H. Iida, K. Orii, Splenic artery aneurysm of the anomalous splenomesenteric trunk: successful treatment by transcatheter embolization using detachable coils, *Cardiovasc. Intervent. Radiol.* 29 (2006) 432–434.
- [12] P.R. Reardon, E. Otah, E.S. Craig, B.D. Matthews, M.J. Reardon, Laparoscopic resection of splenic artery aneurysms, *Surg. Endosc.* 19 (2005) 488–493.
- [13] S.S. Saltzberg, T.S. Maldonado, P.J. Lamparello, et al., Is endovascular therapy the preferred treatment for all visceral artery aneurysms? *Ann. Vasc. Surg.* 19 (2005) 507–515.
- [14] K.D. Kingma, A.N. van der Linden, R.M. Roumen, Rebleeding of a splenic artery aneurysm after coil embolisation, *Case Rep. Surg.* 2016 (2016) 1858461.
- [15] A.C. Heitkamp, C. Dickhoff, J.H. Nederhoed, G. Franschman, J.I. de Vries, Saved from a fatal flight: a ruptured splenic artery aneurysm in a pregnant woman, *Int. J. Surg. Case Rep.* 8C (2015) 32–34.
- [16] P.G. Settembrini, J.M. Jausseran, S. Roveri, et al., Aneurysms of anomalous splenomesenteric trunk: clinical features and surgical management in two cases, *J. Vasc. Surg.* 24 (1996) 687–692.
- [17] J.D. Ghatan, E.R. Beranbaum, L.T. Bowles, F.J. Veith, Aneurysm of anomalous splenic artery, *Ann. Surg.* 166 (1967) 144–146.
- [18] P.S. Sidhu, K.T. Khaw, A.M. Belli, Anomalous splenic artery aneurysm: demonstration on CT scanning and angiography, *Postgrad. Med. J.* 71 (1995) 49–51.
- [19] P. Patel, P.J. Turner, P.J. Curley, Reconstruction of the SMA after excision of an anomalous splenic artery aneurysm, *Eur. J. Vasc. Endovasc. Surg.* 15 (1998) 369–370.

Open Access

This article is published Open Access at [sciencedirect.com](https://www.sciencedirect.com). It is distributed under the [IJSCR Supplemental terms and conditions](#), which permits unrestricted non commercial use, distribution, and reproduction in any medium, provided the original authors and source are credited.