

# Clinical Implication of the Effect of the Production of Neutralizing Antibodies Against SARS-Cov-2 for Chronic Immune Thrombocytopenia Flare-Up Associated with COVID-19 Infection: A Case Report and the Review of Literature

Chika Maekura<sup>1</sup>, Ayako Muramatsu<sup>1</sup>, Hiroaki Nagata<sup>1</sup>, Haruya Okamoto<sup>1</sup>, Akio Onishi<sup>1</sup>, Daishi Kato<sup>1</sup>, Reiko Isa<sup>1</sup>, Takahiro Fujino<sup>1</sup>, Taku Tsukamoto<sup>1</sup>, Shinsuke Mizutani<sup>1</sup>, Yuji Shimura<sup>1,2</sup>, Tsutomu Kobayashi<sup>1</sup>, Keita Okumura<sup>3</sup>, Tohru Inaba<sup>4</sup>, Yoko Nukui<sup>4</sup>, Junya Kuroda<sup>1</sup>

<sup>1</sup>Division of Hematology and Oncology, Department of Medicine, Kyoto Prefectural University of Medicine, Kyoto, Japan; <sup>2</sup>Department of Blood Transfusion, University Hospital, Kyoto Prefectural University of Medicine, Kyoto, Japan; <sup>3</sup>Faculty of Clinical Laboratory, University Hospital, Kyoto Prefectural University of Medicine, Kyoto, Japan; <sup>4</sup>Department of Infection Control & Laboratory Medicine, Kyoto Prefectural University of Medicine, Kyoto, Japan

Correspondence: Junya Kuroda, Division of Hematology and Oncology, Department of Medicine, Kyoto Prefectural University of Medicine, 465 Kajii-cho, Kamigyo-ku, Kyoto, 602-8566, Japan, Tel +81 75 251 5740, Fax +81 75 251 5743, Email [junkuro@koto.kpu-m.ac.jp](mailto:junkuro@koto.kpu-m.ac.jp)

**Abstract:** Previous studies have demonstrated that the appropriate production of serum anti-severe acute respiratory syndrome coronavirus 2 (SARS-Cov-2) neutralizing antibody (nAb) plays a critical role in the recovery from coronavirus disease 2019 (COVID-19); however, the role of nAb production in the recovery from a flare-up of chronic immune thrombocytopenia (ITP) has been unknown. We here report the first retrospectively investigated case of serum anti-SARS-Cov-2 nAb production during chronic ITP flare-up triggered by COVID-19. A 79-year-old woman with a history of corticosteroid-refractory ITP visited our hospital complaining of fever, cough, and sore throat for 4 days. Although chronic ITP was controlled by 12.5 mg of eltrombopag (EPAG) every other day, laboratory tests showed a decreased peripheral blood platelet count of  $15.0 \times 10^9/L$ , which indicated worsening thrombocytopenia. Meanwhile, PCR testing of a nasopharyngeal swab revealed that the patient was positive for SARS-Cov-2, and a computed tomography scan revealed bilateral pneumonia. On the basis of the flare-up of chronic ITP associated with COVID-19 pneumonia which was determined as a moderately severe status according to the WHO clinical progression scale, intravenous immunoglobulin therapy for 5 days (days 0–4) and antiviral therapy were added on top of EPAG, which only resulted in a transient increase in the platelet count for several days. After decreasing to  $8.0 \times 10^9/L$  on day 13, the platelet count increased from day 16, coinciding with a positive detection for serum nAb against SARS-Cov-2. Although the increased dose up to 50 mg/day of EPAG was challenged during the clinical course, rapid dose reduction did not cause another relapse. In addition, no thrombotic or bleeding event was seen. These collectively suggest the vital role of the production of anti-SARS-Cov-2 nAb and improvement of clinical symptoms for recovery from a flare-up of chronic ITP in our case.

**Keywords:** chronic immune thrombocytopenia, COVID-19, flare, neutralizing antibody

## Introduction

Immune thrombocytopenia (ITP) is known as an autoimmune disorder characterized by a transient or persistent decrease in platelet count and an increase in bleeding risk. ITP is classified as primary or secondary and as acute (of six months or less in duration) or chronic, and ITP in adults is generally chronic.<sup>1,2</sup> Secondary ITP occurs in an underlying autoimmune disease or drug exposure. There are also cases of human immunodeficiency virus or HIV-associated and *Helicobacter pylori*-associated.<sup>3</sup>

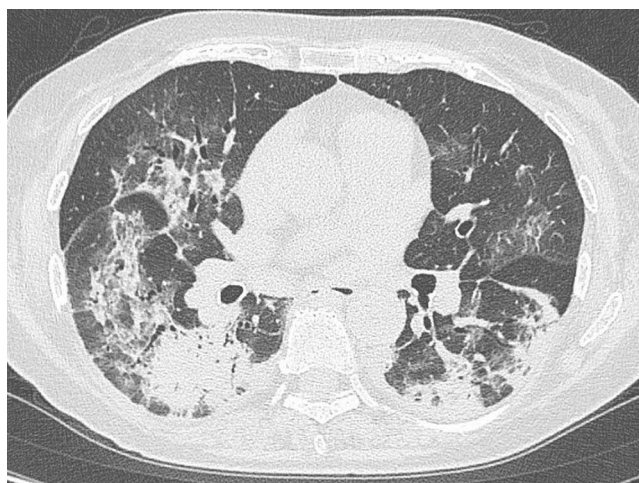
Since the emergence of coronavirus disease 2019 (COVID-19) as a global pandemic, its pathological impacts on various types of immune-mediated hematologic diseases, such as ITP, have been reported; however, information about its

clinical features, treatment strategy, and biomarkers for treatment response with chronic ITP that re-worsened in association with COVID-19 infection have been rather limited.<sup>4-7</sup>

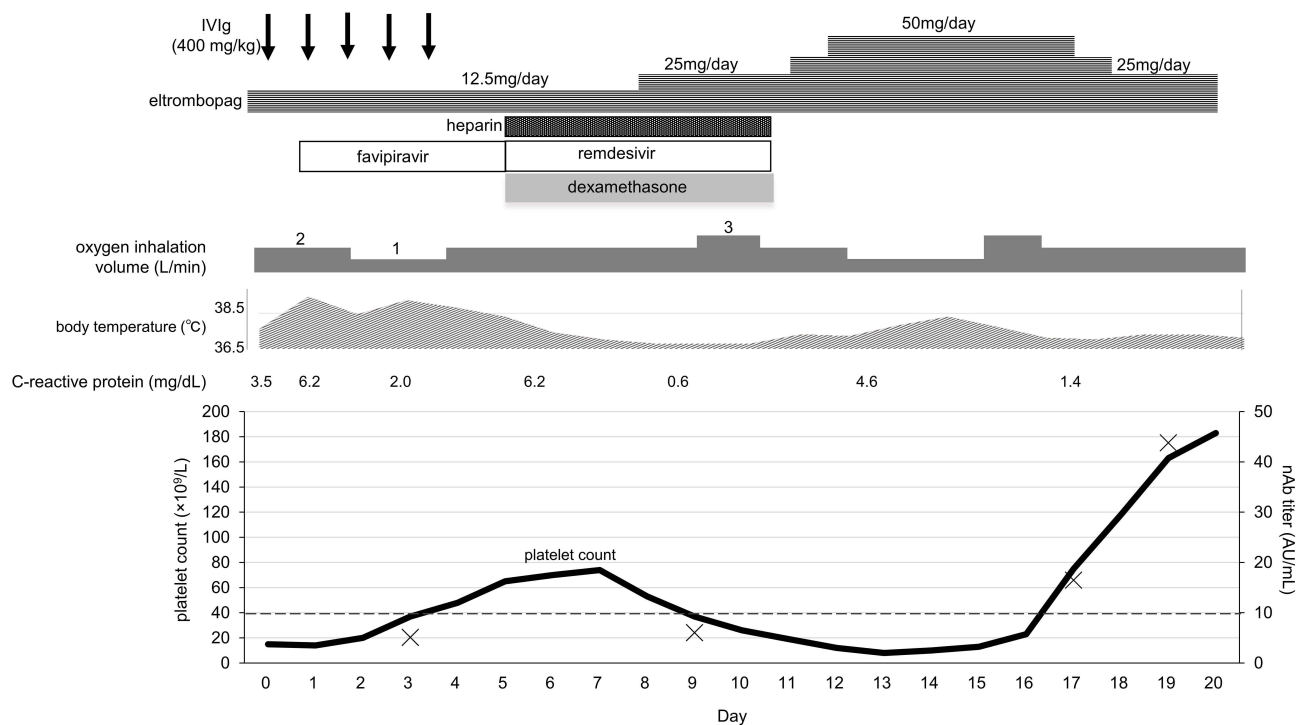
The appropriate production of neutralizing antibody (nAb) against Severe Acute Respiratory Syndrome Coronavirus 2 (SARS-Cov-2) has been reported to be crucial for virus clearance.<sup>8,9</sup> The production of nAb has been shown to correlate with the survival of patients infected by SARS-Cov-2, while the absence of nAb production in the early phase of infection is associated with mortality and delayed viral control.<sup>10</sup> These support the importance of nAb production in recovering from COVID-19 infection; however, the direct or indirect correlation between the nAb production and recovery from a flare-up of chronic ITP has been unknown. We here report a case with chronic ITP that flared in association with COVID-19 infection with which we retrospectively investigated the dynamics of anti-SARS-Cov-2 nAb during infection. We also reviewed cases of ITP flare-ups following COVID-19 infection.<sup>4-7</sup>

## Case Report

A 79-year-old female patient who was diagnosed with chronic ITP 8 years ago has been successfully treated with 12.5 mg of eltrombopag (EPAG), a thrombopoietin receptor agonist, every other day to maintain her peripheral platelet count at approximately  $150.0 \times 10^9/L$  (normal range:  $138.0-309.0 \times 10^9/L$ ) for several years, although the disease was initially refractory to corticosteroid therapy. In March 2021, the patient visited our hospital complaining of high fever, cough, and sore throat for a 4-day duration. Blood test results showed marked thrombocytopenia ( $15.0 \times 10^9/L$ ), but the white blood cell count and hemoglobin level were normal. A slightly increased immature platelet fraction of 6.8% (normal range, 1.1–6.1%) was noted. Blood coagulation tests showed an elevated fibrinogen level (562 mg/dL; normal, 150–400 mg/dL) and prolonged activated partial thromboplastin time (44.6 sec; normal, 24.3–36.0 sec); prothrombin time and D-dimer level were within the normal ranges. The serum C-reactive protein level was also elevated (3.52 mg/dL; normal, 0.0–0.3 g/dL). Other laboratory test results were normal. PCR testing of a nasopharyngeal swab was positive for SARS-Cov-2, and a computed tomography scan revealed bilateral pneumonia with a CT score of 14 (Figure 1).<sup>11</sup> She was admitted to the ward and started on oxygen therapy (2L/min by nasal prongs). According to the WHO clinical progression scale, the disease severity was determined to be moderate.<sup>12</sup> Based on the diagnosis of chronic ITP flare-up associated with COVID-19 pneumonia, 400 mg/kg/day of intravenous immunoglobulin infusion (IVIg) was administered for 5 days on top of EPAG, which was increased to 12.5 mg/day. Meanwhile, treatment for COVID-19 started with favipiravir administration, which was shifted to remdesivir with dexamethasone on day 5 due to poor response during the initial phase. Although the platelet count transiently increased to  $74.0 \times 10^9/L$  on day 7, it decreased to  $8.0 \times 10^9/L$  on day 13 despite increasing the EPAG dose to 50 mg/day. On day 16, fever and respiratory symptoms gradually improved, and the platelet count increased. Despite daily dose tapering of EPAG, the platelet count increased to  $18.3 \times 10^9/L$  on day 20 (Figure 2). Prophylactic anticoagulation therapy consisted of intravenous heparin sodium of 5000–



**Figure 1** Computed tomography (CT) scan of the chest on admission. The CT scan showed frosted glass shadows and partial dense infiltration in bilateral lungs.



**Figure 2** Clinical course of the patient after hospitalization. The crosses indicate neutralizing antibody (nAb) titers, and the dashed line indicates the cutoff value for nAb. IVIg, intravenous immunoglobulin therapy.

10,000U/day or subcutaneous heparin calcium of 2500–5000U/day was added from day 5 to 10, and no thrombotic or bleeding event was observed during illness. Currently, the platelet count is maintained at  $200.0 \times 10^9/L$  with 12.5 mg of EPAG every 3 days. We retrospectively measured the SARS-Cov-2 nAb titer in the patient's sera obtained at several time points during hospitalization. The results show that nAb against SARS-Cov-2 was not present on day 9; it was first detected on day 17, and its level increased as of day 19 (Figure 2).

## Discussion

Thrombocytopenia reportedly develops in 12–36% of patients with COVID-19 infection,<sup>13,14</sup> and acute ITP is one of the causes of COVID-19-related thrombocytopenia.<sup>15–17</sup> In addition, post-COVID-19 vaccination flare-ups have been reported among patients with chronic ITP.<sup>18–20</sup> However, few cases of chronic ITP flare-ups post-COVID-19 infection have been reported,<sup>4–7</sup> and information about its clinical characteristics is limited.

Including the present case, we reviewed 13 cases of chronic ITP flare-ups associated with COVID-19 infection (Table 1).<sup>4–6</sup> In those cases, the severity of COVID-19 symptoms varied widely among patients and was unlikely to be associated with thrombocytopenia. The nadir platelet counts and treatments before flare-up also varied among patients, which were unlikely to be associated with thrombocytopenia triggered by COVID-19 infection. The pharmacological intervention was necessary for 7 of 13 patients, and IVIg with or without corticosteroid treatment was administered to 5 patients who had platelet counts below  $18.0 \times 10^9/L$ . ITP in our case was initially refractory to corticosteroid therapy; this was shown when dexamethasone treatment for respiratory dysfunction due to COVID-19 infection did not increase the platelet count. In addition, the clinical effects of IVIg were transient in our case. The appropriateness of using anti-CD20 monoclonal antibody rituximab remains controversial because of its negative impact on the production of nAb against COVID-19,<sup>21–23</sup> although the role of nAb in patients recovering from COVID-19 infection also remains controversial.<sup>10,21,24</sup> Because of the high risk of thrombotic complications with COVID-19 infection,<sup>25,26</sup> the use of thrombopoietin receptor agonists when managing ITP during infection with COVID-19 requires caution. Of the 13 reported patients, 4 received prophylactic anticoagulants and none reported thrombotic complications. In contrast, 2 of the 9 patients who did not receive prophylactic anticoagulants, including 1 treated with EPAG, experienced thrombotic

**Table 1** Clinical Features of the 13 Cases of Chronic ITP Flare-Up Associated with COVID-19 Infection, Including the Present Case

No.	Age	Gender	COVID-19 Severity	Nadir PLT Count ( $\times 10^9/L$ )	Treatment at COVID-19 Onset	Added Treatment for Relapse	PLT Count at Discharge or After Treatment ( $\times 10^9/L$ )	Prophylactic Anticoagulant	Thrombosis	Hospitalization Length (Days)	Ref.
1	88	M	Moderate	8	None	None	13	None	No	4	[4]
2	89	F	Mild	8	ROMI, MMF	IVIg	N.A.	None	No	N.A.	
3	50	M	Moderate	18	PSL	IVIg	28	Yes	No	21	
4	72	M	Mild	23	None	PSL	180	Yes	No	N.A.	
5	20	F	Mild	26	None	None	26	None	No	1	
6	54	F	Moderate	26	None	DEX	105	Yes	No	4	
7	38	F	Mild	94	None	None	N.A.	None	No	N.A.	
8	38	F	Moderate	112	PSL	None	236	None	No	3	
9	61	M	Moderate	137	Rituximab	None	346	None	Pulmonary embolus, DVT	7	
10	53	F	Mild	158	EPAG	None	158	None	Cerebral venous sinus thrombosis	2	
11	37	F	N.A.	6	MMF	IVIg, mPSL	119	None	No	11	[5]
12	72	F	N.A.	18	PSL, CsA	IVIg, mPSL	240	None	No	N.A.	[6]
13	79	F	Moderate	8	EPAG	IVIg, EPAG	183	Yes	No	20	Our case

**Notes:** The severity of COVID-19 infection was determined as follows: “mild” indicates asymptomatic or not requiring oxygen therapy; “moderate” requires oxygen therapy on hospitalization; and “severe” requires ventilator management or ICU management.

**Abbreviations:** CsA, cyclosporine; DEX, dexamethasone; DVT, deep venous thrombosis; EPAG, eltrombopag; F, female; IVIg, intravenous immunoglobulin; M, male; MMF, mycophenolate mofetil; mPSL, methylprednisolone; PSL, prednisone or its analogue; ROMI, romiplostim; Ref, reference; N.A., not available.

complications, implying the importance of anticoagulant prophylaxis; however, current data are rather limited. Among the 13 patients, our patient was the first in whom the dose escalation of EPAG was challenged. To avoid both bleeding and thrombotic events during treatment of severe thrombocytopenia due to chronic ITP flare-up, close monitoring of bleeding and coagulation parameters is necessary and should be the basis of anticoagulant prophylaxis. Nevertheless, the dose increase of EPAG might at least partly have played a role in the recovery of platelet count in our case.

As far as we are concerned, the present case is the first to investigate the dynamics of nAb against SARS-Cov-2 during the clinically emergent period. Approximately 80% of patients with COVID-19 infection produced nAbs within 2 weeks from disease onset, and there is a correlation between the time of production of nAb against SARS-Cov-2 and time to virus elimination.<sup>10</sup> In our case, the emergence of nAb was accompanied not only by the improvement of fever and respiratory symptoms but also by the increase in platelet count. This suggests that the production of nAb against SARS-Cov-2 and the improvement of symptoms contributed to the resolution of chronic ITP flare-ups in our case.

## Conclusion

We reported a case of chronic ITP flare-up associated with COVID-19 infection and reviewed related literature. The present case suggests the importance of monitoring nAb levels during chronic ITP flare-ups secondary to COVID-19 infection for optimal treatment and prediction of treatment outcomes. The detection of nAb production may help reduce the risks of adverse events by EPAG or corticosteroids. More information is expected to establish the clinical utility of nAb monitoring in the case of flare with chronic ITP by COVID-19 infection.

## Ethics and Consent Statement

Informed consent has been provided by the patient for the publication of the case report and accompanying images. The institutional approval was not required for the publication of the case details.

## Disclosure

Taku Tsukamoto received research funding from Nippon Shinyaku. Tohru Inaba reports non-financial support from YHLO for technical support, during the conduct of the study. Junya Kuroda received research funding from Kyowa Kirin, Chugai Pharmaceutical, Ono Pharmaceutical, Sanofi, Eisai, Bristol-Myers Squibb (BMS), Sysmex, Dainippon Sumitomo Pharma, Nippon Shinyaku, AbbVie, Teijin, and Otsuka Pharmaceutical; received honoraria from Janssen Pharmaceutical K.K., Kyowa Kirin, Chugai Pharmaceutical, Ono Pharmaceutical, Sanofi, Eisai, Symbio, BMS, Astellas Pharma, Pfizer, Nippon Shinyaku, Daiichi Sankyo, Dainippon Sumitomo Pharma, AbbVie, and Otsuka Pharmaceutical; and is a consultant for Janssen Pharmaceutical K.K., and BMS. Other authors report no conflicts of interest in this work.

## References

1. Rodeghiero F, Stasi R, Gernsheimer T, et al. Standardization of terminology, definitions and outcome criteria in immune thrombocytopenic purpura of adults and children: report from an international working group. *Blood*. 2009;113(11):2386–2393. doi:10.1182/blood-2008-07-162503
2. Cines DB, Blanchette VS. Immune thrombocytopenic purpura. *N Engl J Med*. 2002;346:995–1008. doi:10.1056/NEJMra010501
3. Liebman HA. Viral-associated immune thrombocytopenic purpura. *Am Soc Hematol Educ Program Book*. 2008;2008:212–218. doi:10.1182/asheducation-2008.1.212
4. Lee EJ, Liu X, Hou M, Bussel JB. Immune thrombocytopenia during the COVID-19 pandemic. *Br J Haematol*. 2021;193:1093–1095. doi:10.1111/bjh.17457
5. Merli M, Ageno W, Sessa F, et al. Recurrence of immune thrombocytopenia at the time of SARS-CoV-2 infection. *Ann Hematol*. 2020;99:1951–1952. doi:10.1007/s00277-020-04130-2
6. Hu Z, Chen W, Liang W, Xu C, Sun W, Yi Y. Severe exacerbation of immune thrombocytopenia and COVID-19: the favorable response to corticosteroid-based therapy-A case report. *Ann Hematol*. 2021;100:2135–2137. doi:10.1007/s00277-020-04070-x
7. Pantic N, Suvajdzic-Vukovic N, Virijevec M, et al. Coronavirus disease 2019 in patients with chronic immune thrombocytopenia on thrombopoietin receptor agonists: new perspectives and old challenges. *Blood Coagul Fibrinolysis*. 2022;33:51–55. doi:10.1097/MBC.0000000000001109
8. Dogan M, Kozhaya L, Placek L, et al. SARS-CoV-2 specific antibody and neutralization assays reveal the wide range of the humoral immune response to the virus. *Commun Biol*. 2021;4:129. doi:10.1038/s42003-021-01649-6
9. Pang NY, Pang AS, Chow VT, Wang DY. Understanding neutralizing antibodies against SARS-CoV-2 and their implications in clinical practice. *Mil Med Res*. 2021;8:47. doi:10.1186/s40779-021-00342-3
10. Dispinseri S, Secchi M, Pirillo MF, et al. Neutralizing antibody responses to SARS-CoV-2 in symptomatic COVID-19 is persistent and critical for survival. *Nat Commun*. 2021;12:2670. doi:10.1038/s41467-021-22958-8
11. Yuan M, Yin W, Tao Z, Tan W, Hu Y, Schildgen O. Association of radiologic findings with mortality of patients infected with 2019 novel coronavirus in Wuhan, China. *PLoS One*. 2020;15(3):e0230548. doi:10.1371/journal.pone.0230548
12. Marshall JC, Murthy S, Diaz J, et al. WHO Working Group on the clinical characterisation and management of COVID-19 infection. *Lancet Infect Dis*. 2020;20:192–197.
13. Chen N, Zhou M, Dong X, et al. Epidemiological and clinical characteristics of 99 cases of 2019 novel coronavirus pneumonia in Wuhan, China: a descriptive study. *Lancet*. 2020;395:507–513. doi:10.1016/S0140-6736(20)30211-7
14. Guan WJ, Ni ZY, Hu Y, et al. China Medical Treatment Expert Group for Covid-19. Clinical Characteristics of Coronavirus Disease 2019 in China. *N Engl J Med*. 2020;382:1708–1720. doi:10.1056/NEJMoa2002032
15. Bombhof G, Mutsaers PGJ, Leebeek FWG, et al. COVID-19-associated immune thrombocytopenia. *Br J Haematol*. 2020;190:61–64. doi:10.1111/bjh.16850
16. Pedrosa A, Frade L, Trevas S, Correia MJ, Esteves AL. Immune thrombocytopenic purpura - different presentations in two COVID-19 patients. *Cureus*. 2020;12:11202.
17. Watts A, Raj K, Gogia P, Toquica Gahona CC, Porcelli M. Secondary Immune thrombocytopenic purpura triggered by COVID-19. *Cureus*. 2021;13:14505.
18. Ali E, Al-Maharmeh Q, Rozi WM, Habib MB, Yassin M. Immune thrombocytopenia purpura flare post COVID-19 vaccine. *Ann Med Surg*. 2021;6:103164.
19. Shah SRA, Dolkar S, Mathew J, Vishnu P. COVID-19 vaccination associated severe immune thrombocytopenia. *Exp Hematol Oncol*. 2021;10:42. doi:10.1186/s40164-021-00235-0
20. Helms JM, Ansteatt KT, Roberts JC, et al. Severe, refractory immune thrombocytopenia occurring after SARS-CoV-2 vaccine. *J Blood Med*. 2021;12:221–224. doi:10.2147/JBM.S307047
21. Levavi H, Lancman G, Gabrielove J. Impact of rituximab on COVID-19 outcomes. *Ann Hematol*. 2021;100(11):2805–2812. doi:10.1007/s00277-021-04662-1
22. Yasuda H, Tsukune Y, Watanabe N, et al. Persistent COVID-19 pneumonia and failure to develop anti-SARS-CoV-2 antibodies during rituximab maintenance therapy for follicular lymphoma. *Clin Lymphoma Myeloma Leuk*. 2020;20:774–776. doi:10.1016/j.clml.2020.08.017
23. Cattaneo C, Cancelli V, Imberti L, et al. Production and persistence of specific antibodies in COVID-19 patients with hematologic malignancies: role of rituximab. *Blood Cancer J*. 2021;11:151. doi:10.1038/s41408-021-00546-9

24. Horiuchi H, Sasaki H, Miyazaki K, Miyata N, Yoshimura Y, Tachikawa N. Recovery from severe persistent COVID-19 without evidence of an anti-SARS-CoV-2 antibody response in a man with mantle cell lymphoma treated with rituximab. *J Infect Chemother.* 2022;28:329–332. doi:10.1016/j.jiac.2021.11.018
25. Horiuchi H, Morishita E, Urano T, Yokoyama K. Questionnaire-survey joint team on the COVID-19-related thrombosis. COVID-19-related thrombosis in Japan: final report of a questionnaire-based survey in 2020. *J Atheroscler Thromb.* 2021;28:406–416. doi:10.5551/jat.RPT001
26. Klok FA, Kruip MJHA, van der Meer NJM, et al. Incidence of thrombotic complications in critically ill ICU patients with COVID-19. *Thromb Res.* 2020;191:145–147. doi:10.1016/j.thromres.2020.04.013

Infection and Drug Resistance

Dovepress

## Publish your work in this journal

Infection and Drug Resistance is an international, peer-reviewed open-access journal that focuses on the optimal treatment of infection (bacterial, fungal and viral) and the development and institution of preventive strategies to minimize the development and spread of resistance. The journal is specifically concerned with the epidemiology of antibiotic resistance and the mechanisms of resistance development and diffusion in both hospitals and the community. The manuscript management system is completely online and includes a very quick and fair peer-review system, which is all easy to use. Visit <http://www.dovepress.com/testimonials.php> to read real quotes from published authors.

Submit your manuscript here: <https://www.dovepress.com/infection-and-drug-resistance-journal>