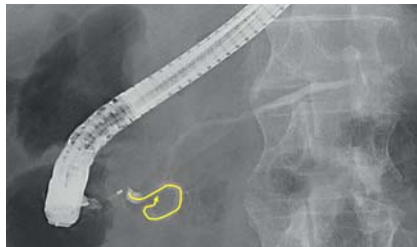


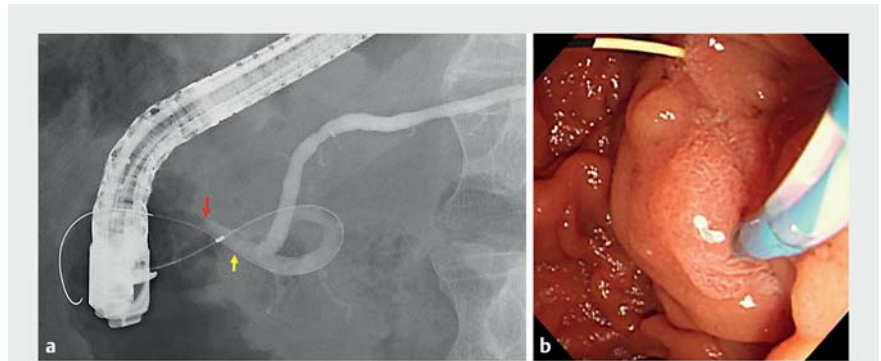
## Antegrade balloon dilation of the minor duodenal papilla to facilitate serial pancreatic juice aspiration cytology



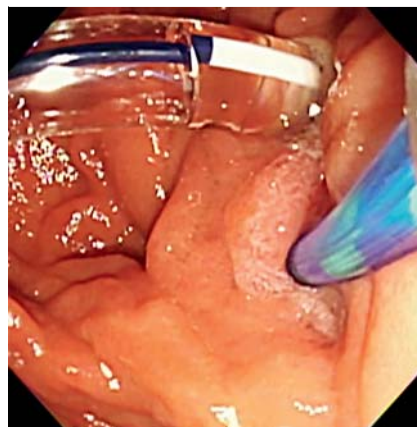
► **Fig. 1** Endoscopic retrograde pancreatography via the major papilla showed loop formation at the main pancreatic duct in the head of the pancreas (yellow curved line).

Repeated pancreatic juice cytology via a nasopancreatic drainage (NPD) catheter, known as serial pancreatic juice aspiration cytologic examination (SPACE), is reportedly useful for the diagnosis of early-stage pancreatic cancer [1]. When NPD catheter insertion through the major papilla is impossible due to main pancreatic duct (MPD) distortion, insertion through the minor papilla is attempted. Here, we describe antegrade dilation of the minor papilla using a balloon catheter inserted through the major papilla to facilitate minor papilla cannulation and NPD catheter insertion.

A 76-year-old man was referred to our hospital due to main pancreatic duct (MPD) stenosis at the pancreatic tail. No pancreatic mass was revealed on endoscopic ultrasonography, and SPACE was attempted. Endoscopic retrograde pancreatography via the major papilla showed loop formation at the MPD in the head of the pancreas, thus a guidewire could not be inserted into the MPD in the tail of the pancreas (► **Fig. 1**). Then, approach to the minor papilla was attempted. A 0.025-inch guidewire (J-WIRE Prologue; J-MIT Co., Ltd, Kyoto, Japan) was successfully inserted into the accessory pancreatic duct and passed through the minor papilla (► **Fig. 2 a, b**).

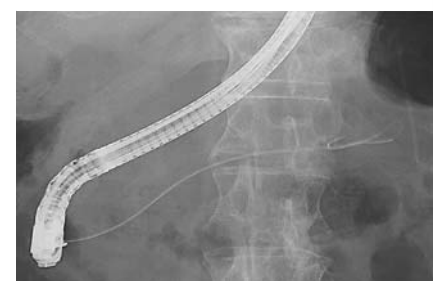

► **Fig. 2 a** Fluoroscopic image shows a 0.025-inch guidewire inserted into the accessory pancreatic duct (yellow arrow) and passed through the minor papilla (red arrow). **b** Endoscopic image shows a 0.025-inch guidewire passed through the minor papilla into the duodenum.



► **Fig. 3** Endoscopic image shows minor papilla dilation using a 6-mm balloon catheter inserted from the major papilla.

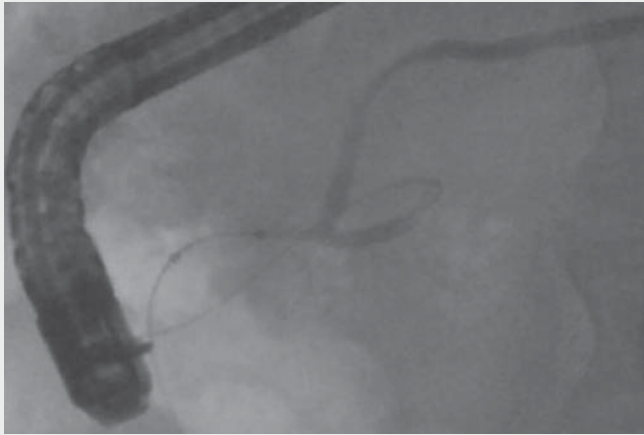
Antegrade dilation of the minor papilla was performed using a 6-mm balloon catheter (REN; Kaneka Medix, Osaka, Japan), to facilitate cannulation (► **Fig. 3**). Following guidewire removal, minor papilla cannulation was successfully performed, and a 5-Fr NPD catheter was inserted into the MPD at the pancreatic tail (► **Fig. 4**, ► **Video 1**). Pancreatic juice was collected six times for cytology, and



► **Fig. 4** Fluoroscopic image showing a 5-Fr nasopancreatic drainage catheter inserted into the main pancreatic duct at the pancreatic tail.

the NPD catheter was removed the following day. Cytology revealed adenocarcinoma, and surgery was planned. The rendezvous technique is sometimes attempted for minor papilla cannulation using a guidewire inserted from the major papilla [2]. However, complicated steps including scope exchange, and grabbing and pulling the guidewire are required. Our method provides an alternative option for minor papilla cannulation.

Endoscopy\_UCTN\_Code\_TTT\_1AR\_2AI



**Video 1** Antegrade dilation of the minor duodenal papilla using a balloon catheter inserted through the major papilla to facilitate minor papilla cannulation and insertion of a nasopancreatic drainage catheter.

## Bibliography

Endoscopy 2022; 54: E1051–E1052

DOI 10.1055/a-1913-7425

ISSN 0013-726X

published online 25.8.2022

© 2022. The Author(s).

This is an open access article published by Thieme under the terms of the Creative Commons Attribution-NonDerivative-NonCommercial License, permitting copying and reproduction so long as the original work is given appropriate credit. Contents may not be used for commercial purposes, or adapted, remixed, transformed or built upon. (<https://creativecommons.org/licenses/by-nc-nd/4.0/>)

Georg Thieme Verlag KG, Rüdigerstraße 14,  
70469 Stuttgart, Germany



## ENDOSCOPY E-VIDEOS

<https://eref.thieme.de/e-videos>



*Endoscopy E-Videos* is an open access online section, reporting on interesting cases

and new techniques in gastroenterological endoscopy. All papers include a high quality video and all contributions are freely accessible online. Processing charges apply (currently EUR 375), discounts and waivers acc. to HINARI are available.

This section has its own submission website at

<https://mc.manuscriptcentral.com/e-videos>

## Competing interests

The authors declare that they have no conflict of interest.

## The authors

### Koichiro Mandai, Ryo Shinomiya

Department of Gastroenterology, Kyoto Second Red Cross Hospital, Kyoto, Japan

## Corresponding author

### Koichiro Mandai, MD

Department of Gastroenterology, Kyoto Second Red Cross Hospital, 355-5 Haruobicho, Kamigyo-ku, Kyoto 602-8026, Japan  
Fax: +81-75-256-3451  
[mndkchr@gmail.com](mailto:mndkchr@gmail.com)

## References

- [1] Mikata R, Ishihara T, Tada M et al. Clinical usefulness of repeated pancreatic juice cytology via endoscopic naso-pancreatic drainage tube in patients with pancreatic cancer. *J Gastroenterol* 2013; 48: 866–873
- [2] Song MH, Kim MH, Lee SK et al. Endoscopic minor papilla interventions in patients without pancreas divisum. *Gastrointest Endosc* 2004; 59: 901–905