

# Retrospective analysis of 9 cases of appendiceal mucocele in 3,071 cases of appendicitis

JIE GAO<sup>1</sup>, ZHENFEI CHU<sup>2</sup>, JUN CHEN<sup>1</sup>, YIPING ZHENG<sup>3</sup>, XING HUANG<sup>1</sup> and KONGWANG HU<sup>4</sup>

<sup>1</sup>Department of Gastrointestinal Surgery, The First Hospital of Nanping Affiliated to Fujian Medical University, Nanping, Fujian 353000; <sup>2</sup>Department of Acute Abdomen Surgery, The First Hospital of Chuzhou, Chuzhou, Anhui 239000;

<sup>3</sup>Department of Respiratory Medicine, The First Hospital of Nanping, Nanping, Fujian 353000;

<sup>4</sup>Department of General Surgery, The First Affiliated Hospital of Anhui Medical University, Hefei, Anhui 230000, P.R. China

Received February 10, 2022; Accepted April 12, 2022

DOI: 10.3892/br.2022.1538

**Abstract.** Appendiceal mucocele is a rare disease. Due to the lack of specific clinical symptoms, and the high misdiagnosis rate before operation, in the present study, the clinical data were assessed to determine a potential basis for the diagnosis and treatment of appendiceal mucocele. The clinical data of 3,071 patients with appendicitis admitted between January 2014 and July 2021, including 9 patients with appendiceal mucoceles were retrospectively analyzed. The data were retrieved from the hospital records and included the patients' age, sex, leukocyte counts (measured in the peripheral venous blood sample), the surgical methods, the pathological results and the postoperative follow-up information. Among the 3,071 patients with appendicitis, 9 cases were appendiceal mucocele. These 9 were treated by laparoscopic surgery in 6 cases (2 laparoscopic appendectomy, 2 laparoscopic partial cecectomy plus appendectomy, and 2 laparoscopic right hemicolectomy) and laparotomy in 3 cases (partial cecectomy plus appendectomy). Pathological examination was performed on the surgically resected specimens of all patients. The results showed that 7 cases were appendiceal mucoceles, and 2 cases were low-grade appendiceal mucoceles. During the follow-up after surgery, one patient with exploratory laparotomy plus partial cecectomy and appendectomy was pathologically diagnosed with low-grade appendiceal myxoma. The patient developed peritoneal implants appeared 2 years later, and the remaining patients are still alive, without any postoperative complications or obvious signs of recurrence. Appendiceal mucocele is a disease that usually causes clinical manifestations of acute appendicitis. Ultrasound and CT scans can be used for preoperative diagnosis. The surgical treatment options for mucoceles are open or laparoscopic appendectomy,

cecectomy, and right hemicolectomy. Although the incidence of appendiceal mucocele is low, special attention should be paid to surgery due to its predisposition to peritoneal implantation and metastasis. Laparoscopic appendectomy with partial cecectomy is not a difficult procedure and is not likely to cause abdominal implantation metastasis, thus it should be the preferred surgical method. When conditions permit, intraoperative rapid cryotherapy can quickly identify the occurrence of malignant tumors.

## Introduction

Appendiceal mucocele is a type I tumor of epithelial origin that can be caused by a number of factors, such as chronic inflammation or the presence of a bezoar, and it can make the discharge of mucus difficult. As a result, mucus secreted by the cells lining the appendix cannot be expelled and instead is deposited into the abdominal cavity. As the amount of mucus accumulates, the pressure in the appendiceal cavity increases, thus leading to the atrophy of the mucosa and the disorder of secretory function, eventually resulting in the formation of stable cysts. Appendiceal mucocele does not have any known markers and is thus often misdiagnosed as acute appendicitis, or can even be missed completely. Patients often come to The First Hospital of Nanping with pain and discomfort in the right lower abdomen and a mass in the right lower abdomen, which is eventually confirmed by CT examination or intraoperative and postoperative pathology as appendiceal mucoceles (1-3). In the patients diagnosed with acute appendicitis, appendiceal mucoceles accounts for about 0.2-0.3% of cases. They are most common in patients >50 years old and can lead to ileus peritoneal effusion or peritonitis (4). Due to the continual improvement and frequent use of imaging methods, especially the application of plain and enhanced CT, the preoperative diagnosis rate of patients has been significantly improved, but there remains differing opinions on its prognosis and treatment methods (5,6). A few experts suggest appendiceal mucous cysts are a benign disease with a tendency towards forming malignant lesions, whereas others suggest that appendiceal mucous cysts may also divide into benign and malignant lesions (7,8). Certain patients may develop edema and inflammation, and possibly a perforated

---

*Correspondence to:* Dr Kongwang Hu, Department of General Surgery, The First Affiliated Hospital of Anhui Medical University, 218 Jixi Road, Shushan District, Hefei, Anhui 230000, P.R. China  
E-mail: 1132490260@qq.com

*Key words:* appendiceal mucocele, surgery, prognosis

appendix. Once the mucus leaks into the abdominal cavity, it can lead to extensive implantation and eventually to the development of secondary peritoneal pseudomyxoma, which drastically reduces the survival rate of patients (9). In the present study, the clinical data of 9 patients with appendiceal mucocèles were retrospectively analyzed in order to improve our understanding of the disease.

## Materials and methods

**Patient data.** There were 9 patients included in the analysis in the present study including 3 males and 6 females, aged 39-86 years old, with a median age 55 years old. The clinical manifestations were: 4 patients were hospitalized with right lower abdominal pain as the primary complaint, which was confirmed by color ultrasound or CT examination; 3 cases complained of abdominal discomfort, especially in the right lower abdomen, without obvious pain; 4 of the 9 exhibited muscle guarding (44.4%) and 3 exhibited rebounding pain (33.3%). Additionally, 1 patient exhibited hematochezia; and 2 patients were hospitalized due to a mass occupying the ileocecal area that was serendipitously found in routine physical examinations. This retrospective clinical study was approved by The Nanping First Hospital's Ethics Committee (approval no. NPSY2021120016) and written informed consent was obtained from all patients. The clinicopathological information of the patients obtained from their medical records are summarized in Table I.

**Surgical methods.** All patients analyzed received surgical treatment, including laparoscopic appendectomy in 2 cases, exploratory laparotomy + partial cecectomy + appendectomy in 3 cases, laparoscopic partial cecectomy + appendectomy in 2 cases, and laparoscopic right hemicolectomy in 2 cases (Table II).

**Pathological results and postoperative follow-up.** Among the reviewed appendiceal mucocèle cases, the diameter of the appendix was 1.2-5 cm, with an mean diameter of 2.89 cm. Among these, 2 cases were pathologically indicated as low-grade appendiceal mucinous tumors, and 7 cases were appendiceal mucinous cysts. The patients were followed up for between 3 months to 5 years after operation.

## Results

**Entire cohort.** Among the 3,071 patients with appendicitis, 9 cases were appendiceal mucocèle, with an incidence of 0.293%. Clinical manifestations included discomfort in the right lower abdomen in 7 out of 9 cases, whereas the other 2 cases were accidentally discovered. Additionally, 4 patients were misdiagnosed as appendicitis prior to operation, and the misdiagnosis rate was as high as 44.4%. In the preoperative imaging examination, 3 patients were diagnosed with appendiceal mucocèle, the accuracy rate of imaging diagnosis was 33.3%.

Of note, two of these cases were misdiagnosed as ascending colon tumors. All 9 patients underwent surgical treatment, including laparoscopic surgery in 6 cases (2 laparoscopic appendectomy, 2 laparoscopic partial cecectomy

Table I. Clinicopathological characteristics of the patients.

| Parameter                                   | Value     |
|---|-----------|
| Age, years                                  | 59.8±13.6 |
| White blood cell count, x10 <sup>9</sup> /l | 6.54±1.81 |
| Dimension, cm                               | 2.89±1.11 |
| Sex, n (%)                                  |           |
| Male  | 3 (33.3%) |
| Female                                      | 6 (66.7%) |
| Abdominal pain, n (%)                       |           |
| Yes   | 7 (77.8%) |
| No  | 2 (22.2%) |
| Muscle guarding, n (%)                      |           |
| Yes   | 4 (44.4%) |
| No  | 6 (55.6%) |
| Rebounding pain, n (%)                      |           |
| Yes   | 3 (33.3%) |
| No  | 6 (66.7%) |
| Pathological result, n (%)                  |           |
| Low grade mucinous neoplasm                 | 2 (22.2%) |
| Appendiceal mucocèle                        | 7 (77.8%) |

Table II. Surgical methods used to manage the patients.

| Surgical method   | n (%)    |
|---|----------|
| Laparoscopic appendectomy                                 | 2 (22.2) |
| Exploratory laparotomy + appendectomy + partial cecectomy | 3 (33.3) |
| Laparoscopic appendectomy + partial cecectomy             | 2 (22.2) |
| Right hemicolectomy cecectomy                             | 2 (22.2) |

plus appendectomy, and 2 laparoscopic right hemicolectomy and laparotomy in 3 cases (partial cecectomy plus appendectomy). Pathological examination was performed on the surgically resected specimens of all patients. The results showed that 7 cases were appendiceal mucocèles, and 2 cases were low-grade appendiceal mucocèles. During the follow-up from 3 months to 5 years after surgery, one patient with exploratory laparotomy plus partial cecectomy and appendectomy was pathologically diagnosed with low-grade appendiceal myxoma. The patient developed peritoneal implants appeared 2 years later, and the remaining patients are still alive, without any postoperative complications or obvious signs of recurrence.

### Typical case

**A patient who underwent laparoscopic partial cecectomy + appendectomy.** The patient came to the hospital complaining of right lower abdominal pain for half a day. After admission, abdominal CT examination was completed as shown in Fig. 1 (Appendix mucocèles is highlighted by arrow).

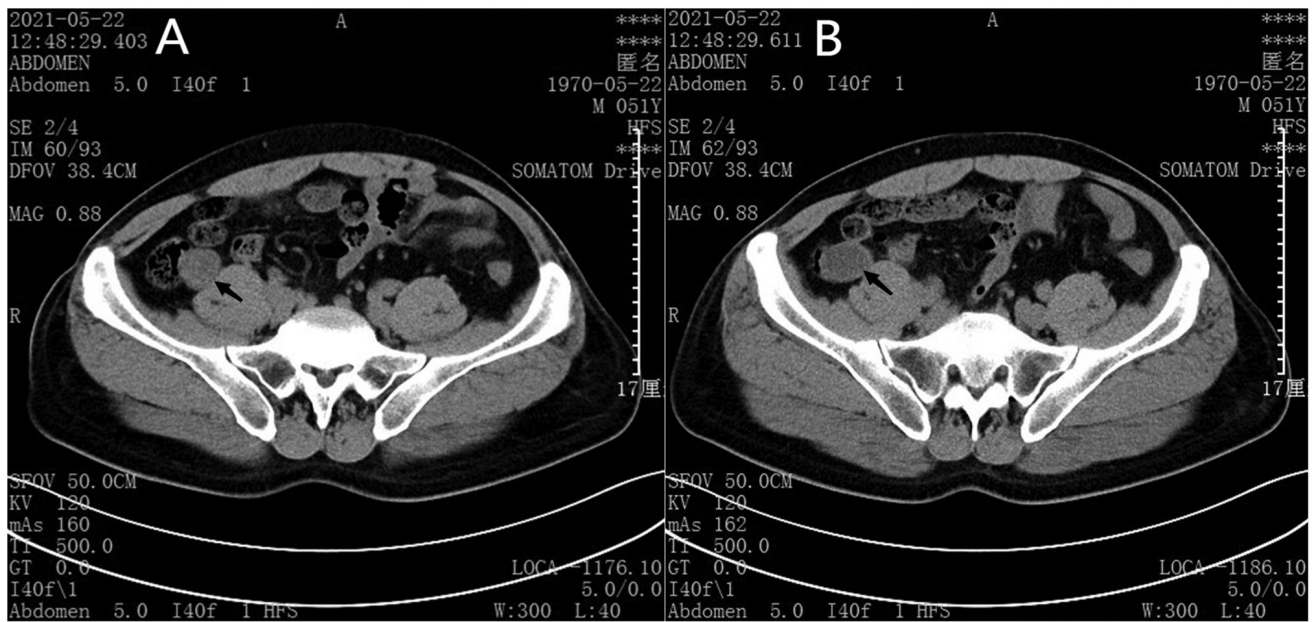


Figure 1. CT findings of the typical case described in the results. CT image of the patient before surgery, with the arrow indicating the location of the appendiceal mucocele. (A and B) The two different layers are shown in the panels.

**CT findings of this case.** After the anesthesia had taken effect, the patient was placed in the supine position, and the tissue was disinfected. Then a curved incision ~10 mm in length was taken from the umbilicus. After successful puncture, a 14 mmHg pneumoperitoneum was established. One incision of 5 mm and one incision of 12 mm were made on the McBurney (the point of outer third between the navel and the right anterior superior iliac spine) and inverse McBurney (the point of outer third between the navel and the left anterior superior iliac spine) incisions (10), respectively. The corresponding Trocar was inserted, and the greater omentum was explored to cover the ileocecal region. When the greater omentum was opened, obvious swelling was seen in the appendix, with a maximum diameter of 3 cm and a length of 7 cm; obvious adhesion to the surrounding tissues, notable mesangial edema, and no perforation or gangrene at the root was observed. Additionally, ~10 ml of a milky exudation was found in the abdominal cavity, which was considered to be an appendiceal mucocele. The appendix was lifted using grasping forceps and the hook was used to dissociate the appendix. The mesoappendix was dissected, then the appendiceal artery was disassociated. The appendiceal artery was clipped using a Hem-o-lock polymeric clips and severed with a hook. On the cecum, 2 cm away from the root of the appendix, the appendix and part of cecum were removed using ENDOPATH Endoscopic Linear Cutters. The stump was reinforced with 4-0 absorbable thread, and the greater omentum was sutured onto the stump. No active bleeding was observed on examination. The appendix was taken out, and an abdominal drainage tube was placed which led out from the right lower abdominal incision. After counting the instruments and gauze, the abdomen was closed layer by layer, and the specimens were sent for examination. The surgical procedure is shown in Fig. 2.

The pathological results were acute onset of chronic appendicitis with the formation of retention mucocele.

## Discussion

Appendiceal mucocele is a type I tumor of epithelial origin. Currently, appendiceal mucoceles are classified into four pathological types: Simple retention cyst and mucocele with mucosal hyperplasia (5-25% of cases), mucocystadenoma (63-84% of cases) and mucocystadenocarcinoma (11-20% of cases) (1). However, the clinical understanding of the pathological types of appendiceal mucoceles, especially the differentiation from pseudomyxosis peritoneum, remains unclear. In order to simplify the diagnosis of appendiceal mucocele, gastrointestinal neoplasms were divided into two separate grade, low grade and high grade, in the fourth edition of WHO Classification, and some morphological features were clarified, such as structure, cytology, presence of signet-ring cells and mitotic images (11). The International Peritoneal Surface Oncology Group extends the current WHO diagnostic terminology on WHO Classification. Finally, the classification of appendiceal mucoceles by the American Cancer Federation 8th edition uses a three-grade classification method: Low-grade tumor (G1), and high-grade tumors (G2 and G3) (12). In the present study, there were 2 cases of low grade appendiceal mucinous tumors, and 7 cases of appendiceal mucinous cysts.

The clinical manifestations of appendiceal mucoceles are atypical and lack specificity. Right lower abdominal pain or a right lower abdominal mass is the primary manifestation, and 25-50% of patients have no clinical symptoms and are found accidentally during physical examination or other operations. One patient in the present study presented with hematochezia, which was caused by the compression of intestinal mucosa by the appendiceal mucocele.

Patients with appendiceal mucocele have a high rate of preoperative misdiagnoses, and often postoperative pathological diagnoses are required. In this group, four patients (44.4%) were diagnosed with appendiceal cystic changes by preoperative CT, confirming that CT-assisted examination of

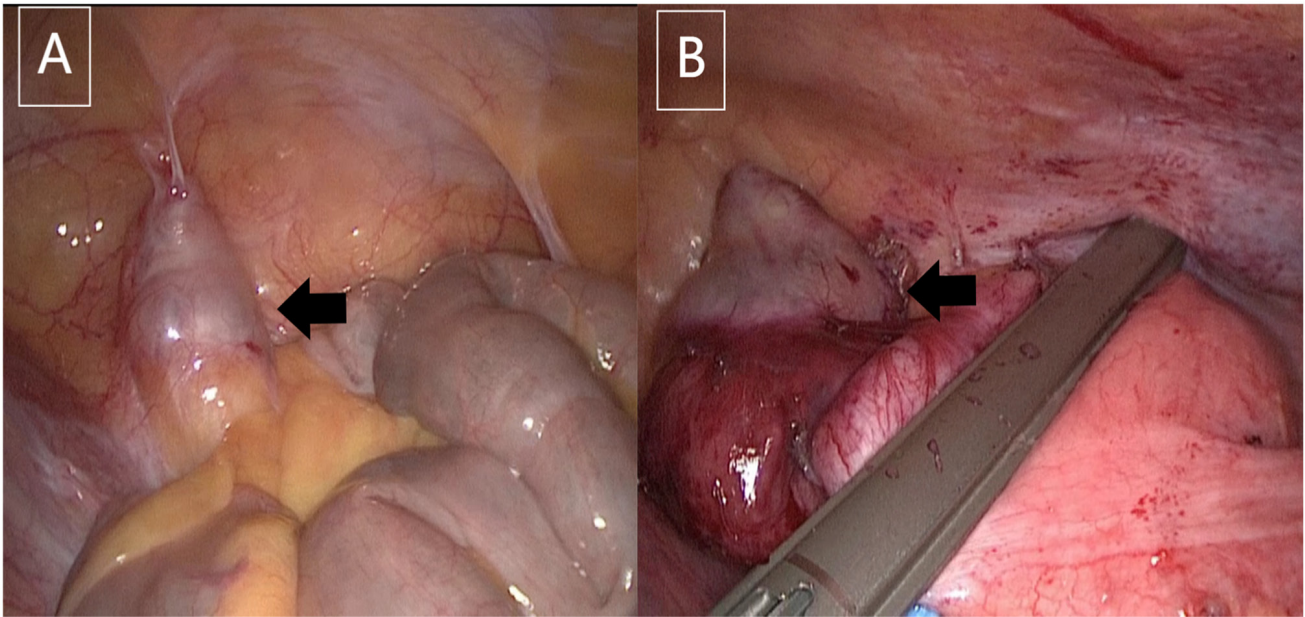


Figure 2. Intraoperative findings of the typical case described in the results. Patient's intraoperative view. (A) The appendiceal mucocoele just after entering the abdomen. (B) The separated appendiceal mucocoele, as it was being prepared to cut part of the cecum with the ENDOPATH Endoscopic Linear Cutters.

appendiceal mucocoeles is preferred, especially enhanced CT of the lower abdomen, such that most appendiceal mucocoeles can be diagnosed.

Once a diagnosis of an appendiceal mucocoele is confirmed, surgical treatment is necessary. The surgical methods for its treatment can be appendectomy, appendectomy + partial cecectomy ileocecectomy and right hemicolectomy. In this group, laparoscopic appendectomy + partial cecectomy provided good postoperative prognoses, and this highlights its preference as the surgical method. When conditions permit, intraoperative rapid cryotherapy can quickly identify the occurrence of malignant tumors. If a malignant cancer is diagnosed, laparoscopic right hemicolectomy is possible. The diameters of mucosal hyperplasia, appendiceal mucinous cystadenoma and appendiceal mucinous cystadenocarcinoma are typically >2 cm, and the specific diameter can provide certain clues for surgeons during surgery (13). However, there is no correlation between the size of the appendix and how malignant the appendiceal mucocoele is (14). Even though mucocoeles of the appendix are benign, they have a malignant tendency and can lead to implantation if the ruptured contents flow into the abdominal cavity. A variety of factors can lead to mucosal proliferation of cysts, including spontaneous perforation and iatrogenic injury. It is hypothesized that iatrogenic factors lead to one tenth of appendiceal mucocoeles developing into pseudomyxoma of the peritoneum (15).

In conclusion, on the cecum, 1.5-2 cm away from the appendix root, patients with complete mucocoele resection combined with direct appendectomy and partial cecectomy had a better prognosis than those with simple appendectomy and less peritoneal implantation metastasis. Meanwhile, compared with ileocecal bowel resection, the injury was less severe, and there were fewer complications; direct appendectomy + partial cecal resection has a smaller surgical scope and should be the first choice for treatment, but it is necessary to protect against ileocecal valve structure damage and cecum and ileum stenosis.

#### Acknowledgements

Not applicable.

#### Funding

No funding was received.

#### Availability of data and materials

The datasets used and/or analyzed during the present study are available from the corresponding author on reasonable request.

#### Authors' contributions

JG conceived the study, curated the data and wrote the original draft of the manuscript. ZC contributed to the acquisition of the data. JC performed the analysis. YZ revised the work critically for important intellectual content. XH contributed to the development and design of the methodology and the creation of models. KH supervised the study, provided the resources and wrote and reviewed the manuscript. JG and KH confirm the authenticity of all the raw data. All authors have read and approved the final manuscript.

#### Ethics approval and consent to participate

This retrospective clinical study was approved by The Nanping First Hospital's Ethics Committee (approval no. NPSY2021120016) and written informed consent was obtained from all patients.

#### Patient consent for publication

Not applicable.

## Competing interests

The authors declare that they have no competing interests.

## References

1. Abuoglu H, Yıldız MK, Kaya B and Odabaşı M: Clinicopathological analysis of patients operated for appendiceal mucocele. *Ulus Travma Acil Cerrahi Derg* 23: 230-234, 2017.
2. García Lozano A, Vázquez Tarrago A, Castro García C, Richart Aznar J, Gómez Abril S and Martínez Abad M: Mucocele of the appendix: Presentation of 31 cases. *Cir Esp* 87: 108-112, 2010 (In Spanish).
3. Carr NJ, McCarthy WF and Sobin LH: Epithelial noncarcinoid tumors and tumor-like lesions of the appendix: A clinicopathologic study of 184 patients with a multivariate analysis of prognostic factors. *Cancer* 75: 757-768, 1995.
4. Marudanayagam R, Williams GT and Rees BI: Review of the pathological results of 2660 appendectomy specimens. *J Gastroenterol* 41: 745-749, 2006.
5. Dixit A, Robertson JH, Mudan SS and Akle C: Appendiceal mucoceles and pseudomyxoma peritonei. *World J Gastroenterol* 13: 2381-2384, 2007.
6. Rymer B, Forsythe RO and Husada G: Mucocoele and mucinous tumours of the appendix: A review of the literature. *Int J Surg* 18: 132-135, 2015.
7. Ali SM, Al-Tarakji M, Shahid F, Qabani AS, Shah AA, Ahmed K, Khan MB and Inamullah: From diagnosis to management; mucocele of stump appendicitis, extremely rare finding in an uncommon surgical disease: Literature review. *Int J Surg Oncol* 2021: 8816643, 2021.
8. Scotté M, Laquerrière A, Riff Y, Majerus B, Manouvrier JL, Leblanc I, Michot F, Hémet J and Ténrière P: Appendiceal mucoceles. Pathophysiology and therapeutic indications. *J Chir (Paris)* 131: 303-312, 1994 (In French).
9. Rabie ME, Al Shraim M, Al Skaini MS, Alqahtani S, El Hakeem I, Al Qahtani AS, Malatani T and Hummadi A: Mucus containing cystic lesions 'mucocele' of the appendix: The unresolved issues. *Int J Surg Oncol* 2015: 139461, 2015.
10. Pattanshetti VM and Krishna KL: Conventional laparoscopic appendectomy versus double-incision, three-port laparoscopic appendectomy: A 1-year randomized controlled trial. *Asian J Endosc Surg* 11: 366-372, 2018.
11. Carr NS: Tumors of the appendix. In: World Health Organization Classification of Tumours. Vol 3. Bosman FT, Carneiro F, Hruban RH and Theise ND (eds). IARC Press, Lyon, pp122-125, 2010.
12. Valasek MA and Pai RK: An update on the diagnosis, grading, and staging of appendiceal mucinous neoplasma. *Adv Anat Pathol* 25: 38-60, 2018.
13. Pickhardt PJ, Levy AD, Rohrmann CA Jr and Kende AI: Primary neoplasms of the appendix: Radiologic spectrum of disease with pathologic correlation. *Radiographics* 23: 645-662, 2003.
14. Leonards LM, Pahwa A, Patel MK, Petersen J, Nguyen MJ and Jude CM: Neoplasms of the Appendix: Pictorial review with clinical and pathologic correlation. *Radiographics* 37: 1059-1083, 2017.
15. Virgilio E, Tallerini A, Addario Chieco P, Castagnola G and Cavallini M: Appendiceal mucocele: The importance of getting a preoperative diagnosis. *ANZ J Surg* 87: E312-E313, 2017.



This work is licensed under a Creative Commons Attribution-NonCommercial-NoDerivatives 4.0 International (CC BY-NC-ND 4.0) License.