



## Pediatrics

# Persistent Urinary Incontinence: A Case Series of Missed Ectopic Ureters



Ming-Hsien Wang, M.D. \*

Department of Urology, Johns Hopkins School of Medicine, Baltimore, MD, USA

## ARTICLE INFO

## Article history:

Received 10 June 2015

Received in revised form

7 July 2015

Accepted 9 July 2015

Available online 25 August 2015

## Keywords:

Pediatric incontinence

Ectopic ureter

Urologic imaging

## ABSTRACT

Ectopic ureter is a rare cause of urinary incontinence in children. Symptomatic cases are unlikely to resolve spontaneously, and incontinence are often associated with significant psychological impact on these children. This case series of 2 older children with missed ectopic ureters by the urologic community outline workup for persistent urinary incontinence, with emphasis on history, physical, embryology review, and radiographic evaluations.

© 2015 The Author. Published by Elsevier Inc. This is an open access article under the CC BY-NC-ND license (<http://creativecommons.org/licenses/by-nc-nd/4.0/>).

## Introduction

Enuresis and urinary incontinence are common diagnoses seen by pediatricians and are among the most common reasons for referrals to a pediatric urologist.<sup>1</sup> Although incontinence is not uncommon in early childhood, persistent pharmacologic- and treatment-refractory incontinence may be a sign of an underlying anatomical defect.

## Case presentation

Between September 2009 and September 2011, two female patients, ages 9 (patient A) and 10 (patient B), were referred for enuresis after receiving multiple evaluation and treatment at outside institutions. Both girls had normal prenatal ultrasounds (US) and were born full term without perinatal complications or other associated medical conditions. However, both patients experienced chronic, persistent urinary incontinence, managed with daily thin sanitary pads. The wetting continued past the age of normal toilet-training. Prior to referral to our institution, both patients had multiple normal urine cultures and had been previously evaluated with renal US, abdominal x-rays, voiding cystourethrography (VCUG), and cystoscopic evaluation by outside urologists. Treatment included various anticholinergics, stool softeners, courses of behavioral modification, and bed-wetting

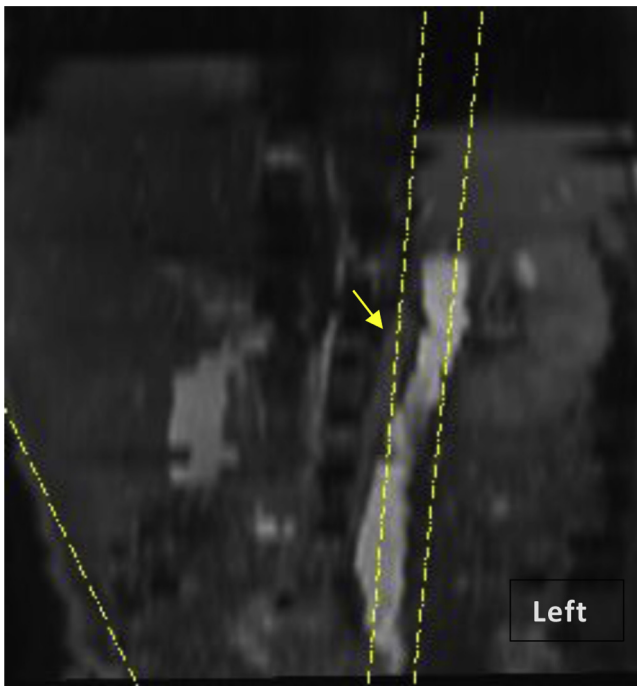
alarms. On our initial consultation, detailed history revealed persistent diurnal and nocturnal urinary incontinence with failure to achieve dryness. Physical examination revealed urine pooling in the vaginal vault. The genitourinary focused history and exam suggest the possibility of an ectopic ureter in each child.

Due to incomplete information from her prior evaluation, we elected to proceed with a repeat cystoscopy at our institution. Cystoscopy and vaginoscopy revealed the possibility of bilateral ureteral duplication, with urine pooling in the vagina and a normal trigone (2 separate ureteral orifices on the right and a laterally placed ureteral orifice on the left). Since the outside US was normal, we decided to perform an MR urography (MRU), in hope to better define her anatomy. The study revealed bilateral renal duplication with a poorly functioning, dysplastic left upper-pole kidney with associated hydroureter (Fig. 1). Parents were counseled with regards to the above findings and a decision was made to proceed with a robot-assisted laparoscopic removal of the upper dysplastic kidney and its associated ureter. Intraoperatively, a severely dilated ureter was noted draining from a small dysplastic upper-pole renal moiety (Fig. 2). Following surgical intervention, the patient reported immediate and complete resolution of urinary incontinence on postoperative day one.

Patient B was discussed at our weekly dedicated pediatric urology/radiology/nephrology conference, and we decided to proceed with an intravenous pyelography (IVP). The study was performed by an experience pediatric radiologist, which revealed prompt uptake of the intravenous contrast by both kidneys and on drainage, noted bilateral ureteral duplication. Oblique films confirmed the right upper-pole ureter draining into the vaginal with pooling of the contrast (Fig. 3). Since the right upper pole

\* Corresponding author.

E-mail address: [mwang33@jhmi.edu](mailto:mwang33@jhmi.edu).



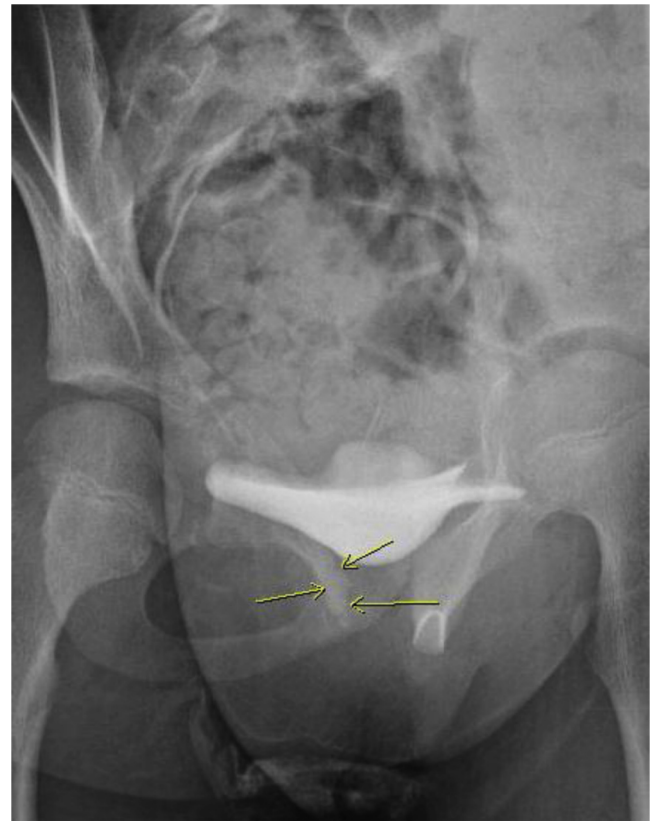**Figure 1.** Patient A has a left small dysplastic upper pole with dilated ureter (arrow).

demonstrated function, it was decided to preserve the renal moiety and patient underwent an extra vesical ureteroureterostomy and was continent immediately after the procedure.

## Discussion

Ectopic ureters are three times more common in females than in males.<sup>2</sup> However, overall prevalence and incidence are unknown because many cases are asymptomatic and discovered incidentally after radiographic imaging and autopsies. In symptomatic patients, approximately 80% of ectopic ureters are associated with duplicated collecting systems.<sup>3</sup>

Ectopic ureters are believed to result from the early splitting of the ureteric bud during embryonic development. The ureteral orifice is subsequently located in a more caudal position either at



**Figure 3.** Oblique IVP reveals insertion of the ectopic ureter into the vaginal cavity in Patient B (arrows).

the bladder neck other Müllerian structures, such as proximal vagina in girls or vas deferens in boys, perineum or anus.<sup>3</sup> The deviant location of the ureteric bud can cause abnormal interactions with nephrogenic blastema, resulting in renal dysplasia.<sup>3</sup> When the ureteral orifice is located below the urethral sphincter or outside the bladder, patients may present with symptoms of urinary incontinence, specifically in female patients.<sup>4</sup>

Detailed urologic history and physical examination provide clues to the presence of ectopic ureters. Specifically, history of continuous incontinence without period of dryness past age of potty training.

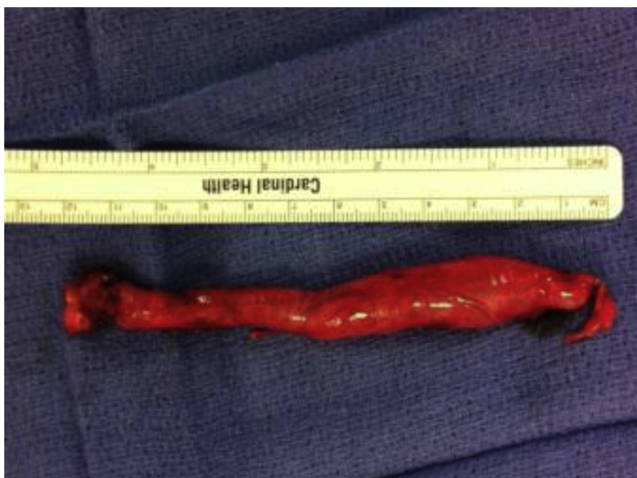Once ectopic ureter has been identified, treatment can be accomplished through several methods. When the renal segment associated with the ectopic ureter functions poorly, surgical removal of the dysplastic renal segment and associated ureter is curative. Renal segments that continue to display adequate function should be preserved.

## Conclusion

Ectopic ureter is a well-recognized entity as a cause of persist incontinence. However, as demonstrated in our case series, it is still missed in the urologic community. This case series serve as a reminder the importance of detail history and physician when evaluating children with incontinence, as unresolved urinary incontinence can have severe social and psychological impacts in these children.

## Acknowledgment

Susan Lin, BS and Eric Massanyi MD for their help in data gathering. Madhan Bosemani, MD and Ulrich Willi, MD for reviewing the imaging studies.



**Figure 2.** Patient A's dilated left upper pole ureter (12 cm). The ureter is serially sectioned to reveal a dilated lumen (0.7 cm).

## References

1. Forrest CB, Glade GB, Baker AE, et al. The pediatric primary-specialty care interface: how pediatricians refer children and adolescents to specialty care. *Arch Pediatr Adolesc Med.* 1999;153(7):705–714.
2. Ellerker AG. The extravesical ectopic ureter. *Br J Surg.* 1958;45:344.
3. Peters CA, Schluskel RN, Mendelsohn C. Ectopic ureter, ureterocele, and ureteral anomalies. In: Wein AJ, ed. *Campbell-Walsh Urology*. 10th ed. Philadelphia, PA: Saunders Elsevier; 2012. Chap 117.
4. Borer JG, Bauer SB, Peters CA, et al. A single-system ectopic ureter draining an ectopic dysplastic kidney: delayed diagnosis in the young female with continuous urinary incontinence. *Br J Urol.* 1998;81:474–478.