

Received: 2018.09.17
Accepted: 2018.10.31
Published: 2019.01.21

Treatment of Hypertensive Cardiogenic Edema with Intravenous High-Dose Nitroglycerin in a Patient Presenting with Signs of Respiratory Failure: A Case Report and Review of the Literature

Authors' Contribution:
Study Design A
Data Collection B
Statistical Analysis C
Data Interpretation D
Manuscript Preparation E
Literature Search F
Funds Collection G

ABCDEFG 1 **Fermín López-Rivera**
ABCDEFG 1 **Hector R. Cintrón Martínez**
ABCDEFG 1 **Christian Castillo LaTorre**
ABCDEFG 1 **Alexis Rivera González**
ABCDEFG 1 **Jose Gabriel Rodríguez Vélez**
ABCDEF 1 **Vanessa Fonseca Ferrer**
ABCDEF 2 **Omar F. Méndez Meléndez**
BCDEF 3 **Edgar J. Vázquez Vargas**
ABCDEFG 1 **Hernán A. González Monroig**

1 Department of Internal Medicine, San Juan City Hospital, San Juan, Puerto Rico
2 Department of Pneumology and Critical Care Medicine, San Juan City Hospital, San Juan, Puerto Rico
3 Department of Cardiology, Hospital Episcopal San Lucas, Ponce, Puerto Rico

Corresponding Author: Fermín López Rivera, e-mail: drlopezrivera.ga@gmail.com
Conflict of interest: None declared

Patient: Male, 63
Final Diagnosis: Hypertensive cardiovenic pulmonary edema
Symptoms: Shortness of breath
Medication: —
Clinical Procedure: —
Specialty: General and Internal Medicine

Objective: Management of emergency care





Background: Pulmonary edema is the accumulation of fluid in the lung secondary to increased hydrostatic pressure. Hypertensive cardiogenic pulmonary edema presents with a sudden onset of severe dyspnea, tachycardia, and tachypnea, and can occur when the systolic blood pressure exceeds 160 mmHg in association with acute decompensated congestive cardiac failure (CCF). A case is presented of hypertensive cardiogenic pulmonary edema treated with high-dose nitroglycerin and includes a review of the literature.

Case Report: A 63-year-old Hispanic male with a medical history of hypertension, coronary artery disease, heart failure with a reduced ejection fraction of 35%, chronic kidney disease (CKD) and diabetes mellitus, presented as an emergency with acute, severe dyspnea. The patient was initially managed with 100% oxygen supplementation and intravenous (IV) high-dose nitroglycerin (30 mcg/min), which was titrated every 3 minutes, increasing by 15 mcg/min until a dose of 120 mcg/min was reached. After 18 minutes of aggressive therapy, the patient's condition improved and he no longer required mechanical ventilation.

Conclusions: Hypertensive cardiogenic pulmonary edema is a challenging clinical condition that should be diagnosed and managed as early as possible, and distinguished from respiratory failure due to other causes. Although hypertensive cardiogenic pulmonary edema is usually managed acutely with high-dose diuretics, this case has highlighted the benefit of high-dose IV nitroglycerin, and review of the literature supports this treatment approach.

MeSH Keywords: Furosemide • Heart Failure • Nitroglycerin • Pulmonary Edema

Full-text PDF: <https://www.amjcaserep.com/abstract/index/idArt/913250>

 4172  1  6  50



Background

Hypertensive cardiogenic pulmonary edema is a hyperacute complication of congestive cardiac failure (CCF) and is defined as the accumulation of fluid in the lung secondary to an abrupt increase in hydrostatic pressure, which cause extravasation of fluid from the lung circulation into the interstitium [1]. Hypertensive cardiogenic pulmonary edema should be distinguished from acutely decompensated heart failure, as the former presents with severe symptoms including tachypnea, hypertension, breathing difficulty and hypoxemia that can lead to an imminent acute respiratory failure, whereas acutely decompensated heart failure presents with a more gradual onset of symptoms.

CCF has an incidence of 10/1,000 and has a prevalence of over 5 million patients in the United States, being responsible for more than 1,000,000 hospital admissions annually [2–4]. Patients with hypertensive cardiogenic pulmonary edema represent approximately 25% of hospital admissions for patients with CCF, resulting in more than 250,000 annual hospital admissions and has a high mortality of between 15–20% [5,6]. Special attention should be paid to the diagnosis in the elderly population, given that the median age for acute pulmonary edema is 74 years [7]. Several comorbidities are associated with hypertensive cardiogenic pulmonary edema, the most common being hypertension and coronary artery disease resulting in ischemic heart disease and CCF (Figure 1) [8].

In recent decades, the pathophysiology of hypertensive cardiogenic pulmonary edema has become increasingly understood, which has resulted in new approaches to clinical management. Hypertensive cardiogenic pulmonary edema is defined as the accumulation of fluid in the lung secondary to an abrupt increase in hydrostatic pressure, which results in extravasation of fluid from the lung circulation into the alveolar space and pulmonary interstitium, as demonstrated by the Starling formula (Figure 2) [9]. The normal pulmonary capillary wedge pressure (PCWP) ranges from 8–12 mmHg and the normal colloid oncotic pressure is 25 mmHg [10,11]. In hypertensive cardiogenic pulmonary edema, cardiac output is reduced due to left atrial impairment or left ventricle dysfunction, with back pressure on the pulmonary capillaries, leading to an increase in PCWP that exceeds the oncotic pressure, pulmonary edema, hypoxia, and reduced alveolar gas exchange. In hypertensive cardiogenic pulmonary edema, the cardiac output does not supply metabolic needs and results in an increase in catecholamines, which increase the systemic vascular resistance and blood pressure with a further increase in the end-diastolic pressure and continued elevation in the PCWP (Figure 3).

Hypertensive cardiogenic pulmonary edema can be triggered by acute exacerbation of left ventricular dysfunction, cardiac

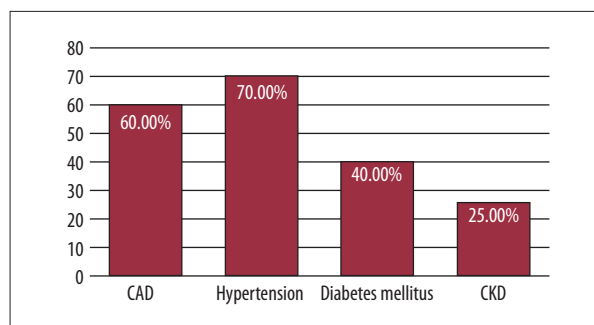


Figure 1. Comorbidities related to hypertensive cardiogenic pulmonary edema. The bar chart shows the most common comorbidities in patients diagnosed with hypertensive cardiogenic pulmonary edema.

$$Q = K_f(P_{cap} - P_{if}) - K_d(\pi_{cap} - \pi_{if})$$

Figure 2. The Starling equation. Q – the net fluid movement; K_f – the permeability in surface area; P_{cap} – capillary hydraulic pressure; P_{if} – the interstitial hydraulic pressure; K_d – the membrane permeability; π_{cap} – the capillary pressure; π_{if} – the oncotic pressure.

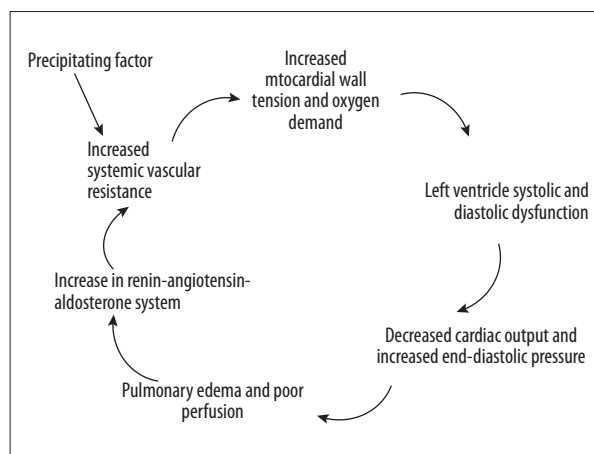


Figure 3. Summary of the pathophysiology of hypertensive cardiogenic pulmonary edema.

ischemia, severely elevated blood pressure, aortic or mitral valve dysfunction, and acute dysrhythmias, and although patients have increased filling pressure, only 50% patients are reported to be fluid overloaded [12,13]. Regardless of the precipitating etiology, patients with hypertensive cardiogenic pulmonary edema should be managed in terms of combined management of cardiac preload and afterload. Although hypertensive cardiogenic pulmonary edema is usually managed acutely with high-dose diuretics, a case is presented of hypertensive cardiogenic pulmonary edema treated with high-dose

nitroglycerin, also known as glyceryl trinitrate (GTN), and includes a review of the literature.

Case Report

A 63-year-old male Hispanic patient presented to hospital as an emergency with sudden onset of severe respiratory distress, palpitations, and profuse sweating. He was in his usual state of health and could freely ambulate with independent activities of daily living until 30 minutes before arrival to emergency room. He had a 20-year history of hypertension, a 15-year history of diabetes mellitus, coronary artery disease requiring insertion of a coronary artery stent five years previously, a ten-year history of New York Heart Association (NYHA) Class II heart failure with a reduced ejection fraction (EF) of 35%, chronic kidney disease (CKD) stage 3B. On admission to hospital, his medications included carvedilol (25 mg twice daily), lisinopril (20 mg daily), spironolactone (25 mg daily), furosemide (20 mg daily), glargine insulin (20 units at bedtime), insulin lispro injection (7 units three times daily), atorvastatin (40 mg daily), and aspirin (81 mg daily), with no known drug allergies.

On examination, his blood pressure was 205/110 mmHg, his respiration rate was 29 breaths/min, his heart rate was 118 beats/min, pulse oximetry was 82% (in room air), and his temperature was 36.2°C. His weight was 72 kg and his height was 68 inches, resulting in a body mass index (BMI) 24.13 kg/m². On physical examination, the patient was in severe respiratory distress, he was sweating, and unable to speak clearly. His jugular venous pressure was elevated, as shown by jugular vein distention (3+). On chest auscultation, profuse bilateral crackles were present in all pulmonary fields. Cardiac auscultation was remarkable for a gallop with a regular rate along and a systolic murmur 3/6 heard at the left midclavicular line, at the level of the fifth intercostal space. The point of maximal cardiac impulse was displaced to the left (at the anterior mid-axillary line) and no abdominal distention or ascites was noted, with lower limb pitting edema (1+) up to the level of the mid-calf.

The patient was placed in the cardiopulmonary resuscitation (CPR) area where blood gases on air were measured, and laboratory tests were ordered. The patient was treated with 100% oxygen using a non-rebreather mask and positioned at 90°, resulting in improvement pulse oximetry, which increased up to 90%. An electrocardiogram (ECG) showed sinus tachycardia, lateral lead ST depression (of 1 mV), left axis deviation and left ventricle hypertrophy. A portable chest X-ray was obtained which was remarkable for an enlarged cardiac silhouette, stag's antler sign of upper lobe pulmonary venous diversion (cephalization), and Kerley B-lines, indicating interstitial edema (Figure 4).

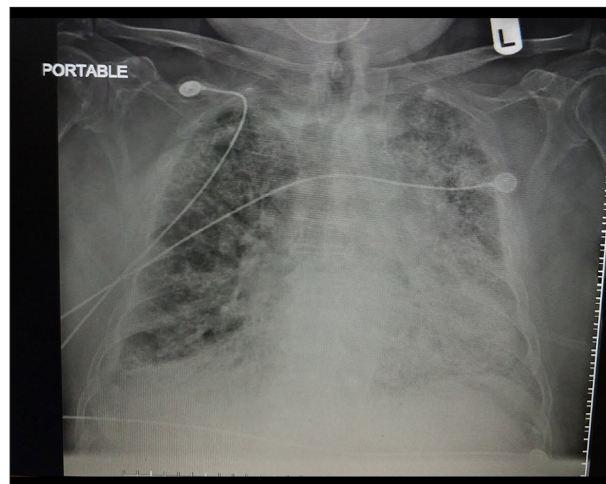


Figure 4. Portable chest X-ray (anteroposterior) shows an increased cardiothoracic index and interstitial edema.

Although laboratory tests were ordered, because the patient was critically ill, and further management could not be delayed, initial treatment was guided based on the clinical findings, clinical history, the ECG, arterial blood gases, and X-ray findings. In view of the findings of the initial investigations and the absence of fever, pneumonia was excluded and a diagnosis of hypertensive cardiogenic pulmonary edema was made. Intravenous (IV) nitroglycerin treatment was commenced, starting at 30 mcg/min and increased by 15 mcg/min every 3 minutes, with continuous pulse oximetry and monitoring of vital signs every 3 minutes. After 18 minutes, nitroglycerin was titrated up to 120 mcg/min and his blood pressure decreased to 148/82 mmHg, his systolic blood pressure reduced by 29%, his diastolic blood reduced by 25%, and his heart rate decreased to 87 beats per minute. A rapid clinical improvement was made and the patient was able to communicate in complete sentences and was able to breathe without the use of accessory muscles. Pulse oximetry showed an oxygen saturation >97%, and oxygen supplementation continued with the use of a nasal cannula at 3 L/min and the patient's pulse oximetry measurement was >96%.

After 25 minutes, the patient was treated with enalapril (2.5 mg IV) combined with furosemide (20 mg IV). Nitroglycerin was decreased at a rate of 10 mcg/min every 5 minutes until it was discontinued, followed with an oral dose of isosorbide dinitrate (30 mg). After complete clinical stabilization, the laboratory results showed a white blood cell (WBC) count of $11.43 \times 10^9/\mu\text{L}$, hemoglobin of 10.9 g/dl, hematocrit of 31.8%, platelets level of $74 \times 10^9/\text{L}$, sodium of 144 mmol/L, potassium of 3.9 mmol/L, chloride of 107 mmol/L, carbon dioxide (CO₂) of 25 mmol/L, blood urea nitrogen (BUN) of 27 mg/dL, creatinine of 1.4 mg/dL, brain natriuretic peptide (BNP) of 3,452 pg/ml, and troponin I <0.05 ng/ml. Blood gas measurements on air included pH of 7.381, pCO₂ of 44.8 mmHg, pO₂ of 57 mmHg, HCO₃ of 25.8 mmol/L, and oxygen saturation of 84%.

The patient was evaluated for the presence of possible underlying pulmonary embolism (PE) using the Wells risk stratification criteria for PE, and stratified as low-risk, with further evaluation with a D-dimer level of 340 ng/ml, which was interpreted as negative. Evaluation for hyperthyroidism showed a normal ultrasensitive plasma thyroid stimulating hormone assay (uTSH) measurement of 2.56 µU/mL and free thyroxine (T4) of 6.87 µU/mL.

The patient was admitted to the internal medicine hospital ward with a diagnosis of hypertensive cardiogenic pulmonary edema and discharge home 48 hours later. On discharge from hospital, his medications included furosemide (40 mg daily), carvedilol (12.5 mg twice a day), sacubitril/valsartan (24 mg/26 mg twice a day), spironolactone (25 mg daily) and isosorbide mononitrate (60 mg daily). The patient underwent weekly follow-up by his cardiologist who optimized the medication therapy. No emergency room visits or hospitalization were reported, at least for the next 60 days.

Discussion

The most common causes of exacerbation of heart failure include missed medication, symptomatic anemia, cardiac arrhythmia, cardiac ischemia, increased cardiac output, renal failure, and pulmonary embolism. The patient described in this case report developed acute, severe hypertensive cardiogenic pulmonary edema. In this case, it was believed that non-compliance with anti-hypertensive medication was the cause of his severe hypertension, which subsequently triggered the exacerbation of heart failure.

The presentation of acute, severe hypertensive cardiogenic pulmonary edema is a medical emergency that requires immediate diagnosis and treatment, even before the results of laboratory tests become available, with the diagnosis based on medical history, physical examination, electrocardiogram (ECG), and chest X-ray findings. However, the frequency of making an accurate and immediate diagnosis based on these initial investigations have been shown to have a sensitivity of no more than 70% [13]. This patient presented with the classical physical finding of hypertensive cardiogenic pulmonary edema, diffuse pulmonary crackles on auscultation, a raised jugular venous pressure, severe acute dyspnea (air hunger), and elevated blood pressure, and was managed successfully with high-dose intravenous nitroglycerin. This patient was not managed with furosemide or other diuretics, but with high-dose intravenous (IV) nitroglycerin, also known as glyceryl trinitrate (GTN)

As shown in Table 1, there is now a range of drugs available to physicians that may be used to treat hypertensive cardiogenic

Table 1. Renal and hepatic dose adjustments.

Drugs	Dose adjustment	
	Renal	Hepatic
Nitroglycerin	No	No
Furosemide	No	Caution advised
Nesiritide	Caution advised	No
Morphine	Yes	Yes
Enalaprilat	Yes	No

pulmonary edema, but few drugs require no dose modification to prevent renal and hepatic toxicity, and there are currently no guidelines for standard of care in patients with hypertensive cardiogenic pulmonary edema (Table 1). Drugs used should have a rapid onset, allow for a titratable dose based on patient response, have a predictable effect, a short half-life, and a mechanism of action that blocks several pathways in the pathophysiology of this disease. During the acute phase of hypertensive cardiogenic pulmonary edema, the compensatory mechanism of activation of the renin-angiotensin-aldosterone system increases myocardial contractility and the adrenergic system.

Frank and Starling first described the relationship between the end-diastolic volume (preload) and ventricular performance. The end-diastolic volume, defined as the filling pressure of the heart at the end of diastole, which is intrinsically related to myocardial distention should not be confused with venous return [14]. To understand venous return, cardiac output can be defined as the amount of blood volume being pumped by the heart during one minute, and venous return can be defined as the amount of blood returning from the periphery to the right atrium [15]. Under normal circumstances, the venous return matches the cardiac output. The preload can be assessed from the left ventricle end diastolic pressure with an invasive procedure (cardiac catheterization) or a non-invasive study (echocardiography). Although cardiac preload is elevated in hypertensive cardiogenic pulmonary edema, this type of evaluation is not needed for the initiation of treatment [16]. A normal heart with augmented end-diastolic volume, as a compensatory mechanism, proportionally increases the stroke volume, as otherwise, a heart with altered function that receives an increased preload is not able to increase the stroke volume efficiently, causing retrograde augmentation of pressure that is translated into increased pulmonary hydrostatic pressure, as occurs in hypertensive cardiogenic pulmonary edema. Pharmacologically, the initial treatment must aim to reduce the preload, which will subsequently reduce the pulmonary hydrostatic pressure, to equalize the cardiac output and the venous return. There are several drugs that have been

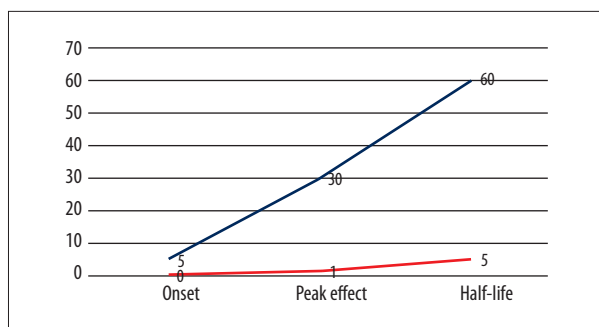


Figure 5. Pharmacokinetics of nitroglycerin compared with furosemide, measured in minutes. The Y-axis shows the time in minutes. The X-axis compares the onset, peak, and half-life. The blue line corresponds to furosemide. The red line corresponds to nitroglycerin. The nitroglycerin line demonstrates a more rapid onset and peak with a shorter half-life.

described to have a therapeutic effect in this part of the cycle of heart failure, nitroglycerin, morphine sulfate, loop diuretics, and recombinant brain natriuretic peptide (BNP).

Nitroglycerin, also known as glyceryl trinitrate (GTN), is a member of the group of nitrovasodilators, which achieve their effect by donating a free radical nitric oxide to activate guanylate cyclase in vascular smooth muscle, leading to dephosphorylation of the myosin light chain. As result, nitroglycerin produces a marked vasodilator effect on veins and a modest vasodilator effect on arteries [17]. The venous vasodilator effect is translated into an increased venous capacitance, which causes a decreased venous return, which also reduces cardiac preload. There are several formulations for nitroglycerin, including sublingual tablets, translingual spray, topical transdermal patches, and intravenous (IV) formulations. The topical and transdermal formulations are not recommended during hypertensive cardiogenic pulmonary edema because of possible overload and profuse sweating, which can cause erratic absorption with unpredictable effects. Therefore, as this case report has shown, the use of the IV formulation of nitroglycerin results in an immediate peak effect, a duration of 3–5 minutes, with a half-life of 1–4 minutes (Figure 5) [18]. Nitroglycerin is the most effective, predictable, and rapidly-acting drug for the treatment of hypertensive cardiogenic pulmonary edema [19]. There has been a previous study that compared the use of nitroglycerin, furosemide, and morphine, in the treatment of hypertensive cardiogenic pulmonary edema, which demonstrated the superiority of nitroglycerin [20]. Because of the characteristic rapid onset and brief half-life of nitroglycerin, hypotension or other undesired effects can be controlled quickly by adjusting the dose, resulting in a return to baseline within 5–10 minutes. It is important to be aware that the dose of nitroglycerin for the treatment of hypertensive cardiogenic pulmonary edema is not the same dose used for angina or heart failure.

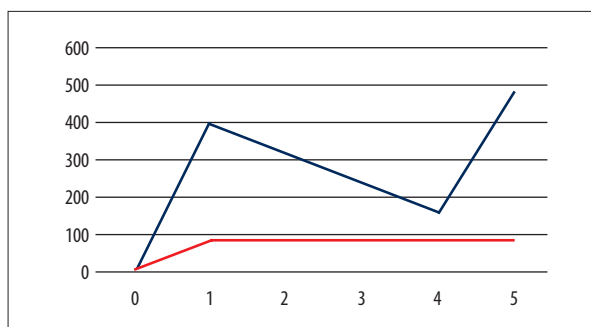


Figure 6. Comparison of blood drug levels from equivalent doses of between intravenous (IV) nitroglycerin and sublingual nitroglycerin. The X-axis shows drug concentrations in the blood in micrograms. The Y-axis shows the time in minutes. The blue line represents sublingual nitroglycerin. The red line represents the intravenous (IV) nitroglycerin. This chart compares the blood drug level using either route of administration during the first 5 minutes. Sublingual nitroglycerin, or glyceryl trinitrate (GTN), at the usual dose (0.4 mg), resulted in a higher drug level than intravenous nitroglycerin at 80 mcg/min.

For hypertensive cardiogenic pulmonary edema, the nitroglycerin dose should be commenced at 20 mcg/min followed by a rapid uptitration of 15–20 mcg/min every 3–5 minutes with an average goal of 100 mcg/min and a maximum dose of 400 mcg/min, which results in a decrease in afterload [21,22]. When an infusion pump is not available, nitroglycerin can be administered as an IV bolus (3 mg) every 5 minutes, where a 3 mg bolus is equivalent to an infusion of 600 mcg/min [23]. The usual anti-anginal sublingual nitroglycerin dose of 0.4 mg every 5 minutes for 3 doses is equivalent to 80 mcg/min as an IV infusion (Figure 6).

Furosemide is a potent diuretic, which belongs to the family of loop diuretics that inhibit the reabsorption of sodium and chloride in the renal ascending loop of Henle, and the proximal and distal renal tubules, which results in reduced preload. This diuretic has several formulations, including oral tablets and solution for intramuscular and intravenous use, and sublingual preparations. Although furosemide can reduce blood pressure, the evidence-based guidelines of the Eighth Joint National Committee (LNC 8) recommend that loop diuretics should not be used for the treatment of hypertension [24]. Furosemide is currently recommended for the treatment of edema associated with renal disease, heart failure, and hepatic disease. The pharmacokinetics of furosemide explain why it should no longer be considered as a monotherapy in hypertensive cardiogenic pulmonary edema. Intravenous furosemide has an average onset of its treatment effects of 5 minutes, a peak effect at 30 minutes and half-life of 60 minutes [25]. It has been shown that, for the treatment of hypertensive cardiogenic pulmonary edema, high doses of furosemide are

required, with an IV bolus of 40–80 mg, with the use of a repeat dose after 20 minutes if there was no improvement [26]. Although higher doses of furosemide can be associated with symptomatic improvement, high doses are associated with impaired renal function and an increased rate of admission to intensive care units [27]. It is important to note that 50% of patients diagnosed with hypertensive cardiogenic pulmonary edema are fluid overloaded, and the remainder are hypovolemic or euvolemic, and treatment with high-dose furosemide will affect renal function. Furthermore, patients with hypertensive cardiogenic pulmonary edema are in an increased sympathetic and adrenergic physiological state with increased systemic vascular resistance, resulting in renal vasoconstriction [28]. The peak effect of furosemide in renal impairment will be considerably delayed, by between 45–120 minutes, which results in treatment delay [29]. Clinical studies have shown that the use of furosemide during the initial phase of hypertensive cardiogenic pulmonary edema results in adverse effects due to the activation of the renal angiotensin aldosterone system in response to the volume depletion with further increase in systemic vascular resistance and pulmonary capillary wedge pressure (PCWP) and reduction in cardiac output and stroke volume [30].

Morphine is an important treatment for pain and cardiac failure and is available in several presentations, including tablets, suppositories, and solutions for intramuscular, intravenous, and intrathecal use and can be prescribed in hypertensive cardiogenic pulmonary edema. When administered intravenously it has an onset of action ranging from 5–10 minutes, a peak dose by 20 minutes, and a half-life of 2–4 hours [31]. Side effects of morphine include mast cell degranulation, the release of histamine, and vasodilation with further reduction in preload, although there have been no randomized controlled trials to support this effect [32,33]. The symptomatic improvement in cardiac function following morphine treatment could be due to the reduction of sympathetic activity, an anxiolytic effect, and reduction of dyspnea [27]. Despite the assumption that this drug reduces preload, a study has shown that in 46% of patient with hypertensive cardiogenic pulmonary edema treated with morphine showed objective clinical deterioration, while another study showed an increased probability for admission to the intensive care unit or for intubation following treatment with morphine [34,35]. Other side effects of morphine use include nausea, bronchoconstriction, pruritus, and anaphylactic reactions.

Afterload is closely related to aortic pressure and can be defined as the stress or tension in the wall of the left ventricle during contraction against peripheral vascular resistance. Patients with hypertensive cardiogenic pulmonary edema have increased levels of catecholamines that increase peripheral vascular resistance, resulting in reduced stroke volume and

reduced cardiac output, and so patients will benefit from drugs that work by reducing afterload. High-dose nitroglycerin can also reduce cardiac afterload, but only after a prolonged infusion, usually after 12–24 hours, and patients can develop tolerance because of depletion of the enzymes responsible for nitrate catabolism. Therefore, the combined use of nitroglycerin with other drugs that reduce afterload might be considered for patients with hypertensive cardiogenic pulmonary edema.

Angiotensin-converting-enzyme (ACE) inhibitors prevent the conversion of angiotensin I to angiotensin II, and the first synthesized ACE inhibitor was captopril [36]. ACE inhibitors are prescribed for hypertension, to prevent the progression of diabetic nephropathy, and in chronic heart failure with reduced ejection fraction, but are also prescribed in acutely decompensated heart failure and hypertensive cardiogenic pulmonary edema. In particular, enalapril can be used as an IV formulation, and the active metabolite of enalapril, after hepatic metabolism, inhibits the conversion of angiotensin I to angiotensin II, resulting in inhibition of the renin-angiotensin-aldosterone system. This drug does not require hepatic dose adjustment but does need renal dose adjustment. Although patients with hypertensive cardiogenic pulmonary edema may have impaired renal function, the benefits of the use of enalapril outweigh the risks. However, premedication with nitrates will enhance affected renal function due to renal vasodilation, and may reduce the possible nephrotoxic effect of enalapril in the acute phase [37]. Due to the mechanism of action of ACE inhibitors, enalapril decreases renal arteriolar efferent tone, which is required to maintain the glomerular filtration rate under states of reduced renal perfusion. Enalapril has an onset of action of 15 minutes, a peak effect of between 1–4 hours, a duration of effect of 6 hours, and a half-life of 36 hours [38]. The overall benefit of this drug includes the reduction of pulmonary capillary wedge pressure, improvement in cardiac stroke volume and cardiac output with no effect on heart rate or change in mean arterial pressure, which translates to a reduction in mechanical ventilation, intensive care unit admission, and length of hospital stay [39,40]. ACE inhibitors should be avoided in patients with a history of angioedema and should be used with extreme caution in hypotensive patients and history of aortic stenosis.

Nesiritide is a recombinant form of brain natriuretic peptide (BNP), with vasodilatory properties that enhances diuresis and improves cardiac output [41]. Nesiritide was first approved in 2001 with an indication for the treatment of acutely decompensated heart failure due to its capacity to reduce pulmonary wedge pressure. Several studies have evaluated the significance of nesiritide in acute decompensated heart failure, including the ASCEND-HF trial and VMAC trial [41–43]. During the ASCEND-HF trial, dyspnea at 6 hours and 24 hours following treatment with nesiritide, the rate of rehospitalization

or death at 30 days was evaluated, which found only a small reduction in dyspnea that did not reach statistical significance [41,42]. The VMAC study included 498 patients and showed that nesiritide treatment had a significant effect on dyspnea at 3 hours, but the effect was similar to intravenous nitroglycerin with no significant effect at 24 hours [42]. These clinical trials had limitations in that most patients received an average nitroglycerin dose of 30–40 mcg/min and did not receive the optimal nitroglycerin dose for the treatment of hypertensive cardiogenic pulmonary edema (>100 mcg/min), because most physicians were reluctant to use high doses [43]. Another small clinical trial showed impaired renal function following nesiritide treatment [44]. Nesiritide has an onset of action within 15 minutes, the peak effect occurs at 1 hour, the duration of its effects last up to 60 minutes, and it has a half-life of 2–18 minutes [45].

In the treatment of cardiogenic pulmonary edema, supplemental oxygen is not required unless the oxygen saturation falls below 92%, because hyperoxemia will increase the circulation of free radicals which will cause vasoconstriction and decrease cardiac output, which may increase mortality [46,47]. There are no guidelines regarding which form of oxygen support should be used, which currently relies on the patient's needs. When oxygen saturation falls below 92%, oxygen can be supplemented via a nasal cannula or face mask, as long as the patient does not develop severe respiratory distress, acidosis, or hypoxemia. Once supplemental oxygen is insufficient, non-invasive ventilation can be considered, which includes bi-level positive airway pressure (BiPAP) and continuous positive airway pressure (CPAP) [48]. The use of non-invasive ventilation is considered to reduce the length of stay in the intensive care unit, reduce hospital costs, and reduce the need for invasive mechanical ventilation. Of the non-invasive ventilation options, the most recommended method is CPAP, based on a small trial, which concluded that patients managed with BiPAP improved more rapidly, but patients in the BiPAP arm initially reported more chest pain than patients in the CPAP arm [49]. Mechanical ventilation is considered to be a treatment of last resort when patients have persistent hypoxia despite the use of non-invasive ventilation, or where there are contraindications that include altered mental status, vomiting, or non-compliance.

Conclusions

This case report has highlighted that hypertensive cardiogenic pulmonary edema is a challenging clinical condition that should be diagnosed and managed as early as possible, and

distinguished from respiratory failure due to other causes. Although hypertensive cardiogenic pulmonary edema is usually managed acutely with high-dose diuretics, this case has demonstrated the benefit of high-dose intravenous (IV) nitroglycerin, also known as glyceryl trinitrate (GTN), and review of the literature supports this treatment approach. Until recently, furosemide was considered the cornerstone in the management of hypertensive cardiogenic pulmonary edema. Although pharmacokinetic and pharmacodynamic studies support the improved therapeutic role for high-dose IV nitroglycerin (>100 mcg/min) when prescribed for hypertensive cardiogenic pulmonary edema, physicians still use high-dose furosemide. High-dose nitroglycerin could be considered a more cost-effective therapy in view of evidence that this medication can reduce the need for tracheal intubation, does not affect renal function, and does not increase intensive care unit admission rates, which as occur with furosemide treatment. We recommend premedication with nitroglycerin and an ACE-inhibitor followed by the use of furosemide once clinical stability has been achieved, as this strategy can reduce the adverse cardiovascular and renal effects of furosemide [50]. Newer drugs, such as nesiritide, might be promising treatments, but are expensive and have not shown superiority when compared with nitroglycerin. However, nesiritide is still suitable for the management of hypertensive cardiogenic pulmonary edema when nitroglycerin is contraindicated, for example when following the recent use of a phosphodiesterase-5 (PDE-5) inhibitor. This case report and literature review showed the superiority of nitroglycerin over furosemide as monotherapy not only by communicating our clinical case but by comparing the pharmacokinetics and pharmacodynamics of these drugs. Cardiology and emergency medicine associations have still to develop evidence-based guidelines for the management of hypertensive cardiogenic pulmonary edema. However, a review of the literature showed that there is evidence from the results of global clinical trials to support the development of formal guidelines for the management of hypertensive cardiogenic pulmonary edema.

Acknowledgments

The authors wish to acknowledge the assistance of Dr Díaz Lozada, attending physician of the Internal Medicine Program at San Juan City Hospital, in the diagnosis, guidance of management and the preparation of the manuscript for this case report.

Conflict of interest

None.

References:

1. Bajwa SS, Kulshrestha A: Diagnosis, prevention and management of post-operative pulmonary edema. *Ann Med Health Sci Res*, 2012; 2(2): 180–85
2. Roger VL: Epidemiology of heart failure. *Circ Res*, 2013; 113: 646–59
3. Blecker S, Paul M, Taksler G et al: Heart failure associated hospitalizations in the United States. *J Am Coll Cardiol*, 2013; 61(12): 1259–67
4. Fonarow GC, Heywood JT, Heidenreich PA et al: ADHERE Scientific Advisory Committee and Investigators. Temporal trends in clinical characteristics, treatments, and outcomes for heart failure hospitalizations. *Am Heart J*, 2007; 153(6): 1021–28
5. Domino FJ, Baldor RA: The 5-minute clinical consult. Philadelphia, PA, Wolters Kluwer Health/Lippincott Williams & Wilkins, 2013; 1098
6. Fromm RE Jr, Varon J, Gibbs LR: Congestive heart failure and pulmonary edema for the emergency physician. *J Emerg Med*, 1995; 13(1): 71–87
7. Marcinkiewicz M, Ponikwicka K, Szpakowicz A et al: Cardiogenic pulmonary oedema: Alarmingly poor long-term prognosis. Analysis of risk factors. *Kardiologia Pol*, 2013; 71(7): 712–20
8. Joseph SM, Cedars AM, Ewald GA et al: Acute decompensated heart failure contemporary medical management. *Tex Heart Inst J*, 2009; 36(6): 510–20
9. Scallan J, Huxley VH, Korhuis RJ: Capillary fluid exchange: regulation, functions, and pathology. In: *Integrated systems physiology: From molecule to function to disease*. San Rafael (CA): Morgan & Claypool Life Sciences, 2010
10. Ganeshpuri SP, Vaidya GN, Gattani V: Secondary pulmonary hypertension and right-sided heart failure at presentation in Grave's disease. *Case Rep Endocrinol*, 2012; 2012: 762023
11. Sussman JB, de Soto M, Torbati D: Plasma colloid osmotic pressure in healthy infants. *Crit Care*, 2001; 5(5): 261–64
12. Chaudhry SI, Wang Y, Concato J et al: Patterns of weight change preceding hospitalization for heart failure. *Circulation*, 2007; 116(14): 1549–54
13. Dao Q, Krishnaswamy P, Kazanegra R et al: Utility of B-type natriuretic peptide in the diagnosis of congestive heart failure in an urgent-care setting. *J Am Coll Cardiol*, 2001; 37(2): 379–85
14. Vincent JL: Understanding cardiac output. *Crit Care*, 2008; 12(4): 174
15. Young DB: Control of cardiac output. In: *Integrated systems physiology: From molecule to function to disease*. San Rafael (CA): Morgan & Claypool Life Sciences, 2010
16. Pourmoghaddas M, Sanei H, Tavassoli A, Shojaei M: Estimation of left ventricular end diastolic pressure (lvedp) in patients with ischemic heart disease by echocardiography and compare it with the results of cardiac catheterization. *ARYA Atheroscler*, 2011; 7(1): 1–6
17. Goodman L, Gilman A, Brunton L et al: *Goodman & Gilman's the pharmacological basis of therapeutics*. 12th ed. New York: McGraw-Hill, 2016
18. Nitroglycerin in 5% Dextrose Injection (nitroglycerin) [prescribing information]. Deerfield, IL: Baxter International Inc. August, 2016
19. Beltrame JF, Zeitz CJ, Unger SA et al: Nitrate therapy is an alternative to furosemide/morphine therapy in the management of acute cardiogenic pulmonary edema. *J Card Fail*, 1998; 4: 271–79
20. Nelson GI, Silke B, Ahuja RC et al: Haemodynamic advantages of isosorbide dinitrate over furosemide in acute heart failure following myocardial infarction. *Lancet*, 1983; 1(8327): 730–33
21. Haber HL, Simek CL, Bergin JD et al: Bolus intravenous nitroglycerin predominantly reduces afterload in patients with severe congestive heart failure. *J Am Coll Cardiol*, 1993; 22: 251–57
22. Imhof PR, Ott B, Frankhauser P et al: Differences in nitroglycerin dose response in venous and arterial beds. *Eur J Clin Pharmacol*, 1980; 18: 455–60
23. Cotter G, Metzker E, Kaluski E et al: Randomized trial high-dose isosorbide dinitrate plus low-dose furosemide vs. high-dose furosemide plus low-dose isosorbide dinitrate in severe pulmonary oedema. *Lancet*, 1998; 351: 389–93
24. James PA, Oparil S, Carter BL et al: 2014 evidence-based guideline for the management of high blood pressure in adults: Report from the Panel Members Appointment to the Eight Joint National Committee (LNC 8). *JAMA*, 2014; 311(5): 507–20
25. Lasix (furosemide) [prescribing information]. Bridgewater, NJ: Sanofi-Aventis US. March, 2016
26. Baird A: Acute pulmonary oedema – management in general practice. *Aust Fam Physician*, 2010; 39(12): 910–14
27. Felker GM, Lee KL, Bull DA et al: NHLBI Heart Failure Clinical Research Network Diuretic strategies in patients with acute decompensated heart failure. *N Engl J Med*, 2011; 364(9): 797–805
28. Figueras J, Weil MH: Blood volume prior to and following treatment of acute cardiogenic pulmonary edema. *Circulation*, 1978; 57(2): 349–55
29. Lal S, Murtagh JG, Pollock AM et al: Acute haemodynamic effect of furosemide in patients with normal and raised left atrial pressures. *Br Heart J*, 1969; 31: 711–17
30. Mond H, Hunt D, Sloman G: Haemodynamic effect of furosemide in patient suspected of having acute myocardial infarction. *Br Heart J*, 1974; 36: 44–53
31. Glare PA, Walsh TD: Clinical pharmacokinetics of morphine. *Ther Drug Monit*, 1991; 13(1): 1–23
32. Bosomworth J: Rural treatment of acute cardiogenic pulmonary edema: Applying the evidence to achieve success with failure. *Can J Rural Med*, 2008; 13(3): 121–28
33. McMurray JJ, Adamopoulos S, Anker SD et al: Task Force for the Diagnosis and Treatment of Acute and Chronic Heart Failure 2012 of the European Society of Cardiology. ESC Committee for Practice Guidelines ESC guidelines for the diagnosis and treatment of acute and chronic heart failure 2012: The Task Force for the Diagnosis and Treatment of Acute and Chronic Heart Failure 2012 of the European Society of Cardiology. Developed in collaboration with the Heart Failure Association (HFA) of the ESC. *Eur J Heart Fail*, 2012; 14: 803–69
34. Sacchetti A, Ramoska E, Moakes ME et al: Effect of ED management on ICU use in acute pulmonary edema. *Am J Emerg Med*, 1999; 17: 571–74
35. Hoffman JR, Reynolds S: Comparison of nitroglycerin, morphine and furosemide in treatment of presumed pre-hospital pulmonary edema. *Chest*, 1988; 92: 586–93
36. Erdős EG: The ACE and I: How ACE inhibitors came to be. *FASEB J*, 2006; 20: 1034–38
37. Tabacova SA, Kimmel CA: Enalapril: Pharmacokinetic/dynamic inferences for comparative developmental toxicity. A review. *Reprod Toxicol*, 2001; 15(5): 467–78.
38. Enalaprilat (prescribing information). Sellersville, PA: Teva Pharmaceuticals. October, 2011
39. Tohmo H, Karanko M, Korpilahti K: Haemodynamic effects of enalaprilat and preload in acute severe heart failure complicating myocardial infarction. *Eur Heart J*, 1994; 15: 523–27
40. Southall JC, Bissell DM, Burton JH et al: ACE inhibitors in acutely decompensated congestive heart failure. *Acad Emerg Med*, 2004; 11: 503
41. Clarkson PB, Wheelon NM, Macleod C et al: TM Brain natriuretic peptide: Effect on left ventricular filling patterns in healthy subjects. *Clin Sci*, 1995; 88: 159–64
42. Publication Committee for the VMAC Investigators (Vasodilatation in the Management of Acute CCF). Intravenous nesiritide vs. nitroglycerin for treatment of decompensated congestive heart failure: A randomized controlled trial. *JAMA*, 2002; 287(12): 1531–40
43. Elkayam U, Akhter MW, Singh H et al: Comparison of effects of left ventricular filling pressure of intravenous nesiritide and high-dose nitroglycerin in patients with decompensated heart failure. *Am J Cardiol*, 2004; 93: 237–40
44. Sackner-Bernstein JD, Skopicki HA, Aaronson KD: Risk of worsening renal function with nesiritide in patients with acutely decompensated heart failure. *Circulation*, 2005; 111: 1487–91
45. Natrecor (nesiritide) [prescribing information]. Titusville, NJ: Scios LLC. November, 2013
46. Beasley R, Chien J, Douglas J et al: Thoracic Society of Australia and New Zealand oxygen guidelines for acute oxygen use in adults: 'Swimming between the flags'. *Respirology*, 2015; 20(8): 1182–91
47. Sjöberg F, Singer M: The medical use of oxygen: A time for critical reappraisal. *J Intern Med*, 2013; 274(6): 505–28
48. Ho KM, Wong K: A comparison of continuous and bi-level positive airway pressure non-invasive ventilation in patients with acute cardiogenic pulmonary oedema: A meta-analysis. *Crit Care*, 2006; 10(2): R49
49. Mehta S, Jay GD, Woolard RH: Randomized, prospective of bilevel versus continuous positive airway pressure in acute pulmonary edema. *Crit Care Med*, 1997; 25(4): 620–28
50. Kraus PA, Lipman J, Becker PJ: Acute preload effect of furosemide. *Chest*, 1990; 98: 124–28