

From Open to Robotic-assisted Latissimus Dorsi Muscle Flap Harvest

Alessandro Fouarge, MD
Nicolas Cuyllits, MD

Background: The latissimus dorsi muscle is the largest muscle in the body. The classic open flap harvest technique of this muscle results in a long posterolateral thoracic vertical oblique incision that can leave an unappealing scar. The minimally invasive robotic approach has the potential to reduce scar length and to overcome technical limitations of endoscopic techniques.

Methods: Six robotically assisted latissimus dorsi muscle flaps were harvested by a single surgeon. One was used as reversed turnover pedicled flap based on lumbar perforators for lumbosacral bone coverage, another flap was transposed for a Poland syndrome anterior axillary line reconstruction, and the remaining 4 were dissected as free flaps for upper and lower limb reconstruction. All 6 procedures used a short 5-cm axillary crease incision along the posterior axillary fold and two 8-mm port incisions for robotic access.

Results: The first robotic flap harvest was converted to the classic open technique due to malposition of the 2 lower port incisions too close to the latissimus dorsi anterior border. The 5 other flaps were successfully transferred without flap or donor site complications. The average flap dissection time was 110 minutes; latter surgeries took less time than the early surgeries as the surgeon became more familiar with the robotic system and due to the use of a newer system.

Conclusion: Robotic-assisted latissimus dorsi muscle flap harvest is a safe, reproducible, and effective tool that offers precise dissection control and that leaves a minimal thoracic scar. (*Plast Reconstr Surg Glob Open* 2020;8:e2569; doi: [10.1097/GOX.0000000000002569](https://doi.org/10.1097/GOX.0000000000002569); Published online 20 January 2020.)

INTRODUCTION

Since Tansini's description in 1906,¹ the latissimus dorsi muscle flap (LDMF) technique has been used in breast, head and neck, thoracic, and limb reconstruction. Harvest of this muscle provides a large, relatively thin, well-vascularized, and possibly innervated muscle with a low donor site morbidity rate proportional to the size of the muscle harvested.^{2,3} LDMF is a workhorse in reconstructive surgery despite the advent of perforator fasciocutaneous flaps.

The traditional open approach leaves a long scar of at least 15 cm in the posterolateral thoracic region that often widens and becomes hypertrophic with time.⁴ To limit scarring, endoscopically assisted harvest of LDMF has been used in many centers for about 2 decades.⁵⁻⁸

Endoscopically assisted harvest is challenging, however. It is difficult to create a suitable optical cavity for tissue dissection around the thoracic curvature and to maneuver instruments.

The advent of the robotically assisted surgery has generated new interest in minimally invasive LDMF harvest. The robot system offers 3-dimensional images, 360-degree motion at the tip of the instruments, tremor filters, and the ability to lock ports at a high level to circumvent the thoracic curvature, while dissecting with comfort and precision. This major technological step forward has been reported by a few plastic surgery teams.^{9,10,11} Here, we share our personal experience with this safe, reproducible, and effective tool.

METHODS

Six LDMFs were harvested by a single surgeon between 2015 and 2019 assisted by the robotic Da Vinci Si or Xi systems (Intuitive Surgical, Sunnyvale, CA, USA). Written informed consent for the use of the data was

From the Plastic, Reconstructive and Aesthetic Surgery Department, Hôpital Erasme, Université Libre de Bruxelles, Brussels, Belgium.

Received for publication May 28, 2019; accepted October 16, 2019.

Copyright © 2020 The Authors. Published by Wolters Kluwer Health, Inc. on behalf of The American Society of Plastic Surgeons. This is an open-access article distributed under the terms of the [Creative Commons Attribution-Non Commercial-No Derivatives License 4.0 \(CCBY-NC-ND\)](https://creativecommons.org/licenses/by-nc-nd/4.0/), where it is permissible to download and share the work provided it is properly cited. The work cannot be changed in any way or used commercially without permission from the journal.

DOI: [10.1097/GOX.0000000000002569](https://doi.org/10.1097/GOX.0000000000002569)

Disclosure: The authors have no financial interest to declare in relation to the content of this article.

Related Digital Media are available in the full-text version of the article on www.PRSGlobalOpen.com.

obtained from all patients, and our institutional committee approved the procedures. One LDMF was used as reversed turnover pedicled flap based on lumbar perforators for lumbosacral bone coverage, another flap was transposed for a Poland syndrome anterior axillary line reconstruction, and the remaining 4 were dissected as free flaps for upper and lower limb reconstruction. All 6 procedures used a short 5-cm axillary crease incision along the posterior axillary fold, and 2 short incisions for robotic access. In each patient, the 2 short incisions were used for externalization of drains at the end of the procedure. The first 4 procedures were performed with the Da Vinci Si system. This system has several shortcomings, including robotic arm restrictions with limited multiple quadrant working range, the necessity to manually rotate the 30-degree angled optic when needed, and 2 different port diameters of 11 and 8 mm for the camera and the other instruments, respectively. The last 2 procedures used the newer Da Vinci Xi system with all instruments fitted for 8-mm ports, automatic optic rotation, and little arm collision when performing multi-quadrant surgery.

Surgical Technique

Patient Positioning and Preoperative Landmarks

Using the same routine as performed for the classic open technique, the anterior border of the latissimus dorsi (LD) muscle was marked with the patient in an upright position during active contraction with hands pushing downwards on the hips. The tip of the scapula, the posterior midline, and the iliac crest were marked after positioning the patient in lateral decubitus with the ipsilateral arm placed on a leg holder and using a contralateral axillary gel to prevent brachial plexus compression.

Incisions and Port Placement

A 5-cm line was drawn in the axilla along the posterior axillary fold. In breast reconstruction, the axillary lymph node clearance scar can be used as well. The first port was placed at the inferior aspect of the incision after airtight closure. The second port entry point was then marked 8–10 cm caudal to the inferior edge of the axillary scar and 8–10 cm anterior to the lateral LD border. The third port was positioned 8–10 cm caudal to the second port and 10–20 cm anterior to the anterior LD border (Fig. 1). It is important to preserve enough space between the anterior border of the LD and the ports to allow robotic arm maneuverability with comfortable access for subcutaneous dissection above the LD.

The axillary incision was performed under direct vision with a light retractor, resulting in a 10- to 20-cm wide subcutaneous space, superficial to the serratus fascia and anterior to the LD. This created a confluent working space for further port placement and robotic dissection. The deep aspect of the LD was undermined as far as possible to shorten the first step of the robotic dissection. To provide a suitable optical window, the subcutaneous plane above the LD was kept intact until the submuscular dissection was complete to avoid a secondary muscle shift toward the chest wall upon insufflation

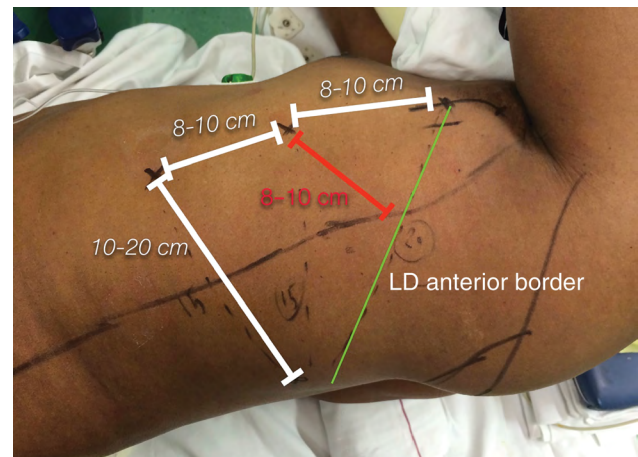


Fig. 1. A 5-cm line was drawn in the axilla along the posterior axillary fold. The first port was placed at the inferior aspect of the incision. The second port entry point was 8–10 cm caudal to the inferior edge of the axillary scar and 8–10 cm anterior to the lateral LD border. The third port was positioned again 8–10 cm caudal to the second port and 10–20 cm anterior to the anterior LD border.

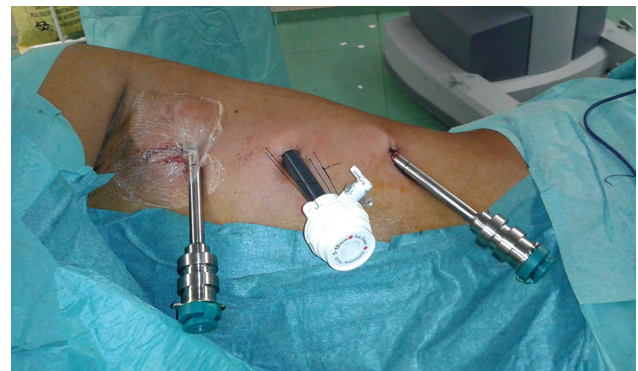

Fig. 2. The first port was placed at the inferior aspect of the axillary incision. A 1-cm incision was performed at the second port marking, and a 12-mm port was blindly inserted with a finger protecting the chest wall through the axillary incision. The 30-degree endoscope was then placed through the second port, and the third 8-mm port was introduced through a 5-mm incision under endoscopic vision.

An 8-mm incision was performed at the second port mark, and an 11-mm port was blindly inserted with a finger protecting the chest wall through the axillary incision. The 30-degree endoscope was then placed through the second port, and the third 8-mm port was introduced through a 5-mm incision under endoscopic vision (Fig. 2). Finally, the axillary incision was closed around an 8-mm port. The 3 ports were made airtight using either a purse-string suture or a Tegaderm (3M, Saint Paul, MN, USA).

Robotic Docking and Dissection

The robot was positioned posterior to the patient with the arms extended over the thorax. In this position, the instruments are aligned with the LD muscle plane facilitating access for the surgical assistant. After docking of the ports, the insufflation was calibrated on 20 mm Hg.

The robotic dissection began at the submuscular plane, taking advantage of the CO₂ pressure inside the cavity to

create an optical window. A 30-degree endoscope, a Cadiere forceps, and monopolar scissors were used. Electrocautery was avoided as the smoke can slow the dissection, and bipolar forceps were used for sectioning of large vessels. Next, after rotating the 30-degree endoscope upward for better visualization of the anterior border of the LD, the subcutaneous plane above the muscle was dissected. The endoscope was then inverted downward to enable further dissection of the surface of the muscle while circumventing the thoracic curvature (Fig. 3). Finally, the inferoposterior muscle borders were incised at the desired size with monopolar scissors, and hemostasis was verified.

Undocking and Extraction of the Muscle

After the muscle was released at the inferoposterior borders and from the tip of the scapula, the robot was undocked, and the axillary incision was reopened to perform both the pedicle dissection and the tendon release under direct vision (Fig. 4). Two suction drains were then placed in the donor site through the 2 lower incisions.

RESULTS

Here, we report harvest of LDMFs from 6 patients by a single surgeon. One was used as reversed turnover pedicled flap based on lumbar perforators for sacral bone coverage after giant cell tumor excision, another flap was transposed for a Poland syndrome anterior axillary line reconstruction, and the remaining 4 were dissected as free flaps for upper and lower limb reconstruction. The first robotic flap harvest was converted to the classic open technique due to malposition of the 2 lower incisions. As the port incisions were too close to the anterior border of the LD, instrument maneuverability was reduced to a narrow optical window that made robotically assisted surgery not feasible. In the remaining 5 procedures, a 5-cm axillary crease incision was made along the posterior axillary fold, and 2 short incisions allowed robotic access (Fig. 5). In the 5 patients, average flap dissection time was 110 minutes, from axillary incision to completion of pedicle dissection. With each surgery, time was reduced as the surgeon

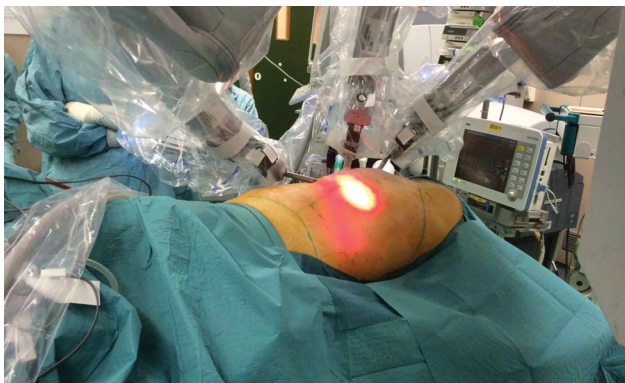


Fig. 3. The robot was positioned posterior to the patient with arms extended over the thorax. In this position, the instruments are aligned with the LD muscle plane facilitating access for the surgical assistant. Transillumination was used to assess the extension of the subcutaneous dissection.

became more familiar with both the robot installation and the endoscopic dissection and as the newer Da Vinci Xi system was used for the last 2 surgeries.

No postoperative complications were reported in the 6 patients who underwent robotically assisted LDMF surgery with regard to donor sites and flaps. Ranges of motion and shoulder strength were not systematically assessed postoperatively but patients did not report any complaints. Postoperative analgesia requirements were moderate. Patients were discharged at the fifth postoperative day with 1 drain at the donor site that was removed within 2 weeks of the operation when less than 30 mL of fluid was produced per day. No seromas were observed, and no quilting sutures were performed.

DISCUSSION

The LDMF remains a workhorse in plastic surgery despite the advent of perforator fasciocutaneous flaps. Nevertheless, the current trend for minimally invasive procedures has raised patient expectations regarding the donor site morbidity and cosmetic outcomes.

Robotically assisted plastic surgery is currently limited to pure muscular flap harvest and by the capacity to obtain a suitable optical window for multi-quadrant dissection. For other types of flaps, skin paddles or fasciocutaneous flaps result in scar lengths that do not justify the cost and time involved in the use of a robotic system. In addition to flap harvest, robotically assisted quadrantectomies and nipple-sparing mastectomies continue to push the boundaries of minimally invasive approaches in plastic surgery.^{11,12}

In the open LDMF harvest approach, the incision has to provide surgical access from the axilla for pedicle dissection and tendon section and to the lower back for caudal muscle release. Depending on muscle size requirements, an unsightly incision of up to 40 cm might be needed. During the 1990s, endoscopic techniques were developed for this surgery, but technical issues limited the enthusiasm of many surgeons.⁶ The creation of a suitable optical cavity for tissue dissection around the thoracic curvature with poorly maneuverable instruments was a limitation that was not resolved until the advent of robotic surgery.

The robotic approach circumvents the endoscopic technical limitations in many ways. The high-definition and 3-dimensional optic provides a superior image rendering for highly accurate dissection. The 360-degree tip motion of the instruments enables precise dissection around the thoracic curvature of tissues that are not in the direct axis of the instrument shafts with enhanced precision, tremor elimination, and motion scaling. Finally, the ports docked in the robotic arms can be elevated and kept steady at a given position both to circumvent the chest wall curvature and to tent the skin with significant improvement of the optical window.

Robotically assisted LDMF harvest does have limitations, however. The pedicle dissection is currently restricted by the port disposition. As described, there was suitable triangulation and optic window for dissection of the flap but not when directed cranially toward the pedicle. The new Da Vinci Xi addresses many of the shortcomings of its predecessor Si, specifically regarding robotic arm restrictions

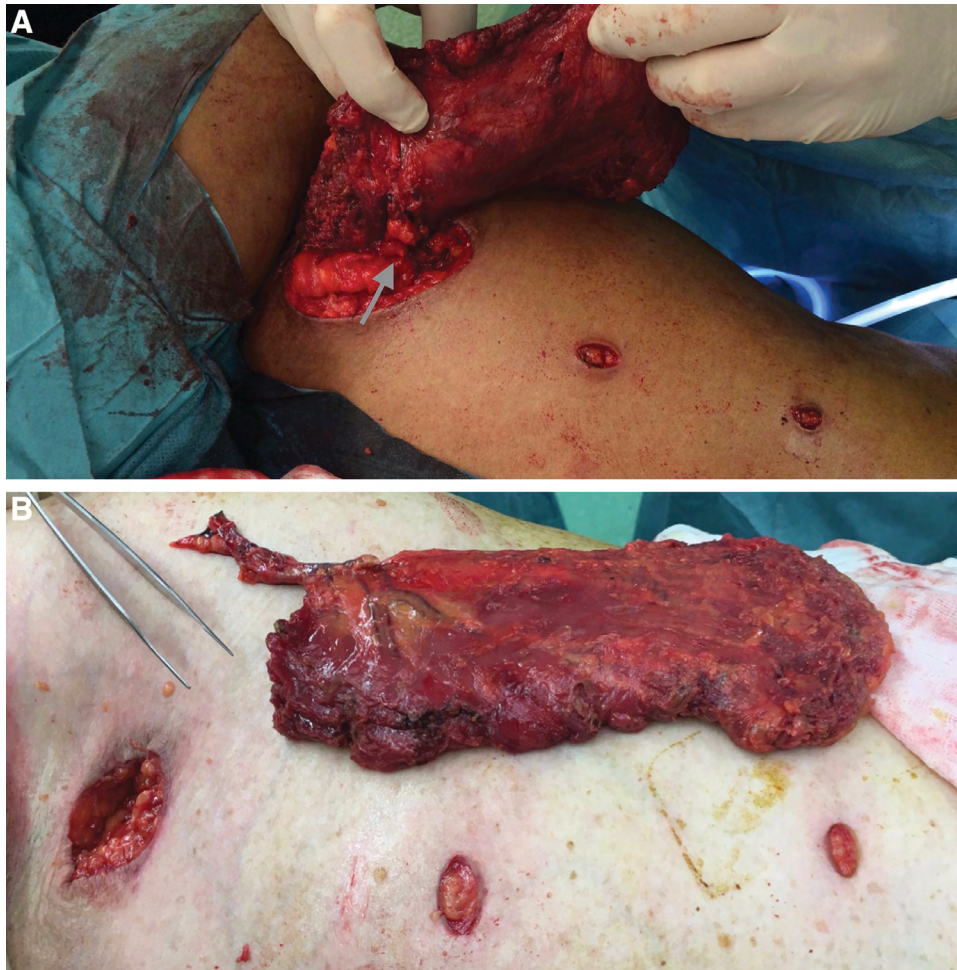

Fig. 4. After the muscle was released from the inferoposterior borders and from the tip of the scapula, the robot was undocked, and the axillary incision was reopened to enable pedicle dissection and the tendon release under direct vision. A, Pedicle is indicated with the gray arrow. B, LDMF after pedicle and tendon release.

and those related to the difficulty working in multiple quadrants, but even with the Xi, LD pedicle dissection cannot be performed due to the lack of triangulation when directed cranially toward the axilla. Nevertheless, the Da Vinci Xi provides standardized 8-mm ports for all instruments, and the camera fits in each port and has the ability to automatically rotate while circumventing the thorax curvature. We performed 2 LDMFs with the Xi, and these new features simplified the dissections and decreased time of surgery. (See Video [online], which displays that Da Vinci Xi has the ability to automatically rotate to ease the circumvention of the thorax curvature and solve instruments' conflicts within the optical window. It simplified the dissections and decreased time of surgery.)

Pedicle dissection described in the literature has been done under direct vision through the axillary incision before the robotic dissection or after when reopening the axilla.⁹⁻¹¹ We recommend that the pedicle be untouched until the end of the endoscopic procedure to avoid accidental trauma to the vessels by instruments moving in the axillary port.

The surgical technique we used for robotically assisted LDMF was based on that reported by Selber et al with very few modifications.⁹ The creation of a confluent subcutaneous working space anterior to the anterior border of the LD is key to preserving optimal robotic arm maneuverability while dissecting in the submuscular and subcutaneous spaces. Therefore, we placed the 2 inferior ports further away from the anterior border at 8–10 cm for the upper one and 10–20 cm for the lower one than the 7–8 cm reported by Selber et al for both lower ports. Chung et al described technical limitations when dissecting the anterior LD border when the 2 inferior ports were placed at 3–5 cm from the anterior muscle border; this necessitated that another incision be placed at the tip of the scapula to overcome arm overlap.¹³ With our configuration, we did not encounter issues with the chest wall convexity, and the LD subcutaneous space was easily accessible even after passive advancement secondary to the submuscular release without need for supplementary incisions. Compared to the majority of robotic procedures that are performed on small surgical targets with a concentric direction of the

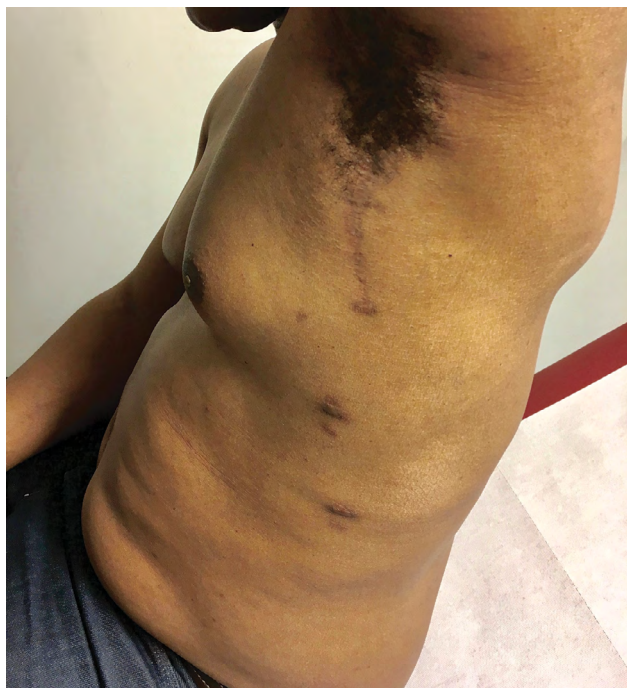

Fig. 5. Postoperative scars from the 5-cm axillary crease incision along the posterior axillary fold and from the two 1-cm incisions used for robotic access.

instruments, raising the LDMF is a multi-quadrant surgery. It requires large amplitude movements from the robotic arms that are facilitated by a greater distance between the entry sites.

Chung et al described a gasless technique using an articulated long retractor through the axillary incision to avoid hypercapnia, respiratory acidosis, tachycardia, subcutaneous emphysema, and air embolism that are potential complications secondary to CO₂ gas inflation.^{13,14} However, despite the use of insufflation, none of these drawbacks occurred during our procedures.

Finally, it is important to mention that the robotically assisted LDMF harvest is an expensive and time-consuming option, and these costs must be balanced with the cosmetic benefits. Compared to the open approach, the benefits of robotic dissection are mainly cosmetic with a significant back scar length reduction from up to 40 cm to a 5-cm scar hidden high in the axilla. The 2 additional port scars are inconspicuous and are similar to those related to drains in the open technique. The newly announced Da Vinci Sp (Intuitive Surgical), which has a single port, will further reduce the scar length to a single 2.4-cm incision and will facilitate multi-quadrant dissection for harvest of other muscle flaps. In the future in analysis of a larger cohort, a subjective study based on the psychometric Likert scale would enable to assessment of the patient perspectives and preferences on type of scars that are acceptable.

CONCLUSION

Robotic-assisted LDMF harvest is a safe, reproducible, and effective tool to overcome the laparoscopic limitations and to considerably reduce the length of the thoracic scar.

Alessandro Fouarge, MD

Plastic, Reconstructive and Aesthetic Surgery Department
Hôpital Erasme
Université Libre de Bruxelles
808 route de Lennik
1070 Brussels, Belgium
E-mail: alessandrofouarge@gmail.com

REFERENCES

1. Tansini I. Sopra il mio nuovo processo di amputazione della mammella. *Gazz Med Ital.* 1906;67:141–142
2. Lee KT, Mun GH. A systematic review of functional donor-site morbidity after latissimus dorsi muscle transfer. *Plast Reconstr Surg.* 2014;134:303–314.
3. Lee KT, Lee YJ, Kim A, et al. Evaluation of donor morbidity following single-stage latissimus dorsi neuromuscular transfer for facial reanimation. *Plast Reconstr Surg.* 2019;143:152e–164e.
4. Moore TS, Farrell LD. Latissimus dorsi myocutaneous flap for breast reconstruction: long-term results. *Plast Reconstr Surg.* 1992;89:666–72; discussion 673.
5. Pomel C, Missana MC, Lasser P. [Endoscopic harvesting of the latissimus dorsi flap in breast reconstructive surgery. Feasibility study and review of the literature]. *Ann Chir.* 2002;127:337–342.
6. Lin CH, Wei FC, Levin LS, et al. Donor-site morbidity comparison between endoscopically assisted and traditional harvest of free latissimus dorsi muscle flap. *Plast Reconstr Surg.* 1999;104:1070–7; quiz 1078.
7. Fine NA, Orgill DP, Pribaz JJ. Early clinical experience in endoscopic-assisted muscle flap harvest. *Ann Plast Surg.* 1994;33:465–9; discussion 469.
8. Ramakrishnan VV, Southern S, Villafane O. Endoscopic harvest of the latissimus dorsi muscle using the balloon dissection technique. *Plast Reconstr Surg.* 1997;99:899–903; discussion 904–905.
9. Selber JC, Baumann DP, Holsinger FC. Robotic latissimus dorsi muscle harvest: a case series. *Plast Reconstr Surg.* 2012;129:1305–1312.
10. Clemens MW, Kronowitz S, Selber JC. Robotic-assisted latissimus dorsi harvest in delayed-immediate breast reconstruction. *Semin Plast Surg.* 2014;28:20–25.
11. Lai HW, Chen ST, Lin SL, et al. Technique for single axillary incision robotic assisted quadrantectomy and immediate partial breast reconstruction with robotic latissimus dorsi flap harvest for breast cancer: a case report. *Medicine (Baltimore).* 2018;97:e11373.
12. Toesca A, Peradze N, Galimberti V, et al. Robotic nipple-sparing mastectomy and immediate breast reconstruction with implant: first report of surgical technique. *Ann Surg.* 2017;266:e28–e30.
13. Chung JH, You HJ, Kim HS, et al. A novel technique for robot assisted latissimus dorsi flap harvest. *J Plast Reconstr Aesthet Surg.* 2015;68:966–972.
14. Daskalakis M, Scheffel O, Weiner RA. High flow insufflation for the maintenance of the pneumoperitoneum during bariatric surgery. *Obes Facts.* 2009;2:37–40.