

## Scientific Report

# Vulvar and vestibulovaginal hemangiosarcoma in a cow: morphological and histopathological observations

Stephan, F.<sup>1\*\*</sup>; Sharun, K.<sup>2\*, \*\*</sup>; Varghese, E.<sup>3</sup>; Hamza, P.<sup>4</sup>  
and George, A. J.<sup>4</sup>

<sup>1</sup>MVSc Student in Livestock Production and Management, Livestock Production and Management Section, ICAR-Indian Veterinary Research Institute, Izatnagar, Bareilly, Uttar Pradesh, India; <sup>2</sup>Division of Surgery, ICAR-Indian Veterinary Research Institute, Izatnagar, Bareilly, Uttar Pradesh, India; <sup>3</sup>MVSc Student in Veterinary Pathology, Department of Veterinary Pathology, College of Veterinary and Animal Sciences, Pookode, Kerala Veterinary and Animal Sciences University, Wayanad, Kerala, India; <sup>4</sup>Department of Veterinary Pathology, College of Veterinary and Animal Sciences, Pookode, Kerala Veterinary and Animal Sciences University, Wayanad, Kerala, India

\*Correspondence: K. Sharun, Division of Surgery, ICAR-Indian Veterinary Research Institute, Izatnagar, Bareilly, Uttar Pradesh, India. E-mail: sharunkhansk@gmail.com

\*\* These authors contributed equally to this work and were considered as the first authors

 10.22099/IJVR.2022.43412.6343

(Received 1 Apr 2022; revised version 27 Aug 2022; accepted 10 Oct 2022)

This is an open access article under the CC BY-NC-ND license (<http://creativecommons.org/licenses/by-nc-nd/4.0/>)

## Abstract

**Background:** Hemangiosarcoma is defined as the malignant mesenchymal neoplasm of endothelial cells. It is a common tumor affecting dogs and is very rare in cattle. **Case description:** A seven-year-old three months pregnant female Holstein Friesian cross-breed cow was presented with a history of a proliferating irregular dark red friable mass in the vulvar region for the past month. **Findings/treatment and outcome:** The surface of the mass had diffuse ecchymotic hemorrhages. Histopathological examination of the tissue biopsy specimen revealed unencapsulated, infiltrating neoplasm composed of numerous vascular channels with irregular borders surrounded by endothelial cells of variable sizes and shapes supported by a scanty fibrovascular stroma. Based on morphological and histopathological findings, the case was diagnosed as vulvar and vestibulovaginal hemangiosarcoma. The animal was culled due to the poor prognosis. **Conclusion:** To the best of our knowledge, this is the first report of vulvar and vestibulovaginal hemangiosarcoma in a cow.

**Key words:** Blood vascular tumor, Cattle, Hemangiosarcoma, Histopathology, Vaginal tumor

## Introduction

Bovine neoplasms are commonly located in the skin and soft tissues and include fibroma, fibropapilloma, melanoma, and squamous cell carcinoma (Vermunt and Thompson, 2001; Mathewos *et al.*, 2021). Vascular tumors, hemangiosarcoma or hemangioma, are relatively uncommon in cattle (Warren and Summers, 2007). Hemangiosarcoma, also known as hemangio-endothelioma or angiosarcoma, is a malignant tumor of endothelial cells that most commonly affects dogs (Vermunt and Thompson, 2001; Yamamoto *et al.*, 2013; Sharun *et al.*, 2019). It is less common in goats, sheep, horses, pigs, and cattle (Schultheiss, 2004). Since hemangiosarcoma emerges from vascular endothelium, it may primarily occur in any tissue or organ (Cohen *et al.*, 2009). However, the spleen, lungs, heart, and liver are the most commonly affected organs in dogs (Kim *et al.*, 2015).

Several cases of hemangiosarcoma have been

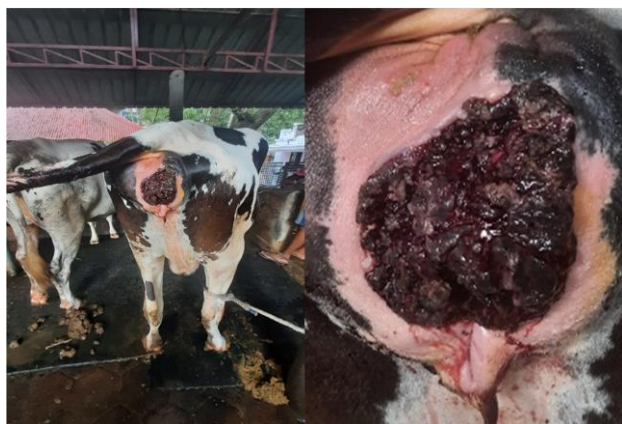reported in cattle. These cases include hemangiosarcoma in the peritoneal cavity (Gholami *et al.*, 1992), lungs (Zachary *et al.*, 1981; Gholami *et al.*, 1992; Poulsen *et al.*, 2008), pleura (Poulsen *et al.*, 2008), neck muscle (Sutton and McLennan, 1982; Vermunt and Thompson, 2001), biceps femoris muscle (Vogel *et al.*, 2012), external naris (Queen *et al.*, 1992), gingiva (Azizi *et al.*, 2017), metatarsus (Guard and Wilkinson, 1984), mandible (Poulsen *et al.*, 2008), brain (Sutton and McLennan, 1982), extradural spinal cord (Sutton and McLennan, 1982), thoracic vertebral body (Zachary *et al.*, 1981), subcutaneous tissue (Poulsen *et al.*, 2008), skin (Urdaz *et al.*, 2001), uterus (Kübar and Jalakas, 2002), liver (Stock *et al.*, 2011), spleen (Stock *et al.*, 2011), urinary bladder (Braun *et al.*, 2009), tricuspid valve (Castagnaro *et al.*, 1996), and congenital multifocal hemangiosarcoma (stillborn calf) (Badylak, 1983).

The present paper reports a rare case of vulvar and vestibulovaginal hemangiosarcoma in a pregnant

Holstein Friesian cross-breed cow and its morphological and histopathological findings.

### Case description

All procedures performed are in accordance with the ethical standards of the institution at which the studies were conducted. A seven-year-old, three months pregnant Holstein Friesian cross-breed cow was presented with a history of a large tumor mass protruding through the vulva for the past month (Fig. 1). The tumor mass was friable on the exposed side and firm towards the inner aspect. It was dark red and had an irregular surface with diffuse ecchymotic hemorrhages. In addition, the vulva and perineum appeared enlarged and prominent. The owner reported that the tumorous growth was initially observed as a small wound in the vulva that later transformed to a larger mass. The feeding history, temperature, respiration rate, pulse rate, and mucous membranes of the animal were normal at presentation. However, the vestibular and vaginal lumen was found to be narrow during the digital examination due to the large tumorous mass compressing the vaginal wall.



**Fig. 1:** Large dark red irregular solid mass protruding from the vulva of a pregnant Holstein Friesian cross-breed cow

The tumor mass was cleaned with potassium permanganate solution (1:10000) to remove all debris and dung particles. On physical examination, the tumor mass was friable to touch with irregular surfaces and some necrotic areas. Pervaginal examination confirmed that the tumor mass was limited to the vagina and not progressing towards the cervix. Biopsy samples were collected from different mass portions and submitted to the Department of Veterinary Pathology, College of Veterinary and Animal Sciences, Pookode, Kerala Veterinary and Animal Sciences University, Kerala, India, for histopathological examination. The tissue samples were fixed in 10% neutral buffered formalin, routinely processed for histopathology, and stained using hematoxylin and eosin. In addition, the animal was treated with a long-acting antibiotic enrofloxacin 10% w/v at the dose rate of 7.5 mg/kg body weight (BW) along with anti-inflammatory drug meloxicam and anti-histaminic drug chlorpheniramine maleate at the dose

rate of 0.5 mg/kg BW as intramuscular injections.

### Histopathological findings and outcome

Histopathology revealed a non-capsulated highly cellular neoplasm composed of numerous blood-filled vascular spaces (Fig. 2a) with irregular borders surrounded by infiltrating neoplastic cells forming nests and cords supported by a thin collagenous stroma. The vascular channels were lined by ovoid to spindle-shaped endothelial cells of varying sizes with abundant eosinophilic cytoplasm (Figs. 2b-d). Marked anisocytosis and anisokaryosis of neoplastic cells were evident with a round to ovoid-shaped, hyperchromatic nuclei with coarsely stippled chromatin and multiple prominent nucleoli (Fig. 2e). Mitotic figures were frequent, and occasionally, binucleated cells were also seen (Fig. 2f). The mitotic index was 9 per 10 high power fields. The lumen between the vascular channels showed infiltration of inflammatory cells such as plasma cells, lymphocytes, and a few hemosiderophages in addition to the neoplastic cells. The histopathological findings confirmed the tumor as hemangiosarcoma. Although surgical correction was recommended to the animal owner, the animal was culled due to the poor prognosis.

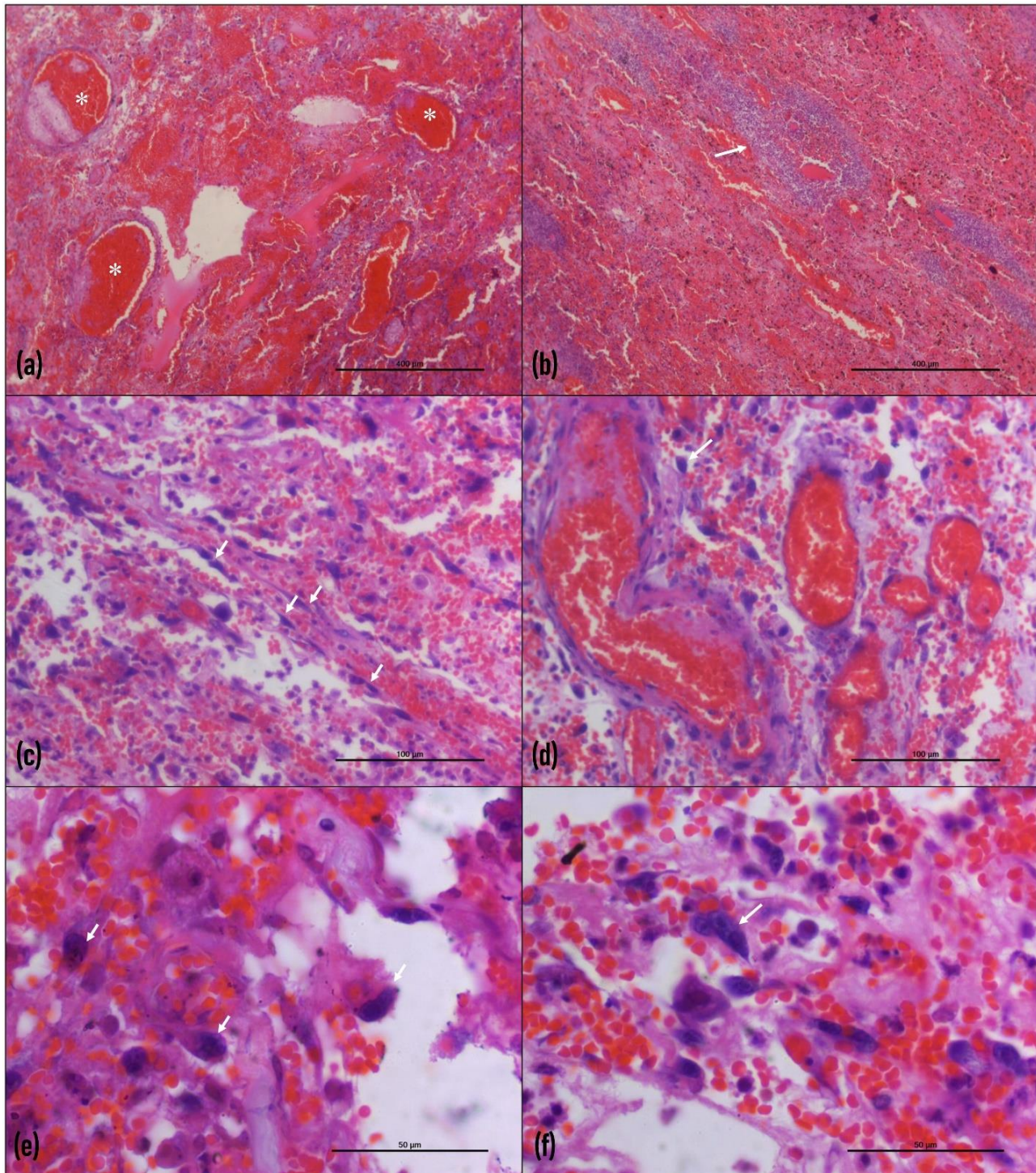
### Discussion

Hemangiosarcoma rarely affects the urogenital system in cattle. Only two cases of urogenital hemangiosarcoma are reported in cattle that affected the uterus and urinary bladder (Kübar and Jalakas, 2002; Braun *et al.*, 2009). The hemangiosarcoma in the uterine blood vessels was diagnosed when the Estonian Holstein breed cow was culled due to infertility (Kübar and Jalakas, 2002). Similarly, hemangiosarcoma of the urinary bladder was diagnosed in a Swiss Braunvieh cow presented with severe hematuria (Braun *et al.*, 2009). Cystoscopy identified a proliferating mass in the bladder wall (0.5 cm diameter) that was bleeding continuously. The cow was treated by performing thermocautery with the help of endoscopy. Unfortunately, even though the clinical signs got resolved post-treatment, the animal was slaughtered 15 months later because of infertility (Braun *et al.*, 2009). In the present case, vulvar and vestibulovaginal hemangiosarcoma was diagnosed when the cow was three months pregnant.

Among the hemangiosarcoma cases reported in cattle, only a few have been documented in old age animals. For example, disseminated hemangiosarcoma was reported in a 9-year-old Brown Swiss cow with liver and spleen involvement (Stock *et al.*, 2011). In the present case, hemangiosarcoma is diagnosed in a seven-year-old pregnant Holstein Friesian cross-breed cow. Similarly, hemangiosarcoma in young animals is rare (Badylak, 1983; Azizi *et al.*, 2017). However, a unique case of congenital multifocal hemangiosarcoma was documented in a stillborn female Hereford calf (Badylak, 1983). Lesions were found in multiple tissues involving the liver, lung, heart, kidney, spleen, skin, skeletal

muscle, bone, and mesentery. Although the congenital hemangiosarcoma resulted in the calf's death, the exact mechanism of the tumor formation is still unknown (Badylak, 1983). Furthermore, hemangiosarcoma is also reported in a 4-month-old Friesian bull calf and a 10-month-old Chianina-Angus steer involving neck

musculature and thoracic vertebral body, respectively (Zachary *et al.*, 1981; Vermunt and Thompson, 2001). Interestingly, the low incidence of hemangiosarcoma in dairy cattle can be attributed to the fact that most of them are culled before they reach an older age (Stock *et al.*, 2011).



**Fig. 2:** Histopathological findings of the tumor mass, hemangiosarcoma, in the vulva of cattle. (a) Numerous vascular channels with irregular borders containing RBCs (asterisks) (scale bar: 400  $\mu$ m,  $\times$ 10), (b) Islands of endothelial cells with hyperchromatic nuclei encircling the vascular channels (arrow) (scale bar: 400  $\mu$ m,  $\times$ 10), (c) Several proliferation of endothelial cells are observed (arrows) (scale bar: 100  $\mu$ m,  $\times$ 40), (d) Vascular channels are surrounded by proliferating mesenchymal cells (arrow) (scale bar: 100  $\mu$ m,  $\times$ 40), (e) Neoplastic cells are ovoid to spindle-shaped (arrows) with hyperchromatic nuclei and eosinophilic cytoplasm (scale bar: 50  $\mu$ m,  $\times$ 100), and (f) Some cells are binucleated (arrow) (scale bar: 50  $\mu$ m,  $\times$ 100)

Hemangiosarcoma is a tumor of vascular endothelium that mostly affects visceral organs (Batschinski *et al.*, 2018). However, they can originate from other primary sites since blood vessels are ubiquitous (Fosmire *et al.*, 2004; Vogel *et al.*, 2012; Chaikin and Welihozkiy, 2018). The histopathological findings, such as the presence of individual fusiform cells with basophilic cytoplasm and nuclei containing fine, granular chromatin and prominent nucleoli along with some binucleated cells, are suggestive of sarcoma (Vogel *et al.*, 2012). In addition, histopathologic features such as irregular vascular canals surrounded by polymorphic neoplastic endothelial cells are characteristics of hemangiosarcoma that helps to differentiate from vascular hamartomas (Azizi *et al.*, 2017). In this case, the presence of irregular blood-filled spaces surrounded by round, oval to spindle-shaped proliferation of endothelial cells suggests vascular origin and malignant nature, which is indicative of hemangiosarcoma. The presence of blood vessels of different sizes lined by polymorphic endothelial cells is considered evidence of malignancy (Azizi *et al.*, 2017).

Impression smears and fine-needle aspiration cytology (FNAC) have limited value in diagnosing hemangiosarcoma since blood cells are prominent in the prepared smears and neoplastic endothelial cells are difficult to identify (Sharma, 2012). Therefore, in live animals, excisional biopsy is generally recommended to collect diagnostic samples. Histopathology is commonly used for the definitive diagnosis of hemangiosarcoma since vascular disorders can be easily differentiated from each other based on histopathology alone (Sharma, 2012). However, immunohistochemical detection of CD31 and von Willebrand's factor antigen would further help confirm the histopathological findings (Ferrer *et al.*, 1995). In a study conducted by Ferrer *et al.* (1995), hemangiomas and hemangiosarcomas expressed CD31 antigen in all samples. However, 11 out of 15 (73.33%) hemangiosarcoma samples expressed von Willebrand's factor antigen compared to 100% hemangioma samples (Ferrer *et al.*, 1995). Therefore, the definitive diagnosis of hemangiosarcoma was based on histopathology in the present case, due to the lack of facilities to perform immunohistochemistry.

Vulvar and vestibulovaginal hemangiosarcoma has been previously reported in a German shepherd dog presented with intermittent vulvar hemorrhage (Hill *et al.*, 2000). The dog was treated by resecting the vulva and caudal vestibulovagina (vulvovaginectomy) along with neo-urethrostomy (Hill *et al.*, 2000). In the present case, intermittent vulvar bleeding was not observed even though pinpoint hemorrhages were present on the surface. Although a similar surgical approach could be performed in the present case, the owner advised culling as it is a production animal. In addition, surgical correction in large ruminants using vulvovaginectomy and neo-urethrostomy may result in post-surgical complications such as retrograde urethritis and urinary incontinence (Hill *et al.*, 2000).

Hemangiosarcoma of the vulva and vestibulovagina

is a rare condition. The present case was diagnosed as vulvar and vestibulovaginal hemangiosarcoma based on morphological and histopathological findings. To the best of our knowledge, this is the first report of vulvar and vestibulovaginal hemangiosarcoma in a cow. Furthermore, the incidence in a pregnant cow makes it more unique. This case report adds to the scarce data on the occurrence of hemangiosarcoma in cattle with atypical clinical presentation.

## Acknowledgements

The authors are thankful to their respective universities and institutes for the facilities provided. No substantial funding is to be stated.

## Conflict of interest

All authors declare that there exist no commercial or financial relationships that could, in any way, lead to a potential conflict of interest.

## References

- Azizi, S; Amirmohammadi, M; Kheirandish, R; Davoodian, Z and Goodarzi, M** (2017). Occurrence of haemangiosarcoma on the gingiva of a calf: a case report. *Bulg. J. Vet. Med.*, 20: 183-188.
- Badylak, SF** (1983). Congenital multifocal hemangiosarcoma in a stillborn calf. *Vet. Pathol.*, 20: 245-247.
- Batschinski, K; Nobre, A; Vargas-Mendez, E; Tedardi, MV; Cirillo, J; Cestari, G; Ubukata, R and Dagli, MLZ** (2018). Canine visceral hemangiosarcoma treated with surgery alone or surgery and doxorubicin: 37 cases (2005-2014). *Can. Vet. J.*, 59: 967-972.
- Braun, U; Tschuur, AC; Hilbe, M; Lange, CE and Schwarzwald, C** (2009). Ultrasonographic findings and treatment in a cow with a haemangiosarcoma of the urinary bladder. *Schweiz. Arch. Tierheilkd.*, 151: 490-494.
- Castagnaro, M; Guarda, F; Goi, R and Grandi, P** (1996). Primary hemangiosarcoma of the tricuspid valve in a cow. *Large Anim. Rev.*, 2: 5-8.
- Chaikin, P and Welihozkiy, A** (2018). Hemangiosarcoma in a dog: unusual presentation and increased survival using a complementary/holistic approach combined with metronomic chemotherapy. *Case Rep. Vet. Med.*, 2018: 6160980.
- Cohen, SM; Storer, RD; Criswell, KA; Doerrer, NG; Dellarco, VL; Pegg, DG; Wojcinski, ZW; Malarkey, DE; Jacobs, AC; Klaunig, JE; Swenberg, JA and Cook, JC** (2009). Hemangiosarcoma in rodents: mode-of-action evaluation and human relevance. *Toxicol. Sci.*, 111: 4-18.
- Ferrer, L; Fondevila, D; Rabanal, RM and Vilafranca M** (1995). Immunohistochemical detection of CD31 antigen in normal and neoplastic canine endothelial cells. *J. Comp. Pathol.*, 112: 319-326.
- Fosmire, SP; Dickerson, EB; Scott, AM; Bianco, SR; Pettengill, MJ; Meylemans, H; Padilla, M; Frazer-Abel, AA; Akhtar, N; Getzy, DM; Wojcieszyn, J; Breen, M; Helfand, SC and Modiano, JF** (2004). Canine malignant hemangiosarcoma as a model of primitive angiogenic endothelium. *Lab. Invest.*, 84: 562-572.
- Gholami, MR; Ezzi, A and Ahourai, PA** (1992). Case report

- of hemangiosarcoma in imported cattle. *Arch. Razi Inst.*, 43: 61-64.
- Guard, C and Wilkinson, JE** (1984). Hemangiosarcoma in a cow. *J. Am. Vet. Med. Assoc.*, 185: 789-790.
- Hill, TP; Lobetti, RG and Schulman, ML** (2000). Vulvovaginectomy and neo-urethrostomy for treatment of haemangiosarcoma of the vulva and vagina. *J. S. Afr. Vet. Assoc.*, 71: 256-259.
- Kim, JH; Graef, AJ; Dickerson, EB and Modiano, JF** (2015). Pathobiology of hemangiosarcoma in dogs: research advances and future perspectives. *Vet. Sci.*, 2: 388-405.
- Kübar, H and Jalakas, M** (2002). Pathological changes in the reproductive organs of cows and heifers culled because of infertility. *J. Vet. Med. A Physiol. Pathol. Clin. Med.*, 49: 365-372.
- Mathewos, M; Teshome, T; Fesseha, H and Yirgalem, M** (2021). Cytopathological characterization of papillomatosis in cattle of Wolaita Sodo district, Southern Ethiopia. *Sci. Afr.*, 13: e00882.
- Poulsen, KP; McSloy, AC; Perrier, M; Prichard, MA; Steinberg, H and Semrad, SD** (2008). Primary mandibular hemangiosarcoma in a bull. *Can. Vet. J.*, 49: 901-903.
- Queen, WG; Masterson, MA and Weisbrode, SE** (1992). Hemangiosarcoma of the external naris in a cow. *J. Am. Vet. Med. Assoc.*, 201: 1411-1412.
- Schultheiss, PC** (2004). A retrospective study of visceral and nonvisceral hemangiosarcoma and hemangiomas in domestic animals. *J. Vet. Diagn. Invest.*, 16: 522-526.
- Sharma, D** (2012). Hemangiosarcoma in a geriatric Labrador retriever. *Can. Vet. J.*, 53: 889-892.
- Sharun, K; Basha, MA; Shah, MA; Kumar, K; Kumar, P; Shivaraju, S and Pawde, AM** (2019). Clinical management of cutaneous hemangiosarcoma in canines: a review of five cases. *Comp. Clin. Pathol.*, 28: 1815-1822.
- Stock, ML; Smith, BI and Engiles, JB** (2011). Disseminated hemangiosarcoma in a cow. *Can. Vet. J.*, 52: 409-413.
- Sutton, RH and McLennan, MW** (1982). Hemangiosarcoma in a cow. *Vet. Pathol.*, 19: 456-458.
- Urdaz, JH; Tyler, JW; Henry, CJ; Gautz, P; Turk, JR and Turnquist, SE** (2001). Primary cutaneous haemangiosarcoma in a cow. *Vet. Rec.*, 149: 306-307.
- Vermunt, JJ and Thompson, KG** (2001). Haemangiosarcoma in a 4-month-old calf. *N. Z. Vet. J.*, 49: 120-121.
- Vogel, SR; Desrochers, A; Lanthier, I; Strina, M and Babkine, M** (2012). Acute compartment syndrome in the pelvic limb of a cow following biopsy of a skeletal muscle-associated hemangiosarcoma. *J. Am. Vet. Med. Assoc.*, 240: 454-458.
- Warren, AL and Summers, BA** (2007). Epithelioid variant of hemangioma and hemangiosarcoma in the dog, horse, and cow. *Vet. Pathol.*, 44: 15-24.
- Yamamoto, S; Hoshi, K; Hirakawa, A; Chimura, S; Kobayashi, M and Machida, N** (2013). Epidemiological, clinical and pathological features of primary cardiac hemangiosarcoma in dogs: a review of 51 cases. *J. Vet. Med. Sci.*, 75: 1433-1441.
- Zachary, JF; Mesfin, MG and Wolff, WA** (1981). Multicentric osseous hemangiosarcoma in a Chianina-Angus steer. *Vet. Pathol.*, 18: 266-269.