

Received: 2020.03.20

Accepted: 2020.07.28

Available online: 2020.09.29

Published: 2020.11.11

Flexible Intramedullary Nailing for Supracondylar Femoral Fractures in Pediatric Duchenne Muscular Dystrophy: A Case Report

Authors' Contribution:

Study Design A
Data Collection B
Statistical Analysis C
Data Interpretation D
Manuscript Preparation E
Literature Search F
Funds Collection G

ABCDEF 1 **Marco Distefano**
BCDF 2,3 **Camilla Bettuzzi**
BCDF 2,3 **Giada Salvatori**
BCDF 4 **Giovanna Cristella**
BCDF 2 **Caterina Novella Abati**
ABCDEF 2,3 **Manuele Lampasi**

1 Orthopaedic Clinic, Department of Surgery and Translational Medicine, University of Florence, Florence, Italy
2 Department of Paediatric Orthopaedics and Traumatology, Anna Meyer Children's Hospital, Florence, Italy
3 Ortopediatria, Center for Education, Research and Patient Care in Paediatric Orthopaedics, Bologna, Italy
4 Unit of Children Rehabilitation, IRCCS Fondazione Don Carlo Gnocchi, Florence, Italy

Corresponding Author: Manuele Lampasi, e-mail: manuele.lampasi@gmail.com

Conflict of interest: None declared

Case series

Patients: 11-year-old • 12-year-old

Final Diagnosis: Duchenne muscular dystrophy

Symptoms: Fracture

Medication: —

Clinical Procedure: —

Specialty: Orthopedics and Traumatology

Objective: Unusual or unexpected effect of treatment

Background: Femoral fractures are common in patients with Duchenne muscular dystrophy (DMD) and represent a critical moment in the natural history of the disease. The immobilization required for fracture healing frequently leads to further weakening and worsening (or definitive loss) of functional abilities. Surgical treatment has been advocated in ambulatory and nonambulatory patients with rapid mobilization of patients as the main goal; however, it exposes patients to considerable anesthetic risk.

Case Reports: We present a previously unreported experience of flexible intramedullary nailing (FIN) in 2 DMD patients (aged 11.7 and 12.8 years) who were still able to walk or stand when the supracondylar femoral fractures occurred. The surgical procedures were performed with sufficient reduction and stabilization of fractures. Rapid mobilization of the patients was achieved, including muscle strengthening exercises. A prompt recovery of the upright standing position and successive ambulation was accomplished in the patient with the higher functional status before the fracture, whereas the standing ability was not recovered in the other patient. No increase of knee flexion contractures and no growth disturbances were recorded at the follow-up.

Conclusions: The operative treatment option should be considered by a multidisciplinary team; they should evaluate the advantages and risks for each patient considering their functional status. For ambulatory children (or patients still able to stand), FIN can represent a valid, minimally invasive, apparently growth-sparing and sufficiently stable osteosynthesis, allowing rapid rehabilitation of the patient that can limit, but not completely avoid the consequences of the femoral fracture.


MeSH Keywords: Child • Femoral Fractures • Fracture Fixation, Intramedullary • Muscular Dystrophy, Duchenne

Full-text PDF: <https://www.amjcaserep.com/abstract/index/idArt/924460>

 2616

 —

 7

 25



Background

Femoral fractures are common in patients with Duchenne muscular dystrophy (DMD) due to marked osteoporosis mainly secondary to corticosteroid treatment and reduced weight-bearing [1], and falls from wheelchairs or a standing position. They represent a critical moment in the natural history of a progressive loss of functional abilities. These fractures commonly affect children who are progressively losing their ability of unsupported walking and standing [1] and the immobilization required for fracture healing commonly leads to further muscle weakening and the loss of these residual skills [2,3]. When the ambulatory ability is tenuous, even minor bruises, ankle sprains or bed rest as short as 2 weeks can cause the end of the walking ability [2,3].

Physicians face a difficult decision between operative and non-operative treatment. The surgical treatment aims to reduce the immobilization (especially bed rest) and inactivity to a minimum in order to preserve function and muscle trophism; however, it exposes the patients to anesthetic risks [4]. Only a few papers describe the management of femoral fractures in patients with DMD, and very few report operative treatment. The surgical options include percutaneous pinning, plating, rigid or flexible intramedullary nailing, and each option has its advantages and drawbacks.

We present our experience of flexible intramedullary nailing (FIN) in 2 children with DMD, who were able to walk or stand when the supracondylar femoral fractures occurred; this has not been previously reported. The functional status and medical therapy before the fracture and the mechanism of the injury were analyzed. Radiographs at the time of the fracture were reviewed to determine the characteristics of the lesion (amount and direction of displacement). The postoperative and follow-up radiographs were reviewed along with the clinical records and the postoperative functional status was assessed. The results are described and literature on the topic is reviewed.

Case Reports

The medical records of 2 pediatric DMD patients, who underwent surgical treatment for supracondylar femoral fractures at our institution between February 2017 and April 2018 were reviewed retrospectively.

Case descriptions

The 2 DMD patients were 12.8 years old (patient A) and 11.7 years (patient B) old at the time of the fractures. No other information is available on these patients' medical and family

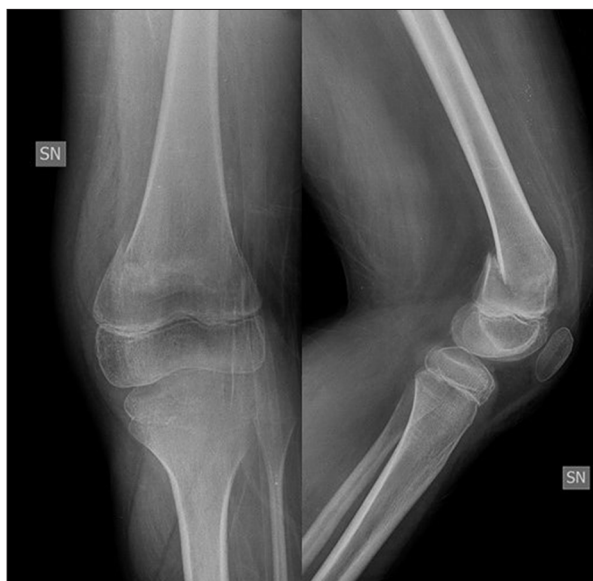

Figure 1. Preoperative radiographs of patient A: Age 12.8 years, able to walk without support for short distances before the fracture.

histories. In patient A, the DMD was diagnosed at the age of 5 years. Before the fracture, his functional status was that he could walk without support for short distances (50 m/5 min) and was undergoing physical treatment and splinting at night due to an equinus triceps contracture that caused toe-walking.

In patient B, the DMD was diagnosed at the age of 4 years, and before the fracture, he was able to autonomously maintain the upright position and perform postural passages. However, wheelchair transport was required for indoor and outdoor mobility from about 6 months before the fracture.

Both patients had used corticosteroids for several years (7 and 8 years, respectively) and were concurrently taking calcium and vitamin D supplements. Before surgery, patient A was taking vitamin D 2000 IU/ml per day, and calcium lactogluconate and calcium carbonate 1000 mg/day. Patient B was on Colecalcium® (food supplement of calcium and vitamin D) 5 ml/day. The preoperative examinations for patient B revealed a vitamin D deficiency; therefore, the supplementation was increased after surgery.

Supracondylar femoral fractures occurred in both patients after low-energy trauma (falls from a standing height) and showed only angulation in flexion with no gross displacement (Figure 1).

In both cases, the possible options for treatment, primarily nonoperative versus operative, and secondarily surgical techniques between percutaneous pinning, plate fixation, intramedullary nailing, and FIN were discussed with the families and a multidisciplinary team; finally, the FIN procedure was chosen.

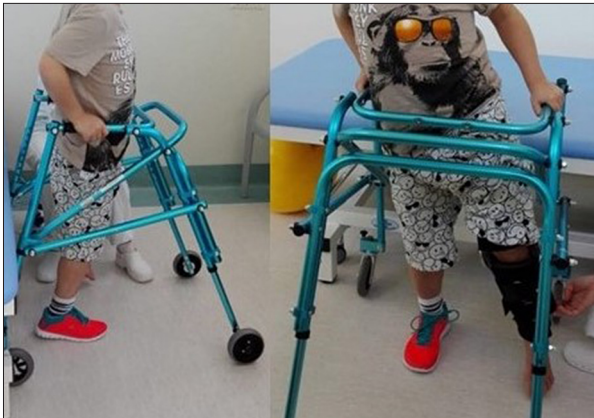

Figure 2. Patient A, 1 week after surgery: standing position achieved with walker support, a knee immobilizer, and no weight-bearing on the operated limb.

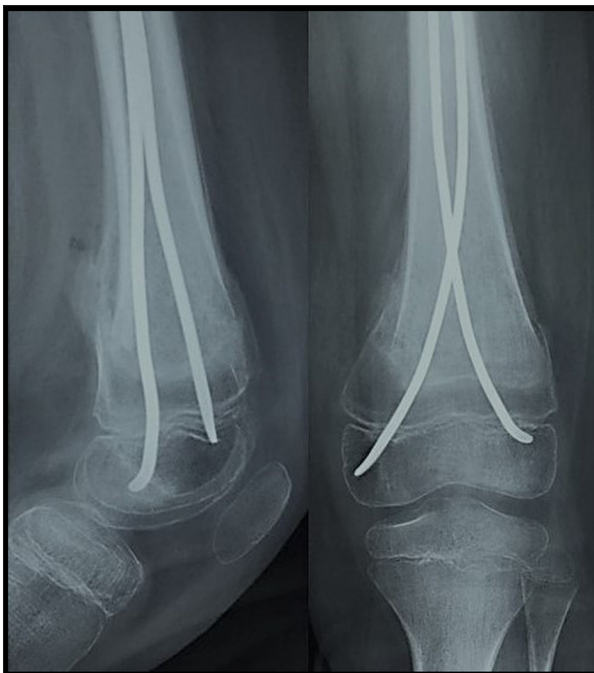

Figure 3. Radiographs of patient A, 2 months after surgery: complete consolidation with normal alignment.

Surgical procedure

The surgery was performed in both cases in the supine position, under general anesthesia without the use of a traction table. An image intensifier was used. The FIN [3] was realized in a descending construct with the 2 nails entering the medullary cavity from the lateral cortex below the greater trochanter. The first nail was advanced up to the fracture site, then the second nail was inserted and advanced. Once the 2 nails were ready to overpass the fracture symmetrically (each pointing to 1 condyle), reduction was achieved by closed maneuvers (mostly extension of the knee) and the nails were pushed across the

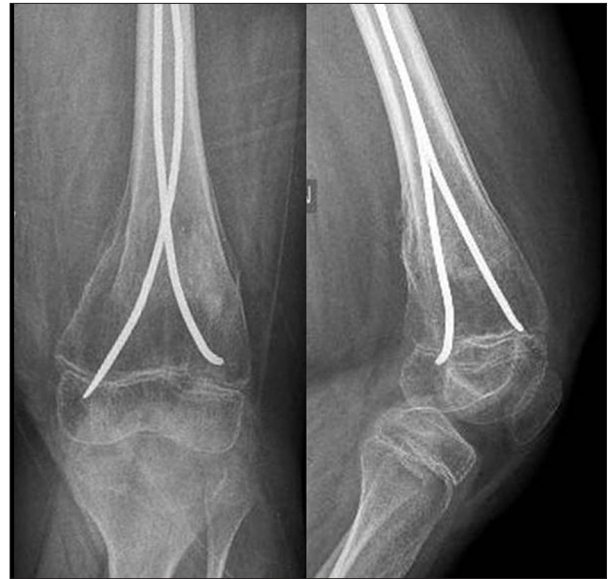

Figure 4. Radiographs of patient A, 18 months after surgery.

fracture and into the distal physes to get more stability for a few millimeters. The quality of the reduction and the stability were tested at the end of the procedure and judged sufficient to allow limb mobilization but not weight-bearing on that limb.

The surgical procedures were performed as described above and no complications were recorded. The evaluation of the postoperative radiographs showed satisfying reductions with the distal fragment in extension as required for functionality. The postoperative course for the 2 patients was 3 days and 6 days, respectively, which was uneventful. No blood transfusion was required. A rigid knee immobilizer was applied for both patients.

A prompt rehabilitation program was implemented from the 2nd postoperative day, including isometric exercises for the quadriceps muscles of the affected limbs and stretching exercises for the contractures (as soon as tolerated), rapid wheelchair mobilization, and progressively an upright standing position with support and no weight-bearing on the operated limb. The supported standing was achieved only in patient A, 5 days after surgery (Figure 2). After hospital discharge (3 and 6 days after surgery, respectively), the patients continued rehabilitation at other institutions. About 30 days after surgery, the radiographs showed a regular healing process with no secondary displacement; complete weight-bearing was allowed (initially maintaining the knee immobilizer and then without the orthosis) along with the initiation of knee range-of-motion and muscle-strengthening exercises. The follow-up radiographs 2 months after the surgery showed complete consolidation (Figure 3). The clinical examination 3 months post surgery showed the absence of knee-flexion contracture in both cases.

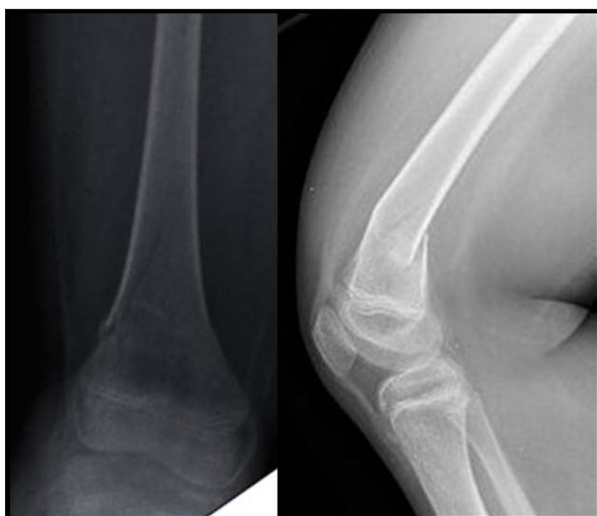


Figure 5. Preoperative radiographs of patient B: Age 11.7 years, able to autonomously maintain the upright position and perform postural passages before the fracture.

With regard to the ambulatory status, patient A recovered independent walking 2.5 months after the fracture. Although during the next 6 months, patient A lost ambulation and was able to perform only when standing at the last follow-up visit, 18 months after the surgery (Figure 4). Patient B (Figures 5–7) did not recover the standing and transfer abilities after the fracture. In both patients, at the 1-year radiographic follow-up, the distal femur showed partial proximal migration of the nails with regard to the physis and no growth arrest. As this is a retrospective case report where the identities of human subjects are kept anonymous, our institution does not need an approval from the review board.

Discussion

Fractures are frequent occurrences in patients with DMD, with a reported incidence in 21% to 44% of patients [1]. The probability of sustaining at least 1 fracture in all DMD patients was reported to be 4% at 6 years, 9% at 9 years, 31% at 12 years, and 60% at 15 years of age with an accelerating frequency around the time of ambulation loss (mean age 11.8 ± 2.7 years) [1]. The lower limb (especially the femur) is the most common site for a fracture [2,5–7].

The fractures are generally due to low-energy trauma, more commonly falls [2] acting on an osteoporotic bone. The falls from wheelchairs or a standing position are facilitated by muscle weakness, joint contractures, and a reduced sitting or standing balance [8]. The side effects of long-term corticosteroids, reduced weight-bearing exercises, reduced exposure to sunlight, and direct pathological effects of the myopathy are among the major risk factors for osteoporosis in DMD [1]. The

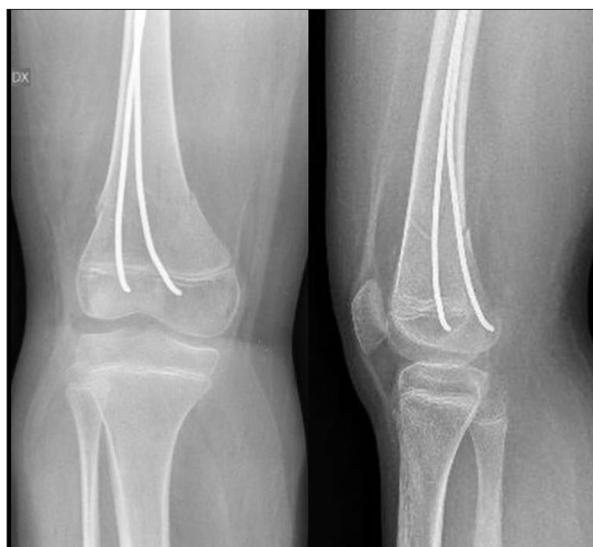

Figure 6. Postoperative radiographs of patient B: achieved reduction in the angulation of flexion.

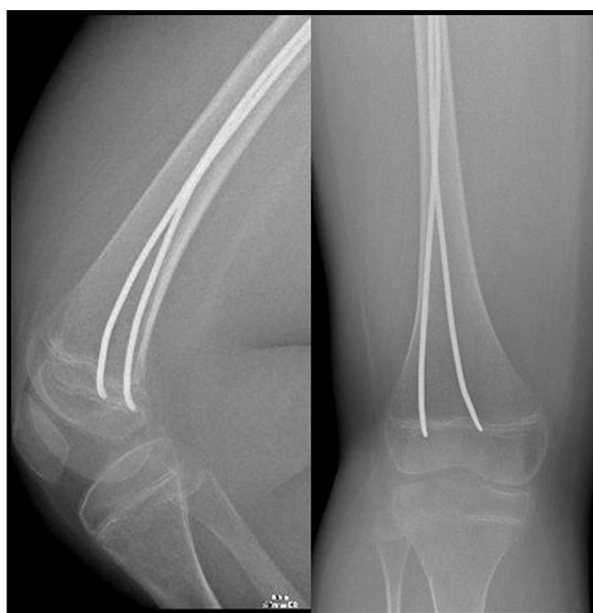

Figure 7. Radiographs of patient B, 1 year after surgery.

osteoporosis is most profound in the lower extremities and begins to develop early while still ambulating [7]. The bone mineral density in the proximal femur was reported to be considerably diminished even when gait was minimally affected; then it progressively decreased to nearly 4 standard deviations below the age-matched normal [7]. Calcium and vitamin D or alendronate administration are investigational treatments to improve bone mineral density, and eventually to reduce the fracture risk [9–11].

In most cases, the femoral fractures involve the supracondylar region [12,13] where the diaphyseal cortical bone ends.

Significant displacement requiring open reduction is rarely found [3,5,13] in these cases, and the distal fragment is usually angulated in flexion. Pre-existing mild flexion contractures of the knee may facilitate this displacement and if the angulation is not completely reduced, it can be augmented after consolidation [3].

The options for treatment primarily include a nonoperative treatment of casts applied with no anesthesia and no possibility of fracture reduction [6,13]. The immobilization can be achieved with a spica or a long leg cast. The former includes an extension of the cast to the pelvis to increase the stability of the fracture; however, it is significantly uncomfortable and hardly accepted by patients. The latter is limited to the thigh, to allow hip movements and facilitate patient management; yet, this greater mobility can cause increased pain especially during the first few days until initial healing has occurred. In both circumstances, there is a high risk of skin breakdown (facilitated by the reduced mobility of the child, and steroid-induced skin fragility) [3] and secondary displacement [14].

A favorable outcome has been reported after nonoperative treatment for nonambulatory patients [12,13]; particularly in the wheelchair-bound patients who did not show worsening in functional ability [6], given the minimum level of autonomy recorded before the fracture.

For the risk of increased knee flexion contracture due to posterior angulation (or secondary displacement) at the site of the fracture, some authors [13] accepted a minimal amount of posterior displacement. Others [3] were concerned about this issue and favored operative treatment even in this group of patients, to prevent the deterioration of contractures that would make positioning, transfers, and standing more difficult.

The main issue for operative treatment in DMD is the considerable anesthetic risk due to the impairment of pulmonary and heart functions typical of the advanced stage of the disease [15,16]. In addition, prolonged glucocorticoid therapy reduces the stress response during surgery [17,18]. There is a risk of anesthesia-induced rhabdomyolysis and cardiac arrest with the use of depolarizing muscle relaxants. Therefore, they are contraindicated in these patients [17]. Inhalational anesthesia is not recommended due to the uncertainty of the risk of malignant hyperthermia-like reactions [15–18].

For these reasons, the decision of operative treatment should be carefully considered, evaluating the advantages and risks, and involving the family and all the medical team (orthopedic surgeons, anesthesiologists, pediatricians, cardiologists, pulmonologists and physiotherapists).

In ambulatory children or patients still able to perform unsupported standing or transfers, the expected advantages of an operative option are significant, while this option is questionable in nonambulatory children. A surgical stabilization of the fractures allows the patients to be quickly mobilized and to stand with light or no orthosis, which is supposed to reduce the muscle weakening. This cannot be permitted with nonoperative treatment due to insufficient stabilization of the fracture, pain, and the cast weight. Prolonging the standing and ambulation is a major therapeutic goal for these patients [2].

Once surgical stabilization has been decided, the type of procedure has to be evaluated. The possible options for supracondylar femoral fractures in children include percutaneous pinning, plating, rigid or elastic intramedullary nailing, each with its own pros and cons. Closed reduction and percutaneous pinning can be performed using Kirschner wires inserted from the lateral and medial epicondyle, and crossing the physis. Due to the osteoporosis, more than 2 cross pins are usually required for the stabilization (this may increase the risk of physeal damage) and the cast is associated. This approach has the advantage of being a simple low-cost technique, with no need for additional surgery for implant removal [19]; yet, rapid postoperative standing is hardly possible due to the cast weight, pain, and pin-related skin irritation [19,20].

Plate fixation has been described in reports of non-pediatric or nondisabled patients with supracondylar femoral fractures [21–23]. In addition to several disadvantages (increased surgical exposure and infective risk, difficult fixation in the osteoporotic bone), plating for these fractures in children requires bridging of the physes with resultant growth damage, and consequences proportional to residual growth [24].

Another option is rigid retrograde intramedullary nailing. Since femoral interlocking nails are not available in the adequate design and size, Biber et al. described the use of standard proximal humeral nails (smaller diameters available) in 2 15-year-old nonambulatory DMD patients with femoral fractures of the distal diaphyses [24]. The main advantage is stable fixation with the possibility of rapid mobilization of the patient. Among disadvantages is the high risk of a false route in the osteoporotic bone for rigid nails, scarce availability of nails for the narrow medullary cavities (with consequent use of off-label hardware), and the growth damage of distal femoral physes in children.

FIN has been previously reported only for 3 nonambulatory DMD patients (ages 7.9 years to 17 years) by Huber et al. [3]. The main advantages described were the minimal invasiveness of the procedure with sufficient stabilization to allow quick wheelchair mobilization and the possibility to seek a nonanatomic reduction to correct the knee flexion contracture.

To the best of our knowledge, we have reported the first 2 cases of DMD in children treated with this technique, who were still able to walk or stand unsupported before the fracture occurred. In such patients, the major goal is to limit the typical functional worsening with loss of the standing ability. In both patients, FIN allowed rapid mobilization with the use of a light orthosis and the initiation of muscle exercises. Yet, achievement of the upright standing position was possible only in patient A, who had the higher preoperative functional status. Since the fracture stability provided by FIN is not complete, full weight-bearing on the operated limb cannot be permitted. However, supported standing on the contralateral limb is very challenging for these patients, which could explain the inability of patient B to regain the standing capability. After the initial recovery, patient A experienced a progressive loss of ambulation over the next 6 months. Muscle weakness secondary to the perioperative immobilization and his ankle contracture likely played a negative role. In a recent analysis [25], patients who became nonambulatory after lower extremity fractures in DMD, initially had slower walking speeds and less ankle dorsiflexion. Other factors like pain threshold and psychological factors should be considered too.

In both cases, the follow-up radiographs showed a 'sliding' of the nails over the growth plate with proximal migration of their tips due to the unaltered growth of the distal physes. We are aware that preservation of growth is not a major objective [24]. However, this advantage should be considered when dealing with young children since the distal physis of the femur provides 70% of the longitudinal growth of the femur (and 40% of the overall growth of the lower extremity); and growth arrest can lead to shortening, axial deviation and articular deformations.

References:

1. Perera N, Sampaio H, Woodhead H, Farrar M: Fracture in Duchenne muscular dystrophy: natural history and vitamin D deficiency. *J Child Neurol*, 2016; 31(9): 1181–87
2. McDonald DG, Kinali M, Gallagher AC et al: Fracture prevalence in Duchenne muscular dystrophy. *Dev Med Child Neurol*, 2002; 44(10): 695–98
3. Huber H, André G, Rumeau F et al: Flexible intramedullary nailing for distal femoral fractures in patients with myopathies. *J Child Orthop*, 2012; 6(2): 119–23
4. Muenster T, Mueller C, Forst J et al: Anaesthetic management in patients with Duchenne muscular dystrophy undergoing orthopaedic surgery: A review of 232 cases. *Eur J Anaesthesiol*, 2012; 29(10): 489–94
5. Siegel IM: Fractures of long bones in Duchenne muscular dystrophy. *J Trauma*, 1977; 17(3): 219–22
6. Granata C, Giannini S, Villa D et al: Fractures in myopathies. *Chir Organi Mov*, 1991; 76(1): 39–45
7. Larson CM, Henderson RC: Bone mineral density and fractures in boys with Duchenne muscular dystrophy. *J Pediatr Orthop*, 2000; 20(1): 71–74
8. Kelly CR, Redford JB, Zilber S, Madden PA: Standing balance in healthy boys and in children with Duchenne muscular dystrophy. *Arch Phys Med Rehabil*, 1981; 62(7): 324–27
9. Bianchi ML, Morandi L, Andreucci E et al: Low bone density and bone metabolism alterations in Duchenne muscular dystrophy: Response to calcium and vitamin D treatment. *Osteoporos Int*, 2011; 22(2): 529–39
10. Palomo Atance E, Ballester Herrera MJ, Marquez de La Plata MA et al: [Alendronate treatment of osteoporosis secondary to Duchenne muscular dystrophy.] *An Pediatr (Barc)*, 2011; 74(2): 122–25 [in Spanish]
11. Ko A, Kong J, Samadov F et al: Bone health in pediatric patients with neurological disorders. *Ann Pediatr Endocrinol Metab*, 2020; 25(1): 15–23
12. Gray B, Hsu JD, Furumasa J: Fractures caused by falling from a wheelchair in patients with neuromuscular disease. *Dev Med Child Neurol*, 1992; 34(7): 589–92
13. Hsu JD, Garcia-Ariz M: Fracture of the femur in the Duchenne muscular dystrophy patient. *J Pediatr Orthop*, 1981; 1(2): 203–7
14. Angelini C, Peterle E: Old and new therapeutic developments in steroid treatment in Duchenne muscular dystrophy. *Acta Myol*, 2012; 31(1): 9–15
15. Annexstad EJ, Lund-Petersen I, Rasmussen M: Duchenne muscular dystrophy. *Tidsskr Nor Laegeforen*, 2014; 134(14): 1361–64
16. Apkon SD, Alman B, Birnkrant DJ et al: Orthopedic and surgical management of the patient with Duchenne muscular dystrophy. *Pediatrics*, 2018; 142(Suppl. 2): S82–89

Conclusions

The operative treatment for supracondylar femoral fractures in children with DMD should be considered by a multidisciplinary team by weighing the advantages and risks for each patient in relation to their functional status. For ambulatory children (or patients still able to stand), FIN may represent a valid, minimally invasive, apparently growth-sparing, and sufficiently stable osteosynthesis that allows rapid mobilization of the patient. A postoperative rehabilitation program including prompt and progressive physical therapy, and protected standing or ambulation is crucial. This may help in limiting the consequences of this critical event; however, these consequences cannot be completely avoided since the other factors play a role (preoperative functional status, contractures etc.) too. More data is needed to understand the real benefits of this approach in relation to the preoperative conditions and functional status of DMD patients.

Department and Institution where work was done

Department of Paediatric Orthopaedics, Anna Meyer Children's Hospital, Florence, Italy.

Conflicts of interest

None.

17. Birnkrant DJ: The American College of Chest Physicians consensus statement on the respiratory and related management of patients with Duchenne muscular dystrophy undergoing anesthesia or sedation. *Pediatrics*, 2009; 123(Suppl. 4): S242–44
18. Bushby K, Finkel R, Birnkrant DJ et al: Diagnosis and management of Duchenne muscular dystrophy, part 2: Implementation of multidisciplinary care. *Lancet Neurol*, 2010; 9: 177–89
19. Isik C, Kurtulmus T, Saglam N et al: Kirschner wire versus titanium elastic nails in pediatric femoral shaft fractures. *Acta Ortop Bras*, 2015; 23(5): 255–58
20. Garrett BR, Hoffman EB, Carrara H: The effect of percutaneous pin fixation in the treatment of distal femoral physeal fractures. *J Bone Joint Surg (Br)*, 2011; 93(5): 689–94
21. Wang WJ, Shi HF, Chen DY et al: Distal femoral fractures in post-poliomyelitis patients treated with locking compression plates. *Orthop Surg*, 2013; 5: 118–23
22. El-Sayed Khalil A: Locked plating for femoral fractures in polio patients. *Arch Orthop Trauma Surg*, 2010; 130(10): 1299–304
23. Abdelgawad AA, Kanlic EM: Pediatric distal femur fixation by proximal humeral plate. *J Knee Surg*, 2013; 26: S45–49
24. Biber R, Stedtfeld HW, Bail HJ: The Targon PH(®) nail for distal femoral fracture fixation in disabled children. A report of three cases. *Orthop Traumatol Surg Res*, 2014; 100(6): 699–702
25. Yildiz S, Glanzman AM, Estilow T et al: Retrospective analysis of fractures and factors causing ambulation loss after lower extremity fractures in Duchenne muscular dystrophy. *Am J Phys Med Rehabil*, 2020; 99(9): 789–94