



The unstable os acromiale: a cause of pain in the young athlete

Antonio Arenas-Miquelez, MD^{*}, Ralph Hertel, Prof

Shoulder and Elbow, Orthopaedics, Lindenhofspital, Switzerland



ARTICLE INFO

Keywords:

Os acromiale
shoulder pain
overhead athlete
vascularity
arthrodesis

Level of evidence: Level IV; Case Series;
Treatment Study

Purpose: Os acromiale is a common entity in the middle-age group, in whom it is frequently associated with rotator cuff tears. However, it can be a cause of shoulder pain in the young athletes. We want to increase awareness of this pathology that may occultly affect the young athlete as well as to present the results of a perfusion-preserving arthrodesis.

Methods: Four consecutive young patients (17–21 years old) with a history of at least 6 months of unrecognized shoulder pain were surgically treated for os acromiale. Through a superior approach, stabilization of the neo-joint by means of cannulated screws and autogenic graft augmentation was performed.

Results: Union of the os acromiale was achieved in all the patients. They had an excellent functional outcome, reaching all the maximum Simple Shoulder Test (12) and Oxford shoulder Score (48) scores. All the patients were able to return to their previous sports level.

Conclusion: Awareness of the os acromiale in the young athlete, appropriate clinical examination, and image studies are crucial to confirm diagnosis. Surgical treatment aiming at fusion in situ has shown excellent result.

© 2020 The Author(s). Published by Elsevier Inc. on behalf of American Shoulder and Elbow Surgeons. This is an open access article under the CC BY-NC-ND license (<http://creativecommons.org/licenses/by-nc-nd/4.0/>).

The os acromiale is an infrequent entity,^{12,14,17} related to rotator cuff tears^{5,10} and acromioclavicular (AC) joint arthritis⁹ in the middle aged. Sometimes it may affect the young and active individual and go unrecognized for a long time. It may present as un-specific subacromial pain.^{8,15}

Normally the ossification centers complete their fusion by the age of 22–25 years and the bony bridging occurs from posterior to anterior.²⁰ The reason for an eventual lack of fusion is possibly the mechanical strain on the developing acromion. During the peri-fusion phase, repetitive stress and strain or even a single traumatic event may stop the bridging process, resulting in a hypermobile joint.⁴ Striving at fusion of this diarthrodial joint has been proposed, with a variable success rate.^{3,8,13,16}

The aim of this case series was to increase awareness of this pathology that may occultly affect the young athlete as well as to present the results of a perfusion-preserving arthrodesis.

Materials and methods

Between 2007 and 2017, 4 patients younger than 22 years underwent surgery for isolated unstable os acromiale (Table I).

The first patient was an 18-year-old right-handed man evaluated at our office with right shoulder pain of 1.5 year's duration. He was a tennis player competing in the national league. The pain had started insidiously without any trauma while undergoing regular training and was more intense when hitting the forehand and serving. Two months after the initial onset of pain, he was referred to the orthopedic surgeon who examined him and asked for image studies. The simple shoulder radiographs were determined to be normal, and he was assigned to a physical therapy, including stretching, strengthening, cryotherapy, and anti-inflammatory drugs on demand. Following this treatment, however, he was unable to return to his previous level and compete in championships.

The second patient was a 17-year-old right-hand-dominant girl who presented in our office with left shoulder pain of 2 years' duration. She was a hockey player on her regional competitive hockey team and she was a potential college scholarship athlete. No specific traumatic event was recalled with the progressive onset of symptoms. She reported that she had more pain when shooting from the left side and with minimal collisions during the game than at rest. Moreover, she felt pain when performing daily-life overhead activities or when sleeping on her left shoulder. Six weeks after the

This study was approved by the Bern Cantonal Commission of Ethics (no. Req-2019-01140). Ethics approval was obtained to evaluate postoperative results, and the patients signed the informed consent form to be part of the research.

^{*} Corresponding author: Antonio Arenas-Miquelez, MD, Shoulder and Elbow, Orthopaedics, Lindenhofspital, Bremgartenstrasse 117, 3001, Bern, Switzerland.

E-mail address: antarenas1987@gmail.com (A. Arenas-Miquelez).

<https://doi.org/10.1016/j.jseint.2020.02.008>

2666-6383/© 2020 The Author(s). Published by Elsevier Inc. on behalf of American Shoulder and Elbow Surgeons. This is an open access article under the CC BY-NC-ND license (<http://creativecommons.org/licenses/by-nc-nd/4.0/>).

Table 1
Pre- and postoperative data for the patients in our series

Case	Age	Sex	Delay before diagnosis to surgery, mo	Mechanism	Stability OA	Screw stabilization	Postsurgical follow-up, mo	Preoperative SST	Postoperative SST	Preoperative OSS	Postoperative OSS
1	18	M	18	Tennis overuse	Severe instability	Yes	45	7	12	30	48
2	17	F	24	Hockey repetitive trauma	Moderate unstable	No	140	6	12	26	48
3	21	M	12	Wrestling overload	Severe instability	Yes	25	8	12	32	48
4	20	M	8	Ski accident	Severe instability	Yes	24	7	12	28	48

M, male; F, female; OA, os acromiale; SST, Shoulder Simple Test; OSS, Oxford Shoulder Score.

initial onset of pain, she visited her family doctor, who did not make a specific diagnosis, referring her to physiotherapy. After 2 months of physical therapy, cryotherapy, and rest, she resumed her sport activity and was involved again in competition. During the next few months, the shoulder pain increased in intensity until she was forced to stop all sport activity. Twenty-three months after the initial onset, the patient again visited the family doctor, who noted subacromial impingement signs and biceps tendinitis and referred her to us.

The third patient was a 21-year-old right-hand–dominant man who presented to our clinic with a 1-year history of left shoulder pain. He was a professional schwinger (a Swiss wrestling modality) ranked among the top 10 in the national league. He referred to multiple collisions and falls on both shoulders during routine fights, but he did not recall any of them as a pain trigger. He reported severe pain on the upper part of the left shoulder when wrestling the opponents. Two months after the onset of symptoms and before the end of the competitive season, he was forced to stop because of the severity of symptoms. The patient underwent physical therapy for 6 months, which failed to relieve shoulder pain when returning to training. After seeing the primary care physician, who examined him and observed the intense pain and mobility restriction, he was referred to our clinic.

The fourth patient was a 20-year-old right-hand–dominant man who showed up at our office after a history of 8 months' right shoulder pain. He was involved in overhead sports such as tennis and volleyball at a recreational level. The patient had first noticed

discomfort in his right shoulder after a ski accident in which he fell on the same shoulder. Three days after the accident, he saw his primary care physician because of persistence of pain. After the examination, he obtained plain shoulder radiographs but they were unremarkable. The family doctor treated him with nonsteroidal anti-inflammatory drugs, cryotherapy, and rest. After 2 months, he began with his regular overhead sport activities but had increasing pain when hitting the ball in tennis, volleyball, and swimming, especially when crawling. The patient used cryotherapy after his workout, reporting temporary pain relief. Because the patient had prolonged pain of 8 months that impeded his daily-life activities, he sought a second opinion at our clinic.

All patients complained of subacromial “impingement-like” symptoms and had no previous surgeries. The physical examination revealed exacerbated pain with active flexion and abduction. The passive shoulder motions were symmetric without any loss of flexo-extension or rotations in the affected shoulders. Subacromial impingement maneuvers (Hawkins, Neer, and Yocum) were positive. Selective tenderness and discomfort occurred when strongly pressing over the acromio-acromial joint. Pressing down the acromion with a finger lead to visible and palpable motion at the site of the os acromiale (Video 1). Rotator cuff tests were consistently normal. Strength was reduced compared with the contralateral side. Neither the palpation of the acromioclavicular joint nor the cross-arm test was painful.

Imaging evaluation included anteroposterior, subacromial outlet, and axillary radiographs. Of these projections, the axillary was the most helpful to identify the os mesoacromiale in all cases (Fig. 1). A magnetic resonance imaging ruled out the presence of rotator cuff tears, SLAP lesions, or arthritic changes of the AC joint (Fig. 2). A further single-photon emission computed tomographic / computed tomographic scan (Fig. 3) confirmed that the nonunion had high metabolic activity.

All patients underwent a course of conservative treatment, which included nonsteroidal anti-inflammatory drugs and physiotherapy, for at least 6 months. The purpose of the surgery was to obtain fusion of the acromion by resecting the joint, interposing an autogenic graft and stabilizing with screws. The patients were operated under general anesthesia in beach chair position using a superior approach.¹⁰ The dissection preserved the anterior deltoid and, thus, the vascular supply coming from the acromial branch of the thoracoacromial artery. The interacromial articulation was approached, performing minimal resection of 3 mm of the bone ends using a burr. About 80% of the “joint” was resected while preserving the inferior, medial, and lateral rims of the joint. The remaining 20% of the articular surfaces prevented shortening and malalignment of the acromion. The acromioclavicular joint was left intact. Autologous cancellous bone graft was harvested from the ipsilateral iliac crest and used to fill the defect. Finally, the os acromiale was stabilized using 2 fully threaded cannulated 3.5-mm screws introduced from the posterior acromial margin. The screws were inserted without compression to avoid shortening. In one patient, stability was considered sufficient to obtain healing of the

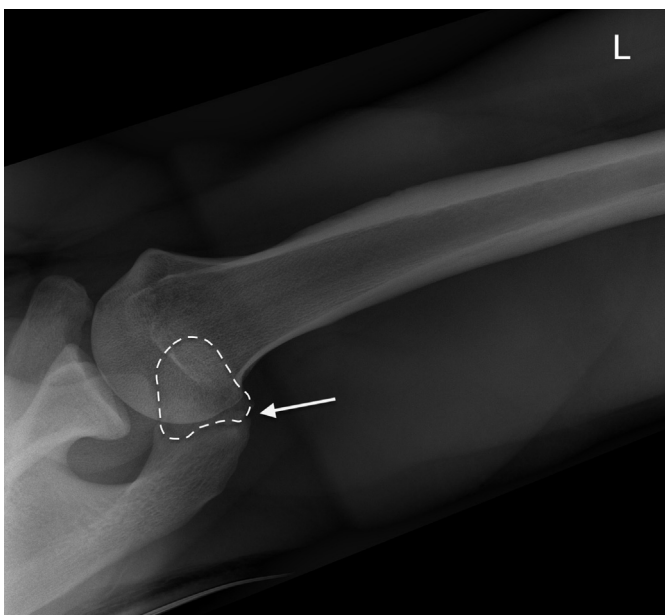


Figure 1 Axillary view radiograph of a left shoulder defines the neo-joint line (→) and the extension of the os mesoacromiale (- - -).

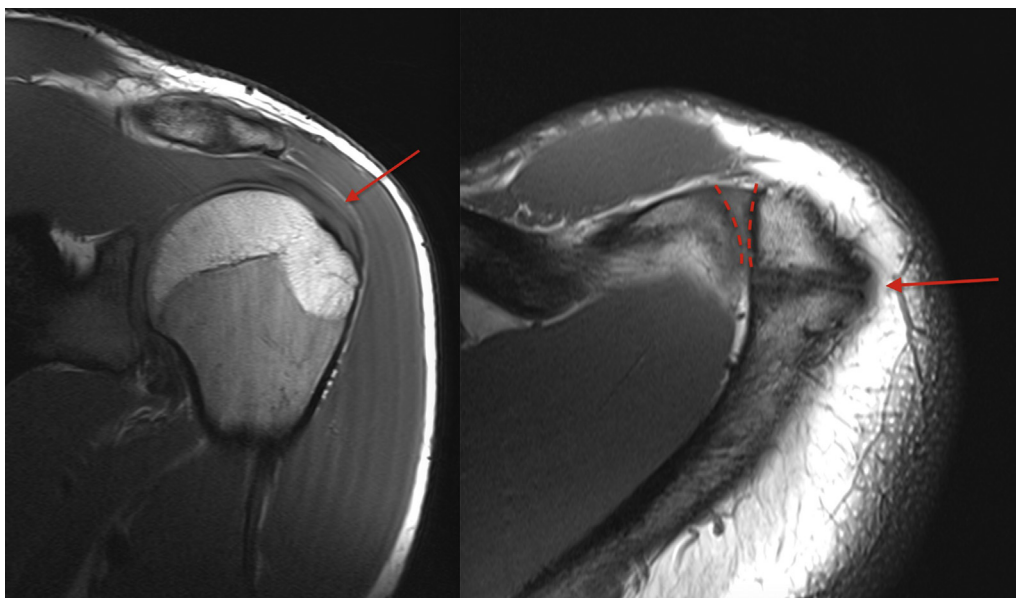


Figure 2 (Left) T1-weighted MRI coronal view of a left shoulder shows intact supraspinatus insertion. (Right) T1-weighted MRI axial view of a left shoulder shows the os mesoacromiale joint line (→) The adjacent acromioclavicular joint remains free of arthritic changes (- - -). MRI, magnetic resonance imaging.

bone graft and therefore no screws were used. Additional decortication of the bone ends and closure of the periosteum was done.

Postoperatively the patients were immobilized with a simple sling for 6 weeks. Within this time, free passive range of motion was allowed. In a second phase from week 7-12, active mobilization without load was allowed.

The patients were reviewed at 6 weeks, 12 weeks, and at 2 or more years postoperatively. At the last follow-up, analysis included clinical examination, the Oxford Shoulder Score, and the Simple Shoulder Test.^{2,7} Radiographic assessments using a modified axillary radiographic view were done to confirm fusion. The radiographic studies were independently assessed by 2 surgeons.

Results

The mean follow-up time at the final revision was 58 months (24, 26, 44, and 140 months, respectively, for each of the patients).

Patient 1 started shoulder-strengthening exercises 12 weeks after surgery and returned to training in the tennis court 5 months after surgery. Seventh months postoperatively he was able to play pain-free. At that time, he was allowed to participate in tennis competition without limitations, reaching the same preoperative level.

Twelve weeks after surgery, patient 2 was allowed to run and do static bicycling. At the fourth month, she was allowed to join her hockey training, progressively using her affected arm. Six months after the surgery, she was completely asymptomatic and returned to competition at the same level.

Patient 3 had complete range of motion 12 weeks after the surgery but was not allowed to return to Schwingen progressively until the seventh month. Because of the heavy load of the shoulder and violent falls during the combats, we adopted a more conservative attitude. He returned to competition 9 months postoperatively and won the national championship 15 months after the surgery.

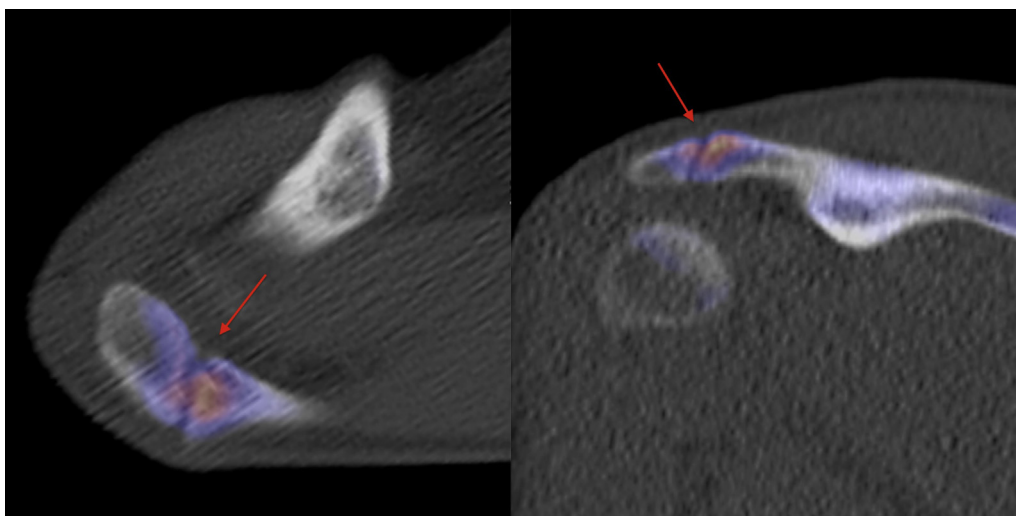


Figure 3 SPECT/CT axial (left) and coronal (right) reveals increased activity at the unfused mesoacromion, indicating ongoing osteoblastic activity likely from a painful os acromiale. SPECT, single-photon emission CT; CT, computed tomography.

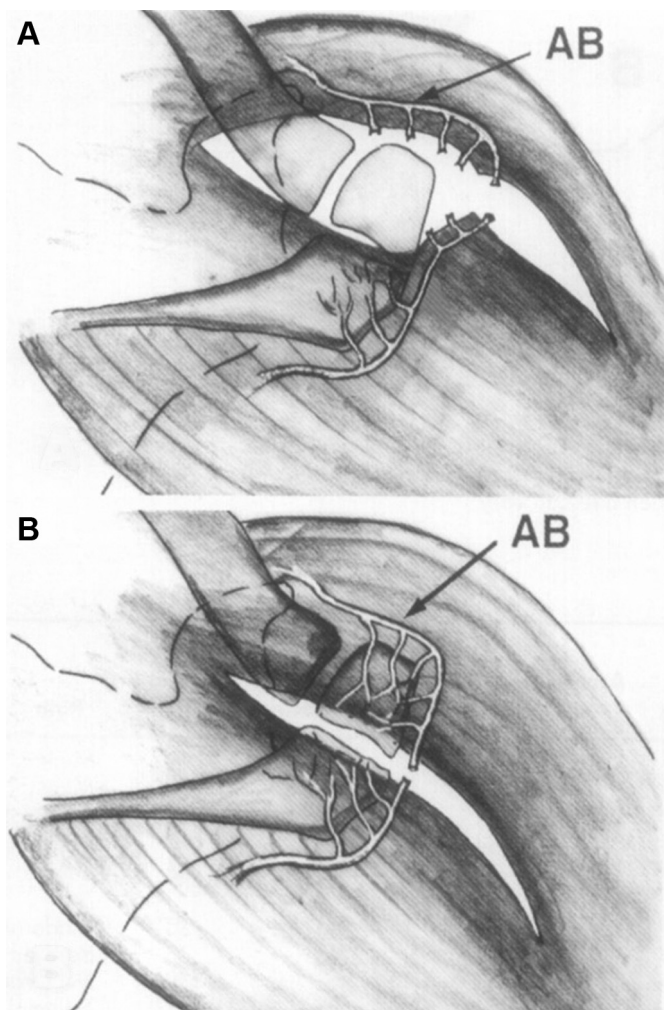


Figure 4 (A) Anterior approach: acromial terminal branches (AB) of the thoracoacromial artery are disrupted. (B) Superior approach: terminal branches of the thoracoacromial artery remain intact. Acromial epiphysis remains vital and maintains full healing potential.

Patient 4 was asymptomatic to perform daily living activities 3 months after the surgery. He started progressively swimming 4 months after the surgery, but was not allowed to return to overhead sports until the sixth month and reached the full level of sport activity at the 8-month mark. He asked for removal of a disturbing screw head on the posterior margin of the acromion 18 months after the index procedure.

On the radiologic studies, the os acromiale union was obtained in all patients (Fig. 4). The blinded radiologic union assessment by the 2 surgeons was always concordant. The mean functional score improved from 7 to 12 on the Simple Shoulder Test and from 29 to 48 on the Oxford shoulder Score.

Discussion

Shoulder symptoms in the presence of an os acromiale represent a particular challenge. Generally os acromiale are discovered when investigating rotator cuff lesions in middle-aged patients. Occasionally, unfused acromial apophyses become symptomatic early in adult life, long before the rotator cuff fails. It seems that sport-associated overuse might destabilize a previously asymptomatic os acromiale.

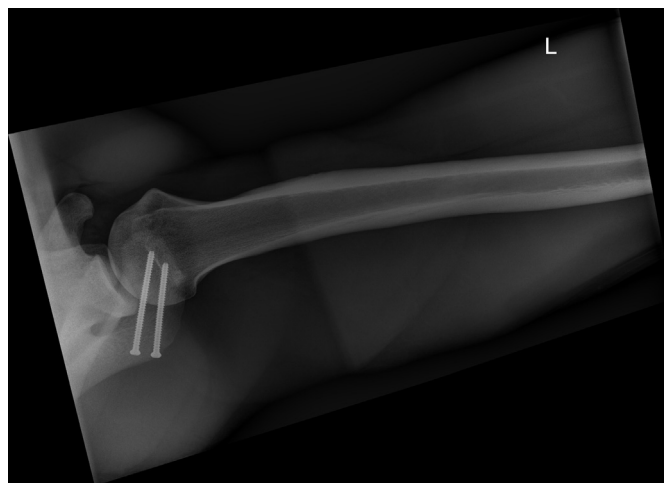

Figure 5 Axillary view radiograph of a left shoulder showing successful surgical fusion of mesoacromiale using 2 retrograde screws (3.5-mm). The acromion maintains its preoperative length and the acromioclavicular joint remains intact.

The authors have previously presented the results of os acromiale associated to rotator cuff tear, comparing the classic deltoid-off approach to the transacromial approach.¹⁰ This report focused on 4 cases in which an unstable os acromiale was the isolated source of shoulder pain. Other causes like AC joint pathology, subacromial impingement, or rotator cuff lesions were ruled out clinically and radiologically. Single-photon emission computed tomography / computed tomography was particularly useful to confirm the diagnosis.¹

Several surgical techniques have been described to stabilize the os acromiale using screws, wire cerclage, or a combination of both.^{4,6,11,18} Most of them describe a complete resection of the neo-joint, applying compression to the fragments and thereby shortening the acromion length. We have chosen an open procedure aiming at a fusion in situ, thus avoiding shortening and angulation. Preservation of perfusion, stable fixation, and bone graft are the hallmarks of the procedure.

Although the type of fixation is considered the most important aspect for os acromiale healing, promotion of biological healing was even more crucial for us. We can argue in this respect that 1 of the cases from our series got the os acromiale consolidated without the necessity of screws, with excellent long-term results. In this specific case with mild os acromiale instability and inherent favorable biology due to the early age, decortication, periosteum restoration, and graft filling were sufficient for the consolidation.

The key element for successful consolidation of the os acromiale is preservation of acromial perfusion (Fig. 4). Through the superior approach, that does not require deltoid detachment and the vascular supply to the unfused epiphysis can be maintained. We also consider that placement of screws from the posterior margin of the acromion has less postoperative screw disturbance (Fig. 5). In addition, the risk of potential damage to the acromial branch when inserting the screws from the anterior is diminished.

We also want to note that when the acromioclavicular joint is not affected, avoiding shortening of the acromion during surgery is paramount to preserve AC joint biomechanics.¹⁹ With this intention, we preserved cortices during resection and did not apply compression with the screws. Maintaining acromial length has an additional benefit by keeping the tension of the coracoacromial ligament. Otherwise, this ligament would behave as a bowstring pulling the tip of the acromion downward and causing impingement.

In conclusion, os acromiale may be a cause of otherwise unexplained shoulder pain in the young athlete. Adequate study of this entity with the appropriate clinical examination and image studies is crucial to confirm diagnosis. Surgical treatment aiming at fusion in situ has shown excellent results.

Disclaimer

The authors, their immediate families, and any research foundations with which they are affiliated have not received any financial payments or other benefits from any commercial entity related to the subject of this article.

Acknowledgments

The authors would like to acknowledge Isabel Räschle for her translation skills to communicate and collect data from patients.

Supplementary Material

Supplementary data to this article can be found online at <https://doi.org/10.1016/j.jseint.2020.02.008>.

References

- Al-faham Z, Jolepalem P. Use of SPECT/CT with 99mTc-MDP bone scintigraphy to diagnose symptomatic os acromiale. *J Nucl Med Technol* 2015;43:236–7. <https://doi.org/10.2967/jnmt.114.150102>.
- Angst F, Schwyzer H-K, Aeschlimann A, Simmen BR, Goldhahn J. Measures of adult shoulder function: Disabilities of the Arm, Shoulder, and Hand Questionnaire (DASH) and its short version (QuickDASH), Shoulder Pain and Disability Index (SPADI), American Shoulder and Elbow Surgeons (ASES) Society standardized shoulder assessment form, Constant (Murley) Score (CS), Simple Shoulder Test (SST), Oxford Shoulder Score (OSS), Shoulder Disability Questionnaire (SDQ), and Western Ontario Shoulder Instability Index (WOSI). *Arthritis Care Res* 2011;63(Suppl 11):S174–88. <https://doi.org/10.1002/acr.20630>.
- Atoun E, van Tongel A, Narvani A, Rath E, Sforza G, Levy O. Arthroscopically assisted internal fixation of the symptomatic unstable os acromiale with absorbable screws. *J Shoulder Elbow Surg* 2012;21:1740–5. <https://doi.org/10.1016/j.jse.2011.12.011>.
- Barbier O, Block D, Dezaly C, Sirveaux F, Mole D. Os acromiale, a cause of shoulder pain, not to be overlooked. *Orthop Traumatol Surg Res* 2013;99:465–72. <https://doi.org/10.1016/j.otsr.2012.10.020>.
- Boehm TD, Matzer M, Brazda D, Gohlke FE. Os acromiale associated with tear of the rotator cuff treated operatively. Review of 33 patients. *J Bone Joint Surg Br* 2003;85:545–9. <https://doi.org/10.1302/0301-620x.85b4.13634>.
- Campbell PT, Nizlan NM, Skirving AP. Arthroscopic excision of os acromiale: effects on deltoid function and strength. *Orthopedics* 2012;35:e1601–5. <https://doi.org/10.3928/01477447-20121023-16>.
- Dawson J, Rogers K, Fitzpatrick R, Carr A. The Oxford Shoulder Score revisited. *Arch Orthop Trauma Surg* 2009;129:119–23. <https://doi.org/10.1007/s00402-007-0549-7>.
- Demetrapopoulos CA, Kapadia NS, Herickhoff PK, Cosgarea AJ, McFarland EG. Surgical stabilization of os acromiale in a fast-pitch softball pitcher. *Am J Sports Med* 2006;34:1855–9. <https://doi.org/10.1177/0363546506288305>.
- Gordon BH, Chew FS. Isolated acromioclavicular joint pathology in the symptomatic shoulder on magnetic resonance imaging: a pictorial essay. *J Comput Assist Tomogr* 2004;28:215–22. <https://doi.org/10.1097/00004728-200403000-00011>.
- Hertel R, Windisch W, Schuster A, Ballmer FT. Transacromial approach to obtain fusion of unstable os acromiale. *J Shoulder Elbow Surg* 1998;7:606–9.
- Johnston PS, Paxton ES, Gordon V, Kraeutler MJ, Abboud JA, Williams GR. Os acromiale: a review and an introduction of a new surgical technique for management. *Orthop Clin North Am* 2013;44:635–44. <https://doi.org/10.1016/j.jocl.2013.06.015>.
- Kumar J, Park WH, Kim SH, Lee HI, Yoo JC. The prevalence of os acromiale in Korean patients visiting shoulder clinic. *Clin Orthop Surg* 2013;5:202–8. <https://doi.org/10.4055/cios.2013.5.3.202>.
- Lebus GF, Fritz EM, Hussain ZB, Pogorzelski J, Millett PJ. Operative treatment of symptomatic meso-type os acromiale. *Arthrosc Tech* 2017;6:e1093–9. <https://doi.org/10.1016/j.jeats.2017.03.025>.
- Nicholson GP, Goodman DA, Flatow EL, Bigliani LU. The acromion: morphologic condition and age-related changes. A study of 420 scapulas. *J Shoulder Elbow Surg* 1996;5:1–11.
- Pagnani MJ, Mathis CE, Solman CG. Painful os acromiale (or unfused acromial apophysis) in athletes. *J Shoulder Elbow Surg* 2006;15:432–5. <https://doi.org/10.1016/j.jse.2005.09.019>.
- Peckett WRC, Gunther SB, Harper GD, Hughes JS, Sonnabend DH. Internal fixation of symptomatic os acromiale: a series of twenty-six cases. *J Shoulder Elbow Surg* 2004;13:381–5. <https://doi.org/10.1016/j.jse.2004.01.023>.
- Sammarco VJ. Os acromiale: frequency, anatomy, and clinical implications. *J Bone Joint Surg Am* 2000;82:394–400.
- Stetson WB, McIntyre JA, Mazza GR. Arthroscopic excision of a symptomatic meso-acromiale. *Arthrosc Tech* 2017;6:e189–94. <https://doi.org/10.1016/j.jeats.2016.09.021>.
- Tauber M. Diseases of the acromioclavicular joint. *Orthopade* 2016;45:555–68 [in German]. <https://doi.org/10.1007/s00132-016-3269-2>.
- Yammine K. The prevalence of os acromiale: a systematic review and meta-analysis. *Clin Anat* 2014;27:610–21. <https://doi.org/10.1002/ca.22343>.