

Reoperation after modified Björk procedure for tricuspid atresia

Sana Chatti¹, Faker Ghedira¹, Houaida Mahfoudhi², Melek Ben Mrad¹, Mohamed Messai¹, Mohamed Nouar¹, Raouf Denguir¹

¹Department of Cardiovascular Surgery, Faculty of Medicine of Tunis, La Rabta Hospital, University of Tunis El Manar, Tunis, Tunisia, ²Department of Cardiology, Faculty of Medicine of Tunis, Military Hospital, University of Tunis El Manar, Tunis, Tunisia

ABSTRACT

Rarely performed nowadays, the Björk procedure is an alternative to the Fontan palliation for biventricular repair in patients with tricuspid atresia. The right atrium to right ventricle conduit failure leads to serious long-term complications. The management of such patients at high surgical risk remains challenging. We report a successful reoperation in a young adult 25 years after the modified Björk intervention, who presented with severely narrowed and calcified valved conduit.

Keywords: Bjork surgery, Fontan operation, tricuspid atresia

INTRODUCTION

Tricuspid atresia (TA) is a rare cyanotic congenital heart defect. The usual surgical approach is Blalock Taussig shunt or pulmonary artery banding soon after birth, followed by Glenn surgery at 3–6 months of age, and finally Fontan surgery at 2–3 years of age.

In 1979, Björk reported a procedure for TA by connecting the right atrium (RA) and the right ventricle (RV) in three patients with good clinical outcomes.^[1] The Fontan-Björk physiology seems to offer positive clinical and hemodynamic results from having pulsatile flow from the RV to the pulmonary artery, including fewer interventions for tachyarrhythmias and decreased cardiac decompensation compared with those with nonpulsatile flow.^[2] This modification was abandoned in favor of the total cavopulmonary connection, mostly due to stenosis/regurgitation over the atrioventricular connection and unfavorable hemodynamics.

The management of adult patients who have undergone the Björk procedure in the past surgical era is controversial.

CASE REPORT

The 30-year-old female patient born with Type IC TA presented with signs of a failing Fontan. She had undergone pulmonary artery banding in infancy, then at the age of 5, a modified Björk surgery which consisted in the ventricular septal defect closure and the placement of RA-RV 22mm Hancock valved conduit. She was then lost to follow-up until the age of 28 when she developed progressive exercise intolerance (NYHA Class II/III) and cyanosis (oxygen saturation of 82%). Her cardiac rhythm was sinus. Echocardiography showed dilated RA (54 cm²) and proximal conduit stenosis with a peak and mean gradient of 15 and 9 mmHg. Cardiac magnetic resonance imaging revealed RV end-diastolic volume of 42 mL/m² and ejection fraction of 44%. Catheterization showed peak pulmonary artery pressure of 36 mmHg and RA-RV end-diastolic gradient of 13 mmHg. Taking into account, the RV size and function, and good long-term clinical tolerance after Björk procedure in infancy, we decided to abandon Fontan conversion. Moreover, massive conduit calcification was unsuitable for percutaneous valve-in-valve treatment.

This is an open access journal, and articles are distributed under the terms of the Creative Commons Attribution-NonCommercial-ShareAlike 4.0 License, which allows others to remix, tweak, and build upon the work non-commercially, as long as appropriate credit is given and the new creations are licensed under the identical terms.

For reprints contact: WKHLRPMedknow_reprints@wolterskluwer.com

How to cite this article: Chatti S, Ghedira F, Mahfoudhi H, Mrad MB, Messai M, Nouar M, *et al.* Reoperation after modified Björk procedure for tricuspid atresia. *Ann Pediatr Card* 2021;14:530-2.

Access this article online

Quick Response Code:



Website:

www.annalspc.com

DOI:

10.4103/apc.apc_213_20

Address for correspondence: Dr. Sana Chatti, La Rabta Hospital, Jebal Lakhdar, 1007, Tunis, Tunisia.

E-mail: sanashatti@gmail.com

Submitted: 11-Sep-2020 Accepted: 02-Dec-2020 Published: 25-Mar-2022

The patient was operated through sternotomy with central cardiopulmonary bypass without aortic clamping. The calcified Hancock conduit was excised; the RA and RV openings were enlarged [Figures 1 and 2]. Adult size Hancock conduits as well as homografts were not available, so we decided to create a conduit by suturing a 31mm bioprosthesis inside a 30 mm Dacron tube [Figure 3]. The new conduit was then implanted to the RV and connected to the RA [Figure 4]. The postoperative course was uneventful and the inotropic support was stopped after 4 days. Echocardiography showed a nonobstructed flow through the conduit with no tricuspid regurgitation. She was put on anticoagulant therapy and discharged home. At 3-month follow-up, her clinical condition improved substantially and she remains asymptomatic.

DISCUSSION

In patients with Type IC TA, the Björk procedure offers the advantage of right ventricular growth and satisfying

biventricular function. Long-term complications occur because of the free regurgitant flow, calcification and/or stenosis of the conduit, RA dilatation, atrial arrhythmias, liver congestion, thromboembolism, and ventricular dysfunction.^[3] Currently, there are no guidelines for the management of such patients. The possible options as alternatives to transplant include percutaneous treatment, surgical removal of the obstruction, and conduit replacement or conversion to a total cavopulmonary connection.^[4-7]

In patients with sufficiently developed and well-functioning RV, the strategy to conserve Björk physiology seems reasonable. Patients who are not suitable for percutaneous valve implantation require surgery. Reintervention is often laborious and carries high risk of conduit disruption. Thus, femoral cannulation is often established before sternotomy. The calcified conduit is completely excised, the obstruction is removed, and the new valved tube is implanted. Several authors reported good short- and mid-term results after reoperation for calcified/stenotic RA-RV conduit.^[8,9]

In case of decreased RV function or difficulties to come off bypass, Fontan conversion with the creation of a

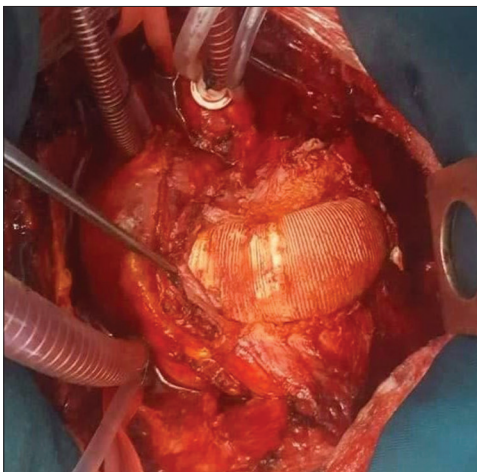


Figure 1: Calcified RA-RV Hancock conduit. RA: Right atrium, RV: Right ventricle

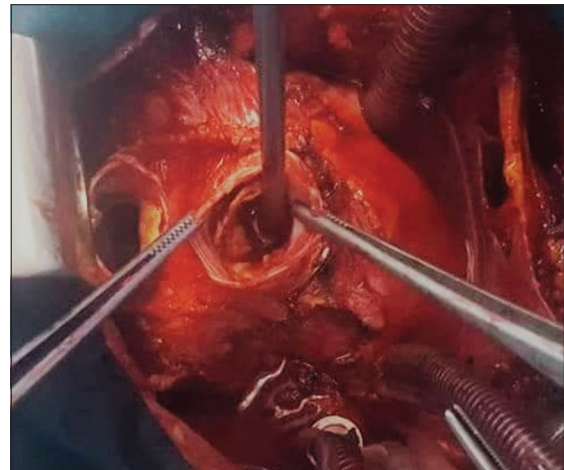

Figure 2: Massive valve calcification and narrowed anastomotic sites

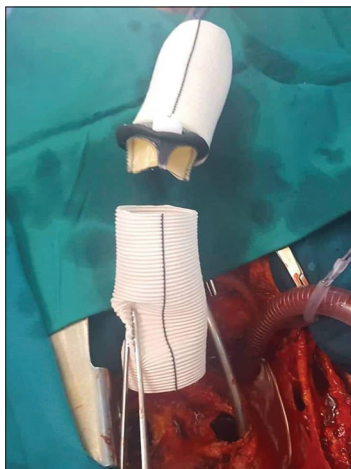


Figure 3: Bioprosthetic valve sutured inside the Dacron tube

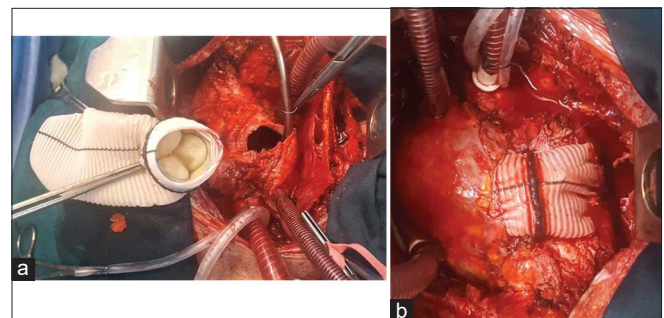


Figure 4: (a) Connection of the new conduit to the right atrium and the right ventricle. (b) Final result

1.5-ventricle circulation by creating a bidirectional Glenn anastomosis (superior vena cava to pulmonary artery) may be a good alternative. Hopkins *et al.*^[10] reported a successful 1,5 ventricle cure in a 42-year-old male after Björk surgery at the age of 9, with an RV size of 73 mL/m² and ejection fraction of 31%. In our case, the Fontan conversion option was not excluded, but hopefully, the patient had not presented RV failure postoperatively.

Furthermore, surgery offers the possibility to treat simultaneously tachyarrhythmias which are often associated with this pathology. Studies have shown that surgical treatment of arrhythmias at the time of Fontan conversion is superior to conversion without arrhythmia surgery.^[3]

CONCLUSION

Surgical replacement of RA-RV conduit rather than Fontan conversion can be performed in grown-up patients who underwent Björk connection if the RV size and function are adequate.

Declaration of patient consent

The authors certify that they have obtained all appropriate patient consent forms. In the form the patient(s) has/have given his/her/their consent for his/her/their images and other clinical information to be reported in the journal. The patients understand that their names and initials will not be published and due efforts will be made to conceal their identity, but anonymity cannot be guaranteed.

Financial support and sponsorship

Nil.

Conflicts of interest

There are no conflicts of interest.

REFERENCES

1. Bjork VO, Olin CL, Bjarke BB, Thorén CA. Right atrial-right ventricular anastomosis for correction of tricuspid atresia. *J Thorac Cardiovasc Surg* 1979;77:452-8.
2. Ono M, Vogt M, Cleuziou J, Kasnar-Samprec J, Burri M, Strbad M, *et al.* Improved exercise performance in patients with tricuspid atresia after the Fontan-Björk modification with pulsatile systolic pulmonary flow. *Ann Thorac Surg* 2016;101:1012-9.
3. Said SM, Burkhart HM, Schaff HV, Cetta F, Driscoll DJ, Li Z, *et al.* Fontan conversion: Identifying the high-risk patient. *Ann Thorac Surg* 2014;97:2115-21.
4. Huddleston CB. The failing Fontan: Options for surgical therapy. *Pediatr Cardiol* 2007;28:472-6.
5. Marcelletti CF, Hanley FL, Mavroudis C, McElhinney DB, Abella RF, Marianeschi SM, *et al.* Revision of previous Fontan connections to total extracardiac cavopulmonary anastomosis: A multicenter experience. *J Thorac Cardiovasc Surg* 2000;119:340-6.
6. Eicken A, Fratz S, Hager A, Vogt M, Balling G, Hess J. Transcatheter Melody™ valve implantation in 'tricuspid position' after a Fontan Björk (RA-RV homograft) operation results in biventricular circulation. *Int J Cardiol* 2010;142:45-7.
7. Baumgartner H, Bonhoeffer P, De Groot NM, de Haan F, Deanfield JE, Galie N, *et al.* Guidelines for the management of grown-up congenital heart disease (new version 2010). *Eur Heart J* 2010;31:2915-57.
8. Huang C, Gao L, Zhao T, Xu X, Yang Y. Modified Bjork procedure for tricuspid atresia with pulmonary hypertension. *J Card Surg* 2011;26:657-9.
9. Rybicka J, Kowalska M, Rózanski J, Hoffman P. Successful reoperation of the valveless calcified right atrium to right ventricle conduit in an adult patient with tricuspid atresia after Fontan procedure. *Eur J Cardiothorac Surg* 2012;41:18-20.
10. Hopkins KA, Brown JW, Darragh RK, Kay WA. Converting Fontan-Bjork to 1.5-or 2-ventricle circulation. *Ann Thorac Surg* 2019;107:259-61.