

Successful treatment of electrical storm in a child with early repolarization syndrome with orciprenaline and radiofrequency ablation

Yakup Ergül, Hasan Candaş Kafalı, Mustafa Gülgün
 Department of Pediatric Cardiology, Sağlık Bilimleri University
 İstanbul Mehmet Akif Ersoy Thoracic and Cardiovascular Surgery
 Training and Research Hospital; İstanbul-Turkey

Introduction

Early repolarization (ER) is a benign electrographic pattern and described as J-point elevation ≥ 1 mm in two or more adjacent inferior and/or lateral derivations, resulting in QRS slurring or notching (1-3). Some researchs have shown that ER might be one of the arrhythmogenic reasons for idiopathic ventricular fibrillation (VF) (1, 3). Here we present the case of a boy with inferolateral ER complicated by an electrical storm and treated with orciprenaline and radiofrequency ablation of the Purkinje network.

Case Report

A 14-year-old boy was referred to our center after having a survived sudden cardiac arrest at rest. The patient's electrocardiogram (ECG) yielded inferolateral ER (Fig. 1a). He had received an implantable cardioverter defibrillator (ICD; Medtronic Evera MRI SVR Sure scan) after the arrest, and mexiletine (3.5 mg/kg/day), sotalol (200 mg/m²), and metoprolol (1 mg/kg/day) had been prescribed because of three ICD shocks for VF. The device had been programmed VF only mode (with 35 joule) and no anti-tachycardia pacing. One month later, he experienced 14 shocks and 3 external defibrillations due to VF without success, despite amiodarone infusion (10 mg/kg/24 h) and taking mexiletine, sotalol, and metoprolol (Fig. 1b). Finally, orciprenaline infusion (0.03 mg/min) was started, which eliminated VF by increasing heart rate. In addition, disopyramide (6 mg/kg/day) was started. However, the patient experienced three shocks again when the orciprenaline dose was reduced. We decided to perform an electrophysiologic study for the ablation of premature ventricular contractions and the Purkinje fibers. The distal Purkinje fiber foci in the right and left ventricles were successfully ablated using an irrigated radiofrequency ablation catheter via the EnSite three-dimensional electroanatomic mapping system (St. Jude Medical, Inc.). The radiofrequency ablation (30 W, 43°C, 96–104 ohm) was implemented empirically in a linear style over 1–2 cm in the mid-right and mid-left ventricles at the site of presystolic Purkinje potentials without any complication (Fig. 2). Total procedure and fluoroscopy time were 210 and 24.7 min,

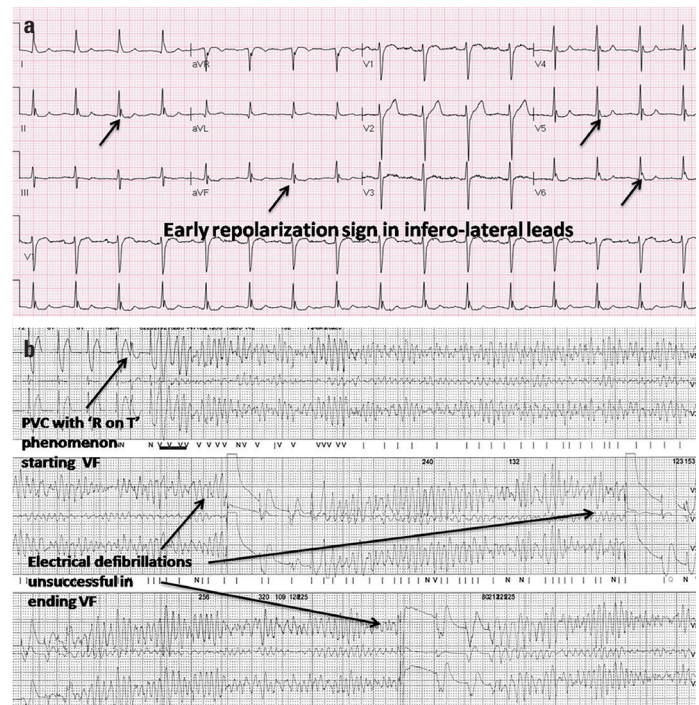


Figure 1. (a) The 12-lead surface electrocardiogram (ECG) on admission with the signs of malignant early repolarization in the inferolateral leads. (b) This Holter ECG record shows the episodes of ventricular fibrillation and implantable cardioverter defibrillator shocks in the pediatric intensive care unit

respectively. After the procedure, the J-point elevation on the ECG was almost disappeared (Fig. 3). The patient has remained symptom-free with quinidine (5 mg/kg/day) and amiodarone (5 mg/kg/day) for 5 months.

Discussion

Three types of ERs have been determined by Antzelevitch et al. (2) according to risk stratification. In type 1, ER is seen only in the lateral leads. It is common in healthy athletes and is usually benign regarding arrhythmias. In type 2, ER is seen in the inferolateral leads and is associated with a higher risk for malignant arrhythmias. Finally, type 3 is characterized by ER in the inferolateral plus anterior or right ventricular leads, and it is significantly associated with malignant dysrhythmias and electrical storms. In our patient, the ER pattern was probably similar to type 2.

Currently, the isoproterenol infusion or rapid cardiac pacing is the most useful treatment approach in the early phase of an electrical storm (4). The drug of choice for the long-term treatment of recurrent idiopathic VF is quinidine, an inhibitor of fast sodium channel (I_{Na}) (1, 4, 5). In our patient, we started with orciprenaline to control the electrical storm. Isoproterenol and orciprenaline are beta-adrenergic agonists, and both of them can decrease the electrical gradient and reduce the J-point elevation by activating I_{Ca} ; moreover, because heart rate can affect I_{Na} functions, these drugs may inhibit I_{Na} by accelerating heart rate, which results in normalization of repolarization abnormalities. Kyriazis et al. (6)

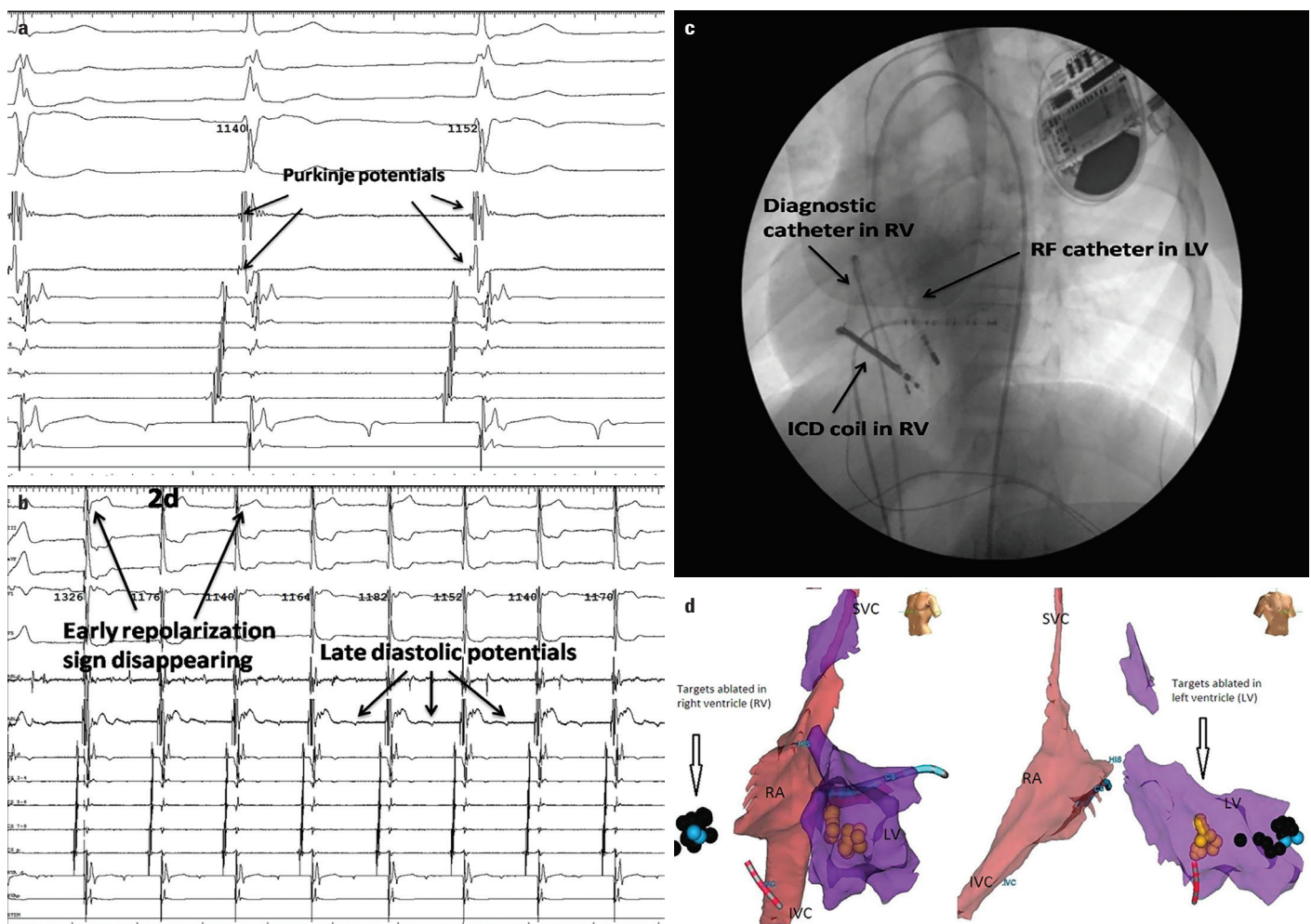


Figure 2. (a) This intracardiac record demonstrates the Purkinje potential before the ablation of the Purkinje network. (b) After the ablation, the J-point elevation almost disappeared in the 12-lead electrocardiogram and the late diastolic potentials from the ventricle were seen in the intracardiac record. (c) The fluoroscopy image shows the irrigated-tip radiofrequency ablation catheter in the left ventricle as well as the diagnostic catheter and the implantable cardioverter defibrillator coil in the right ventricle. (d) Three-dimensional mapping determining the ablated Purkinje potentials in the right (black points) and left (yellow points) ventricles

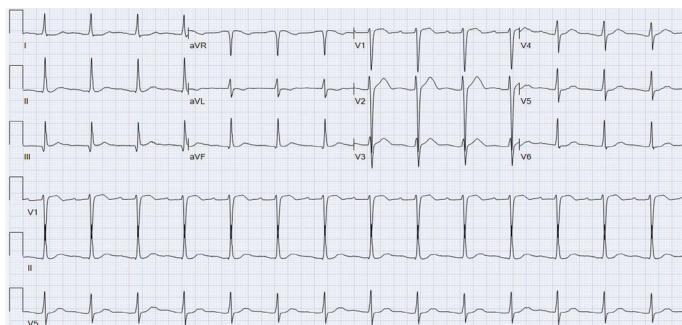


Figure 3. This surface electrocardiogram after the ablation shows no early repolarization characterized by the J-point elevation

have reported the effectiveness of orciprenaline in a 42-year-old patient with an electrical storm. Our case is the first report in terms of usefulness of orciprenaline for early treatment of electrical storm in a child.

Catheter ablation at experienced centers is useful for the treatment of idiopathic VF (7, 8). It has been shown that the

Purkinje network might be a driver for VF due to its feature of a very rapid burst activity, and the Purkinje–myocardial junction can be part of a re-entry circle (8). Unfortunately, we could not perform any voltage mapping regarding any scar or fibrosis due to lack of premature ventricular contractions, which was a limitation in our case. We successfully performed the Purkinje network ablation.

Conclusion

This pediatric case report shows the efficiency of orciprenaline infusion in the termination of recurrent VFs in the ER syndrome. In addition, the ablation of the distal Purkinje system seems feasible in a child with idiopathic VF triggered by ER.

Informed consent: Informed consent was obtained from the single patient described in this case report.

References

1. Badertscher P, Kuehne M, Schaer B, Sticherling C, Osswald S, Reichlin T. Case report: electrical storm during induced hypothermia in a patient with early repolarization. *BMC Cardiovasc Disord* 2017; 17: 277.
2. Antzelevitch C, Yan GX, Ackerman MJ, Borggrefe M, Corrado D, Guo J, et al. J-Wave syndromes expert consensus conference report: Emerging concepts and gaps in knowledge. *Europace* 2017; 19: 665-94.
3. Haïssaguerre M, Sacher F, Nogami A, Komiya N, Bernard A, Probst V, et al. Characteristics of recurrent ventricular fibrillation associated with inferolateral early repolarization role of drug therapy. *J Am Coll Cardiol* 2009; 53: 612-9.
4. Takahiro T, Kou S, Toshinobu Y, Yuichi H. Accidental hypothermia-induced electrical storm successfully treated with isoproterenol. *Heart Rhythm* 2015; 12: 644-7.
5. Priori SG, Wilde AA, Horie M, Cho Y, Behr ER, Berul C, et al. HRS/EHRA/APHRS expert consensus statement on the diagnosis and management of patients with inherited primary arrhythmia syndromes: document endorsed by HRS, EHRA, and APHRS in May 2013 and by ACCF, AHA, PACES, and AEPC in June 2013. *Heart Rhythm* 2013; 10: 1932-63.
6. Kyriazis K, Bahlmann E, van der Schalk H, Kuck KH. Electrical storm in Brugada syndrome successfully treated with orciprenaline; effect of low-dose quinidine on the electrocardiogram. *Europace* 2009; 11: 665-6.
7. Saba MM, Salim M, Hood RE, Dickfeld TM, Shorofsky SR. Idiopathic ventricular fibrillation in a 10-year-old boy: technical aspects of radiofrequency ablation and utility of antiarrhythmic therapy. *Pacing Clin Electrophysiol* 2011; 34: e85-9.
8. Knecht S, Sacher F, Wright M, Hocini M, Nogami A, Arentz T, et al. Long-term follow-up of idiopathic ventricular fibrillation ablation: a multicenter study. *J Am Coll Cardiol* 2009; 54: 522-8.

Address for Correspondence: Dr. Yakup Ergül,
İstanbul Mehmet Akif Ersoy Göğüs Kalp ve Damar Cerrahisi
Eğitim ve Araştırma Hastanesi,
Çocuk Kardiyoloji/Elektrofizyoloji Bölümü,
İstanbul-*Türkiye*

Phone: +90 212 692 20 00/4019

E-mail: yakupergul77@hotmail.com - yakupergul77@gmail.com

©Copyright 2019 by Turkish Society of Cardiology - Available online

at www.anatoljcardiol.com

DOI:10.14744/AnatolJCardiol.2019.37085

