The Korean Journal of Internal Medicine
Vol. 1, No. 2, July, 1986

Endoscopic Nd-YAG Laser Therapy for Gastric Polyp

Sun Moon Cheong, M.D., Duk Jhae Sun, M.D.
and Kyu Sung Rim, M.D.

Department of Internal Medicine,
Kang Nam Sacred Heart Hospital, Hallym University, Seoul, Korea

With the development of a special quartz fiberoptic transmission system, the application of laser energy through an endoscope became possible. Now, endoscopic laser therapy is widely used for gastrointestinal bleeding, and gastrointestinal neoplasm, and we have removed broad-based gastric polyps using an endoscopic Nd:YAG laser in 12 patients between January and December 1985.

The size of the polyps ranged from 0.2 cm to 1.0 cm in diameter. The most frequent location for the polyp was in the antrum (7 cases) and followed by the fundus (5 cases).

The application number of laser energy was from 6 to 58 and the small lesions of the 10 patients were completely ablated by the first endoscopic laser therapy.

Follow-up endoscopy in all patients revealed no new polyp formation, but all patients had a residual ulcer at the end of the first week postpolypectomy, and ulcers were healed by the fifth week of follow up.

Key Words: *Endoscopic Nd-YAG laser, Gastric polyp*

INTRODUCTION

Since the special quartz fiberoptic transmission system was developed, it is possible to apply laser energy through a flexible fiber endoscope.

After the first use of the endoscopic laser for the treatment of active gastrointestinal bleeding in 1975, by Fruhmorgen, endoscopic laser therapy has been widely used, not only for the treatment of acute gastrointestinal bleeding and non-bleeding gastrointestinal angiodysplasia, but also for the treatment of gastrointestinal neoplasm.

In our experience, the use of the endoscopic Nd-YAG laser for the removal of protruding, broad-based polyps of the stomach is efficient and safe.

SUBJECTS AND METHODS

Twelve patients with broad-based gastric polyps which protruded submitted to the removal of the polyps with an endoscopic Nd-YAG laser (Table 1).

The quartz fiber with a polyethylene sheath was guided through the biopsy channel of a prototype panendoscope, GIF-Q10, and GIF-2T. A filtering lens was attached to the eyepiece of the endoscope to prevent damage to the operator's eye from the laser beam.

Multiple 0.5 sec pulse irradiation of the Nd-YAG laser (Medilas YAG, Germany), with a power of 60 watts, at the tip of the quartz fiber were utilized. The flexible light guided assembly was quartz fiber with a diameter of 600 μm, a length of 3-4 m, and a divergence angle of 8.

The tip was positioned at a distance of about 1 cm from the lesion. The application number of laser energy was from 6 to 58 depending on the location and size of the lesion (Table 1).

After the laser application, an H_2 receptor antagonist (Ranitidine) for laser-induced ulcers was administered perorally for four weeks routinely, and all patients except one were submitted to a follow-up gastroscopy 1 week and 5 weeks after the laser application (Table 2).

Address reprint requests: Kyu Sung Rim M.D., Department of Internal Medicine, Kang Nam Sacred Heart Hospital, Hallym University, 948-1 Daelim Dong, Youngdeungpo Gu, Seoul 150, Korea

RESULTS

From January to November 1985, endoscopic Nd-YAG laser treatment was utilized to eradicate gastric polyp in 12 patients.

The male to female ratio was 1:1.4 (Male: 5, Female: 7), and ranging, in age from 34 to 70 with a mean of 50 years (Table 1).

The most frequent presenting symptoms initiating the diagnostic work up were epigastric discomfort, indigestion or nausea.

The presence of gastric polyp was confirmed by endoscopy and by upper gastrointestinal contrast study.

The most frequent location for the polyp was in the antrum (7 cases) and followed by the fundus (5 cases). Multiple polyps were noted in two cases and they were located in the body or antrum of the stomach.

The number of polyps of type I (Yamada classification) was 7, type II, 5; type III, 2; and type IV, 1 (Table 1).

The size of the lesions treated with the laser ranged from 0.2 cm to 1.0 cm in diameter.

The application number of laser energy was from 6 to 58, while the small lesions of the 10 patients were completely ablated by the first endoscopic laser therapy, the other two lesions of the two patients required repetitive laser treatment to achieve complete ablation of the lesion (Table 2).

During and after endoscopic laser therapy, no complication were encountered except for mild

Table 1. Gastroscopic Findings in Patients with Gastric Polyps

Patient	Sex/age	Location	Size (cm)	Yamada classification	Associated disease
L.K.N.	M/36	Lower body posterior wall	0.3×0.3×0.2	Y.II	
K.Y.K.	M/70	Lower antrum posterior wall	0.5×0.4×0.2	Y.II	Chronic atrophic gastritis
C.S.H.	F/37	1) Antrum greater curvature	0.3×0.3×0.5	Y.I	Chronic superficial gastritis
		2) Lower body	1.0×0.8×0.8	Y.II	
J.D.S.	F/54	Lower body anterior wall	0.3×0.2×0.5	Y.I	Chronic superficial gastritis
K.S.I.	M/34	Antrum anterior wall	0.3×0.3×0.5	Y.II	Acute superficial gastritis
L.H.B.	F/67	Antrum greater curvature	1)0.8×0.7×1.0	Y.IV	
			2)0.3×0.2×0.5	Y.I	
K.Y.S.	F/47	Antrum lesser curvature	0.5×0.5×0.3	Y.II	Adenocarcinoma signet ring cell type
J.K.O.	F/64	Mid-body greater curvature	0.3×0.2×0.3	Y.I	Chronic superficial gastritis
J.W.H.	M/40	Angle proximal part.	0.3×0.5×0.3	Y.III	Chronic hyperplastic gastritis
K.D.J.	F/55	Lower body greater curvature	0.6×0.6×0.5	Y.III	
N.Y.M.	M/60	1) Mid-body anterior wall	0.3×0.2×0.3	Y.I	Esophageal varix
		2) Antrum posterior wall	0.2×0.3×0.2	Y.I	
L.Y.S.	F/34	Antrum posterior wall	0.6×0.7×0.6	Y.I	

bleeding and occasional mild epigastric burning pain in the case of two of the patients.

Follow-up endoscopy in all patients, which was done at the ends of the first and fifth weeks after the laser application, revealed no new polyp formation or recurrence. All patients had residual ulcers at the end of the first week postopolypectomy, but all ulcers were healed by the end of the fifth week of follow-up (Table 2).

DISCUSSION

With the development of a flexible fiberoptic system, diagnostic and therapeutic endoscopy is

Table 2. Laser Application on Gastric Polyps and Follow-up Gastroscopic Findings

Patient	number of applications (60 watt, 0.5 set)	Gastroscopic findings after treatment	
		1 week later	5 weeks later
L.K.N.	21	Small ulcer with slight hyperemic margin (A2)	Red linear scar (S1)
K.Y.K.	58	Small ulcer crater with heaped-up margin (A1)	Elevated red scar (H2)
C.S.H.	1)7,5,6,6 2) 38	1) Small ulcer crater (A1) 2) Reapplication (43x)	White linear scar (S2)
J.D.S.	11	Ulcer with hyperemic heaped-up margin (A2)	Red scar (S1)
K.S.I.	32	Ulcer with hyperemic margin (A2)	Red linear scar (S1)
L.H.B.	50	Ulcer crater (A1)	White linear scar (S2)
K.Y.S.	26	Ulcer crater (A1)	Operation
J.K.O.	7	Small ulcer with hyperemic margin (A2)	White scar (S2)
J.W.H.	50	Ulcer with white coated floor (A1)	White scar (S2)
K.D.J.	57	Round ulcer covered with white floor (A1)	White linear scar (S2)
N.Y.N.	1) 12 2) 7	Ulcer crater (A1) Ulcer crater (A1)	Red linear scar (S1) White linear scar (S2)
L.Y.S.	27	Ulcer with marginal swelling (A1)	White linear scar (S2)

( ): Analysis of ulcer according to Sakita classification (A1, A2, H1, H2, S1, S2)

Table 3. Types of Medical Lasers

Laser medium	Type of medium	Operating wavelength (μm)	Power (W)	Applications
Ruby	Solid	0.69	1~1000	Ophthalmology
Krypton	Gas	0.65	0.5~2.0	Ophthalmology
Co_2	Gas	10.6	10~5000	Gynecology
He-Ne	Gas	0.63	0.001~0.1	Ophthalmology
Dye	Liquid	0.25~0.7	0.5~5.0	Microsurgery, ophthalmolgy
Argon	Gas	0.51/0.49/0.48	1.0~2.0	Ophthalmology
Nd:YAG	Solid	1.06/1.3	1~150	Gastroenterology, urology, bronchology, neurology, general surgery, dentistry, pulmonary, dermatology, ENT, gynecology

* (From reference 26)

playing a major role in the management of gastrointestinal polyps.[1-5]

The incidence of gastric polyps is low. A review of several studies has revealed the incidence of adenomatous polyps of the stomach to be 0.4%[6] to 0.7%.[7]

Although the term gastric polyp has been used to refer to any protrusion into the gastric lumen, recent experience has led to classification schemes based on topographic,[8] histologic,[9-12] and vital staing[13] criteria.

The most frequently encountered gastric polyp, hyperplastic or regenerative polyp, is reported to contain malignancy rarely. The incidence of malignant change in adenomatous polyp has been reported to be from 6 to 75 percent.[14] The malignant potential appears to be related to the size of the polyp, with larger adenoms (particulary

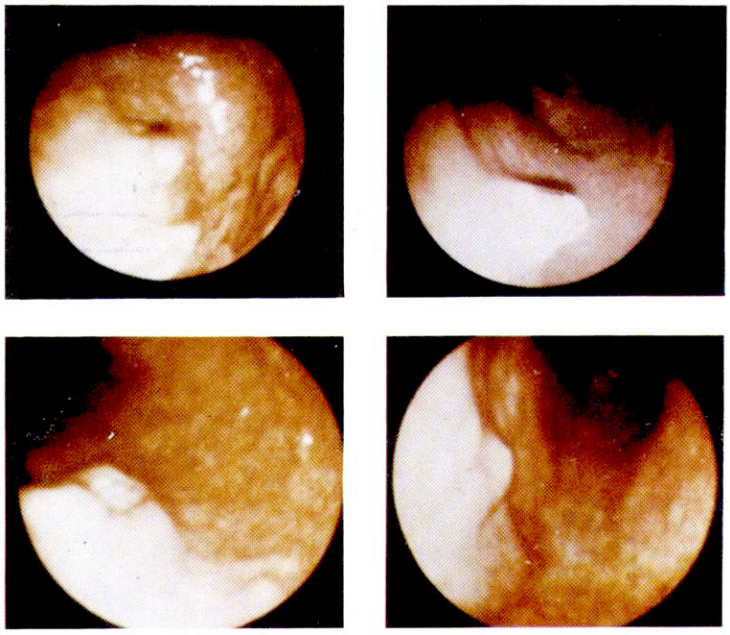

Fig. 1. *Gastroscopic finding of patient K.S.I*
- *Left upper: gastric polyp in antrum*
- *Right upper: just after laser application*
- *Left bottom: 1 week after laser application*
- *Right bottom: 5 weeks after laser application*

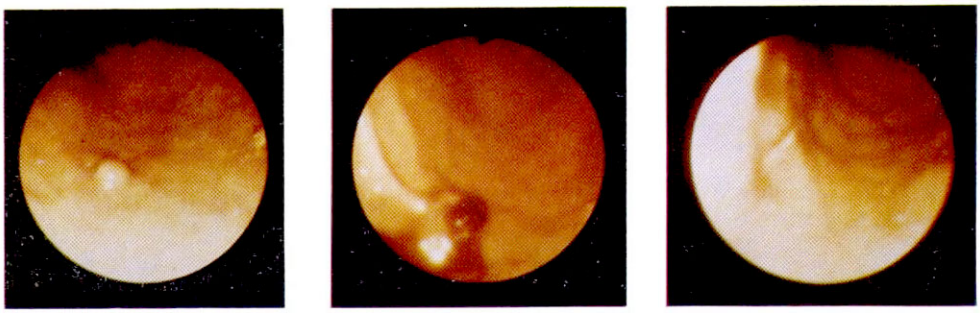

Fig. 2. *Gastroscopic finding of patient J.K.O.*
- *Left; gastric polyp in mid-body*
- *Center; 1 week after laser application*
- *Right; 5 week after laser application*

those greater than 2 cm) having a greater potential for malignant change.[15]

At the Mayo clinic, patients were offered endoscopic polypectomy if the gastric polyps had been diagnosed and they met one of the following criteria.[1]

1) Unchanged or enlarging gastric polyp on serial upper gastrointestinal contrast studies.
2) Expected noncomplaint patient follow-up.
3) Previous gastric surgical procedure with the presence of a new polyp.
4) A gastric polyp in a patient known to have pernicious anemia.

One of the known procedures for the ablation of gastric polyps by endoscope is electro-coagulation with a snare. The complications that can ensue from this snare excision method are bleeding, perforations and ulceration,[1,16] and broad based, protruding polyps (such as the Yamada classification type I or type II lesions) are technically difficult to excise by this method.

In the last few years, the use of endoscopic laser for the therapy of gastrointestinal disease has grown exponentially, due to its therapeutic benefit and safety.[17]

The Nd-YAG lasers are no longer thought of as being investigational for therapy. There are 3 main indications for their use:[18,19]

1) Acute gastrointestinal bleeding.
2) Non-bleeding gastrointestinal angiodysplasia.
3) Gastrointestinal neoplasm, where palliation is needed.

The application of the Nd-YAG laser in the treatment of gastrointestinal disorder is still in an evolutionary process.[18] One area of interest is the treatment of inoperable neoplasm of the esophagus, stomach, duodenum, and colon. Palliative therapy with an Nd-YAG laser is indicated for obstructing symptoms, bleeding from the malignancy, and tumor bulk.[18]

The Nd-YAG laser is effective in reducing the size of a mass. The patients with polyps of the gastrointestinal tract, also, have been successfully treated with it. Even benign sessile polyps can be successfully ablated, using it.[18-21]

The number of serious complications,[17] which

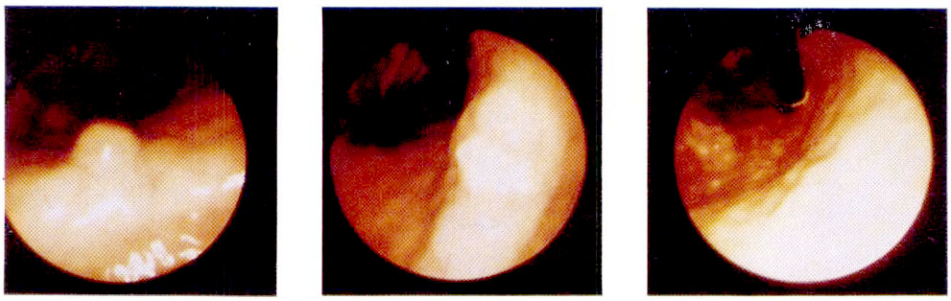

Fig. 3. *Gastroscopic finding of patient J.W.H.*
- *Left; gastric polyp in angle*
- *Center; 1 week after laser application*
- *Right; 5 weeks after laser application*

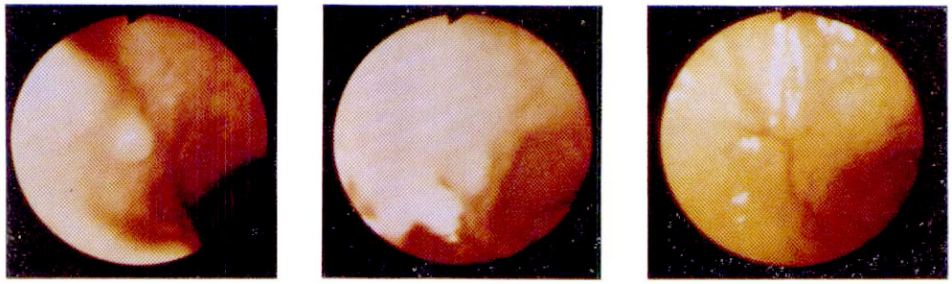

Fig. 4. *Gastroscopic finding of patient K.D.J.*
- *Left; gastric polyp in lower body*
- *Center; 1 week after laser application*
- *Right; 5 weeks after laser application*

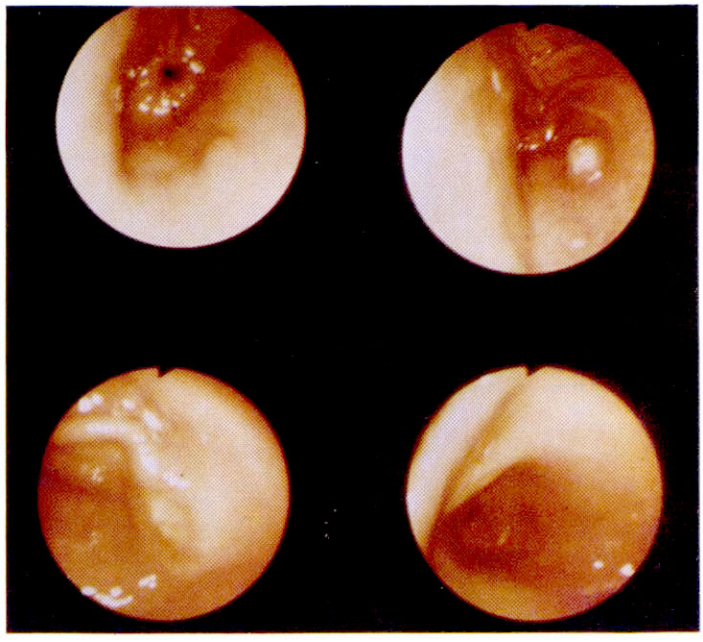

Fig. 5. *Gastroscopic finding of patient N.Y.M.*
- *Left upper: gastric polyp in antrum*
- *Right upper: just after laser application*
- *Left bottom: 1 week after laser application*
- *Right bottom: 5 weeks after laser application*

can occur during therapy with laser energy, have been impressively few.

Rosch and Fruhmorgen[22,23] have reported the efficacy of using the endoscopic argon laser for the gastric borderline lesions and early, protruding gastric carcinoma. Dixon et al.[22,24] also treated both gastric and rectal polyps by endoscopic argon laser photocoagulation.

However, there is a tendency toward using the Nd-YAG laser because of its greater power output.[22,25] Anthony A. Goossens and his fellow investigators[26] reported that the argon laser emits a beam which has lower surface absorption and tissue healing than other lasers, making it ideal for ophthalmological work where high surface tissue absorption is not desired and thermal coagulation at shallow depth is, but since Nd-YAG lasers emit a beam which has low surface absorption and penetrates tissue to more depth than the argon laser beam does, there is enough energy to overcome the dynamic condition of tissue to allow more deep thermal coagulation, tissue destruction, and tumor removal (Table 3).

Osamu Kato and his associates reported[22] a case of broad-based, protruding gastric borderline lesions, which was successfully treated, using the endoscopic Nd-YAG laser.

We ablated broad-based, protruding gastric polyps of 12 patients without complications, such as the bleeding or perforations, which can ensue from snare excision.

We, therfore, emphasize that endoscopic Nd-YAG laser therapy is an effective and safe method of treatment for ablation of broad-based, protruding polyps of the stomach.

However, long term follow up study should be done, because laser therapy precludes a total biopsy.

REFERENCES

1. Rollin WHJ: *Gastric polyp and polypectomy. Gastrointestinal Endoscopy 30:101, 1984*
2. Tsuneoka K, Uchida T: *Endoscopic polypectomy*

of the stomach. Second World Congress of Gastrointestinal Endoscopy. Copenhagen 1970

3. Burns D, Jacobs WH: *Endoscopic electrosurgical polypectomies of the upper gastrointestinal tract. South Med J 70:926, 1977*
4. Gaisford W: *Gastrointestinal polypectomy via the fiberendoscope. Arch Surg 106:458, 1973*
5. Papp JP: *Electrosurgical advances in upper gastrointestinal endoscopy. Am J Gastroenterol 66:248, 1976*
6. Stewart MJ: *Observations on the relation of malignant disease to benign tumors of the gastrointestinal tradt Br Med J 2:267, 1929*
7. Lawrence JC: *Gastrointestinal polyps a statistical study of malignancy incidence. Am J Surg 31: 499, 1936*
8. Yamada T: *Polypoid lesions of the stomach. Stomach Intestinal 1:145, 1966*
9. Tomasuco J: *Gastric polyps. Cancer 27:1346, 1971*
10. Morson BC: *Pathology of the gastrointestinal tract. Curr Topics Pathol 63:77, 1976*
11. Si-Chun Ming: *The classification and significance of gastric polyps. Monogr Pathol 18: 149, 1977*
12. Hay LJ: *Surgical management of gastric polyps and adenocarcinoma. Surgery 39:114, 1956*
13. Bowden L: *Adenocarcinoma in a small gastric polyp: a case report. Cancer 15:468, 1962*
14. Ming S: *The classification and significance of gastric polyps. International academy of pathology Monoraph: The Gastrointestinal Tract 99:149, 1977*
15. Tomasulo J: *Gastric polyps Histologic types and their relationship to gastric carcinoma. Cancer 27:1946, 1971*
16. Seifert E, Elster K: *Gastric polypectomy Am J Gastroentero 63:451, 1975*
17. David F: *Who should use laser therapy and how should they learn. Gastrointestinal Endoscopy 30:113, 1984*
18. Victor WG: *Nd-YAG laser therapy of gastrointestinal tumors. Gastrointestinal Endoscopy 30: 311, 1984*
19. Kiefhaber P, Kiefhaber K: *Present endoscopic laser therapy in the gastrointestinal tract. Gastroenterology 85:439, 1983*
20. Brunetaud JM, Mosquet L, Bourez J: *Laser application in nonhemorrhagic digestive lesions. Excerpta Medica 455, 1983*
21. Lamber R, Sabben G: *Laser therapy in colorectal tumors. Gastroenterology 84:1223, 1983*
22. Kato O, Kazuhiko Hattorik, Tarashi Suzzukit, Kaxnki Yoshio K, Shimizu Y: *Endoscopic Nd-YAG laser therapy for gastric border line lesions. Gastrointestinal Endoscopy 30:77, 1984*
23. Rosch W, Fruhmorgen P: *Endoscopic treatment of precancerosis and early gastric carcinoma. Endoscopy 12:109, 1980*
24. Dixon JA, Burt RW, Rotering RH, McCloskey DW: *Endoscopic argon laser photocoagulation of sessile colonic polyps. Gastrointest Endoscopy 27:133, 1981*
25. Fleischer D: *The current status of gastrointestinal laser activity in the United States. Gastrointest Endoscopy Ph D: Fundumentals of medical lasers. Gastrointestinal Endoscopy 30: 75, 1984*