

Fusobacterium Nucleatum: Atypical Organism of Pyogenic Liver Abscess Might be Related to Sigmoid Diverticulitis

Karn Wijarnpreecha, Nataliya Yuklyaeva, Suthanya Sornprom, Charles Hyman

Department of Internal Medicine, Bassett Medical Center, Columbia University College of Physicians and Surgeons, New York, USA

Abstract

Context: Pyogenic liver abscesses (PLAs) are the most common form of liver abscesses in the United States. Most cases are caused by enteric bacteria and anaerobes. We report a case of PLA caused by a rare pathogen, *Fusobacterium nucleatum*, from an unusual primary site of infection. **Case Report:** A 60-year-old male presented with subacute fever. Initial work-up revealed leukocytosis and elevated alkaline phosphatase (ALP). Dental examination and Panorex x-ray were normal. Imaging of the liver with abdominal computed tomography demonstrated a 5.5 cm abscess in the right lobe of the liver. Culture of the aspirate grew *Fusobacterium nucleatum*. He improved with abscess drainage and antibiotic therapy with moxifloxacin and metronidazole. Colonoscopy performed a few weeks later, demonstrated sigmoid ulceration most likely from the previous diverticulitis. **Conclusion:** PLAs can be a complication of sigmoid diverticulitis and as a result of occult dental disease as well. The clinical presentation of *Fusobacterium* infection is diverse and can be fatal if diagnosis is delayed. Therefore, early diagnosis and treatment are the keys to preventing serious complications.

Keywords: Diverticulitis, fusobacterium nucleatum, oral infection, pyogenic liver abscess

Address for correspondence: Dr. Karn Wijarnpreecha, One Atwell Road, Cooperstown - 13326, New York, USA.
E-mail: dr.karn.wi@gmail.com

Introduction

While amebic liver abscesses are commonly found worldwide, pyogenic liver abscesses (PLAs) are the most common form of liver abscess in the United States. The treatment requires early drainage and proper antibiotics. If diagnosis is delayed or if they are left untreated, they can lead to high mortality and morbidity.^[1] *Fusobacterium nucleatum* has been reported to be a rare cause of PLA especially in immunocompromised patients with recurrent periodontal infection. It is an anaerobic gram-negative organism which is considered normal flora in the human oral cavity. The organism is recognized well

to be presented with infectious thrombophlebitis of the internal jugular vein or history of periodontal infection.^[2] We present an immunocompetent patient diagnosed with PLA caused by *Fusobacterium nucleatum* with an unusual site of infection.

Case Presentation

A 60-year-old man with a history of hypertension presented to the hospital with subacute subjective fever

Access this article online

Quick Response Code:



Website:
www.najms.org

DOI:
10.4103/1947-2714.179961

This is an open access article distributed under the terms of the Creative Commons Attribution-NonCommercial-ShareAlike 3.0 License, which allows others to remix, tweak, and build upon the work non-commercially, as long as the author is credited and the new creations are licensed under the identical terms.

For reprints contact: reprints@medknow.com

How to cite this article: Wijarnpreecha K, Yuklyaeva N, Sornprom S, Hyman C. *Fusobacterium nucleatum*: Atypical organism of pyogenic liver abscess might be related to sigmoid diverticulitis. North Am J Med Sci 2016;8:197-9.

with flu-like symptoms (headache, fatigue, decreased appetite). In addition, he had left hip pain without significant limited activity. He denied cough, nausea, vomiting, diarrhea, abdominal pain, or other abnormal symptoms. At first presentation, vital signs were as follows: Body temperature 36.3°C, blood pressure 130/71 mmHg, respiratory rate 16, heart rate 75, and 98% oxygen saturation in room air. Physical examination revealed no dental caries or poor oral hygiene, no abnormal lung or heart sounds, normal abdominal exam, no extremities, edema, or swelling, left hip tenderness without limited range of motion, redness, or swelling. Initial labs demonstrated leukocytosis with left shift, elevation of erythrocyte sedimentation rate, alkaline phosphatase (ALP), gamma-glutamyl transferase (GGT). Serology of hepatitis B, C, or human immunodeficiency virus came back negative. Initially, we suspected that the source of infection could be from the left hip due to abnormal finding from physical exam. We performed left hip arthrocentesis. However, synovial fluid did not show abnormal finding that suggest of inflammatory or infectious process. According to elevated GGT, which is more specific to hepatobiliary origin than bone, we decided to do ultrasonography of the liver. The test revealed a lobulated hypoechoic 5.9 cm lesion in the right lobe of the liver. Abdominal computed tomography scan revealed an ill-defined lobulated hypodensity right lobe of liver lesion up to 5.5 cm and sigmoid diverticulitis [Figure 1]. The diagnosis of liver abscess was made. Blood culture and intravenous infusion of piperacillin/tazobactam were initiated. Percutaneous drainage was performed. The final report from the abscess culture showed *Fusobacterium nucleatum*. Serial blood culture showed no organism. Panorex was negative for dental abscess. After drainage of the abscess, the fever resolved and clinically the patient improved significantly. The patient developed rash after initiated piperacillin/tazobactam on day 3. We switched antibiotic to ertapenem for two doses and then switched to oral moxifloxacin 400 mg daily and metronidazole 500 mg three times daily for 10 days. The patient was discharged with metronidazole 500 mg for 3 weeks. Repeat imaging during outpatient follow-up revealed complete resolution of liver abscess after treatment without hepatic vein thrombosis. The follow-up colonoscopy in the next 6 weeks showed numerous medium-to-large descending and sigmoid colon diverticuli; one site in the sigmoid has ulceration and erythema, most likely the site of the previous diverticulitis. Biopsy of subcentimetal cecal polyp and 9 mm of rectal polyp revealed tubular adenoma with no malignancy seen.

Discussion

PLAs are more common than amebic liver abscess in developed countries. A previous study reported

the incidence of PLA in the United States is 3.6 out of 100,000 people, with increased annual average percent in incident being 4.1% from 1994 to 2005.^[1] Patients with delayed treatment or percutaneous drainage have been shown to have increased morbidity and mortality.^[1] The sequence of PLA secondary to rupture of acute appendicitis has been reported.^[3] Occasionally, PLA occurred from surgical or penetrating wounds. Recently, a study demonstrated the significant change in etiology of PLA, which is predominantly caused by *Klebsiella pneumoniae* and occurred in patients with underlying hepatobiliary disease that spread directly from biliary infection.^[4] However, *Fusobacterium nucleatum* was reported in the previous 14 cases.^[2,5-16] Twelve of the cases were immunocompromised. The other two cases were reported in immunocompetent patients, one with history of dental caries,^[10] and one in a healthy young man.^[2] Mostly PLAs were caused by polymicrobial infection; the causative organism in our case was only *Fusobacterium*. Immunodeficiency or periodontal disease are demonstrated in more than half of the patients with liver abscesses containing this bacteria. Our case demonstrated the first instance of immunocompetent PLA without a history of periodontal infection and coincident with sigmoid diverticulitis, which was presumed to be the source of PLA via hematogenous spreading. The translocation of this pathogen from the colon to the liver in the rectal carcinoma has been previously reported.^[17,18] The proposed mechanism is the breakdown of the colonic mucosa secondary to ulceration of diverticulitis leading to bacteremia. Most of the cases that reported *Fusobacterium* with PLA mentioned the association between this organism and infectious thrombophlebitis of the internal jugular vein or history of periodontal infection. Although the true mechanism of PLA caused by *Fusobacterium* is still unknown, the hematogenous spreading was thought to be the pathogenesis of this condition. Many studies demonstrated that *Fusobacterium nucleatum* may be linked with the risk of colorectal carcinoma.^[16-18] The follow-up colonoscopy in the first patient showed only tubular adenoma with no malignancy.

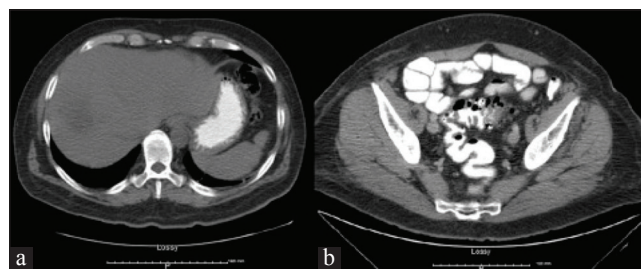


Figure 1: (a left) Abdominal CT scan showed ill-defined lobulated hypodensity in the dome of the right lobe of liver measuring 4.5 cm × 3.4 cm × 5.5 cm consistent with liver abscess (b right) CT scan showed marked thickening of the proximal sigmoid colon with diverticula compatible with diverticulitis. That may be the source of the patient's liver abscess

Interestingly, our cases presented with atypical clinical manifestation of PLA, with none of the usual risk factors associated with PLA (diabetes, underlying hepatobiliary or pancreatic disease, or liver transplant),^[19-21] and no specific signs or symptoms of abdominal findings. Of note, the suggestion of liver and biliary etiologies of the cases was an elevation of ALP and GGT. ALP is known to be a sensitive marker of liver abscess and this pointed our investigation toward liver imaging. Early diagnosis and treatment is the key to prevent complications such as bacteremia, necrosis of the liver tissue, and significant mortality from this condition. The spectrum with *Fusobacterium* species is broad and causes high mortality if diagnosis is delayed. The early percutaneous drainage and appropriate antibiotics played a major role in the treatment of PLA. To our best knowledge, we report the first case of PLA with *Fusobacterium* that might be secondary to sigmoid diverticulitis.

Conclusion

We presented a case of immunocompetent PLA caused by *Fusobacterium nucleatum*, most likely secondary to sigmoid diverticulitis, as the source of the infection. Even though it rarely occurs, awareness of PLA complication after sigmoid diverticulitis should be accentuated to the physician. This case emphasized that physicians should suspect liver abscess with *Fusobacterium* infection even in immunocompetent patients without specific abdominal presentation. Early drainage and proper antibiotic treatment have been shown to significantly reduce mortality.

Financial support and sponsorship

Nil.

Conflicts of interest

We do not have any financial or nonfinancial potential conflicts of interest.

References

- Meddings L, Myers RP, Hubbard J, Shaheen AA, Laupland KB, Dixon E, *et al.* A population-based study of pyogenic liver abscesses in the United States: Incidence, mortality, and temporal trends. *Am J Gastroenterol* 2010;105:117-24.
- Ahmed Z, Bansal SK, Dhillon S. Pyogenic liver abscess caused by *Fusobacterium* in a 21-year-old immunocompetent male. *World J Gastroenterol* 2015;21:3731-5.
- Bonner K, Passi Y, Depaz H. Liver abscess secondary to acute appendicitis: How a chicken bone started it all. *Am Surg* 2014;80:E320-1.
- Rahimian J, Wilson T, Oram V, Holzman RS. Pyogenic liver abscess: Recent trends in etiology and mortality. *Clin Infect Dis* 2004;39:1654-9.
- Ala A, Safar-Aly H, Millar A. Metallic cough and pyogenic liver abscess. *Eur J Gastroenterol Hepatol* 2001;13:967-9.
- Crippin JS, Wang KK. An unrecognized etiology for pyogenic hepatic abscesses in normal hosts: Dental disease. *Am J Gastroenterol* 1992;87:1740-3.
- Etienne M, Gueit I, Abboud P, Pons JL, Jacquot S, Caron F. *Fusobacterium nucleatum* hepatic abscess with pylephlebitis associated with idiopathic CD4(+) T lymphocytopenia. *Clin Infect Dis* 2001;32:326-8.
- Gertsch P, Diserens H, Mosimann R. Superinfected actinomycotic abscess of the liver. *Int Surg* 1985;70:39-40.
- Jermini I, Luethy R, Gubler J. An unusual case of hepatic abscess. *Praxis (Bern 1994)* 2004;93:1781-4.
- Kajiya T, Uemura T, Kajiya M, Kaname H, Hirano R, Uemura N, *et al.* Pyogenic liver abscess related to dental disease in an immunocompetent host. *Intern Med* 2008;47:675-8.
- Le Roux K, Sève P, Gomard E, Boibieux A, Beziat C, Stankovic K, *et al.* Lemierre syndrome variant: Hepatic abscesses and hepatic venous thrombosis due to *fusobacterium nucleatum* septicemia. *Rev Med Interne* 2006;27:482-6.
- Mémmain N, Arvaniti K, Bruneel F, Lepout C, Wolff M, Regnier B. Septic shock with liver abscess in an immunocompetence patient. Presentation of an unusual *fusobacterium nucleatum* infection. *Presse Med* 2001;30:1777-9.
- Scouler A, Corcoran GD, Malin A, Evans BA, Davies A, Miller RF. *Fusobacterium nucleatum* bacteraemia with multiple liver abscesses in an HIV-I antibody positive man with IgG2 deficiency. *J Infect* 1992;24:321-5.
- Tweedy CR, White WB. Multiple *fusobacterium nucleatum* liver abscesses. Association with a persistent abnormality in humoral immune function. *J Clin Gastroenterol* 1987;9:194-7.
- Wells CD, Balan V, Smilack JD. Pyogenic liver abscess after colonoscopy in a patient with ulcerative colitis. *Clin Gastroenterol Hepatol* 2005;3:xxiv.
- Young EJ, Harper WK, Taylor RL. Hepatic necrobacillosis. Report of a case resembling metastatic tumor. *Arch Intern Med* 1977;137:804-7.
- Castellarin M, Warren RL, Freeman JD, Dreolini L, Krzywinski M, Strauss J, *et al.* *Fusobacterium nucleatum* infection is prevalent in human colorectal carcinoma. *Genome Res* 2012;22:299-306.
- Warren RL, Freeman DJ, Pleasance S, Watson P, Moore RA, Cochrane K, *et al.* Co-occurrence of anaerobic bacteria in colorectal carcinomas. *Microbiome* 2013;1:16.
- Chan KS, Chen CM, Cheng KC, Hou CC, Lin HJ, Yu WL. Pyogenic liver abscess: A retrospective analysis of 107 patients during a 3-year period. *Jpn J Infect Dis* 2005;58:366-8.
- Huang CJ, Pitt HA, Lipsett PA, Osterman FA Jr., Lillemoe KD, Cameron JL, *et al.* Pyogenic hepatic abscess. Changing trends over 42 years. *Ann Surg* 1996;223:600-9.
- Thomsen RW, Jepsen P, Sørensen HT. Diabetes mellitus and pyogenic liver abscess: Risk and prognosis. *Clin Infect Dis* 2007;44:1194-201.