

Ruxolitinib, a JAK1/2 Inhibitor as Treatment for Paraneoplastic Pemphigus: A Case Report

Birao FAN¹⁻³ and Mingyue WANG^{1-3*}¹Department of Dermatology, Peking University First Hospital, Beijing 100034, ²National Clinical Research Center for Skin and Immune Diseases and ³Beijing Key Laboratory of Molecular Diagnosis on Dermatoses, Beijing, China. *E-mail: wangmy@pku.edu.cn

Accepted May 23, 2022; Epub ahead of print May 23, 2022

Acta Derm Venereol 2022; 102: adv00732. DOI: 10.2340/actadv.v102.1378

Paraneoplastic pemphigus (PNP) is a severe bullous autoimmune condition associated with neoplasms. Blisters and suprabasal acantholysis are usually evident in histology. Because PNP mimics many autoimmune blistering diseases, several immunological assays have been developed to better detect different PNP antibodies and facilitate differential diagnosis. Among them, anti-desmoglein (Dsg) 3 IgG on enzyme-linked immunoassay (ELISA), indirect immunofluorescence (IIF) on rat bladder, and immunoprecipitation or immunoblotting show antibodies against Dsg and/or plakins display high sensitivity or specificity, playing important roles in diagnostic criteria for PNP (1, 2). Skin lesions of PNP can usually be controlled by systemic glucocorticoid with or without immunosuppressant after tumorectomy. In some cases, mucosal lesions are recalcitrant to standard combination therapy. Multi-organ manifestations can present bronchiolitis obliterans (BO), myasthenia gravis, and gastrointestinal bleeding, of which irreversible BO with progressive respiratory failure is one of the leading death causes in patients with PNP (1–3). Ruxolitinib, an oral selective inhibitor of the Janus kinase 1/2 (JAK 1/2), because of its pivotal role in inflammation and activation of T cells, was reported to be effective in the treatment of steroid-refractory graft-versus-host disease (SR-GVHD) (4). The similarity between GVHD and PNP pathogenically and clinically led us to propose ruxolitinib as a putative option for persistent stomatitis and BO in a post-operative patient with PNP.

without other autoimmune or respiratory conditions or relevant family history. Physical examination revealed multiple erosive lesions on the buccal mucosa and tongue, and blisters on the hands, vulva, and the vermilion border of the lips. The oral erosion was biopsied, showing dyskeratosis with suprabasal acantholysis. Anti-Dsg 3 antibody level was 40.95 U/ml. IIF on rat bladder was 1:10 positive. Immunoblotting showed that her sera reacted with the 210-kDa envoplakin and the 190-kDa periplakin. Prednisolone was administered, at an initial dose of 30 mg, and, later, cyclosporine, at 200 mg daily, but the bullae and erosion barely improved. Even worse, she gradually developed dyspnoea and wheezing, despite taking a 3-month course of azithromycin. Pulmonary function examination demonstrated expiratory volume in 1 s (FEV1) was 0.73 L, FEV1 in percent predicted values (FEV1%pred), and FEV1/forced volume vital capacity ratio (FEV1/FVC) were 26.3% and 30.2%, respectively. Combined with a high-resolution computed tomography image showing airway wall thickening and bronchiectasis, the patient was diagnosed with BO. Surgical removal of the tumour was performed, and pathology confirmed Castleman's disease (CD). Steroid administration was decreased to 10 mg daily, together with ciclosporin 100 mg daily. Post-operative lung function showed FEV1 0.74 L, FEV1%pred 28.3%, and FEV1/FVC 30.9%. The appearance on the skin showed consistent healing, but there was no notable improvement in oral lesions and respiratory function.

Six months after the operation, the patient still experienced dyspnoea with painful ulceration on the right lingual margin (Fig. 2a). As a result, combined therapy with ruxolitinib, 5 mg once daily, was initiated. After 2 weeks, ruxolitinib was increased to 5 mg twice a day with good tolerance, and ciclosporin was tapered to 50 mg per day. Within 2 months, the patient reported an improvement in symptoms. Evaluations at clinic visits confirmed marked regression of the oral lesions, with FEV1 0.78 L, FEV1%pred 29.5%, and FEV1/FVC 31.6%. After 4 months, the patient returned with negative IIF and decreased antibody of Dsg 3 (5.87 IU/ml). The ulcer on the tongue had almost disappeared (Fig. 2b), and respiratory assessment showed FEV1 0.89 L, FEV1%pred 33.6%, FEV1/FVC 40.2%. Recurrent symptoms were not observed for 15 months after the initiation of ruxolitinib.

CASE REPORT

A 31-year-old woman was diagnosed with PNP and retroperitoneal mass 3 years previously (Fig. 1). She was otherwise healthy

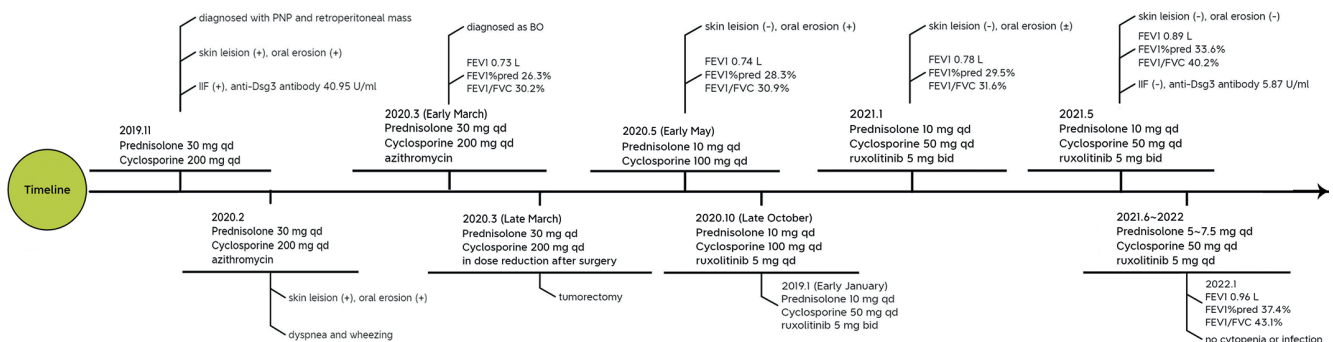


Fig. 1. Timeline of the event with symptoms and treatments listed. Dsg: desmoglein; qd: once a day; bid: twice a day; PNP: paraneoplastic pemphigus; BO: bronchiolitis obliterans; IIF: indirect immunofluorescence; FEV1: expiratory volume in one second; FEV1%pred: FEV1 in percent predicted values; FEV1/FVC: FEV1/forced volume vital capacity ratio.

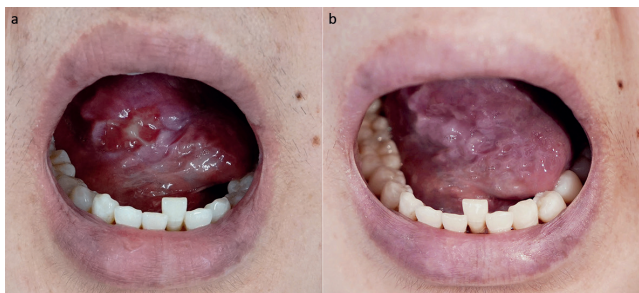

Fig. 2. Ulceration on the right lingual margin (a) before JAK inhibitor (JAKi) treatment, (b) with visible improvement after 4 months of treatment with ruxolitinib and reduction of cyclosporine from 100 to 50 mg per day.

DISCUSSION

Although the pathogenesis of PNP is not completely clear, it is plausible that both autoantibodies and cell-mediated immunity dominate in the disorder. Patients develop IgG autoantibodies against Dsg 1/3 and proteins of the plakin family, which induce loss of cell adhesion between keratinocytes and cause subsequent blister formation. Meanwhile, cell-mediated cytotoxicity attacks proteins in different layers of the epidermis, and more intractable stomatitis are seen compared with classic forms of pemphigus (1). Moreover, Dsg 3-specific T cells could not only help B cells produce anti-Dsg 3 IgG, but also infiltrate into the epidermis and induce an interface dermatitis in the mice model (5). Because mucosal lesions are usually resistant to prednisolone and immunosuppressive regimen, intravenous immunoglobulin, plasmapheresis, rituximab, and other monoclonal antibody agents were used in selected patients (1). However, due to the high cost and inconvenience of these emerging therapies, they are not widely accepted. On the other hand, PNP could also damage the respiratory epithelium, causing a series of respiratory complications, among which BO is strongly related to a worse prognosis despite treatment of the underlying malignancy (1–3).

The JAK family is essential in mediating cytokine signalling by phosphorylation of downstream signal transducer and activator of transcription (STAT) proteins, guiding differentiation and function of inflammatory cells (6). Due to the vital role of JAK1/2-STAT3 pathways on T cells activation, JAK 1/2 inhibitor may inhibit donor alloreactive T-cell expansion and inflammatory cytokine production, inflammation, tissue damage, and fibrosis (7). Accordingly, some members of the JAK inhibitor (JAKi) family, such as baricitinib and tofacitinib, showed benefits in mucous membrane pemphigoid (8, 9). Furthermore, JAKi could keep chemokines and other profibrotic factors from accumulating in the airway, blocking macrophage infiltration and collagen deposition, decelerating airway remodelling, and obstruction (6, 10). Ruxolitinib, the oral JAK 1/2 inhibitor, was the first JAKi approved for use in myelofibrosis by the US Food and Drug Administration (FDA) and European

Medicines Agency (EMA) in 2011. Currently, it is used as salvage therapy for SR-GVHD, especially in cases with BO and oral involvement (11, 12).

There are several significant similarities between PNP and GVHD, such as the common pathogenesis (mainly mediated by cellular immunity and pathogenic antibodies), tissues with strong heterogeneity *in vivo* (tumour or human leukocyte antigens), dermatological manifestations (present as blisters, erythema multiforme-like, and lichen planus-like lesions, and hyperpigmentation), and multi-organ involvement (with BO as a fatal complication) (2, 3, 13). Collectively, we considered the potent immunosuppressive and anti-inflammatory activities of JAKi might be valuable for the management of BO in this case of intractable PNP. As there are several reports and studies describing the high efficacy and favourable survival of ruxolitinib in the treatment of SR-GVHD, we chose ruxolitinib over the isoinhibitor baricitinib or tofacitinib, the JAK 1/3 inhibitor.

It is known that ruxolitinib might increase the incidence of cytopaenia and infections (14, 15). Thus, screening for haemocytopaenia and infectious events should be done before and during JAKi treatment and combined with anti-infection therapy before initiation of ruxolitinib for those at high risk (14). Fortunately, no severe adverse effects were noted for the current patient in subsequent years.

We believe that the off-label use of JAKi could provide a promising therapy for patients with autoimmune bullous disease, particularly when conventional agents are ineffective. However, further research is necessary into the underlying mechanism, safety, and efficacy of JAKi with long-term use in PNP.

The authors have no conflicts of interest to declare.

REFERENCES

- Paolino G, Didona D, Magliulo G, Iannella G, Didona B, Mercuri SR, et al. Paraneoplastic pemphigus: insight into the autoimmune pathogenesis, clinical features and therapy. *Int J Mol Sci* 2017; 18: 2532.
- Wang M, Li F, Wang X, Wang X, Wang R, Yang Y, et al. Features and risk factors for paraneoplastic autoimmune multiorgan syndrome in 145 Chinese patients. *Acta Derm Venereol* 2020; 100: adv00312.
- Ouedraogo E, Gottlieb J, de Masson A, Lepelletier C, Jachiet M, Salle de Chou C, et al. Risk factors for death and survival in paraneoplastic pemphigus associated with hematologic malignancies in adults. *J Am Acad Dermatol* 2019; 80: 1544–1549.
- Zeiser R, Burchert A, Lengerke C, Verbeek M, Maas-Bauer K, Metzelder SK, et al. Ruxolitinib in corticosteroid-refractory graft-versus-host disease after allogeneic stem cell transplantation: a multicenter survey. *Leukemia* 2015; 29: 2062–2068.
- Takahashi H, Kouno M, Nagao K, Wada N, Hata T, Nishimoto S, et al. Desmoglein 3-specific CD4+ T cells induce pemphigus vulgaris and interface dermatitis in mice. *J Clin Invest* 2011; 121: 3677–3688.
- McLornan DP, Pope JE, Gotlib J, Harrison CN. Current and future status of JAK inhibitors. *Lancet* 2021; 398: 803–816.
- Spoerl S, Mathew NR, Bscheider M, Schmitt-Graeff A, Chen S, Mueller T, et al. Activity of therapeutic JAK 1/2 blockade in graft-versus-host disease. *Blood* 2014; 123: 3832–3842.

8. Sarny S, Hucke M, El-Shabrawi Y. Treatment of mucous membrane pemphigoid with janus kinase inhibitor baricitinib. *JAMA Ophthalmol* 2018; 136: 1420–1422.
9. James H, Paley GL, Brasington R, Custer PL, Margolis TP, Paley MA. Tofacitinib for refractory ocular mucous membrane pemphigoid. *Am J Ophthalmol Case Rep* 2021; 22: 101104.
10. Barker AF, Bergeron A, Rom WN, Hertz MI. Obliterative bronchiolitis. *N Engl J Med* 2014; 370: 1820–1828.
11. Zhao Y, OuYang G, Shi J, Luo Y, Tan Y, Yu J, et al. Salvage therapy with low-dose ruxolitinib leads to a significant improvement in bronchiolitis obliterans syndrome in patients with cGVHD after allogeneic hematopoietic stem cell transplantation. *Front Pharmacol* 2021; 12: 668825.
12. Kaurinovic M, Delli K, Jonk AE, Biswana A, Hazenberg CLE, Choi G, et al. Effect of ruxolitinib on the oral mucosa of patients with steroid-refractory chronic graft-versus-host disease and oral involvement. *Clin Oral Investig* 2022; 26: 4209–4216.
13. Ferrara JL, Levine JE, Reddy P, Holler E. Graft-versus-host disease. *Lancet* 2009; 373: 1550–1561.
14. Wang D, Liu Y, Lai X, Chen J, Cheng Q, Ma X, et al. Efficiency and toxicity of ruxolitinib as a salvage treatment for steroid-refractory chronic graft-versus-host disease. *Front Immunol* 2021; 12: 673636.
15. Lussana F, Cattaneo M, Rambaldi A, Squizzato A. Ruxolitinib-associated infections: a systematic review and meta-analysis. *Am J Hematol* 2018; 93: 339–347.