

# Hereditary hemorrhagic telangiectasia diagnosed by enteroscopy: a case report

Journal of International Medical Research  
49(12) 1–5

© The Author(s) 2021


Article reuse guidelines:

sagepub.com/journals-permissions

DOI: 10.1177/03000605211067391

journals.sagepub.com/home/imr



**Margarita Rey, Johana Milena Salazar,  
Drixie Dalyla Leal, Fernando Sierra,  
Erika Pérez, Jose De la Hoz,  
Gustavo Adolfo Reyes and  
Mariana Vásquez Roldán** 

## Abstract

Hereditary hemorrhagic telangiectasia (HHT) is a very rare autosomal dominant multisystemic disease. Patients with this disease usually present with punctate mucocutaneous telangiectasias and arteriovenous malformations. The diagnostic criteria currently in use are the Curaçao criteria. HHT is considered a clinical diagnosis; thus, no imaging or preclinical laboratory is mandatory, and diagnosis and management are performed according to the experience of the treating team. We herein describe a 58-year-old man with no significant medical history who presented with a 15-day history of intermittent hematochezia. He was admitted to the hospital and underwent a series of laboratory tests, including colonoscopy, which showed normal results. Therefore, the patient was discharged with a diagnosis of gastrointestinal bleeding. During his second visit to the emergency room, the doctors requested video capsule endoscopy because of the patient's history, and a diagnosis of HHT was made. The entire approach and treatment were completed with antegrade double-balloon enteroscopy. This case highlights the importance of endoscopic methods for timely diagnosis and proper management.

## Keywords

Telangiectasia, hereditary hemorrhagic, arteriovenous malformation, endoscopy, balloon enteroscopy, case report

Date received: 22 June 2021; accepted: 29 November 2021

Fundación Santa Fe de Bogotá, Bogotá, D.C. Colombia

### Corresponding author:

A.M. Rey Rubiano, Gastroenterology and Digestive  
Endoscopy Department, Fundación Santa Fe de Bogotá,  
Avenue 116 # 7-75, Bogotá 110111, Colombia.  
Email: margaritareyl@hotmail.com



## Introduction

Hereditary hemorrhagic telangiectasia (HHT), also known as Osler–Weber–Rendu syndrome, is a rare autosomal dominant multisystemic vascular disease. The estimated worldwide prevalence ranges from 1/5000 to 1/8000; however, the prevalence is higher in some regions, such as the Jura region in France, the island of Funen in Denmark, and the Netherlands Antilles of the Caribbean.<sup>1</sup>

Patients with HHT have elevated levels of vascular endothelial growth factor and transforming growth factor beta, which affect angiogenesis. Characteristic vascular lesions are punctate mucocutaneous telangiectasias and arteriovenous malformations that affect organs such as the lungs, liver, and brain. Telangiectasias close to the surface of the membranes can often bleed with mild trauma; thus, spontaneous nosebleed (epistaxis) is the cardinal symptom. In addition, gastrointestinal bleeding can occur, affecting approximately 25% of patients, most of whom are in their 50s. The diagnostic criteria currently in use are the Curaçao criteria, which are composed of four clinical elements: epistaxis, telangiectasia, visceral lesions, and a family history of HHT in a first-degree relative. Beyond these clinical criteria, there are no mandatory imaging or laboratory tests; therefore, doctors do not have a gold standard or diagnostic algorithm.<sup>2</sup>

Moreover, despite the medical community's clear knowledge of the symptoms and genes associated with HHT, a definitive cure is lacking; only palliative measures and pharmacological trials are available. The goals of treatment are control of symptoms and prevention of bleeding complications. We herein present a clinical case of HHT to show the importance of a timely diagnosis. This is crucial because HHT is a rare condition with a low prevalence in countries such as Colombia, where

many doctors do not initially suspect it. Furthermore, we emphasize the importance of enteroscopy in the exploration of small bowel disease even when the disease is rare. Finally, we discuss the different types of therapeutic approaches for patients with HHT.<sup>3</sup>

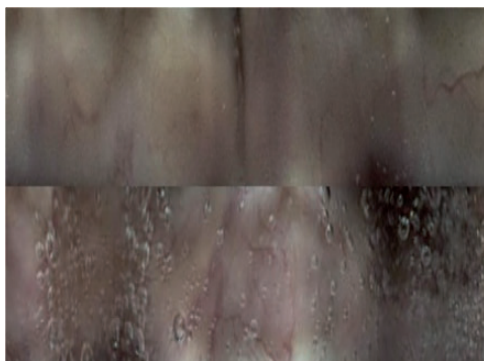
## Case report

This case is reported in accordance with the CARE checklist.<sup>4</sup> A 58-year-old man with no significant pathological history presented with a 15-day history of intermittent hematochezia associated with asthenia, adynamia, palpitations, and dizziness with positional change. In addition, deterioration of New York Heart Association functional class III/IV heart failure was detected. He had a family history of two brothers with Osler–Weber–Rendu syndrome, diagnosed after 50 years of age, and a brother with cavernous sinus venous thrombosis with a positive prothrombin gene mutation.

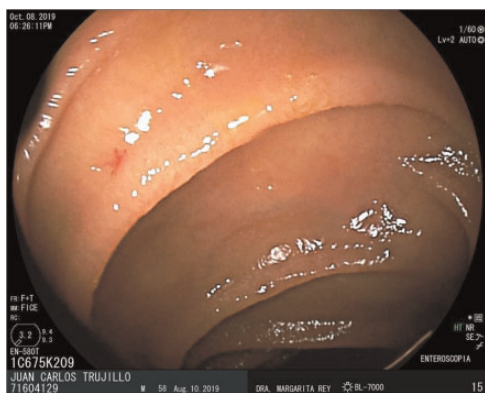Physical examination showed a hemodynamically stable patient, mucocutaneous paleness with conjunctival hypochromia, wet oral mucosa with evidence of telangiectatic-type lesions on the tongue, no thoracic or abdominal abnormalities, and normal findings of a digital rectal examination without bleeding or dilation. A hemogram revealed a leukocyte count of  $5 \times 10^3/\mu\text{L}$ , neutrophil count of  $2.5 \times 10^3/\mu\text{L}$ , lymphocyte count of  $1.9 \times 10^3/\mu\text{L}$ , monocyte count of  $0.5 \times 10^3/\mu\text{L}$ , hemoglobin concentration of 11.3 g/dL, hematocrit of 36.6%, mean corpuscular volume of 88.3 fL, mean corpuscular hemoglobin concentration of 31 g/dL, red blood cell distribution width of 12.9%, and platelet count of  $185 \times 10^3/\mu\text{L}$ . The patient was hospitalized with a diagnosis of lower digestive tract bleeding and hypochromic microcytic anemia. Colonoscopy and endoscopy

findings were normal, and the patient was discharged.

Because of persistent symptoms with rectal bleeding episodes, he was readmitted to the hospital and scheduled for capsule endoscopy (Figure 1). The video capsule showed findings of angiodysplasia lesions in the proximal midgut. We therefore decided to perform antegrade double-balloon enteroscopy, during which angiectasis was found in the distal duodenum (Figure 2). The areas of angiectasis were sclerosed with argon plasma (Figure 3(a) and (b)) without complications and with excellent



**Figure 1.** Endoscopic video capsule images showing angiodysplasia lesions.



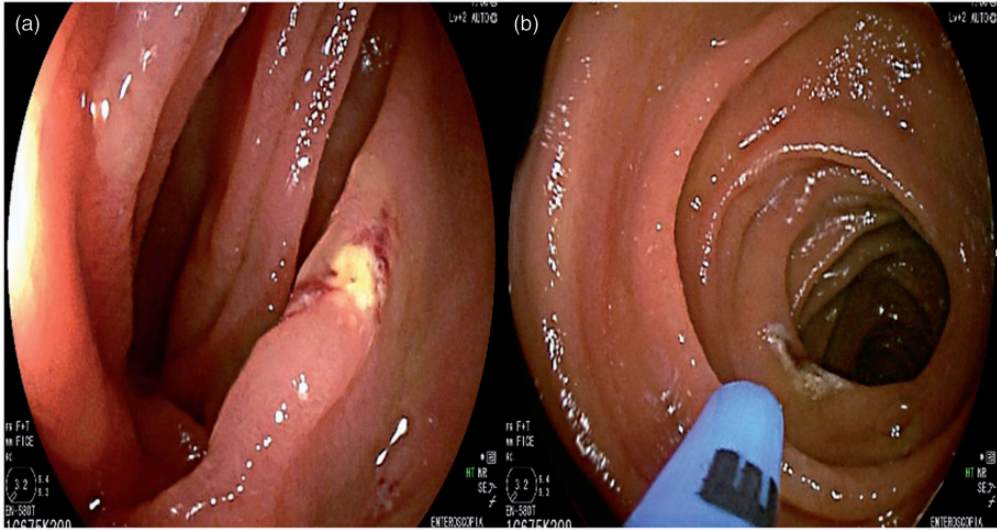
**Figure 2.** Antegrade double-balloon enteroscopy findings of angiodysplastic lesions in the proximal middle intestine.

results, after which the patient was discharged without evidence of new bleeding or anemia. Outpatient follow-up with the internal medicine and gastroenterology departments was performed with clear recommendations and education regarding warning signs. At the time of this writing, the patient was in good health condition without new bleeding episodes or the need for new interventions.

## Discussion

Identification of HHT is challenging because of its rarity, variations in clinical manifestations, difficulties in achieving a diagnosis through imaging examinations or genetic tests, and low clinical suspicion among physicians. A timely diagnosis is essential because the morbidity and mortality of affected patients increase proportionally with age.<sup>4</sup> In the present case, the diagnosis was made on the second emergency visit through capsule video endoscopy and antegrade double-balloon enteroscopy, which are essential to visualize and treat lesions.<sup>1</sup> Capsule endoscopy has been shown to have a better diagnostic capacity for arteriovenous malformations in patients with HHT; therefore, this technique should be used in the study of bleeding of unknown origin because it is a minimally invasive procedure. Therapeutic enteroscopy can then be used to manage the injuries.

Pharmacological therapies are used alone or in combination with endoscopic therapy. Given the variability of clinical manifestations, there is no standard treatment; the premise of personalized medicine must be followed with reliance on the experience of the referring physician.<sup>2</sup> Therapeutic options include estrogen-progestins, danazol, tamoxifen, thalidomide, lenalidomide, interferon 2 beta, sirolimus, octreotide, aminocaproic or tranexamic acid, and bevacizumab. Octreotide is considered a therapy with the fewest



**Figure 3.** (a) Antegrade double-balloon enteroscopy. (b) Antegrade double-balloon enteroscopy with use of argon plasma for sclerosis of angiectasis.

adverse effects that can be used as a rescue drug in patients with active bleeding.<sup>5,6</sup> The choice of any of the above therapies depends on each patient, their possible related adverse effects, and the consideration that little experimental evidence is available.<sup>7</sup>

Although our patient developed no complications or new bleeding episodes, it is important to continue investigating this disease. Studies of gastrointestinal management are scarce, and although the diagnosis was made promptly in our case, HHT is still seldom suspected because of its low prevalence.<sup>8</sup> Therefore, further studies are required to determine the most appropriate therapy according to the manifestations. The present case shows that inclusion of endoscopic images can be helpful as a diagnostic and therapeutic approach.

### Consent to publish

Written informed consent was obtained and included the patient's authorization to

publish his case, images, and medical history. The consent form was duly signed by the patient and the responsible doctor.

### Authors' contributions

DDL, JMS, and MRR contributed to the conception of the case report; acquisition, analysis, and interpretation of the data; and writing of the case report. EPR, MVR, and JDH contributed to the acquisition of the data and the writing and translation of the case report. MRR and FS contributed to the critical revision of the case report. All authors read and approved the final manuscript.

### Availability of data and materials

We confirm that all the information present in the manuscript is stored in the REDCap repository managed by the institution and will be provided upon the request of the journal or any interested party.

### Ethics approval

The present study was approved by the Institutional Committee of Ethics in Research on 28 May 2021.

## Declaration of conflicting interest

The authors declare that there is no conflict of interest.

## Funding

This research received no specific grant from any funding agency in the public, commercial, or not-for-profit sectors.

## ORCID iD

Mariana Vásquez Roldán  <https://orcid.org/0000-0002-5230-145X>

## References

1. Albiñana V, Cuesta AM, de Rojas-P I, et al. Review of pharmacological strategies with repurposed drugs for hereditary hemorrhagic telangiectasia related bleeding. *J Clin Med* 2020; 9: 1766. Available from: <https://www.ncbi.nlm.nih.gov/pmc/articles/PMC7356836/>
2. Bernabeu C, Bayrak-Toydemir P, McDonald J, et al. Potential second-hits in hereditary hemorrhagic telangiectasia. *J Clin Med* 2020; 9: 3571. Available from: <https://www.ncbi.nlm.nih.gov/pmc/articles/PMC7694477/>
3. Elawad OAMA, Albashir AAD, Mirghani Ahmed MM, et al. Hereditary hemorrhagic telangiectasia in a Sudanese patient. *Case Rep Med* 2020; 2020: 6395629. Available from: <https://www.ncbi.nlm.nih.gov/pmc/articles/PMC7752298/>
4. Gagnier JJ, Kienle G, Altman DG, et al. The CARE guidelines: consensus-based clinical case reporting guideline development. *Headache* 2013; 53: 1541–1547.
5. Kritharis A, Al-Samkari H and Kuter DJ. Hereditary hemorrhagic telangiectasia: diagnosis and management from the hematologist's perspective. *Haematologica* 2018; 103: 1433–1443.
6. Kühnel T, Wirsching K, Wohlgemuth W, et al. Hereditary hemorrhagic telangiectasia. *Otolaryngol Clin North Am* 2018; 51: 237–254.
7. Singh K, Zubair A, Prindle A, et al. Diagnostic yield of capsule endoscopy for small bowel arteriovenous malformations in patients with hereditary hemorrhagic telangiectasia: a systematic review and meta-analysis. *Endosc Int Open* 2019; 7: E282–E289.
8. Jackson SB, Villano NP, Benhammou JN, et al. Gastrointestinal manifestations of hereditary hemorrhagic telangiectasia (HHT): a systematic review of the literature. *Dig Dis Sci* 2017; 62: 2623–2630.