

A Cosmetic Surgical Approach Effectively Reconstructed Facial Nerve Paralysis

Shunichi Nomoto, MD, PhD*

Hiroki Umezawa, MD, PhD†

Rei Ogawa, MD, PhD*

Summary: In general, facial nerve palsy is treated by reconstructive surgeons, and the role of cosmetic surgeons is largely seen as secondary. The present report describes a case of refractory facial nerve palsy that arose after malignant parotid-tumor resection and high-dose radiotherapy, and that we reconstructed with a combination of cosmetic and reconstructive procedures. The procedures consisted of facelift techniques (lateral SMASectomy, creation of a nasolabial fold with three suture loops anchored at the temporal fascia, and frontal lift), a new wrinkle-removing technique wherein the frontal-muscle function was disrupted, and excision of surplus skin to rejuvenate the face. The outcomes were good, including at 1 year after surgery, and the 71-year-old patient expressed considerable satisfaction. The frontalis muscle resection effectively removed the wrinkles, helped balance the left and right sides, and permitted anti-aging surgery. This procedure has permanent effects, unlike other methods (eg, botulinum-toxin injections) that serve to weaken facial muscle function. It is notable that despite the high-dose radiotherapy the patient had received and the resulting extensive subcutaneous-tissue adhesion, our surgical protocol was relatively easy to perform as well as highly effective. Thus, even static reconstruction can give great hope and satisfaction to patients with facial nerve palsy. (*Plast Reconstr Surg Glob Open* 2021;9:e3452; doi: [10.1097/GOX.0000000000003452](https://doi.org/10.1097/GOX.0000000000003452); Published online 22 June 2021.)

INTRODUCTION

In general, facial nerve palsy is treated by reconstructive surgeons; the role of cosmetic surgeons is seen as secondary. Here, we describe a case of refractory facial-nerve palsy after malignant parotid tumor resection and radiotherapy that we treated with a combination of cosmetic and reconstructive procedures. The protocol mainly consisted of facelift techniques with an additional innovation, namely wrinkle-removing frontalis-muscle resection. The results were good, and the patient was very satisfied. The merits of our approach are discussed.

PATIENT AND SURGICAL METHODS

One year earlier, the patient, a 71-year-old woman, underwent resection of a malignant right parotid tumor

followed by vascularized nerve transfer with anterolateral thigh flap reconstruction and then high-dose radiotherapy/chemotherapy. The radiotherapy damaged the facial soft tissue and the transferred nerve, causing refractory right-facial palsy. Just before secondary surgery, the facial nerve palsy of the patient was classified as Grade V, according to the House-Brackmann classification (Fig. 1).

The basic surgical concept in secondary surgery was to lift the palsied side with a facelift, while releasing healthy frontal-muscle hypertonia (Fig. 1). Thus, the right mid-lower face was subjected to lateral SMASectomy. Thereafter, to create the right-nasolabial fold, buried subcutaneous threads were placed at three locations along the nasolabial fold and anchored at the temporal fascia; tightening of the three loops suspended the fold (Fig. 2). The incision line was then extended along the hairline to the healthy side of the head, and frontal lifting was performed. The skin incision was conducted according to Camirand et al¹: it was a follicular oblique incision, with the scalpel lying at 45 degrees. The frontalis muscle on the healthy side was resected after harvesting the skin-muscle flap (Fig. 3). The left and right eyebrow heights were adjusted by not raising the healthy sides of the eyebrows. Finally, all surplus skin was excised to rejuvenate the entire area. Single lateral canthopexy was performed for right ectropion.

From the *Department of Plastic, Reconstructive and Aesthetic Surgery, Nippon Medical School, Tokyo, Japan; and †Research Laboratory for Magnetic Resonance, Nippon Medical School, Tokyo, Japan.

Received for publication September 17, 2020; accepted December 28, 2020.

Copyright © 2021 The Authors. Published by Wolters Kluwer Health, Inc. on behalf of The American Society of Plastic Surgeons. This is an open-access article distributed under the terms of the [Creative Commons Attribution-Non Commercial-No Derivatives License 4.0 \(CCBY-NC-ND\)](https://creativecommons.org/licenses/by-nc-nd/4.0/), where it is permissible to download and share the work provided it is properly cited. The work cannot be changed in any way or used commercially without permission from the journal.

DOI: [10.1097/GOX.0000000000003452](https://doi.org/10.1097/GOX.0000000000003452)

Disclosure: All the authors have no financial interest to declare in relation to the content of this article.

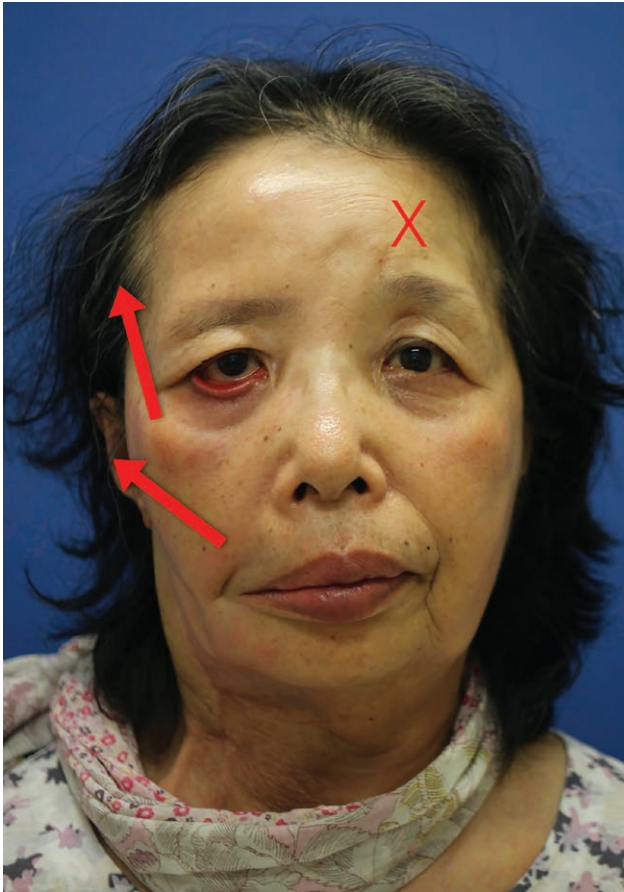


Fig. 1. Preoperative view showing the basic concept underlying our surgical approach. The affected side of the face was lifted with SMASectomy and soft-tissue lift with a traction system (red arrows). Thereafter, the frontal muscle function on the healthy side was disrupted (red X mark). The aesthetic balance of the facial expression was also adjusted by manipulating the eyebrows.

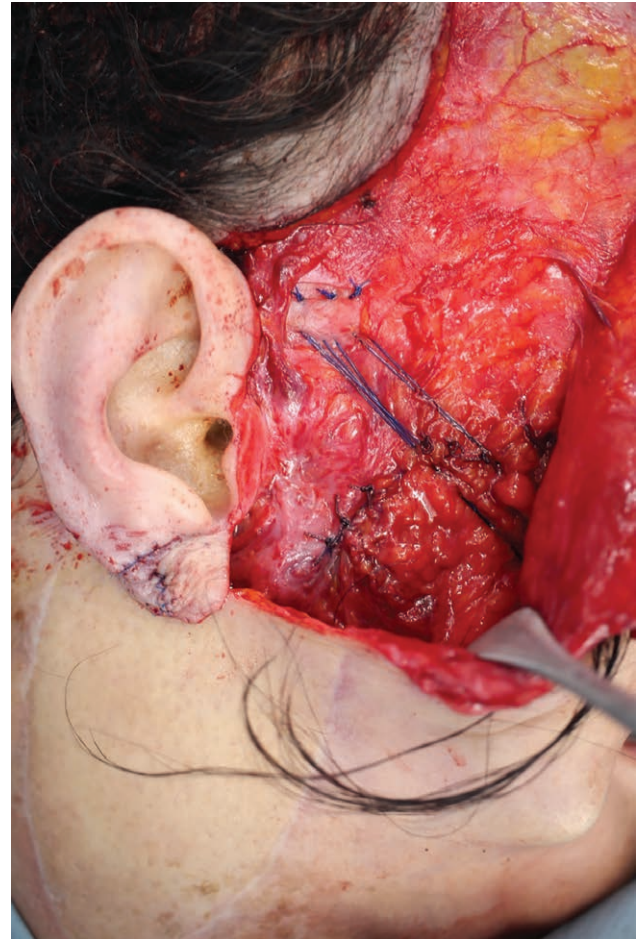

Fig. 2. Facelifting procedure. A lateral SMASectomy was performed, after which soft tissue lift was conducted by immersing the traction system along the skin of the nasolabial fold, attaching it to the temporal fascia, and then lifting it in a loop.

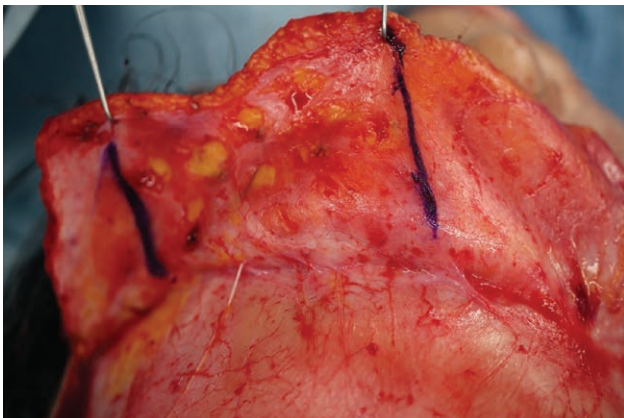


Fig. 3. Forehead lift procedure. After elevating the flap, only the frontal muscle on the healthy side was removed. After it was completely removed, the cut end of the muscle bulged and stood out near the eyebrows, leaving many small windows and the frontal muscle in a grid pattern.

RESULT OF SURGERY

During secondary surgery, almost half of the patient's face was carefully undermined. Because the subcutaneous tissue exhibited considerable radiation-induced adhesion, some areas required some effort. Nevertheless, compared with the preoperative period, the patient's appearance was markedly improved (Fig. 4). Frontalis muscle resection eliminated the wrinkles on the left side, thereby improving upper facial-expression symmetry and the eyebrow positions. Excess forehead skin excision had a significant antiaging effect. The periorbital area was also improved in terms of upper eyelid skin laxity and lower eyelid ectropion. According to the House-Brackmann classification, the facial paralysis improved to Grade III/IV. The patient expressed considerable satisfaction with the results.

DISCUSSION

In general, plastic surgery for advanced facialnerve palsy prioritizes dynamic reconstruction procedures such as nerve grafting, anastomosis, and muscle transfer; static reconstruction surgery that involves lifting the eyebrow or changes the mouth angle is seen as secondary surgery.

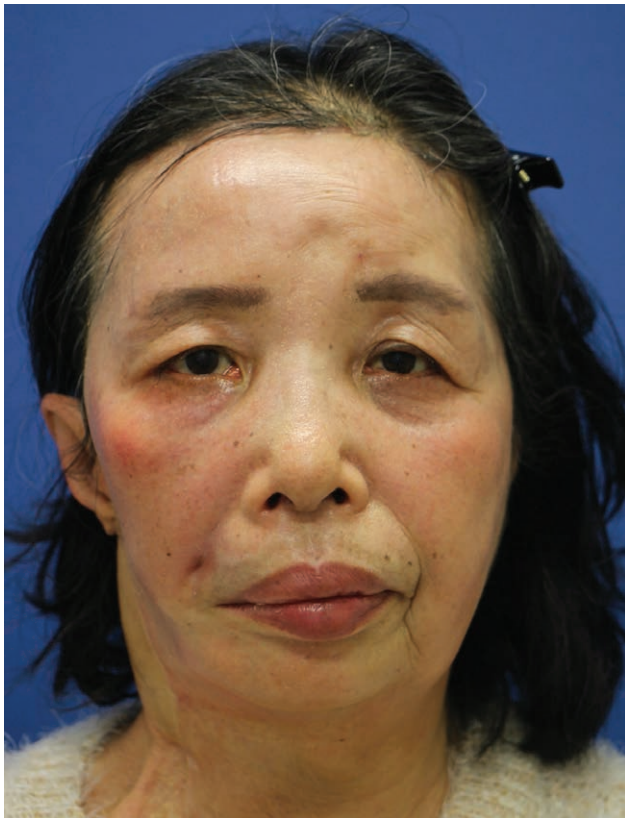


Fig. 4. Photograph of the patient trying to elevate her eyebrows 1 year after surgery. The left and right facial expressions were well-balanced even 1 year after the operation. The right and left sides were symmetrical because the eyebrows cannot be elevated, even when the patient was seeking to do so.

However, our case of postoperative radiation-induced refractory facial palsy shows that although static reconstructive surgery is a palliative method, it can also greatly improve the appearance of the patient's face, thereby significantly augmenting patient well-being. We therefore suggest that cosmetic surgery can be useful for advanced facial-nerve palsy cases that have a history of malignant-tumor resection and/or radiotherapy.

Facelift is not a new static reconstruction procedure for facial nerve palsy.² However, in the present case, we devised a new method for balancing the right and left expression muscles, namely combining frontal-forehead lift with almost entire resection of the healthy frontalis muscle. The resection satisfactorily removed the wrinkles on the left side of the face. However, it also caused a slight deformity in the upper part of the eyebrows that appeared later during the postoperative period. This may be the result of deflection of the cutting edge.

It may be argued that it is unwarranted to remove healthy muscle to balance the facial muscles. However, this approach not only effectively removed the forehead wrinkles of our patient, it also balanced the left and right sides of the face and allowed antiaging surgery. Our patient, an older woman who had experienced malignant cancer and disfiguring surgery/adjunct therapies, was very satisfied. Another advantage of this approach is that it permanently

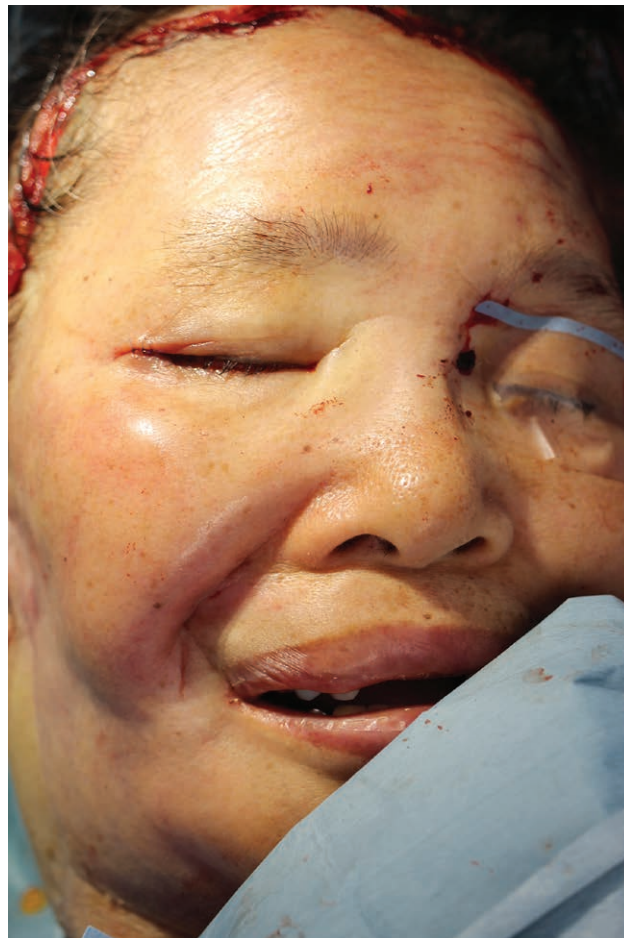

Fig. 5. Photograph of the deep nasolabial groove that was created when we pulled up a loop of 1-0 Prolene that was buried under the skin.

achieved the same results of botulinum-toxin injections, which are widely used to weaken facial-muscle function^{3,4}; indeed, botulinum toxin has also been used to suppress the raising of healthy eyebrows in facial-nerve palsy.⁵

Alam et al⁶ reported that conventional SMAS face-lifts are ineffective for the nasolabial fold in facial nerve palsy. Therefore, they placed an elongated Gore-Tex patch under the nasolabial-fold skin and then hooked and sutured the patch to the temporal fascia with nylon thread. We followed the principles of this procedure by fixing the subcutaneous nasolabial-fold tissue at three points to the temporal fascia with thick nonabsorbable thread (1-0 Prolene). When the three large loops were tightened, the nasolabial fold was suspended from its temporalis-fascia anchor. Our procedure thus employs the concept of the extended minimal-access cranial suspension lift, which was reported by Tonnard and Verpaele,⁷ where three purse-string sutures are placed at different positions in the nasolabial fold and anchored in the temporal fascia. There is one difference between our approach and that of Tonnard and Verpaele⁷: the latter placed the third loop so that tightening it pulled up the malar-fat pad and erased the nasolabial fold, whereas we oriented all three loops so that their tightening distributed tension evenly

between the lifted tissues and stably created a nasolabial fold⁸ (Fig. 5).

It is notable that our surgical protocol was effective despite the patient's high-dose radiotherapy and the resulting extensive subcutaneous-tissue adhesion. Careful undermining of almost half the face and then adjusting the elevator/depressor factors to reconstruct a symmetrical expression led to good effects that persisted 1 year later. Thus, this case shows that even static reconstruction can give facial nerve palsy patients great hope and satisfaction.

With regard to scoring facial palsy severity, we used the House-Brackmann classification.⁹ Although there are also other scoring methods, Niziol et al¹⁰ reported how to combine multiple existing scoring methods and to use photographs and videos to measure eyebrow movements and smiling facial expressions. This approach may become the standard method for scoring facial palsy in the future.

CONCLUSIONS

This case showed that it is worthwhile to reconstruct the cosmetic surface of patients with facial nerve palsy by combining facelift, healthy-frontal myotomy, and wrinkle-removal surgery: our patient, who had a history of malignant cancer, radiation, and refractory facial nerve palsy, was very satisfied with the outcome and expressed that it made her more hopeful.

Shunichi Nomoto, MD

Department of Plastic, Reconstructive and Aesthetic Surgery
Nippon Medical School
1-1-5 Sendagi Bunkyo-ku
Tokyo 113-8603, Japan
E-mail: nomo@nms.ac.jp

PATIENT CONSENT

The patient provided written consent for the use of her image.

REFERENCES

1. Camirand A, Doucet J. A comparison between parallel hairline incisions and perpendicular incisions when performing a face lift. *Plast Reconstr Surg*. 1997;99:10–15.
2. Panfilov DE. Secondary facelift. In Panfilov DE (ed), *Aesthetic Surgery of the Facial Mosaic*. Berlin: Springer-Verlag. 2007:394–401.
3. Carruthers JA, Lowe NJ, Menter MA, et al; BOTOX Glabellar Lines I Study Group. A multicenter, double-blind, randomized, placebo-controlled study of the efficacy and safety of botulinum toxin type A in the treatment of glabellar lines. *J Am Acad Dermatol*. 2002;46:840–849.
4. Binder WJ, Blitzer A, Brin MF. Treatment of hyperfunctional lines of the face with botulinum toxin A. *Dermatol Surg*. 1998;24:1198–1205.
5. Clark RP, Berris CE. Botulinum toxin: a treatment for facial asymmetry caused by facial nerve paralysis. *Plast Reconstr Surg*. 2005;115:573–574.
6. Alam D. Rehabilitation of long-standing facial nerve paralysis with percutaneous suture-based slings. *Arch Facial Plast Surg*. 2007;9:205–209.
7. Tonnard P, Verpaele A. The MACS-lift short scar rhytidectomy. *Aesthet Surg J*. 2007;27:188–198.
8. Tonnard P, Verpaele A, Monstrey S, et al. Minimal access cranial suspension lift: a modified S-lift. *Plast Reconstr Surg*. 2002;109:2074–2086.
9. House JW, Brackmann DE. Facial nerve grading system. *Otolaryngol Head Neck Surg*. 1985;93:146–147.
10. Niziol R, Henry FP, Leckenby JL, et al. Is there an ideal outcome scoring system for facial reanimation surgery? A review of current methods and suggestions for future publications. *J Plast Reconstr Aesthet Surg*. 2015;68:447–456.