

# Embolization with Onyx® of an arterial pseudoaneurysm with an arteriovenous fistula complicating a percutaneous nephrolithotomy: A case report and review of literature

Ana Isabel Simões Ferreira<sup>1</sup>, Filipe Veloso Gomes<sup>2</sup>, Tiago Bilhim<sup>2,3</sup>, Élia Coimbra<sup>2</sup>

<sup>1</sup>Department of Radiology, Centro Hospitalar Lisboa Norte, <sup>2</sup>Department of Radiology (Interventional Radiology Unit), Hepato-Biliary-Pancreatic and Transplant Center, Hospital Curry Cabral, Centro Hospitalar Lisboa Central,

<sup>3</sup>Department of Anatomy, Nova Medical School, Universidade Nova de Lisboa, Lisbon, Portugal

## Abstract

Percutaneous nephrolithotomy (PCNL) has proven very effective in the management of renal stones. However, complications are not so rare, and bleeding is one of the most worrisome; it has a reported incidence of 1%–3% and may happen during track dilatation. In addition, arterial pseudoaneurysms and/or arteriovenous fistulas (AVF) may occur. We report the case of a patient with an intrarenal pseudoaneurysm associated with an AVF, after PCNL. Superselective endovascular embolization with Onyx® was successfully performed, achieving exclusion of the pseudoaneurysm and AVF with preservation of the remaining vascularization of the kidney. We review the literature regarding endovascular management of kidney vascular lesions after PCNL. Selective renal embolization is a minimally invasive procedure, highly effective with a low incidence of complications. Currently, it is considered the most appropriate technique in the treatment of arterial iatrogenic complications following percutaneous renal procedures. Onyx® is an effective, easy to handle, and safe alternative embolic agent for these procedures.

**Keywords:** Arterial pseudoaneurysm, arteriovenous fistula, endovascular treatment, onyx, percutaneous nephrolithotomy

**Address for correspondence:** Dr. Ana Isabel Simões Ferreira, Av. Prof. Egas Moniz, Departamento de Radiologia, Hospital de Santa Maria, 1649-035 Lisboa, Portugal.  
E-mail: anaisabelvnfsf@gmail.com

**Received:** 23.02.2017, **Accepted:** 01.06.2017

## INTRODUCTION

Percutaneous nephrolithotomy (PCNL) has proven very effective in the management of renal stones. However, complications rate after PCNL is in the range of 20%–83%. Major bleeding requiring intervention has a reported incidence of 1%–3% in large series.<sup>[1–4]</sup> In addition, arterial pseudoaneurysms, arteriovenous fistulas (AVF), and arterio-caliceal fistulas may occur, with a reported incidence of 0.9%–2%, 0.2%–1.5%, and 0.3%, respectively.


In 24%–36% of the cases with pseudoaneurysms, there is also an AVF associated.<sup>[2–5]</sup>

Bleeding after PCNL is mainly controlled with conservative treatment options. If it does not cease spontaneously, it can cause gross hematuria or even life-threatening hemorrhage, requiring prompt treatment by transarterial embolization (TAE). Endovascular treatment is recommended in these cases due to its effectiveness and low complications rate.<sup>[6]</sup>

This is an open access journal, and articles are distributed under the terms of the Creative Commons Attribution-NonCommercial-ShareAlike 4.0 License, which allows others to remix, tweak, and build upon the work non-commercially, as long as appropriate credit is given and the new creations are licensed under the identical terms.

**For reprints contact:** reprints@medknow.com

**How to cite this article:** Simões Ferreira AI, Gomes FV, Bilhim T, Coimbra É. Embolization with Onyx® of an arterial pseudoaneurysm with an arteriovenous fistula complicating a percutaneous nephrolithotomy: A case report and review of literature. *Urol Ann* 2018;10:225-8.

Access this article online	
Quick Response Code:	Website: www.urologyannals.com
	DOI: 10.4103/UA.UA_29_17

We report our experience with TAE of a renal pseudoaneurysm and AVF after PCNL, using Onyx® as the primary embolic agent.

### CASE REPORT

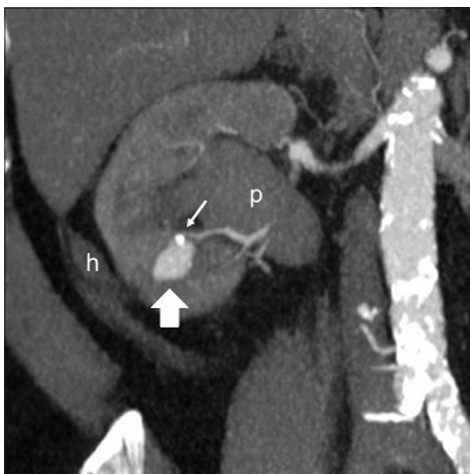A 68-year-old male treated with a standard PCNL for a 30 mm inferior caliceal stone in the right kidney, using an intracorporeal ultrasonic lithotripter, started complaining of intermittent hematuria after being discharged home. Thirteen days later, he had an episode of urinary retention that led him back to the hospital. Blood tests showed a drop in hemoglobin level (14.6–11.9 mg/dL) and normal renal function. Initial ultrasound (US) documented hydronephrosis, multiple clots in the right renal pelvis and bladder. A Foley catheter was placed confirming macroscopic hematuria, irrigation and washout procedures were started. A contrast-enhanced computed tomography (CT) revealed a pseudoaneurysm of a segmental artery in the PCNL “track” [Figures 1 and 2]; additionally, the CT confirmed the US findings and showed a double-J stent incorrectly positioned and a residual 6 mm stone. The patient was initially managed conservatively. Ureterorenoscopy was performed for blood clot evacuation and repositioning of a double-J stent. Following the intervention there was a further drop of hemoglobin (8.1 mg/dL), blood transfusions were required, and the patient was referred for digital subtraction angiography (DSA).

Selective renal angiography was performed, through right retrograde femoral access, using a 5F vascular sheath and a 5F cobra catheter advanced over a hydrophilic 0.035 inch guidewire. A 2.7F coaxial microcatheter was advanced, over 0.021 inch guidewire, enabling superselective approach of

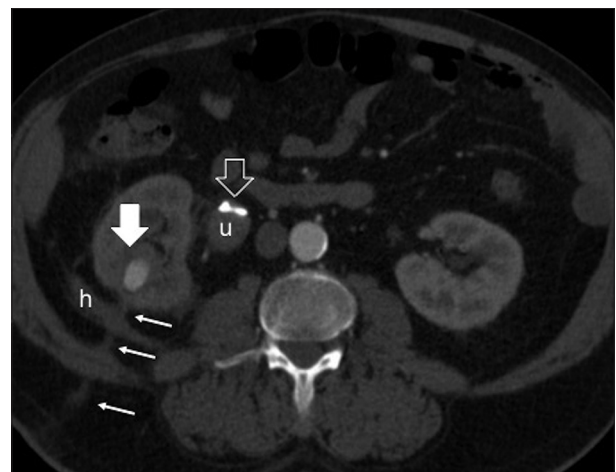the feeding artery, confirming a pseudoaneurysm originating from an inferior pole branch and further documenting an AVF [Figures 3 and 4]. To perform embolization, 0.6 mL of dimethyl sulfoxide (DMSO) were injected to fill the microcatheter’s dead space, followed by 0.8 mL of Onyx18®, at a rate of approximately 0.1 mL/min, under fluoroscopic control. Exclusion of the pseudoaneurysm and the AV fistula was successfully achieved, with preservation of the remaining vascularization of the right kidney and no evident parenchymal loss [Figures 5 and 6]. Doppler US was performed in the angiosuite before and after the procedure confirming the findings [Figure 7]. Total procedure time was 40 min; no immediate complications were registered and hematuria disappeared 3 days later. The patient remained asymptomatic, and no relapse was found at 3-month CT follow-up.

### DISCUSSION

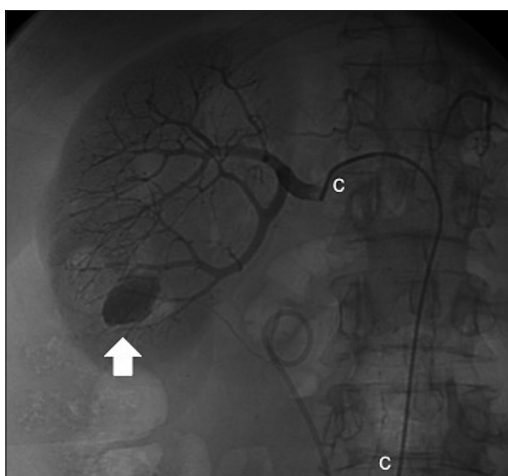
Symptoms of bleeding after PCNL may present within the first 24 hours or as far as 20 days, although the mean time to the onset varies between 6 and 8 days in large series.<sup>[2-8]</sup> Noninvasive diagnostic modalities, US and CT, should be included in the initial work-up, but DSA remains the gold standard.<sup>[9]</sup> When PCNL complicates with bleeding that cannot be controlled with conservative treatment, DSA is used both as a diagnostic and therapeutic modality. DSA should be considered in case of gross hematuria-related tachycardia, a serum haemoglobin level <10 g/dL, and hypotension resulting in hemodynamic instability and requiring blood transfusions.<sup>[5]</sup> The most common angiographic findings associated with hemorrhage after PCNL are arterial pseudoaneurysms and/or AVF; less



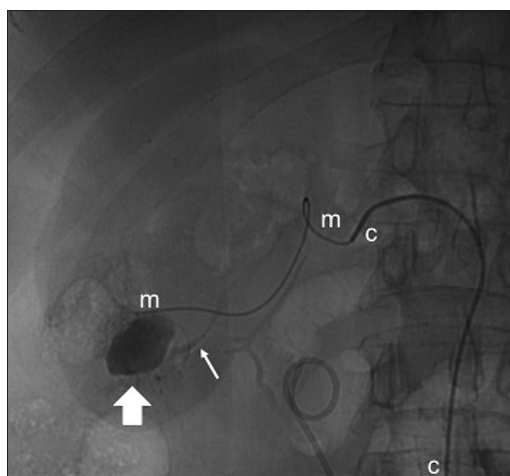
**Figure 1:** Enhanced computed tomography multiplanar reconstruction showing the pseudoaneurysmal sac (thick arrow) at the lower renal pole near a residual millimetric inferior caliceal stone (thin arrow) in the right kidney. Enlarged renal pelvis (p). Small right perirenal hematoma (h)



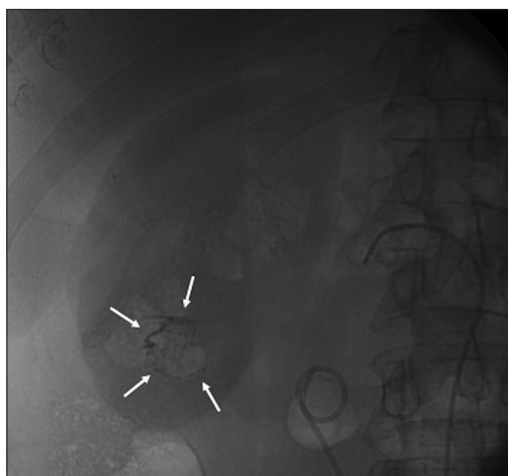
**Figure 2:** Enhanced computed tomography axial view showing the pseudoaneurysm (thick arrow) at the percutaneous nephrolithotomy “track” (thin arrows). Small right perirenal hematoma (h). Notice the double-J catheter (open arrow) incorrectly positioned at the lumbar ureter (u), not seen at the enlarged renal pelvis (p) in Figure 1



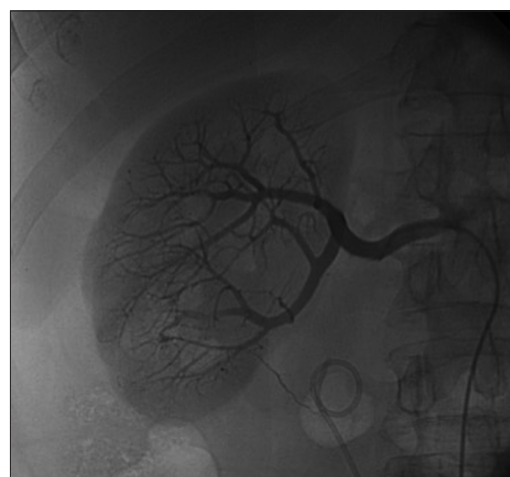
**Figure 3:** Digital subtraction angiography before embolization, with the 5F cobra catheter (c) selectively positioned at the right renal artery, showing the pseudoaneurysm (thick arrow)



**Figure 4:** Digital subtraction angiography during embolization, with the 2,7F coaxial microcatheter (m) selectively positioned at the feeding artery showing the pseudoaneurysm (thick arrow) and further documenting an arteriovenous fistula (thin arrow) at the lower renal pole



**Figure 5:** Digital subtraction angiography after embolization, showing Onyx® (thin arrows) at the distal extremity of the feeding artery, the pseudoaneurysmal sac and the proximal extremity of the venous component of the fistula



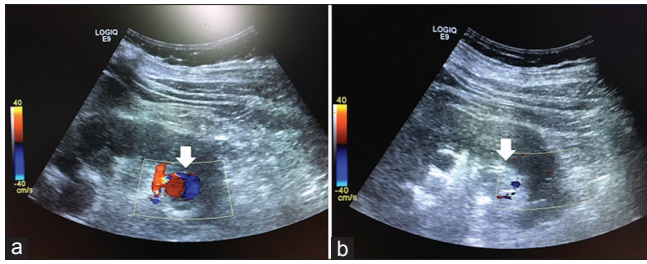
**Figure 6:** Control digital subtraction angiography after embolization, showing successful exclusion of the pseudoaneurysm and the arteriovenous fistula, with preservation of the remaining vascularization of the right kidney and no evident parenchymal loss

often arterio-caliceal fistulas, lumbar artery injury or active hemorrhage may also be found.<sup>[2-5]</sup> The lesions responsible for hematuria are believed to happen after trauma, during track dilatation and are nearly always located in segmental arteries, which supply a small portion of the kidney that can be embolized.<sup>[4,10]</sup> The lacerated artery is a high-pressure system and will leak into the lower pressure system of a vein leading to AVF formation or the parenchyma or hilar areolar tissue leading to pseudoaneurysm formation.<sup>[2]</sup>

Selective renal embolization is currently considered the most appropriate technique in the treatment of vascular complications of percutaneous renal procedures, with a success rate >80% and low complications rate.<sup>[6]</sup> Microcatheters are used to allow a superselective approach of the distal segmental branches, minimizing loss of viable

tissue.<sup>[5]</sup> Endovascular techniques have a lower complication rate than surgical management. Complications that can develop during TAE are limited and include complications related to femoral arterial puncture; selective catheterization of a vessel; and embolization-related complications, such as nontarget embolization and postembolization syndrome. When AVF is present, there is a possible risk of migration of the embolic agent to the venous system, which may be complicated of pulmonary embolism. Late complications such as vascular recanalization have seldom been reported.<sup>[5,9]</sup>

Various embolic agents are available to treat vascular complications of PCNL including coils, particulate agents (e.g., gelfoam) and liquid agents (e.g. Onyx®; n-butyl cyanoacrylate [n-BCA]). They can be used either alone



**Figure 7:** Ultrasound with color Doppler. (a) Before embolization, showing turbulent flow in the pseudoaneurysmal sac (arrow) at the lower kidney pole. (b) After embolization, showing higher echogenicity in the pseudoaneurysmal sac (arrow), due to Onyx<sup>®</sup>, with no flow

or as complementary tools. Onyx<sup>®</sup> has been used for the endoluminal treatment of vascular cerebral malformations, as a permanent and efficient occluding agent, for several years. However, there are few reports concerning embolization of iatrogenic intrarenal pseudoaneurysm and AFV with Onyx<sup>®</sup>.<sup>[11,12]</sup> Onyx<sup>®</sup> is a biocompatible polymer, ethylene vinyl alcohol copolymer (EVOH), that is dissolved in an organic solvent, DMSO. When it enters in contact with blood, the DMSO rapidly diffuses, leaving the EVOH to precipitate and solidify as a spongy embolus at the tip of the catheter.<sup>[11,12]</sup> It has a lava-like flow pattern and long solidification time. In addition, the injection can be interrupted and continued again until the desired result is achieved. Therefore, Onyx<sup>®</sup> can be delivered in a slower, accurate and more controlled way than other embolic agents, reducing significantly the risk of ischemic complications and reflux to the venous component of AVF.<sup>[11]</sup> Unlike n-BCA, it causes no postprocedural pain, neither catheter adhesion.<sup>[5]</sup> From a surgical point of view, Onyx<sup>®</sup> is a suitable preoperative embolic agent, since it is mechanically occlusive but not adherent to the arterial wall.<sup>[11]</sup>

In conclusion, we performed embolization with Onyx<sup>®</sup> of an iatrogenic pseudoaneurysm on a segmental arterial renal branch associated with an AVF. It allowed a controlled, fast, painless, safe and effective embolization.

## Financial support and sponsorship

Nil.

## Conflicts of interest

There are no conflicts of interest.

## REFERENCES

1. Kaufman JA, Lee MJ. *Vascular and Interventional Radiology: The Requisites*. 2<sup>nd</sup> ed. Philadelphia: Elsevier Saunders; 2014.
2. Srivastava A, Singh KJ, Suri A, Dubey D, Kumar A, Kapoor R, Mandhani A, Jain S. Vascular complications after percutaneous nephrolithotomy: Are there any predictive factors? *Urology* 2005;66:38-40.
3. El-Nahas AR, Shokeir AA, El-Assmy AM, Mohsen T, Shoma AM, Eraky I, El-Kenawy MR, El-Kappany HA. Post-percutaneous nephrolithotomy extensive hemorrhage: A study of risk factors. *J Urol* 2007;177:576-9.
4. Tan TJ, Teh HS, Pua U, Ho SH. Endovascular management of iatrogenic renal vascular injuries complicating percutaneous nephrolithotripsy: Role of renal angiography and superselective coil embolisation. *J HK Coll Radiol* 2008;11:103-7.
5. Kervancioglu S, Gelebek Yilmaz F, Erturhan S. Endovascular management of vascular complications after percutaneous nephrolithotomy. *Vasa* 2014;43:459-64.
6. Soyer P, Desgrippes A, Vallée JN, Rymmer R. Intrarenal pseudoaneurysm after percutaneous nephrostolithotomy: Endovascular treatment with N-butyl-2-cyanoacrylate. *Eur Radiol* 2000;10:1358.
7. Ozturk H. Intrarenal pseudoaneurysm after percutaneous nephrolithotomy at solitary kidney. *Nephrourol Mon* 2014;6:e19037.
8. Falahatkar S, Hemmati H, Mokhtari G, Assadollahzadeh A, Allahkhah A. Intrarenal Pseudoaneurysm after percutaneous nephrolithotomy: A rare and important complication of minimally invasive surgery. *UroToday Int J* 2011;4:2.
9. Chandradev S, Ateesh S. Endovascular and percutaneous management of the pseudoaneurysms. *Open J Radiol* 2014;4:241-54.
10. Abath C, Andrade G, Cavalcanti D, Brito N, Marques R. Complex renal artery aneurysms: Liquids or coils? *Tech Vasc Interv Radiol* 2007;10:299-307.
11. Rennert J, Herold T, Schreyer AG, Banas B, Jung EM, Feuerbach S, *et al.* Evaluation of a liquid embolization agent (Onyx) for transcatheter embolization for renalvascular lesions. *Rofo* 2009;181:996-1001.
12. Zelenák K, Sopilko I, Svihra J, Kliment J. Successful embolization of a renal artery pseudoaneurysm with arteriovenous fistula and extravasations using Onyx after partial nephrectomy for renal cell carcinoma. *Cardiovasc Intervent Radiol* 2009;32:163-5.